

Effect of N-acetylcysteine on intimal hyperplasia and endothelial proliferation in rabbit carotid artery anastomosis

Ali Ayca Kavala, Yusuf Kuserli, Saygin Turkyilmaz

Department of Cardiovascular Surgery, Bakirkoy Dr Sadi Konuk Education and Research Hospital Bakirkoy, Istanbul, Turkey

Submitted: 19 June 2018

Accepted: 7 August 2018

Arch Med Sci 2019; 15 (6): 1576–1581

DOI: <https://doi.org/10.5114/aoms.2018.77769>

Copyright © 2018 Termedia & Banach

Corresponding author:

Saygin Turkyilmaz
Department of
Cardiovascular Surgery
Bakirköy Dr Sadi Konuk
Education and
Research Hospital
İstanbul, Turkey
Phone: +90 5052557993
E-mail: sygnty@hotmail.com

Abstract

Introduction: Neointimal hyperplasia due to smooth muscle cell migration and proliferation, as well as extracellular matrix accumulation, plays an important role in stenosis and restenosis that develop after reconstructive vascular interventions. Various agents are being tested to reduce neointimal hyperplasia and to prevent lumen stenosis. In the present study, the effect of N-acetylcysteine (NAC) on intimal hyperplasia and endothelial hyperplasia after carotid anastomosis was investigated in a rabbit model.

Material and methods: In the course of the study, rabbits were divided into two groups. The control group ($n = 7$) underwent right carotid artery anastomosis and received no medication. The NAC group ($n = 7$) underwent right carotid artery anastomosis and received NAC for 21 days following surgery. NAC was administered at a dose of 150 mg/kg/day just after the surgery. The carotid artery underwent anastomosis, and the histological examination findings of anastomosed and opposite non-anastomosed carotid arteries were compared in two experimental groups that either received NAC or did not.

Results: Compared with the control group, the reduction in the lumen area and diameter after anastomosis was significantly recovered in the NAC group ($p = 0.018$; $p = 0.612$). Increases in the intima and media areas and the intima/media ratio were smaller in the NAC group after anastomosis than in the control group, but the differences were not significant.

Conclusions: We believe that vascular anastomosis and post-intervention NAC administration will prolong vascular patency by reducing intimal hyperplasia and providing vascular remodeling.

Key words: N-acetylcysteine, intimal hyperplasia, endothelial proliferation, carotid artery.

Introduction

Vascular reconstruction is one of the methods frequently used for the treatment of obstructive arterial diseases; however, the success of these interventions is less than expected because of development of thrombosis or stenosis [1]. Unlike the formation of acute thrombus that causes sudden obstruction after reconstructive vascular interventions, neointimal hyperplasia due to smooth muscle cell migration and proliferation as well as extracellular matrix accumulation plays an important role in stenosis and restenosis in the late period [2]. In the animal and human models of arterial injury, smooth muscle cell proliferation and connective

tissue accumulation in intima have been defined as the main causes of lumen stenosis [3].

Each arterial reconstruction procedure causes partial endothelial injury. The most common cause of this injury is the various degrees of trauma occurring during the graft removal procedure and anastomosis. Subendothelial fibroproliferation and formation of neointima are the intimal responses to endothelial injury. Although this intimal neoplastic response is a part of vascular repair after trauma, it might be unnecessarily severe under certain conditions. As a result of excessive neointimal proliferation, impairment of the anticoagulant property of endothelium, and lumen stenosis, blood flow decreases and thrombosis may occur in some cases [4]. More *et al.* observed unusual intimal thickening after 3 days of ballooning in rabbits, re-endothelialization started, and on the 14th day this process was completed. It has been determined that intimal thickening reaches the maximum level at the end of the first month and decreases within 3 months due to extracellular matrix accumulation [5].

Vascular inflammation developed by free oxygen radicals resulting from leukocyte and thrombocyte activation in the coronary angioplasty region plays a major role in vascular restenosis [6]. Antioxidants may modify neointima formation and vascular remodeling by inhibiting this inflammatory reaction [7]. Glutathione acts as a nucleophilic scavenger and an antioxidative catalyst in oxidative tissue injury [8]. Thus, it has a major role in preserving biological structures and functions. Intracellular reduced glutathione plays an important role in the protection of endothelial cells against free oxygen radicals [9]. It has been demonstrated to enhance the endothelial vasomotor response to acetylcholine when directly infused into the coronary arteries [10]. Intravenous N-acetylcysteine (NAC) administration has also been demonstrated to have similar effects as glutathione on endothelial functions due to its capability of inducing glutathione synthesis [11]. Studies conducted by Jeremias *et al.* have shown that NAC administered at the dose of 150 mg/kg/day effectively increases serum glutathione levels [12].

N-acetylcysteine is the N-acetylated derivative of the natural amino acid L-cysteine. N-acetylcysteine displays a direct antioxidant property by interacting with the electrophilic group of oxidative radicals via its free thiol (-SH) nucleophilic group [13]. N-acetylcysteine, which easily enters into the cell owing to its molecular structure, is acetylated there and turns into L-cysteine. L-cysteine is a glutathione precursor and enhances glutathione synthesis [14–16]. Glutathione is a highly reactive tripeptide, which protects cells against harmful effects of exogenous or endogenous cytotoxic sub-

stances and oxidative radicals, and plays a major role in an endocellular mechanism for the maintenance of cellular integrity and functions [17]. From this aspect, NAC is of primary importance in glutathione synthesis at a level that would protect the cells against injury. N-acetylcysteine is a source of sulfhydryl groups. Sulfhydryl groups have many biological functions, including scavenging free oxygen radicals and modifying the half-life of NO [18].

Various clinical trials and animal studies, in which various agents including lipid-lowering drugs, anti-platelet agents, immunosuppressants, and antioxidants were investigated to reduce neointimal hyperplasia and to prevent lumen stenosis, have been conducted [19].

In the present study, the effect of NAC, which is an antioxidant, on intimal hyperplasia and endothelial proliferation after carotid anastomosis was investigated in a rabbit model. For this purpose, histological findings of anastomosed and opposite non-anastomosed carotid arteries of the same experimental animals were compared in two distinct experimental groups, which either received NAC or did not.

Material and methods

Experimental animals

The present randomized, controlled, experimental trial study was started after the approval of Dokuz Eylül University Medical Faculty, Experimental Animals Ethics Committee. The study included 14 randomly selected New Zealand-type male rabbits weighing 2–3 kg on average. In the course of the study, all experimental animals were kept under the same conditions (in a room at temperature of 20 ± 2°C with a ventilation system and receiving sunlight) and fed rabbit feed. Rabbits were divided into two groups. The control group (*n* = 7) underwent right carotid artery anastomosis and received no medication. The NAC group (*n* = 7) underwent right carotid artery anastomosis and received NAC for 21 days following surgery. NAC was administered at a dose of 150 mg/kg/day just after the surgery. The initial dose was given via the intravenous route and subsequent doses were given via the intramuscular route.

Anastomosis

All anastomoses were performed by the same researcher. A cannula was preoperatively inserted into the marginal vein of the ear of the rabbits. Anesthesia was induced with 50 mg/kg intramuscular ketamine and 5 mg/kg intramuscular xylazine. Incision areas were shaved to provide better vision during surgery and disinfected with povidone-iodine. The right carotid artery was explored through a right vertical neck incision. Intravenous heparinization was performed at a dose of

100 IU/kg. The right carotid artery was transected after clamping proximal and distal segments with a bulldog clamp. Afterwards, anastomosis was completed by suturing one by one with 8-0 polypropylene suture, and tissues were closed in an anatomical layer. The procedure was performed using a loop with 3.5× magnification.

All experimental animals were alive in the course of the study. None of the rabbits developed any wound site infection or neurological problem at the end of the postoperative 28th day. All experimental animals were sacrificed using pentobarbital at the end of the 28th day, and the right anastomosed and the left non-anastomosed carotid artery segments were removed and sent to the histology laboratory for examination.

Histopathological examination

After right and left carotid artery segments were fixed with 10% buffered formaldehyde solution and embedded in paraffin, 5 µm serial sections were obtained from these paraffin blocks using a rotary microtome (Leica RM 2135, Leica Instruments, Nussloch, Germany). These sections were stained with hematoxylin and eosin and additionally with Verhoeff-Van Gieson stain. The prepared slides were examined under the light microscope (Olympus BX-50, Tokyo, Japan). Furthermore, the acquired images were transferred to a computer via a high-resolution camera (Olympus DP-70, Japan) and then evaluated by a digital image analysis program (Image Tool, UTHSC Image software for Windows 3.0, Texas University, USA). During the examination of vascular tissue, tunica intima and tunica media thicknesses, tunica intima and tunica media areas, vascular diameters, and vascular lumen areas were measured with serological methods. These parameters were assessed for both anastomosed and non-anastomosed arteries of the control and NAC groups.

Statistical analysis

Data were analyzed using SPSS (SPSS Inc., Chicago, IL, USA) version 15.0. Data were expressed as mean ± standard deviation. For non-normally distributed numerical variables, comparison between independent two groups was performed using the Mann Whitney-U test and comparison between two dependent groups was performed using the Wilcoxon signed-rank test. A *p*-value < 0.05 was considered significant.

Results

The results of the histological measurements of anastomosed and non-anastomosed carotid arteries of the NAC and control groups are presented in Table I. The images of internal elastic lamina of the groups stained with hematoxylin and eosin

are shown in Figure 1, and Verhoeff elastic stain images are shown in Figure 2.

The mean values of lumen, intima and media areas and the ratio of intima area/media area of non-anastomosed arteries were similar in the control and NAC groups, whereas they were significantly different for anastomosed arteries except media area. Lumen diameter of both the anastomosed and non-anastomosed arteries showed a significant difference between the control and NAC groups; it was also significantly narrower in the anastomosed arteries compared to that in the non-anastomosed arteries in both groups (Table I). While lumen area was significantly lower in the anastomosed arteries of the control group, no difference was observed between anastomosed and non-anastomosed arteries of the NAC group. Carotid artery intima area was found to be significantly larger in the anastomosed arteries than that in the non-anastomosed arteries in both the control and NAC groups. While media area was significantly larger in the anastomosed arteries of the control group, no difference was found between anastomosed and non-anastomosed arteries of the NAC group. A significantly higher intima/media ratio was observed in the anastomosed arteries as compared to non-anastomosed arteries in both groups (Table I).

Comparing the percentages of changes in the parameters of both the control and NAC groups after anastomosis, the reduction in the lumen diameter and area was significantly smaller in the NAC group compared to the control group. Although the percentage increases in intima and media areas were lower in the NAC group, there was no significant difference between the control and NAC groups (Table II).

Discussion

N-acetylcysteine is considered to have important cytoprotective effects [8]. Endogenous antioxidants (such as glutathione) are depleted during tissue reperfusion following sepsis, trauma, burns, pancreatitis, hepatic failure, hemorrhage, and acute myocardial infarction and related cellular injuries and thus they may mediate production and release of numerous free radicals. N-acetylcysteine is an oxidative free radical scavenger. Moreover, NAC is a glutathione precursor through its capability of replacing depleted intracellular glutathione and its role in the additional antioxidant defense theory [20, 21]. In studies, NAC has been demonstrated to be successful in preventing nephropathy in experimental models [22, 23]. N-acetylcysteine stimulates glutathione synthesis and potentiates nitroglycerine-mediated coronary artery vasodilatation as well [24]. Likewise, it potentiates the inhibitory effect of platelet aggregation

Table I. Histological measurements of the anastomosed and non-anastomosed carotid arteries of the study groups

Parameter	Control group	NAC group	P-value
Lumen diameter [μm]:			
Non-anastomosed	822.0 \pm 43.4	1021.2 \pm 139.4	0.004
Anastomosed	556.2 \pm 73.3	836.9 \pm 41.1	0.001
P-value	0.018	0.028	
Lumen area [μm^2]:			
Non-anastomosed	443289.2 \pm 62461	515336.6 \pm 217288.6	0.620
Anastomosed	165695.8 \pm 50279.2	419170.4 \pm 40959	0.001
P-value	0.018	0.612	
Intima area [μm^2]:			
Non-anastomosed	11681.8 \pm 1496.6	10149.1 \pm 3242.7	0.383
Anastomosed	104350.3 \pm 22827.9	52014.4 \pm 35605.3	0.011
P-value	0.018	0.018	
Media area [μm^2]:			
Non-anastomosed	383848.8 \pm 40308.7	407709.5 \pm 114100.6	0.805
Anastomosed	473009.4 \pm 91112.2	435646.6 \pm 47598.5	0.259
P-value	0.043	0.735	
Intima/media ratio:			
Non-anastomosed	0.1 \pm 0.1	0.1 \pm 0.1	0.209
Anastomosed	0.221 \pm 0.027	0.2 \pm 0.1	0.026
P-value	0.018	0.018	

Values are presented as mean \pm standard deviation. NAC – N-acetylcysteine.

of nitroglycerine [25]. A study on an animal model demonstrated that NAC reduced the release of matrix metalloproteinases from macrophages, called foam cells, in atherosclerotic plaques, and thus it contributed to plaque stabilization [26].

Recent studies have shown that NAC is an important regulator of nuclear factor- κB (NF- κB) activity in endothelial and smooth muscle cells. NAC regulates neointimal formation by promoting upregulation of specific adhesion molecules and post-injury vascular cell activation of endothelial cells and smooth muscle cells via NF- κB inhibition [27].

In their study, Ghigliotti *et al.* [28] compared NAC and heparin in a rabbit model of abdominal aortic balloon injury and reported that NAC provided considerable reduction in smooth muscle cell proliferation and intimal hyperplasia and substantially contributed to vascular remodeling. In a study by Jeremias *et al.* [29], although a significant increase in glutathione levels was obtained due to NAC administration after experimental endothelial damage in the iliac arteries of rabbits via balloon angioplasty, no significant difference was observed regarding restenosis and inflammatory markers between the groups. In contrast, Mass *et al.* [30] reported significant decreases in inflammatory markers, endothelial damage, thrombus formation, and elastic lamina injury in the rabbit carotid arteries in an experimental balloon injury model after NAC administration. They suggested

that NAC had the potential of inhibiting the inflammatory process developed after mechanical vascular damage. In these three studies, the damage caused by the balloon is only in the intima layer. We believe that the anastomosis model used in our study is a more suitable model for intimal hyperplasia developed after surgery because it damages all the layers of the artery.

In the present study, while reduction in the lumen area and diameter after anastomosis was significantly improved in the NAC group as compared to the control group, increases in the intima and media areas and intima/media ratio were smaller in the NAC group after anastomosis as compared to those in the control group, but the difference was not significant. We concluded that this effect of NAC resulted from its antioxidant property and its capability of regulating proliferation and migration of vascular smooth muscle cells [31, 32]. In a study by Kanber *et al.* [33], early restenosis in diabetic and non-diabetic patients undergoing carotid endarterectomy was evaluated but no difference was found. More information may be provided as a result of the examination of the vessel patency in similar patient groups using NAC.

In conclusion, we opine that vascular anastomosis and post-intervention NAC administration will prolong vascular patency by reducing intimal hyperplasia and providing vascular remodeling.

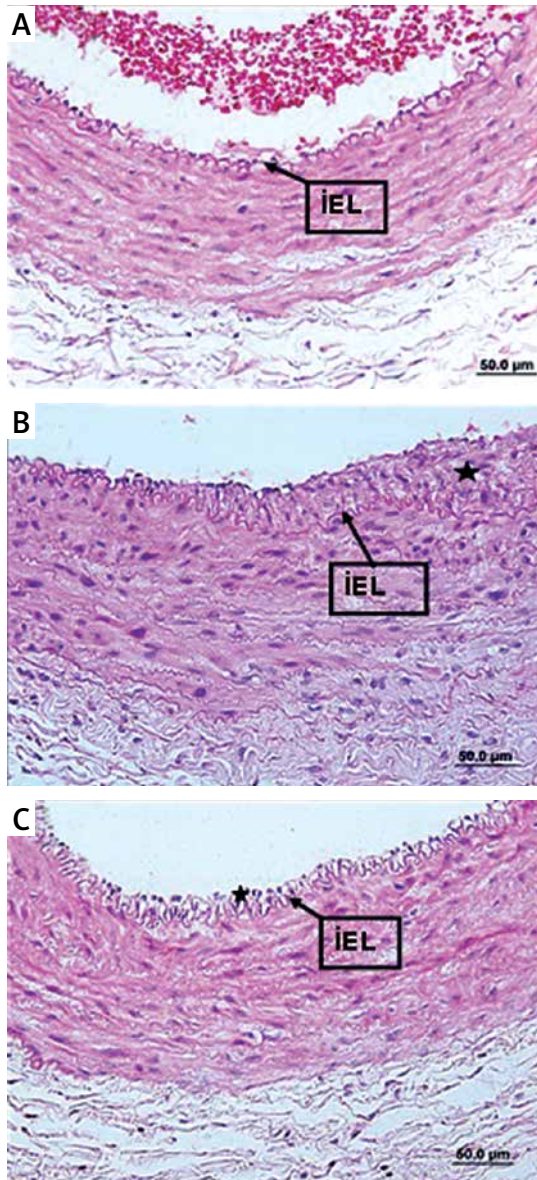


Figure 1. Images of internal elastic lamina of the groups stained with hematoxylin and eosin (A – control group, non-anastomosed, B – control group, anastomosed, C – NAC group, anastomosed. IEL – internal elastic lamina)

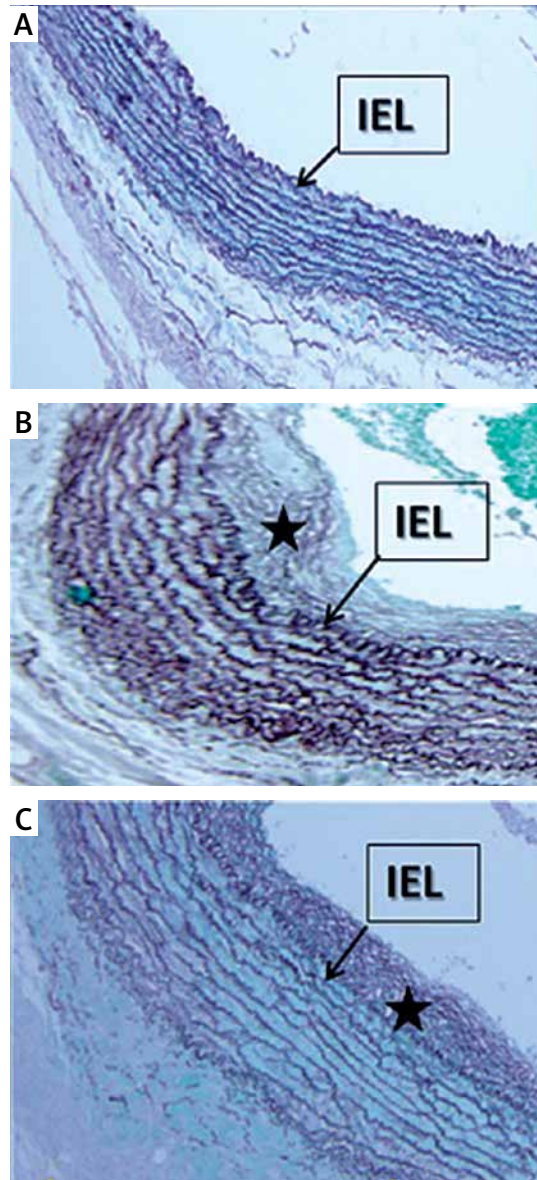


Figure 2. Verhoeff elastic stain images of the groups. A – Verhoeff elastic stain of the non-anastomosed arteries in the control group. B – Verhoeff elastic stain of the carotid anastomosis in the control group, the elastic fibrils were disorganized and irregular. C – Verhoeff elastic stains of the carotid anastomosis in the N-acetylcysteine administered group, the elastic fibrils were more organized and regular compared to those in the control group
→ indicates membrane elastic interna, *intimal hyperplasia.

Table II. Percentage of changes in the parameters after anastomosis in the study groups

Variable	Control group	NAC group	P-value
% change in lumen diameter	-32.4 ±8.2	-16.7 ±12.7	0.007
% change in lumen area	-62.4 ±12.4	-9.8 ±26.1	0.001
% change in intima area	805.1 ±246.1	471.1 ±422	0.165
% change in media area	24.2 ±28.3	13.5 ±31.6	0.535
% change in intima/media ratio	641 ±186.3	364.6 ±285.7	0.073

Values are presented as mean ± standard deviation. NAC – N-acetylcysteine.

Conflict of interest

The authors declare no conflict of interest.

References

- Davies MG. Intimal hyperplasia: basic response to arterial and vein graft injury and reconstruction. In: *Vascular Surgery*. 6th ed. Rutherford RB (ed.). Elsevier Saunders; Philadelphia 2005; 149-72.
- Pauletto P, Sartore S, Pessina AC. Smooth-muscle-cell proliferation and differentiation in neointima formation and vascular restenosis. *Clin Sci (Lond)* 1994; 87: 467-79.
- Takahashi A, Taniguchi T, Ishikawa Y, Yokoyama M. Trilast inhibits vascular smooth muscle cell growth and intimal hyperplasia by induction of p21(waf1/cip1/sdi1) and p53. *Circ Res* 1999; 84: 543-50.
- Zubilewicz T, Wronski J, Bourriez A, et al. Injury in vascular surgery: the intimal hyperplastic response. *Med Sci Monit* 2001; 7: 316-24.
- More RS, Ruddy G, Underwood MJ, Brack MJ, Gershlick AH. A time sequence of vessel wall changes in an experimental model of angioplasty. *J Pathol* 1994; 172: 287-92.
- Ip JH, Fuster V, Israel D, et al. The role of platelets, thrombin and hyperplasia in restenosis after coronary angioplasty. *J Am Coll Cardiol* 1991; 17 (6 Suppl B): 77B-88B.
- Rosenbaum MA, Miyazaki K, Graham LM. Hypercholesterolemia inhibits endothelial cell healing after arterial injury through reactive oxygen species. *J Vasc Surg* 2012; 55: 489-96.
- Ruffmann R, Wendel A. GSH rescue by N-acetylcysteine. *Klin Wochenschr* 1991; 69: 857-62.
- Meister A. Glutathione-ascorbic acid antioxidant system in animals. *J Biol Chem* 1994; 269: 9397-400.
- Kugiyama K, Ohgushi M, Motoyama T, et al. Intracoronary infusion of reduced glutathione improves endothelial vasomotor response to acetylcholine in human coronary circulation. *Circulation* 1998; 97: 2299-301.
- Nishikawa Y, Kanki H, Ogawa S. Differential effects of N-acetylcysteine on nitroglycerin- and nicorandil-induced vasodilation in human coronary circulation. *J Cardiovasc Pharmacol* 1998; 32: 21-8.
- Jeremias A, Dusa C, Forudi F, et al. N-acetyl-cysteine in the prevention of vascular restenosis after percutaneous balloon angioplasty. *Int J Cardiol* 2004; 95: 255-60.
- Aruoma OI, Halliwell B, Hoey BM, Butler J. The antioxidant action of N-acetylcysteine: its reaction with hydrogen peroxide, hydroxyl radical, superoxide, and hypochlorous acid. *Free Radical Biol Med* 1989; 6: 593-7.
- Penugonda S, Ercal N. Comparative evaluation of N-acetylcysteine (NAC) and N-acetylcysteine amide (NACA) on glutamate and lead-induced toxicity in CD-1 mice. *Toxicol Lett* 2011; 201: 1-7.
- Neal R, Cooper K, Gurer H, Ercal N. Effects of N-acetylcysteine and 2,3-dimercaptosuccinic acid on lead induced oxidative stress in rat lenses. *Toxicology* 1998; 130: 167-74.
- Moldéus P, Cotgreave IA. N-acetylcysteine. *Methods Enzymol* 1994; 234: 482-92.
- Ruffmann R, Wendel A. GSH rescue by N-acetylcysteine. *Klin Wochenschr* 1991; 69: 857-62.
- Stamler JS, Slivka A. Biological chemistry of thiols in the vasculature and in vascular-related disease. *Nutr Rev* 1996; 54: 1-30.
- Desai M, Mirzay-Razzaz J, von Delft D, et al. Inhibition of neointimal formation and hyperplasia in vein grafts by external stent/sheath. *Vasc Med* 2010; 15: 287-97.
- Bakker J, Zhang H, Depierreux M, van Asbeck S, Vincent JL. Effects of N-acetylcysteine in endotoxic shock. *J Crit Care* 1994; 9: 236-43.
- Rackow EC, Astiz ME. Pathophysiology and treatment of septic shock. *JAMA* 1991; 266: 548-54.
- Conesa EL, Valero F, Nadal JC, et al. N-acetyl-L-cysteine improves renal medullary hypoperfusion in acute renal failure. *Am J Physiol Regul Integr Comp Physiol* 2001; 281: R730-7.
- Tepel M, van der Giet M, Schwarzfeld C, et al. Prevention of radiographic-contrast-agent-induced reductions in renal function by acetylcysteine. *N Engl J Med* 2000; 343: 180-4.
- Winniford MD, Kennedy PL, Wells PJ, Hillis LD. Potentiation of nitroglycerin-induced coronary dilatation by N-acetylcysteine. *Circulation* 1986; 73: 138-42.
- Chirkov YY, Horowitz JD. N-Acetylcysteine potentiates nitroglycerin-induced reversal of platelet aggregation. *J Cardiovasc Pharmacol* 1996; 28: 375-80.
- Galis ZS, Asanuma K, Godin D, Meng X. N-acetyl-cysteine decreases the matrix-degrading capacity of macrophage-derived foam cells: new target for antioxidant therapy? *Circulation* 1998; 97: 2445-53.
- Hayashi K, Pu H, Tian J, et al. HIV-Tat protein induces P-glycoprotein expression in brain microvascular endothelial cells. *J Neurochem* 2005; 93: 1231-41.
- Ghigliotti G, Mereto E, Eisenberg PR, et al. N-acetyl-cysteine reduces neointimal thickening and procoagulant activity after balloon-induced injury in abdominal aortae of New Zealand white rabbits. *Thromb Haemostasis* 2001; 85: 724-9.
- Jeremias A, Dusa C, Forudi F, et al. N-acetyl-cysteine in the prevention of vascular restenosis after percutaneous balloon angioplasty. *Int J Cardiol* 2004; 95: 255-60.
- Mass H, Pirazzi B, Gonzalez P, Collazo V, Fitzovich D, Avakian E. N-acetylcysteine diminishes injury induced by balloon angioplasty of the carotid artery in rabbits. *Biochem Biophys Res Commun* 1995; 215: 613-8.
- Gawaz M, Brand K, Dickfeld T, et al. Platelets induce alterations of chemotactic and adhesive properties of endothelial cells mediated through an interleukin-1-dependent mechanism. Implications for atherogenesis. *Atherosclerosis* 2000; 148: 75-85.
- Lee JS, Kypreos KE, Sonenshein GE. Synchronization of cultured vascular smooth muscle cells following reversal of quiescence induced by treatment with the antioxidant N-acetylcysteine. *Exp Cell Res* 1998; 239: 447-53.
- Kanber EM, Ugurlucan M, Sahin M, Saribal D, Alpagut U. Do standard carotid artery endarterectomy and primary closure technique cause early restenosis in diabetic patients? *Arch Med Sci Atheroscler Dis* 2017; 2: e103-7.