

# Primary Duodenal Adenocarcinoma without Stenosis: A Case Report with a Brief Literature Review

Daisuke Usuda<sup>a</sup> Yu Hashimoto<sup>a</sup> Emiri Muranaka<sup>a</sup> Hideyuki Okamura<sup>b</sup>  
Tsugiyasu Kanda<sup>a</sup> Sachio Urashima<sup>b</sup>

Departments of <sup>a</sup>Community Medicine and <sup>b</sup>Gastroenterology, Himi Municipal Hospital, Kanazawa Medical University, Himi-shi, Japan

## Key Words

Primary duodenal adenocarcinoma, without stenosis · Primary duodenal adenocarcinoma, first portion · Primary duodenal adenocarcinoma, third portion · Best supportive care · Symptoms · Clinical manifestations

## Abstract

This article focuses on the symptomatic and diagnostic problems of primary duodenal adenocarcinoma (PDA) by way of two case reports and a literature review. An 85-year-old woman with an adenocarcinoma in the 1st duodenal portion was offered palliative care. A 90-year-old woman with an adenocarcinoma in the 3rd duodenal portion was also offered palliative care. A unique finding in the two cases reported herein is that PDA did not cause stenosis and occlusion of the lumen. As no reports of PDA without stenosis have been published so far, these cases may add to our knowledge of PDA. The diagnosis of PDA is often delayed because its symptoms may be absent until the tumor has progressed, thus leading to a delay of several months. Patients typically present with a long history of variable and vague symptoms, and many are diagnosed with advanced disease. As regards clinical manifestations, abdominal pain is the most frequent symptom. The majority of these tumors are found to have infiltrated the duodenal wall at presentation, with many being unresectable due to local and distal invasion. Esophagogastroduodenoscopy and gastrointestinal barium radiography are the main diagnostic tests for PDA, detecting 88.6 and 83.3% of tumors, respectively. In some cases, ultrasonography or computed tomography are useful for detecting PDA and determining vascular invasion.

© 2014 S. Karger AG, Basel

Daisuke Usuda, MD, MTM  
Department of Community Medicine  
Himi Municipal Hospital, Kanazawa Medical University  
1130 Kurakawa, Himi-shi, Toyama-ken 935–8531 (Japan)  
E-Mail [united19771108@yahoo.co.jp](mailto:united19771108@yahoo.co.jp)

## Introduction

We have recently studied two cases of advanced primary duodenal adenocarcinoma (PDA). In both cases, we were unable to determine the primary location of the carcinoma by contrast-enhanced computed tomography (CT). CT images showed a large tumor (7.9 × 6.5 × 8.5 cm and 6.7 × 6.4 × 7.0 cm) of unknown origin with metastases, ascites, and lymph node invasion. Subsequent endoscopy and histologic examination revealed a poorly differentiated adenocarcinoma of the duodenum.

The aim of the present work is to offer a further contribution to the resolution of therapeutic and diagnostic problems by reporting a new case of adenocarcinoma of the 1st duodenal portion and reviewing the relevant literature.

## Case Report

### Case 1

An 85-year-old woman was admitted to our hospital with melena, hypotension, and a 2-month history of appetite loss. The underlying cause of her loss of body weight was unknown. Her medical history included an operation to correct a right inguinal hernia and hypertension, and her vital signs were within normal limits in the emergency room. A physical examination showed no abnormal findings. Routine blood tests showed leukocytosis, hypoalbuminemia, and elevation of C-reactive protein, aspartate aminotransferase and lactate dehydrogenase, along with an elevation of tumor markers, of which carcinoembryonic antigen, CA19-9, DU-PAN-2 and SPAN-1 antigen were subsequently confirmed. The presence of a tumor (7.9 × 6.5 × 8.5 cm) and irregular thickening of the wall, multiple metastases, multiple lymphadenopathy, and ascites were confirmed by CT scan (fig. 1). Endoscopy and histologic examination revealed a poorly differentiated adenocarcinoma of the duodenum (in the 1st portion), which did not contain hormone and was not differentiated into a neuroendocrine carcinoma (fig. 2). *Helicobacter pylori* infection was ruled out. The carcinoma was at an advanced stage with multiple lymph node and liver metastases. After having given informed consent, she and her family were offered palliative care.

### Case 2

A 90-year-old woman was admitted to our hospital with transient loss of consciousness and a 1-year history of palpitation associated with light effort. The cause of her loss of body weight was unknown. Her medical history was nonexistent as she did not like to attend hospitals. Her vital signs were within normal limits in the emergency room. On physical examination, she presented conjunctival pallor. Routine blood investigations showed leukocytosis, anemia, hypoalbuminemia, and elevation of C-reactive protein and tumor markers, with carcinoembryonic antigen being confirmed subsequently. A tumor (6.7 × 6.4 × 7.0 cm), irregular thickening of the wall, decreased blood vessel density, bilateral pleural fluid, and ascites were confirmed by CT scan (fig. 3). Endoscopy and histologic examination revealed a well-differentiated adenocarcinoma of the duodenum (in the 3rd portion), which did not contain hormone and was not differentiated into a neuroendocrine carcinoma (fig. 4). *H. pylori* infection was ruled out. The carcinoma was at an advanced stage. After having given informed consent, she and her family were offered palliative care.

In these two cases, the progress of duodenal cancer did not constrict the lumen, and both patients were able to eat until end of life. Written informed consent was obtained from these patients for the publication of this case report and accompanying images. (A copy of

the written consent is available for review from the Editor-in-Chief of this journal on request. All authors have agreed to protect the privacy of their patients.)

## Discussion

As there have been no studies so far reporting PDA without stenosis and occlusion of the lumen, this may be a major addition to our understanding of PDA.

PDA is relatively rare [1–3], representing 33–45% of all small bowel tumors, which themselves represent 4–5% of all gastrointestinal tumors [2]. Moreover, it is responsible for only 1% of deaths due to gastrointestinal neoplasms [2, 4]. Approximately 30–50% of small intestinal adenocarcinomas occur in the duodenum [5]. According to a report from China, only 0.02% of all inpatients suffered from PDA [3]. Duodenal adenocarcinomas represent approximately 0.3–0.5% of all malignant gastrointestinal tumors [4, 5], with studies showing that 1–15% of tumors are located in the 1st portion, 50–75% in the 2nd portion, 14–33% in the 3rd portion, and 5–17% in the 4th portion of the duodenum [2–6].

The causative factors for this disease have not been clearly identified [4], although patients with familial adenomatous polyposis and Gardner syndrome are considered to have a higher likelihood of developing duodenal cancer [4]. Similarly, patients with duodenal polyps but no predisposing family history are also at increased risk [4].

Histologically, adenocarcinoma is the most common type, with lymphoma and leiomyosarcoma being encountered less frequently [3, 4].

Symptoms may be absent until the tumor has progressed, thus leading to a delay of several months in presentation [4]. Patients typically present with a long history of variable and vague symptoms, and many present with advanced disease [4]. The diagnosis of PDA is often delayed because its symptoms and signs are nonspecific [2, 3, 5, 6]. As a result, an average delay of 2–15 months from the onset of symptoms to the time of diagnosis of PDA is not uncommon [5]. Clinical manifestations include upper abdominal pain, nausea, vomiting, jaundice, fatigue, weakness, anemia, gastrointestinal obstruction, gastrointestinal bleeding and weight loss [6], with abdominal pain being the most common symptom (56.0%) [3].

The majority of these tumors are found to have infiltrated the duodenal wall at presentation, with many being unresectable due to local and distal invasion [4]. One reason for this is that an examination of the entire duodenum by upper gastrointestinal endoscopy is challenging; adenocarcinomas of the 3rd and 4th portions of the duodenum are frequently inaccessible using endoscopy, and most cases require multiple investigations [5]. However, new modalities such as double-balloon enteroscopy or capsule endoscopy can make the diagnosis of small bowel or duodenal adenocarcinoma easier [5].

Esophagogastroduodenoscopy and gastrointestinal barium radiography are key diagnostic tests for PDA, detecting 88.6 and 83.3% of tumors, respectively [3]. As such, they are effective in screening this rare tumor [3]. However, their location is often inaccessible to endoscopic viewing, which may result in a failure to diagnose them endoscopically [2, 4]. Consequently, endoscopy with extra-long fiber optic scopes may be of benefit [4]. In some cases, ultrasonography (US) or CT findings have prompted repeat endoscopy with deeper than usual advancement into the 3rd and 4th duodenal portion, which allowed diagnosis in our patient [4]. US is particularly useful for detecting duodenal carcinoma and determining vascular invasion. Lesions appear as irregularly marginated hypoechoic masses, although tumors smaller than 2 cm may not be detected [4]. Thus, US can contribute significantly to the choice of the endoscopic procedure and patient management [7]. Contrast-enhanced CT is also useful for the diagnosis and the determination of malignancy and resectability, with a

sensitivity of 94% and a specificity of 82%, although, again, tumors smaller than 2 cm may not be detected [2, 4]. Features indicative of malignancy are an exophytic or intramural mass, central necrosis, and ulceration, whereas an entirely intraluminal location indicates a benign tumor [4]. However, these features are sensitive but nonspecific [4]. Vascular encasement, invasion of contiguous organs other than the head of the pancreas, distal lymphadenopathy, or metastasis precludes curative resection [4]. Although not commonly used to date, endoscopic US and magnetic resonance imaging are useful for the diagnosis, staging, and determination of resectability of these tumors [4]. The preoperative correct diagnosis rate by bronchoscopic ultrasound is 41.7 and 69.4% by CT, 75.0% by magnetic resonance imaging, 84.0% by duodenal endoscopy, and 80.9% by air barium double radiography [6]. Furthermore, patients may have at least one negative gastrointestinal contrast study before a positive result is obtained in a subsequent study [4].

Although early-stage duodenal carcinoma should be considered for endoscopic mucosal resection [5], mucosal duodenal cancer is extremely rare, and endoscopic submucosal dissection of a lesion in the duodenum requires a high level of skill [8]. In contrast, endoscopic polypectomy using information from endoscopic US would appear to be a safe and effective method for the diagnosis and treatment of pedunculated early duodenal cancers [9]. Surgical treatment is then indicated for more advanced disease [5].

The treatment of choice is radical surgical resection [4, 5], although the optimal surgical procedure remains controversial [4]. Advanced stages of PDA require surgical resection for a cure [5]. Worldwide, there is no general agreement as regards the optimal surgical procedure for the treatment of primary nonampullary adenocarcinoma of the duodenum, especially for early-stage disease [4]. Thus, some authors prefer local excision or segmental resection whereas others perform duodenopancreatic resection, even in the case of early-stage duodenal cancer, in order to avoid tumor recurrence, with pancreaticoduodenectomy being considered the procedure that best satisfies the principles of an adequate curative cancer operation [4]. Amongst the surgical procedures available, pancreaticoduodenectomy is recommended for tumors located in the 1st and 2nd portion of the duodenum, and segmental resection may be appropriate for selected patients, especially for tumors of the distal duodenum [10]. In contrast, duodenocephalopancreatectomy remains the standard treatment for adenocarcinomas of the 1st and 2nd portion of the duodenum [5]. Patients with locally advanced (N1) tumors (stage III) can benefit from this aggressive approach with good long-term results [5]. Some studies have reported good survival results following segmental duodenectomy, despite limited lymphadenectomy occurring during the surgical procedure, and considerably lower postoperative morbidity [5]. Segmental duodenectomy is the preferred resection method for patients with adenocarcinoma of the 3rd and 4th portions of the duodenum [5].

In advanced disease, and particularly in duodenal obstruction, palliative resection, gastrojejunal bypass or duodenal stents may be indicated [4]. The role of adjuvant chemotherapy is still unclear [2], with some studies showing important statistical benefits as regards medium- and long-term survival [2]. In light of this evidence, the treatment provided for our patient seems to be appropriate [2].

Some studies have reported that metastases to lymph nodes, positive resection margins, pancreas invasion, duodenum invasion, and tumor size are prognostic predictors for survival in patients with duodenal adenocarcinoma who underwent surgery [4–6, 11]. In contrast, other studies have reported that tumor size, tumor location within the duodenum, depth of partial penetration, local nodal metastases, tumor differentiation, and invasion of the pancreas were not predictive of prognosis [5]. The location of the duodenal neoplasia seems to be another factor affecting survival [2], with tumors of the proximal duodenum appearing

to have a worse long-term prognosis since such tumors promote retroperitoneal neofor- mation [2]. In the absence of lymph node involvement, tumors with a proximal location have a survival rate of between 0 and 25% 5 years after surgery, whereas this rate is 62% for distal locations [2]. The worst prognosis for neoplasms in the 1st duodenal portion seems to be due to the close topographic relationship with the surrounding organs, which may be affected rapidly [2]. The same does not occur, however, for neoplasms in the 3rd and 4th duodenal portion, which have an independent embryological development from the surrounding organs [2].

In light of the above, an aggressive surgical approach that achieves complete tumor resection with negative margins should be pursued [3, 11]. As regards surgery types, pancreaticoduodenectomy is usually required for cancers of the 1st and 2nd portion of the duodenum [11], whereas segmental resection may be appropriate for selected patients, especially for tumors of the distal duodenum [11].

The overall 1-, 3- and 5-year survival rates in two studies were 62.6–78.1, 43.7–43.8 and 18.8–33.1%, respectively [3, 10], with resected and nonresected patients with PDA having 5-year survival rates of 25–75 and 0%, respectively [3, 5, 6, 10]. Similarly, 5-year survival rates for T4 stage and non-T4 stage patients with PDA were 20 and 40%, respectively [3, 5, 6, 10], and a 5-year survival rate of 100 and 52% for stage I and II, respectively, and of 45 and 0% for stage III and IV, respectively, has been reported [5]. Life expectancy after resection of the 1st and 2nd portions of the duodenum is reported to be shorter than that after resection of the 3rd and 4th portions [5]. The median survival times after resection of the 1st and 2nd portions of the duodenum and after resection of the 3rd and 4th portions were 30 and 46 months, respectively [5]. The 5-year survival rate for the resection of the 3rd and 4th portions of the duodenum was 58%, whereas that for the resection of the 1st and 2nd portions was 32% [5].

In conclusion, having examined our cases and the literature data, and taking into account the rarity of adenocarcinoma of the duodenum, an early diagnosis of this neoplasm is crucial. A higher degree of suspicion and a more aggressive and persistent investigation should lead to earlier treatment, higher curative resectability rates, and, therefore, better long-term results. In these two cases, the patients and their families were not offered an aggressive medical treatment because of the patients' age. In general, while fit elderly patients with malignancy can receive the same therapeutic treatment as their younger counterparts, a palliative approach should be considered for frail elderly patients and for those with a short life expectancy. In these two cases, the progress of duodenal cancer did not result in constriction of the duodenal lumen, and both patients were able to eat until end of life. This is a unique finding given the absence of published studies reporting PDA without stenosis. This fact might add new knowledge to our understanding of PDA.

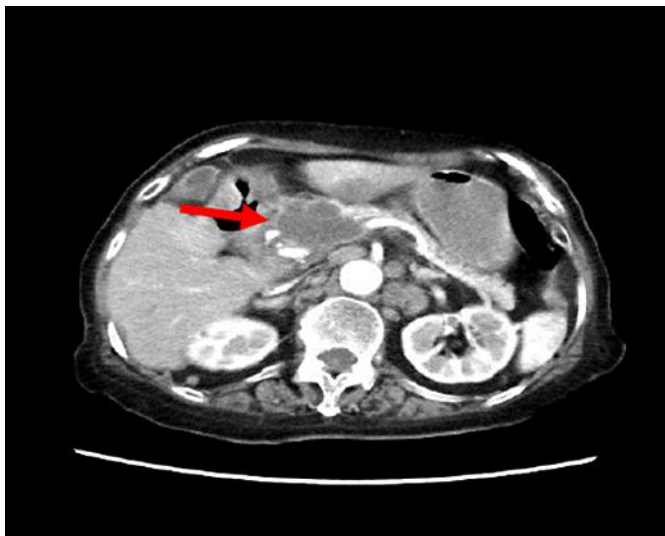### Disclosure Statement

The authors report no conflicts of interest.

### References

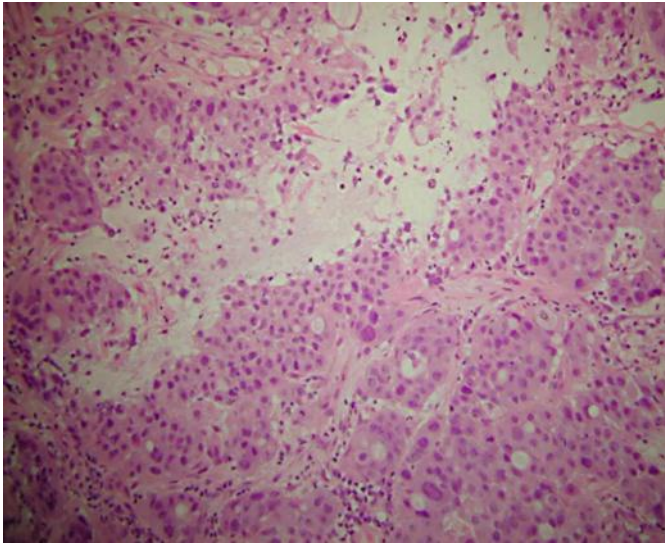
- 1 Wasike RW: Primary duodenal cancer: case report. *East Afr Med J* 2007;84:296–298.
- 2 Sista F, De Santis G, Giuliani A, Cecilia EM, Piccione F, Lancione L, Leardi S, Amicucci G: Adenocarcinoma of the third duodenal portion: case report and review of literature. *World J Gastrointest Surg* 2012;4:23–26.

- 3 Zhang S, Cui Y, Zhong B, Xiao W, Gong X, Chao K, Chen M: Clinicopathological characteristics and survival analysis of primary duodenal cancers: a 14-year experience in a tertiary centre in South China. *Int J Colorectal Dis* 2011;26:219–226.
- 4 Markogiannakis H, Theodorou D, Toutouzas KG, Gloustanou G, Katsaragakis S, Bramis I: Adenocarcinoma of the third and fourth portion of the duodenum: a case report and review of the literature. *Cases J* 2008;1:98.
- 5 Nakano T, Sugawara K, Hirau K, Hirano Y, Hashimoto M, Kaiho T, Ohuchi N: Primary adenocarcinoma of the fourth portion of the duodenum: 'a case report and literature review'. *Int J Surg Case Rep* 2013;7:619–622.
- 6 Qu H, Tian YT, Sun YM, Wang CF, Shan Y, Zhao DB, Zhao P: Surgical treatment and prognosis of primary duodenal carcinoma. *Zhonghua Zhong Liu Za Zhi* 2009;31:233–235.
- 7 Ishida H, Konno K, Sato M, Naganuma H, Komatsuda T, Yamada N, Hamashima Y, Ishida J, Segawa D, Watanabe S: Duodenal carcinoma: sonographic findings. *Abdom Imaging* 2001;26:469–473.
- 8 Shinoda M, Makino A, Wada M, Kabeshima Y, Takahashi T, Kawakubo H, Shito M, Sugiura H, Omori T: Successful endoscopic submucosal dissection for mucosal cancer of the duodenum. *Dig Endosc* 2010;22:49–52.
- 9 Yoshimoto T, Akahoshi K, Nakanishi K, Nawata H: Endoscopic removal of a pedunculated early duodenal cancer: diagnostic value of endoscopic ultrasound. *Acta Gastroenterol Belg* 2002;65:52–54.
- 10 Han SL, Cheng J, Zhou HZ, Zeng QQ, Lan SH: The surgical treatment and outcome for primary duodenal adenocarcinoma. *J Gastrointest Cancer* 2010;41:243–247.
- 11 Bakaeen FG, Murr MM, Sarr MG, Thompson GB, Farnell MB, Nagorney DM, Farley DR, van Heerden JA, Wiersema LM, Schleck CD, Donohue JH: What prognostic factors are important in duodenal adenocarcinoma? *Arch Surg* 2000;135:635–641.

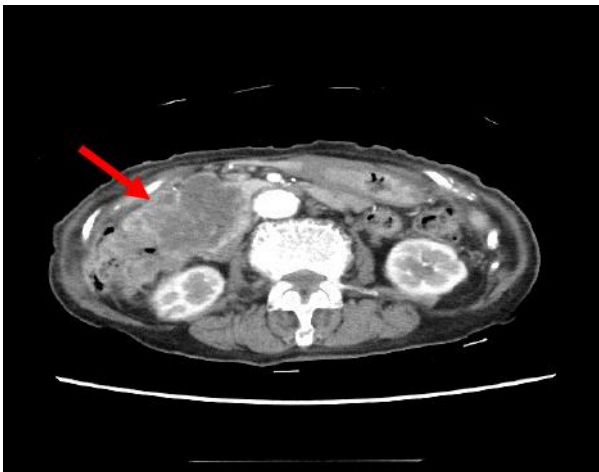


**Fig. 1.** CT with intravenous contrast of the abdomen showing a duodenal tumor, multiple liver metastases, multiple lymphadenopathy, and ascites (arrow).

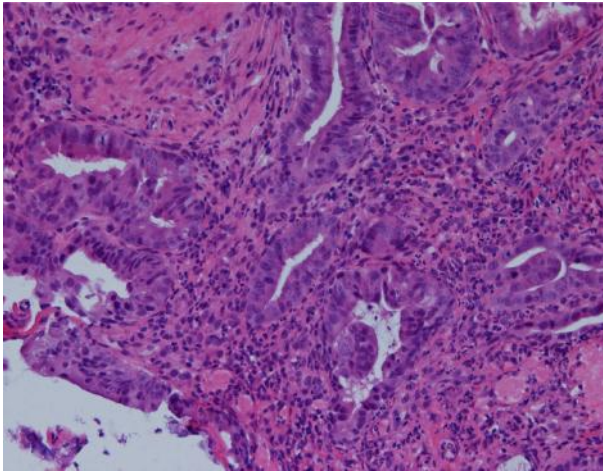




**Fig. 2.** Histopathologically verified infiltration of the duodenal muscular wall by adenocarcinoma of the duodenum. HE.  $\times 100$ .



**Fig. 3.** CT with intravenous contrast of the abdomen showing a duodenal tumor, multiple lymphadenopathy, and ascites (arrow).



**Fig. 4.** Histopathologically verified infiltration of the duodenal muscular wall by adenocarcinoma of the duodenum. HE.  $\times 100$ .