

CASE REPORT

Open Access



A case of meningococcal meningitis with multiple cerebellar microbleeds detected by susceptibility-weighted imaging

Keita Miyazaki^{1†}, Hidetada Fukushima^{1*}, Youhei Kogeichi^{2†}, Tomoo Watanabe^{3†}, Kazunobu Norimoto^{1†}, Toshiaki Taoka^{4†} and Kazuo Okuchi^{1†}

Abstract

Background: Bacterial meningitis is a fatal infectious disease of the central nervous system complicating intravascular involvements. Multiple microbleeds are rarely identified as complications because of the limited detection threshold of conventional imaging modalities. We report the first case of meningococcal meningitis with successful identification of multiple microbleeds in the cerebellum by susceptibility-weighted imaging.

Case presentation: A 19-year-old Japanese female was brought to our emergency department because of fever and coma. A spinal tap was performed and turbid yellow fluid was collected. A diagnosis of bacterial meningitis was established and the patient was admitted to an intensive care unit. Dexamethasone and Antibiotics were administered and *Neisseria meningitides* was cultured from the spinal fluid. On day 10, postcontrast magnetic resonance imaging identified enhanced subarachnoid space in the cerebellum. Susceptibility-weighted imaging showed spotty low-intensity signals in the cerebellar tissue, indicating microbleeds. The patient made a full recovery from coma and was discharged without neurological sequelae on day 24.

Conclusion: Meningococcal meningitis can cause multiple microbleeds in the cerebellum. In this report, we successfully identified microbleeds by susceptibility-weighted imaging. Using this imaging modality, further investigations will clarify its clinical incidence and significance.

Keywords: Bacterial meningitis, Magnetic resonance imaging, Susceptibility-weighted imaging, Bleeding

Background

Bacterial meningitis is a fatal infectious disease of the central nervous system with an annual incidence of 4–6 cases per 100,000 adults (patients older than 16 years of age). The most common pathogens are *Streptococcus pneumoniae*, *Neisseria meningitides*, and *Haemophilus influenzae*. Even with advanced medical care, mortality remains high between 10 and 40 % and severe neurological damage affects 30–52 % of survivors [1, 2].

Among the complications of bacterial meningitis, intracranial vascular involvement is well known, i.e., ischemic infarction, sinus thrombosis, and hemorrhagic complications [3]. According to both animal experiments and a

human autopsy study, bacterial meningitis can also cause microbleeds [4–6]. However, microbleeds are not commonly identified in clinical practice because of the limited detection threshold of head computed tomography (CT) scans and conventional magnetic resonance imaging (MRI). Therefore, microbleeds, as a complication of bacterial meningitis, are rarely recognized.

In this report, we present a case of bacterial meningitis due to *N. meningitides* with successful identification of microbleeds in the cerebellum by susceptibility-weighted imaging (SWI), a sensitive method that can be used to detect microbleeds in brain tissue.

Case presentation

A 19-year-old Japanese female without known medical history was transported to our emergency department because of coma. She complained of fever over 39 °C

* Correspondence: hidetakarina@gmail.com

†Equal contributors

¹Department of Emergency and Critical Care Medicine, Nara Medical University, Shijo-cho, 840, Kashihara City, Nara, Japan

Full list of author information is available at the end of the article

and severe occipital headache the night before her family found her unconscious. Physical examination revealed that her Glasgow coma scale was 6 (E1V1M4) with blood pressure of 128/72 mmHg, heart rate of 88 beats/min, and respiratory rate of 19 breaths/min. Both pupils were 3.5 mm with a sluggish light reflex. Neurological examination found no motor laterality or pathological reflex, except for nuchal rigidity. A head CT scan revealed no focal region, but diffuse swelling of the brain. Her blood tests showed elevated leukocytes (21,100 cells/ μ L) and C-reactive protein (20.6 mg/dL). A lumbar tap was performed and turbid yellow spinal fluid was collected. Spinal fluid examination revealed protein 394 mg/dl, glucose 0 mg/dl and a cell count of 10112/mm³ (96 % polymorphonuclear leukocytes), which confirmed the diagnosis of bacterial meningitis.

She was intubated and admitted to an intensive care unit. Due to poor study of the gram staining, meropenem and vancomycin were administered right after IV dexamethasone. On day 8, *N. meningitidis* was cultured from the spinal fluid collected on admission and antibiotic therapy was changed to ampicillin (Fig. 2). Brain MRI study was performed on day 10 (Fig. 1). Postcontrast T1-weighted imaging showed enhanced subarachnoid space of the cerebellum, typically along the great horizontal fissure (Fig. 1a and b). Additionally, Diffusion-weighted imaging (DWI) found high intensity area and SWI revealed multiple low-intensity spots in subarachnoid space along the great horizontal fissure (Fig. 1c and d). Since these spotty low-intensity areas in the cerebellum located nonlinearly and there were no enhanced spots in the axial contrasted T1-weighted imaging, we confirmed that these low-intensity signals were not telangiectasia, but microbleeds. Antibiotic management was successful and her clinical symptoms improved. She was discharged on day 24 without neurological deficits. A follow-up brain MRI was performed on day 42. SWI showed the regions of multiple low-intensity spots in cerebellum persisted, but were disappearing (Fig. 1e). She had no neurological deficits and complained no symptoms on day 42.

We reported a case of meningitis due to *N. meningitidis* in which the patient's SWI findings indicated diffuse microbleeds in the cerebellum. Despite an extensive literature search, we could not find a report of bacterial meningitis with microbleeds in the cerebellum or cerebral cortex identified by SWI.

The most common MRI findings in bacterial meningitis are intraventricular signal alterations, meningeal enhancement, and intraparenchymatous signal changes [7]. In this case, postcontrast T1-weighted imaging revealed enhancement in subarachnoid space of cerebellum, which is consistent with general MRI findings of bacterial meningitis. Interestingly, DWI showed high intensity areas and SWI revealed multiple low-intensity spots

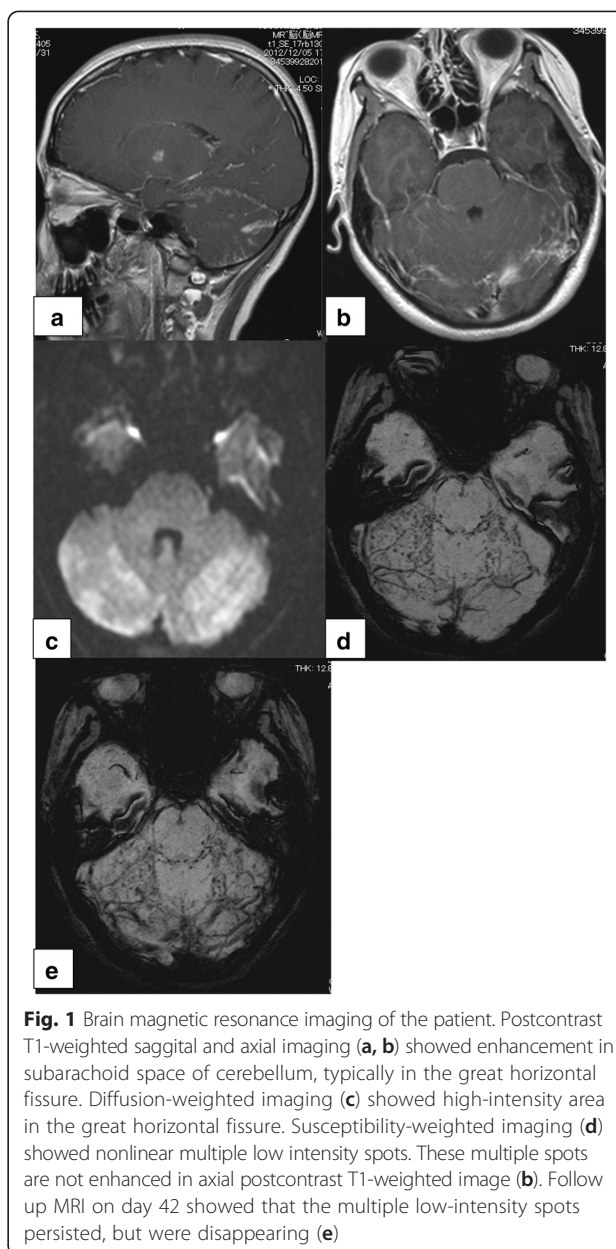


Fig. 1 Brain magnetic resonance imaging of the patient. Postcontrast T1-weighted sagittal and axial imaging (a, b) showed enhancement in subarachnoid space of cerebellum, typically in the great horizontal fissure. Diffusion-weighted imaging (c) showed high-intensity area in the great horizontal fissure. Susceptibility-weighted imaging (d) showed nonlinear multiple low intensity spots. These multiple spots are not enhanced in axial postcontrast T1-weighted image (b). Follow up MRI on day 42 showed that the multiple low-intensity spots persisted, but were disappearing (e)

located with veins in subarachnoid space along the great horizontal fissure. On SWI, deoxyhemoglobin, hemorrhagic blood products, and methemoglobin of hemorrhagic lesions can be visualized as low-intensity signals [8]. With the findings of DWI and SWI, we speculated that a collection of purulent exudate in subarachnoid space caused microbleeds on the surface of cerebellum. Animal experiments and a recent autopsy study of bacterial meningitis reported that both macroscopic and microscopic hemorrhages can be observed [4, 6]. In a pneumococcal meningitis mouse model, microscopic hemorrhages can be found in both the subarachnoid space and cortex [4]. An autopsy study of pneumococcal meningitis by Vergouwen et al. [6] also reported that the

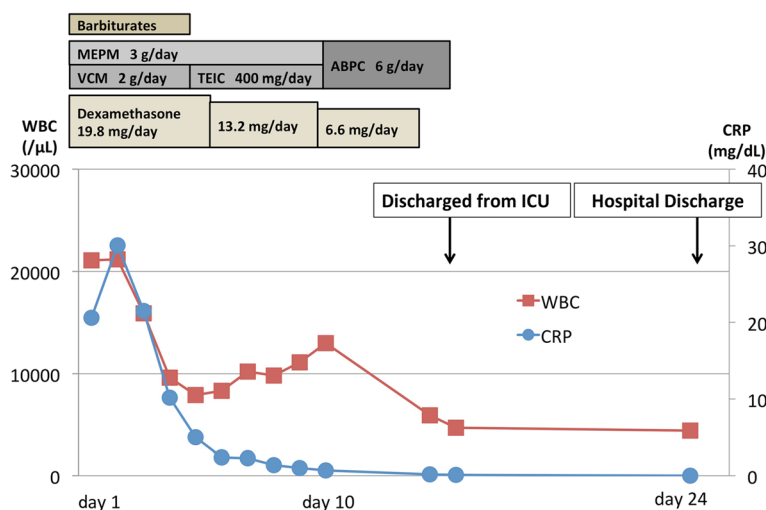


Fig. 2 Clinical course of the case. The patient was managed successfully with antibiotics and dexamethasone and discharged on day 24. MEPM, meropenem; VCM, vancomycin; TEIC, teicoplanin; WBC, white blood cell; ICU, intensive care unit; ABPC, ampicillin

majority of microbleeds were located in the cortex and subcortex with no evidence of infarction. The mechanism of microbleeds is considered as pyogenic vasculitis following vascular wall injury or extravasation of red blood cells from congested small veins caused by severe inflammation [6]. Microbleeds in meningococcal meningitis, however, has not been observed in human studies.

Other pathophysiology which can cause microbleeds detected by SWI are hypertensive vasculopathy or amyloid angiopathy [9]. This patient, however, had no history indicating these pathophysiologies.

The clinical significance of microbleeds in bacterial meningitis, however, is not well documented. In this current case report, the cerebellar microbleeds did not seem to cause any neurological deterioration. Further studies are needed to investigate the pathogenesis of microbleeds and their clinical significance.

Conclusions

Meningococcal meningitis can cause multiple microbleeds in the cerebellum. In this report, we successfully identified microbleeds by susceptibility-weighted imaging. Using this imaging modality, further investigations will clarify its clinical incidence and significance.

Consent

Written informed consent was obtained from the patient for publication of this case report and any accompanying images. A copy of the written consent is available for review by the Editor of this journal.

Abbreviations

CT: Computed tomography; MRI: Magnetic resonance imaging; DWI: Diffusion-weighted imaging; SWI: Susceptibility-weighted imaging.

Competing interests

The authors have no competing interests to declare.

Authors' contributions

KM – conception, design, and manuscript preparation. HF – manuscript preparation and English translation. YK, TW, and KN – contributed to manuscript preparation. TT – contributed to radiological assessment. KO – substantial contribution to the concept of the manuscript and final correction of the manuscript. All authors have approved the final version of the manuscript.

Authors' information

All authors are medical doctors. TT is currently at Department of radiology, Nagoya University Graduate school of Medicine, Nagoya, Japan.

Acknowledgements

This report received no funding.

Author details

¹Department of Emergency and Critical Care Medicine, Nara Medical University, Shijo-cho, 840, Kashihara City, Nara, Japan. ²Department of Neurosurgery, Nara Medical University, Shijo-cho, 840, Kashihara City, Nara, Japan. ³Department of Neurosurgery, Nara Prefecture General Medical Center, Hiramatsu, 1-30-1, Nara City, Nara, Japan. ⁴Department of Radiology, Nara Medical University, Shijo-cho, 840, Kashihara City, Nara, Japan.

Received: 19 March 2015 Accepted: 9 October 2015

Published online: 22 October 2015

References

1. Sigurdardottir B, Bjornsson OM, Jonsdottir KE, Erlendsdottir H, Gudmundsson S. Acute bacterial meningitis in adults. A 20-year overview. *Arch Intern Med.* 1997;157(4):425–30.
2. Hussein AS, Shafraan SD. Acute bacterial meningitis in adults. A 12-year review. *Medicine (Baltimore).* 2000;79(6):360–8.
3. Bodilsen J, Dalager-Pedersen M, Schonheyder HC, Nielsen H. Stroke in community-acquired bacterial meningitis: a Danish population-based study. *Int J Infect Dis.* 2014;20:18–22.

4. Mook-Kanamori B, Geldhoff M, Troost D, van der Poll T, van de Beek D. Characterization of a pneumococcal meningitis mouse model. *BMC Infect Dis.* 2012;12:71.
5. Woehrl B, Brouwer MC, Murr C, Heckenberg SG, Baas F, Pfister HW, et al. Complement component 5 contributes to poor disease outcome in humans and mice with pneumococcal meningitis. *J Clin Invest.* 2011;121(10):3943–53.
6. Vergouwen MD, Schut ES, Troost D, van de Beek D. Diffuse cerebral intravascular coagulation and cerebral infarction in pneumococcal meningitis. *Neurocrit Care.* 2010;13(2):217–27.
7. Lummel N, Koch M, Klein M, Pfister HW, Bruckmann H, Linn J. Spectrum and prevalence of pathological intracranial magnetic resonance imaging findings in acute bacterial meningitis. *Clin Neuroradiol.* 2014. doi:10.1007/s00062-014-0339-x.
8. Haacke EM, Xu Y, Cheng YC, Reichenbach JR. Susceptibility weighted imaging (SWI). *Magn Reson Med.* 2004;52(3):612–8.
9. Yates PA, Villemagne VL, Ellis KA, Desmond PM, Masters CL, Rowe CC. Cerebral microbleeds: a review of clinical, genetic, and neuroimaging associations. *Front Neurol.* 2014;4:205.

**Submit your next manuscript to BioMed Central
and take full advantage of:**

- Convenient online submission
- Thorough peer review
- No space constraints or color figure charges
- Immediate publication on acceptance
- Inclusion in PubMed, CAS, Scopus and Google Scholar
- Research which is freely available for redistribution

Submit your manuscript at
www.biomedcentral.com/submit

