

Impact of primary posterior capsulorhexis on regenerative after-cataract and YAG laser rates with an acrylic micro-incision intraocular lens with plate haptics: 1-year and 3-year results

Rupert Menapace,  Sabine Schriebl, Christoph Lwowski and Christina Leydolt 

Department of Ophthalmology, Medical University of Vienna, Vienna, Austria

ABSTRACT.

Purpose: To evaluate the posterior capsule opacification (PCO) and YAG laser capsulotomy (YAG-LCT) rates with a plate-haptic acrylic micro-incision intraocular lens (IOL) and the impact of primary posterior capsulorhexis.

Methods: A total of 97 patients scheduled for immediate sequential bilateral cataract surgery underwent a randomized, prospective intraindividual comparison with the ZEISS Asphina 409MV plate-haptic acrylic IOL with the eyes receiving an additional primary posterior capsulorhexis (PPCR) or not. YAG-LCT and PCO rates were evaluated at 1 and 3 years. Three-year PCO rates were calculated with a 3-scenario method for eyes that underwent YAG-LCT between 1 and 3 years.

Results: A total of 56 patients were seen at 1 year, and 57 at 3 years. For the eyes without and with PPCR, YAG-LCT rates were 14.3% and 0% at 1 year, and 59.7% and 3.5% at 3 years, respectively. Opacification rates at 1 year were 0.55 ± 0.99 and 0.05 ± 0.21 for the central 2-mm optic zone. A total of 42 patients completed both the 1- and 3-year follow-up. Three-year opacification rates for the group without PPCR were 1.99 ± 2.20 , 2.26 ± 2.66 and 3.66 ± 3.61 for the central 2-mm zone and 2.57 ± 2.07 , 3.13 ± 3.03 and 4.09 ± 3.34 for the 4.5-mm zone for the best, extrapolated and worst-case scenarios, respectively.

Conclusion: The ZEISS Asphina 409MV plate-haptic acrylic IOL exhibited unusually high YAG-LCT and PCO rates with standard in-the-bag implantation. PPCR was safe and effective in preventing central opacification and the need for YAG laser treatment.

Key words: posterior capsule opacification – primary posterior capsulorhexis – YAG laser capsulotomy – ZEISS CT Asphina 409MV plate-haptic acrylic micro-incision intraocular lens

Acta Ophthalmol. 2019; 97: e1130–e1135

© 2019 The Authors. Acta Ophthalmologica published by John Wiley & Sons Ltd on behalf of Acta Ophthalmologica Scandinavica Foundation.

This is an open access article under the terms of the Creative Commons Attribution-NonCommercial License, which permits use, distribution and reproduction in any medium, provided the original work is properly cited and is not used for commercial purposes.

doi: 10.1111/aos.14156

Introduction

Central posterior capsule opacification (PCO) caused by migration, proliferation

and differentiation of lens epithelial cells (LECs) that require Nd:YAG laser capsulotomy (YAG-LCT) is still

a significant clinical issue in spite of improvements in the design and material properties of modern intraocular lenses (IOLs) (Menapace 2004, 2014). Though the importance of a slim optic-haptic junction has been recognized as a key parameter, single-piece IOLs with open-loop and closed-loop or flange haptics have widely replaced IOLs with thin loop haptics. Broad haptics interfere with circumferential bend formation of the posterior capsule along the posterior optic edge and thus open a gateway for retrolental LEC ingrowth. Implementation of a stepped or ‘enhanced’ edge beneath such a broad junction may be an inadequate substitute since capsular fusion as the prerequisite for capsular bending is expected to be still impaired. A stepped edge beneath broad flanged haptics, even when exquisitely sharp is therefore expected to only delay, but not permanently prevent LEC ingrowth into the posterior optic-capsule interspace.

One such IOL type with plate haptics widely used in Europe is the ZEISS CT Asphina 409MV IOL model, formerly named Acri.Smart 46YLC. This IOL comes with an easy-to-use pre-loaded system for implantation through sub-2-mm micro-incisions and is promoted as to offer excellent long-term rotational stability and centration. Posterior capsule opacification (PCO) and YAG-LCT rates after standard in-the-bag implantation have not been published in the peer-reviewed literature for this particular type of plate-haptic IOL, nor the potentially

preventive impact of a primary posterior capsulorhexis (PPCR). We therefore conducted a prospective randomized clinical trial in order to objectively evaluate the PCO and YAG-LCT rates and to assess the impact of adding a primary posterior capsulorhexis (PPCR) before IOL implantation on reducing opacification and YAG laser treatment rates.

Materials and Methods

The CT Asphina 409MV, formerly termed Acri.Smart 46YLC, is a hydrophilic acrylic IOL with a 6-mm optic and flanged, non-angulated plate haptic with an overall length of 11 mm. It is made of a hydrophilic acrylic with 25% water content. The edges are proven exquisitely sharp (Werner et al. 2009). Beneath the flanges, the sharp posterior optic edge continues as a stepped ('enhanced') edge (Fig. 1). The surface of the IOL is made hydrophobic by a proprietary method. These features shall reduce PCO and YAG-LCT rates. The CT Asphina 409MV comes with a single-use 2-component semi-preloaded push injector system (Bluemix[®]) for single-step implantation through micro-incisions as small as 1.8 mm.

For optimal comparability, immediate sequential bilateral cataract surgery was performed with one eye assigned to standard cataract surgery, while the partner eye had additional PPCR. All eyes were operated by the same surgeon (R.M).

Topical anaesthesia was applied. A 1.8 mm, internally funnelled posterior-limbal micro-incision was formed temporarily with a bevel-up steel blade and the aqueous exchanged for 2% methylcellulose (Medioclear[®]). Two clear corneal stab incisions were created infero- and supero-temporally, and a 5-mm capsulorhexis centred on the visual axis was created with a bent needle. Thorough hydrodissection and rotation of the cataractous lens within the bag was followed by infusion-assisted coaxial high-fluidics micro-phacoemulsification (Menapace & Di Nardo 2010) using a vertical chop technique. The residual cortex material was aspirated with biaxial infusion-aspiration instrumentation. For standard in-the-bag implantation, the bag was expanded with a cohesive ophthalmic viscoelastic device (OVD) (Healon[®]) and the IOL injected by docking the injector tip to the non-widened cataract incision. In the contralateral eye, a PPCR was performed as previously described in detail (Menapace 2006, 2008) (Video Clip S1): 2% hyaluronic acid was injected to flatten out the posterior capsule and bring down the anterior capsule leaf to collapse the capsular fornix. A bent 27-gauge needle was introduced through a side port and the central posterior capsule incised in a flat angle. 2% hyaluronic acid is used to ensure separation of the central anterior hyaloid from the posterior capsule. The edge of the incised posterior capsule was grasped by Utrata Style Capsulorhexis Forceps, and the capsule

torn towards the periphery and then circular with the edge following the anterior capsulorhexis edge in 0.5 mm distance, followed by viscoseparation of the peripheral anterior hyaloid surface from the residual posterior capsule ring. When completed, the collapsed nasal and temporal portions of the capsular fornix were reformed and the chamber deepened using 2% hyaluronic acid. During IOL injection, the leading flange was inserted into the patent nasal fornix first, and the trailing haptic then manoeuvred into the temporal fornix by pushing down on the haptic-optic junction with a spatula while the trailing haptic exited the cartridge.

As a postoperative routine, patients were instructed to present in case of headache or eye pain the day of surgery and were seen for an intraocular pressure (IOP) measurement 1 day and a visual acuity assessment 1 month after surgery to rule out cystoid macular oedema (CME).

The study was performed at the Department of Ophthalmology at the Vienna General Hospital (Medical University of Vienna, Austria). The patients were recruited in a continuous cohort. Inclusion criteria were bilateral age-related cataract, eligibility and willingness to undergo immediate sequential bilateral cataract surgery, and good overall physical constitution. Exclusion criteria were a history of ocular disease (PEX, uveitis, glaucoma) or intraocular surgery, laser treatment, diabetes requiring medical control, glaucoma and severe retinal pathology that would make a postoperative visual acuity of 20/40 (decimal equivalent = 0.5) or better unlikely. The study was approved by the Ethics Committee of the Medical University of Vienna, Austria. All the research and measurements followed the tenets of the Helsinki agreement, and informed consent was obtained from all subjects in this study.

A total of 97 patients were enrolled in the study, 62 female and 35 male. Patients were called in after 1 year and after 3 years. Patients were instructed to present in the hospital should vision deteriorate before the scheduled follow-ups.

YAG laser treatment was performed only if the patient subjectively complained for halo or glare or visual loss and if best corrected high-contrast visual acuity had decreased to 0.8 or less due to central PCO formation.

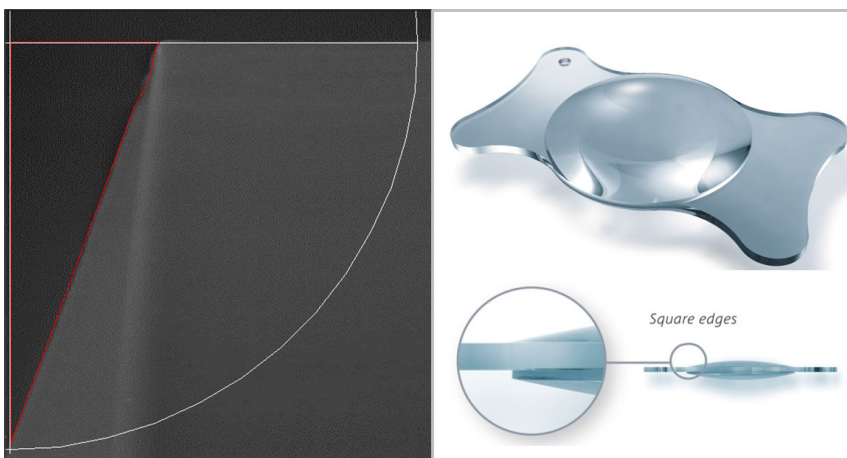


Fig. 1. Design of the ZEISS CT Asphina 409M IOL Model. On the left: AutoCAD analysis of posterior optic edge sharpness of a $\times 25$ magnification scanning electron microscopy (SEM) photograph of a 20 dioptre IOL. The white line represents a $40\text{-}\mu\text{m}$ radius circle. The area within the red lines corresponds to the deviation from the ideal square (Courtesy by Liliana Werner).

The following parameters were retrieved during all show-ups: refraction, corrected visual acuity, IOP; biomicroscopy of the anterior segment including scrutiny of the anterior vitreous surface and retroillumination photography focused on the posterior capsule or the posterior optic surface were performed in full mydriasis. Images were assessed objectively using the pixel-entropy-based AQUA (Automated Quantification of After-Cataract) software, with 0 indicating a clear capsule and 10 a very dense capsule opacification by regenerative after-cataract. The fully automated AQUA system has been previously shown to highly correlate with subjective grading as well as the subjective EPCO system (Findl et al. 2003). In addition to the area within the anterior capsulorhexis edge, the optic areas of 4.5, 3.5 and 2 mm were evaluated separately.

Anterior capsule fibrosis was graded as previously described (Sacu et al. 2002). Also, haptic deformation and optic decentration were considered.

Statistical workup was performed using paired t-tests for the PCO scores and the McNemar test for the YAG rates.

Results

No capsular, vitreous or other complication occurred during the surgery. No early postoperative IOP peaking occurred, and no cases of cystoid macular oedema or other retinal complications were observed or reported.

For the follow-up examinations, all patients were contacted by postal mail if not reached by telephone. A total of 56 (57.7%) patients showed up for the 1-year follow-up examination and 57 (58.8%) for the 3-year examination, with 42 (43.3%) patients attending both examinations. Of the 57 patients examined at 3 years, 40 were female and 17 male. Mean age was 72 and 69 years, respectively. Mean follow-up was 37 months, minimum 31 months, and maximum 43 months. Of the patients not showing up after 3 years, 3 patients had died and 10 had become immobile. Of the remaining 27 patients, 20 could not be reached and 7 did not want to comply.

For the sake of simplicity, the conventional terms 'PCO' and 'YAG-LCT' will be used also for retrolental opacification and YAG laser treatment

in the PPCR group in spite of the fact that the posterior capsule had been removed.

YAG rates

Of the 56 patients showing up at 1 year, 8 (14.3%) of the standard and no patient (0%) of the PPCR eyes had already undergone or required YAG-LCT as indicated by the above-mentioned guidelines ($p < 0.001$).

Of the 57 patients presenting at 3 years, 14 (24.6%) of the standard eyes already had, whereas 20 (35.1%) needed YAG-LCT by this time giving a total of 34 (59.7%) eyes with YAG-LCT 3 years after surgery ($p < 0.001$); 2 (3.5%) of the PPCR eyes needed YAG-LCT at the 3 years control ($p < 0.001$). Of the 42 (43.4%) patients attending both visits, 5 (11.9%) versus no patient (0%) had additionally undergone YAG-LCT between years 1 and 3 (Fig. 2).

In the eyes with PPCR, central opacification by LEC outgrowth from the capsulorhexis edge occurred in only 2 cases (3.5%). In these 2 cases, the posterior capsule opening was easily cleared by ablating the LECs using minimal YAG laser energies of 0.6–0.8 Milli-Joules only.

PCO rates

At 1 year, PCO grades within the capsulorhexis area were 1.13 ± 1.14 in the standard and 0.81 ± 0.95 in the PPCR eyes ($p = 0.04$). Posterior capsule opacification (PCO) grades for the

visually relevant central 2 mm area were 0.55 ± 0.99 and 0.04 ± 0.21 ($p < 0.001$), that for the 4.5 mm area 1.07 ± 1.25 and 0.61 ± 0.76 ($p = 0.006$), respectively. At 3 years, PCO grades within the capsulorhexis area were 3.05 ± 2.29 in the standard and 2.48 ± 2.13 in the PPCR eyes ($p = 0.1$). Posterior capsule opacification (PCO) grades for the 4.5 mm area were 2.76 ± 2.05 and 1.78 ± 1.90 ($p = 0.004$), and those for the clinically relevant 2 mm area 2.22 ± 2.16 and 0.30 ± 1.15 ($p < 0.001$), respectively (Figs. 2, 3). Figure 3 shows retroillumination photographs of 3 eye pairs with different severities of PCO formation after in-the-bag IOL implantation and the efficacy of PPCR in preventing LEC ingrowth in the contralateral eye. Of the eyes with additional PPCR, 2 (3.5%) exhibited peripheral LEC ingrowth and another 2 (3.5%) near-central overgrowth of the posterior capsule opening. Figure 4 shows 4 examples of eyes with peripheral to near-central overgrowth.

Disregarding those eyes that already have undergone YAG laser treatment leads to a false-positive bias of PCO rates by selection which falsely improves PCO results as the number of dropouts increases. Therefore, a special algorithm was used which calculates 3 possible future scenarios for those cases that have undergone YAG-LCT (Buehl et al. 2008): no further increase (best case scenario), linear increase (extrapolated scenario) and increase of PCO score to 10 (worst-case scenario). When separately

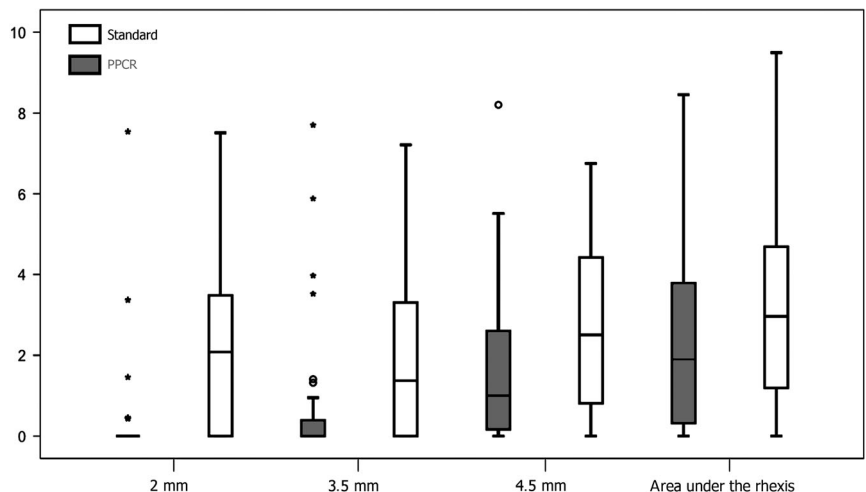


Fig. 2. PCO rates at 1 and 3 years for different eccentricities.




Fig. 3. Three eye pairs representing different severities of PCO formation in the standard eye and the efficacy of PPCR in preventing LEC ingrowth.

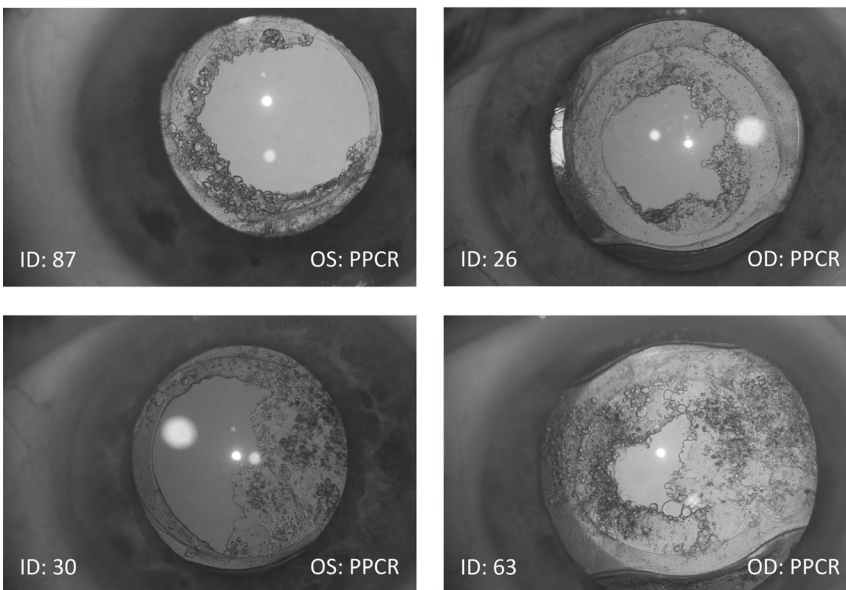


Fig. 4. Four examples of eyes with peripheral to near-central overgrowth.

1.99 ± 2.20 and 2.26 ± 2.66 and 3.66 ± 3.61 for the visually relevant central 2-mm zone, respectively.

Fibrosis and decentration: Some amount of anterior capsule fibrosis was present in almost all (53 of 57 or 93% of the) cases. Severity was homogeneously distributed between grades 1 and 3 and comparable in both groups. No case of excessive capsular contraction and no case of consecutive haptic deformation were observed. One IOL optic decentration caused by IOL optic edge capture by the capsulorhexis rim was observed in each group.

Discussion

Silicone plate-haptic IOLs manufactured by STAAR in Monrovia, CA, USA, have been very popular in the 1990s because of the ease of folded implantation through small incisions using push injectors. Though clinical results were good, this lens type was largely abandoned mostly because of the general shift towards acrylics as the preferred IOL material. Later on, the Acri.Tec Company, based in Munich, Germany, manufactured an IOL with a similar design made of a hydrophilic acrylic with a modified hydrophobic surface.

This IOL became popular in a number of European countries especially when ZEISS in Jena, Germany, acquired the IOL portfolio from Acri-Tec and implemented toric and multifocal optics into the platform. Growing popularity of sub-2-mm micro-incision cataract surgery further boosted the use of this IOL injectable through incisions as small as 1.6 mm.

To allow compression and avoid tearing while passing a super small injector tip, MICS IOLs are made from hydrophilic material and feature a compact design with broad-based closed-loop or flange haptics. Due to the material and the manufacturing process, edges cannot be made as sharp as with hydrophobic acrylic or silicone IOLs (Nanavaty et al. 2019), and broad-based haptics interfere with posterior capsule bending and barrier formation against LEC migration. Consequently, PCO and YAG-LCT rates have generally been high with all MICS IOLs.

For the ZEISS Asphina 409M plate-haptic IOL model, PCO and YAG-LCT rates have not yet been published

calculating these three scenarios for the group with standard implantation and a YAG-LCT rate of 59.7%, estimated

PCO scores for these scenarios are 2.57 ± 2.07 and 3.13 ± 3.03 and 4.09 ± 3.34 for the 4.5-mm zone and

in the peer-reviewed literature, nor the potentially preventive impact of a PPCR. Concerns about high PCO and YAG-LCT rates because of the interrupted edge barrier along the broad optic-haptic junction and reports of occasional excessive capsulorhexis contraction (Faschinger & Eckhardt 1999) causing deformation, decentration and tilt motivated us to conduct a prospective randomized intraindividual study assessing the IOL performance when using a capsulorhexis overlap not greater than 0.75 mm and compare it with that after adding a PPCR. The removal of the central posterior capsule was expected to reduce or abolish central retrolental opacification by creating a second line of defence along the posterior capsulorhexis edge. In addition, the patients were checked for postoperative IOP spikes and CME. The hermetical sealing of the PPCR by the monobloc IOL should avoid postoperative IOP rises and peaks seen with looped IOLs by trapping the OVD left back behind the IOL (Stifter et al. 2007, 2010). In the early postoperative period, the OVD cushion trapped behind the closed diaphragm may additionally withhold inflammatory cytokines from reaching the macula and thus have a positive impact on the CME rate.

With YAG laser treatment rates of 14.3% at 1 year and cumulative treatment rates of 59.7% at 3 years, this study showed early and pronounced PCO formation with high YAG-LCT rates with this type of plate-haptic IOL implanted in an intact capsular bag. Primary posterior capsulorhexis (PPCR) was shown to be very effective in reducing especially central opacification rates, with only 3.5% of eyes requiring YAG laser treatment at 3 years.

The high PCO and YAG-LCT rates observed with standard in-the-bag implantation compare well with those of other MICs IOLs. Own studies found rates between 31% and 32% after 1-2 years, and 77% and 49% after 3 years (Schrieffl et al. 2015a, 2015b) for the single-piece hydrophilic M60 and Physiol Micro AY IOLs, respectively. These rates by far exceed the rates reported for standard hydrophobic acrylic IOLs fitting 2.2-mm incisions. In a 3-year follow-up study comparing for the Tecnis ZCB00

and Acrysof SA60AT hydrophobic acrylic one-piece IOLs, objective PCO scores were 1.3 ± 1.7 and 0.9 ± 1.3 , and YAG-CT rates 26.1% and 21.7%, respectively (Leydolt et al. 2013). This may be partly explained by the specific haptic design which interferes with capsular bending along the haptic-optic junction. With the ZEISS Asphina 409MV plate haptic IOL, the inhibitory effect of the 'stepped' or 'enhanced' sharp edge extending beneath the uninterrupted broad haptic junction is obviously not permanent and not an adequate substitute for posterior capsule bending along an exposed optic edge. The low rates of LEC ongrowth and need for laser treatment with a PPCR compare well with those previously reported for silicone and hydrophobic acrylic IOLs (Georgopoulos et al. 2001).

Even minimal retro-optical PCO reduces the optical performance of an IOL. Even thin layers of LEC ongrowth often overlooked under retroillumination may reduce contrast. Patients with a PPCR in one eye and none in the other often immediately recognize the PPCR eye even with a clear capsule in the other because of the better contrast. Multifocal IOLs (MIOLs) are specifically susceptible to even minimal PCO formation due to already reduced contrast and specifically profit from PPCR. Langenbucher et al. have demonstrated in a laboratory setting that under identical capsule conditions, stray light formation is significantly enhanced and optical performance deteriorated with a MIOL compared with a monofocal IOL (A. Langenbucher, S. Schröder, T. Eppig. Impact of posterior capsule opacification on the image quality of monofocal and multifocal IOLs. 31st Congress of the German Ophthalmic Surgeons, Nuremberg). The ZEISS and Physiol trifocal MIOLs are among the most popular MIOLs.

YAG laser treatment was uneventful in all cases. With PCO forming after standard surgery, care was taken to make the YAG-LCT circular and not wider than 4 mm. Due to the minimal or lacking fibrotic PCO component typical for hydrophilic IOLs, the posterior capsule was easy to open with a low laser power and number of shots, minimizing the risk of optic pitting. Radial tearing of the capsulotomy rim potentially leading to a posterior optic

and hyperopic refractive shift or previously reported IOL dislocation never occurred. In the rare cases of central opacification after a PPCR, even lower near-threshold laser energy was required to blow the LECs off the posterior optic surface. As opposed to standard capsulotomy, LEC ablation therefore often allowed to spare the vitreous surface.

Fibrosis was equally distributed in both groups and did not induce deformation or significant decentration or tilt. Minor decentration occurred in one case of each group when the capsulorhexis rim captured the IOL optic edge. Primary posterior capsulorhexis (PPCR) did not change the fibrotic response. With the rhexis-optic overlap limited to 0.75 mm, no case of excessive rhexis shrinking or fibrosis occurred.

Other than with open-loop IOLs (Stifter et al. 2007, 2010), no early IOP rise or peaking occurred after additional PPCR in the early postoperative period. No case of vision-reducing CME was seen at 1 month or reported. This is in accordance with an earlier study investigating the possible impact of a PPCR on macular morphology. In the 50 patients undergoing standard in-the-bag implantation of an IOL in one eye and PPCR with posterior optic buttonholing in the other eye, no case of CME was observed. Macular thickness and volume were not only statistically significantly different, but virtually identical in both groups (Stifter et al. 2008). This proves the safety of planned anterior-hyaloid-sparing surgical removal of the central posterior capsule.

One potential weakness of the study is the percentage of patients lost to follow-up and lasered elsewhere. Patients included in PCO studies are inherently elderly patients. After a 3-year follow-up, the condition of these patients has often changed. Patients may have become immobile, moved to a retirement home or changed address and unable to be contacted, or understandably unwilling to take the effort of travelling to the hospital for an academically motivated thorough re-examination or a laser treatment that can be performed by their local ophthalmologist when PCO is diagnosed. This should not result in a selection bias. A closely 60% 3-year follow-up rate favourably compares with other PCO studies published in the peer-reviewed

literature and is a representative follow-up percentage considering the highly different PCO and YAG rates found in the 2 groups. A particular strength of the study is its intraindividual comparison design.

Conclusion

The ZEISS semi-preloaded MICS system makes loading and injecting of the ZEISS Asphina 409MV IOL through micro-incisions easy and safe. Due to its plate haptic design, however, the IOL exhibited excessively high PCO and YAG-LCT rates with standard in-the-bag implantation. Surface modification obviously did not prohibit PCO formation. When combining surgery with PPCR, however, retro-optical opacification and YAG laser treatment rates dropped dramatically to rates even lower than those reported for the best hydrophobic IOLs with narrow-based haptics.

The monobloc design hermetically sealed off the PPCR opening, precluding retrolental OVD dissipating into the anterior and potentially withholding cytokines from dissipating into the posterior segment.

Therefore, adding a PPCR should always be considered when using the ZEISS Asphina 409MV and similar design IOLs, specifically when featuring multifocal optics.

References

- Buehl W, Heinzl H, Mittlboeck M & Findl O (2008): Statistical problems caused by missing data resulting from neodymium: YAG laser capsulotomies in long-term posterior capsule opacification studies: problem identification and possible solutions. *J Cataract Refract Surg* **34**: 268–273.
- Faschinger CW & Eckhardt M (1999): Complete capsulorhexis opening occlusion despite capsular tension ring implantation. *J Cataract Refract Surg* **25**: 1013–1015.
- Findl O, Buehl W, Menapace R, Georgopoulos M, Rainer G, Siegl H, Kaider A & Pinz A (2003): Comparison of 4 methods for quantifying posterior capsule opacification. *J Cataract Refract Surg* **29**: 106–111.
- Georgopoulos M, Menapace R, Findl O, Rainer G, Petternel V & Kiss B (2001): Posterior continuous curvilinear capsulorhexis with hydrogel and silicone intraocular lens implantation: development of capsulorhexis size and capsule opacification. *J Cataract Refract Surg* **27**: 825–832.
- Leydolt C, Kriechbaum K, Schriefl S, Pachala M & Menapace R (2013): Posterior capsule opacification and neodymium:YAG rates with 2 single-piece hydrophobic acrylic intraocular lenses: three-year results. *J Cataract Refract Surg* **39**: 1886–1892.
- Menapace R (2004): Prevention of posterior capsule opacification. In: Koch DD & Kohlen T (ed.) *Essentials in Ophthalmology*. Berlin-Heidelberg: Springer 101–122.
- Menapace R (2006): Routine posterior optic buttonholing for eradication of posterior capsule opacification in adults: report of 500 consecutive cases. *J Cataract Refract Surg* **32**: 929–943. Erratum in: *J Cataract Refract Surg* **32**: 1410.
- Menapace R (2008): Posterior capsulorhexis combined with optic buttonholing: an alternative to standard in-the-bag implantation of sharp-edged intraocular lenses? A critical analysis of 1000 consecutive cases *Graefes Arch Clin Exp Ophthalmol* **246**: 787–801.
- Menapace R (2014): Effect of anterior capsule polishing on capsule opacification and YAG laser capsulotomy. In: Saika S, Werner L & Lovicu FJ (eds) *Lens Epithelium and Posterior Capsule Opacification*. Tokyo: Springer 253–278.
- Menapace R & Di Nardo S (2010): How to better use fluidics in MICS. In: Alió J & Fine H (eds.) *Minimizing incisions and maximizing outcomes in cataract surgery*. Berlin-Heidelberg: Springer 57–68.
- Nanavaty MA, Zukaite I & Salvage J (2019): Edge profile of commercially available edged intraocular lenses: part 2. *J Cataract Refract Surg* (in press).
- Sacu S, Findl O, Menapace R, Georgopoulos M, Buehl W & Rainer G (2002): Assessment of anterior capsule opacification: photographic technique and quantification. *J Cataract Refract Surg* **28**: 271–275.
- Schriefl SM, Menapace R, Stifter E, Zaruba D & Leydolt C (2015a): Posterior capsule opacification and neodymium:YAG laser capsulotomy rates with 2 microincision intraocular lenses: Four-year results. *J Cataract Refract Surg* **41**: 956–963.
- Schriefl SM, Leydolt C, Stifter E & Menapace R (2015b): Posterior capsular opacification and Nd:YAG capsulotomy rates with the iMics Y-60H and Micro AY intra-ocular lenses: 3-year results of a randomized clinical trial. *Acta Ophthalmol* **93**: 342–347.
- Stifter E, Luksch A & Menapace R (2007): Postoperative course of intraocular pressure after cataract surgery with combined primary posterior capsulorhexis and posterior optic buttonholing. *J Cataract Refract Surg* **33**: 1585–1590.
- Stifter E, Menapace R, Neumayer T & Luksch A (2008): Macular morphology after primary posterior capsulorhexis and posterior optic buttonholing. *Am J Ophthalmol* **146**: 15–22.
- Stifter E, Menapace R, Kriechbaum K & Luksch A (2010): Posterior optic buttonholing prevents intraocular pressure peaks after cataract surgery with primary posterior capsulorhexis. *Graefes Arch Clin Exp Ophthalmol* **248**: 1595–1600.
- Werner L, Tetz M, Feldmann I & Buecker M (2009): Evaluating and defining the sharpness of intraocular lenses: microedge structure of commercially available square-edged hydrophilic intraocular lenses. *J Cataract Refract Surg* **35**: 556–566.

Received on January 15th, 2019.
Accepted on May 12th, 2019.

Correspondence:

Rupert Menapace, MD, FEBO
Department of Ophthalmology
Medical University Vienna
Waehringer Guertel 18-20
A-1090 Vienna
Austria
Tel: +43-1-40400-7931, FAX: +43-1-40180-1440
Email: rupert.menapace@meduniwien.ac.at

Supporting Information

Additional Supporting Information may be found in the online version of this article:

Video Clip S1. Videoclip demonstrating primary posterior capsulorhexis with implantation of a ZEISS plate-haptic IOL.