



Cervical Trident-Shaped Neurofibroma: A Rare Variant

Inamul Haque¹ Navanil Barua¹ Nabajyoti Borah¹ Sneha Gang² Ananya Barman²
Shabnam A. Ahmed³

¹Department of Neurosurgery, GNRC Hospitals, Dispur, Assam, India

²Department of Research and Analytics, GNRC Hospitals, Dispur, Assam, India

³Department of Pathology, GNRC Hospitals, Dispur, Assam, India

Address for correspondence Inamul Haque, MCh, MS, MBBS, Department of Neurosurgery, GNRC Hospitals, Dispur, 781006, Assam, India (e-mail: inamulgmc20@gmail.com).

AJNS 2023;18:357–365.

Abstract

Spinal nerve root tumors can arise throughout the spine and at multiple levels, likely representing plexiform neurofibromas that grow from the nerve root into the intraspinal space either intradurally or epidurally and exit through the neural foramen, producing a dumbbell-shaped appearance. Although many cases of dumbbell-shaped extramedullary neurofibromas in the cervical spine have been reported, to the best of our knowledge, there are no reports of trident-shaped extramedullary neurofibromas. A 26-year-old woman presented with swelling over the right side of her neck. Diagnostic workup included magnetic resonance imaging (MRI) and contrast-enhanced computed tomography (CECT) of the neck, which revealed an intradural, extramedullary tumor mass at the right C2–C6 level with an extraspinal extension. Spinal cord compression or canal compromise is the most reliable indication for surgery. The solitary cervical neurofibroma was treated surgically in a single stage through laminoplasty and excision of the intradural tumor along with that of the neck component. This was performed without any complications. A single-stage double approach was adopted in this case. After total excision, the shape of the tumor was found to be more like a trident than a dumbbell. Hence, here we would like to suggest a new nomenclature for this neurofibroma, the trident neurofibroma.

Keywords

- ▶ spinal tumors
- ▶ extramedullary
- ▶ neurofibroma
- ▶ dumbbell
- ▶ laminoplasty

Introduction

Spinal nerve root neurofibromas (NFs) can arise throughout the spine and at multiple levels, and likely represent plexiform tumors based on the involvement of multiple nerve fascicles.¹ Cervical spinal neurofibromas (SNFs) are benign, well-defined, encapsulated tumors, usually arising from the

nerve roots. NFs may present either as solitary lesions or as part of a syndrome, that is, neurofibromatosis 1 (NF-1) or von Recklinghausen's disease of the skin.^{2,3} The etiology behind solitary NF is still unknown. Marocchio et al³ considered solitary NFs to be hyperplastic hamartomatous malformations rather than neoplastic malformations. Anatomically,

article published online
June 7, 2023

DOI <https://doi.org/10.1055/s-0043-1768579>.
ISSN 2248-9614.

© 2023. Asian Congress of Neurological Surgeons. All rights reserved.

This is an open access article published by Thieme under the terms of the Creative Commons Attribution-NonDerivative-NonCommercial-License, permitting copying and reproduction so long as the original work is given appropriate credit. Contents may not be used for commercial purposes, or adapted, remixed, transformed or built upon. (<https://creativecommons.org/licenses/by-nc-nd/4.0/>)

Thieme Medical and Scientific Publishers Pvt. Ltd., A-12, 2nd Floor, Sector 2, Noida-201301 UP, India

neck NFs are relatively rare, with slow painless growth. NFs are usually treated by excision, especially when they are symptomatic or disfiguring.² Based on their location, these tumors can take the form of a dumbbell-shaped mass. The dumbbell NFs are classified into nine types on the basis of extraforaminal extension.^{4,5} Type I (within the spinal canal) and type IIa (extension up to the intervertebral foramen) NFs are usually approached through conventional hemilaminectomy or open-door laminoplasty.⁵ Type IIb and IIc NFs pose a surgical challenge because the majority of these tumors lie in the extraforaminal region. Type III tumors are those which have both dural and foraminal constrictions. The anatomical knowledge of the posterolateral neck triangle and surgical corridors is needed for maximal safe excision.⁴ The variability in terms of location, extent, and size of a dumbbell cervical SNF poses unique technical challenges to the surgeon.⁴ The attachment of the extramedullary part to the surrounding tissues makes dumbbell tumors much important. Surgical expertise is offered over adjuvant radiotherapy as it is a benign disease. In this article, we present a study on type IIIb tumors, the intradural and extradural–paravertebral type with a different shape.

Case Presentation

A 26-year-old woman presented at our Department of Neurosurgery, Guwahati Neurological Research Centre (GNRC), Dispur, Guwahati, Assam, with a history of swelling over the right side of the neck (►Fig. 1). This was gradually progressing in size but with no pain, tingling and numbness, or weakness of limbs. There was no bladder and bowel disturbance either. On presentation, the patient had no deficit. The computed tomography (CT) scan of her neck showed a bilobed soft-tissue density lesion. It was noted in the right paravertebral region of the neck at the C3–C4 disk level causing widening of the right C3 neural foramen involving the C4 exiting nerve root. The lesion was seen abutting and displacing the spinal cord laterally at the C3–C4 level. The lesion showed mild central enhancement on postcontrast study feature, suggesting nerve sheath tumor, likely NF, involving the right C4 nerve root (►Fig. 2). Magnetic resonance imaging (MRI) revealed clear widening of the right C3–C4 neural foramen. A T2 mildly hyperintense (►Fig. 3) and T1 isointense well-defined lesion was seen in the middle third of the neck on the right lateral aspect deep to the sternocleidomastoid muscle extending through the widened neural foramen. There was an intraspinal component of the lesion measuring about 10.5 cm × 1.7 cm (►Fig. 4) effacing the right lateral thecal sac. There was compression and displacement of the cord to the left. The component of the lesion in neck measured approximately 4.1 cm × 2.5 cm (►Fig. 5). Postcontrast scan revealed moderate enhancement of the lesion. There was compression of the right internal jugular vein (IJV). Features were suggestive of NF arising from the right C4 existing nerve root with both intra- and extraspinal components.

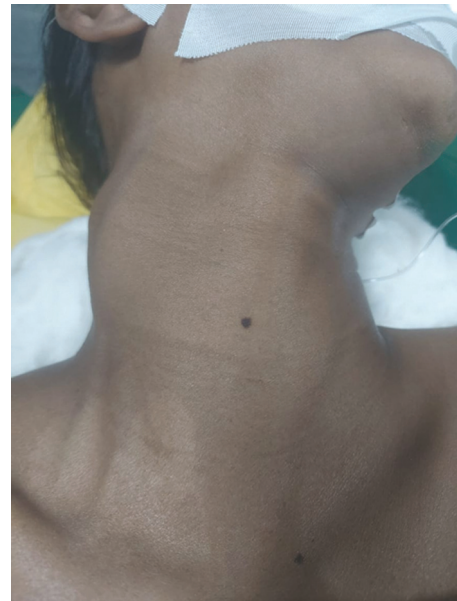

Fig. 1 Intraoperative image showing the large mass on the right neck.

Treatment

The details of the procedure were explained to her. It consisted of a twin approach to the tumor and was operated under general anesthesia. The operation procedure adopted was C2–C6 laminoplasty and excision of the intradural trident tumor along with excision of the neck component. The neck component was excised first (►Fig. 6), followed by the intradural part (►Fig. 7). After total excision, the specimen did not appear like a dumbbell in shape as the intradural component was significantly long extending from C2 to C6. It looked more like a trident (►Fig. 8). Since such a shape of NF is not reported and described in the literature to the best of our knowledge, we would like to address such NFs as TRIDENT NFs. The resected specimen was sent for histopathological examination. The histopathology on hematoxylin and eosin (H&E) staining demonstrated spindle cells with a loose myxoid background (►Fig. 9). The tumor cells had spindle-shaped nuclei, and some of them were curved. Deposition of the collagen bundles in the stroma between the spindle tumor cells was also seen. The results thus confirmed the diagnosis of NF. Postoperatively the patient was mobilized the next day and did not have any motor or sensory deficit with normal power in all the four limbs. The patient made an uneventful recovery and was discharged on postoperative day 4. At the follow-up neurological examinations, she showed normal motor power and sensations. She showed no deficit and was afebrile, continent, and ambulatory.

Discussion

SNFs are benign, well-defined, encapsulated tumors, usually arising from the dorsal nerve roots. It is commonly present in

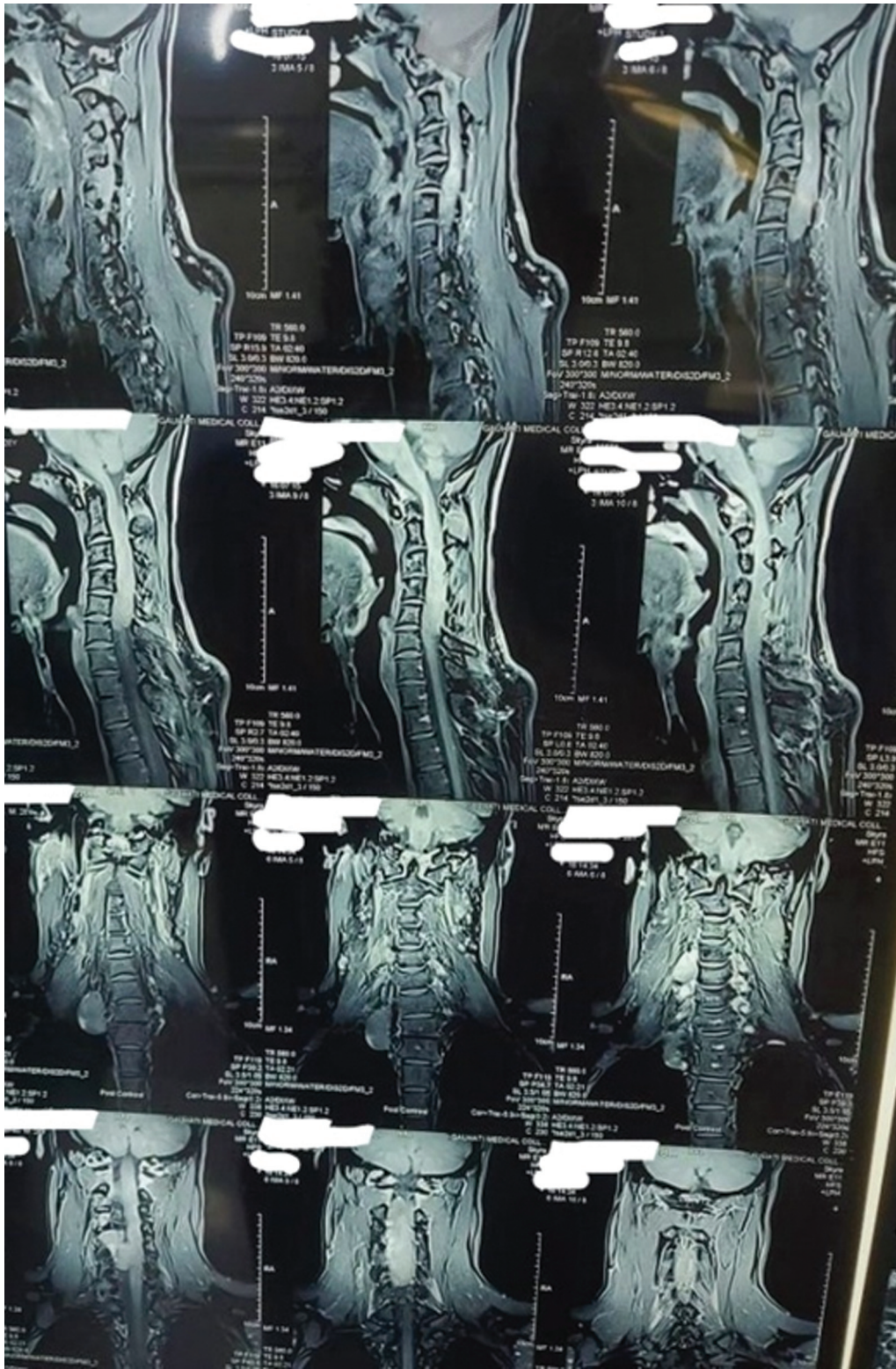


Fig. 2 Sagittal view of the pre-op magnetic resonance imaging showing intradural extramedullary mass.

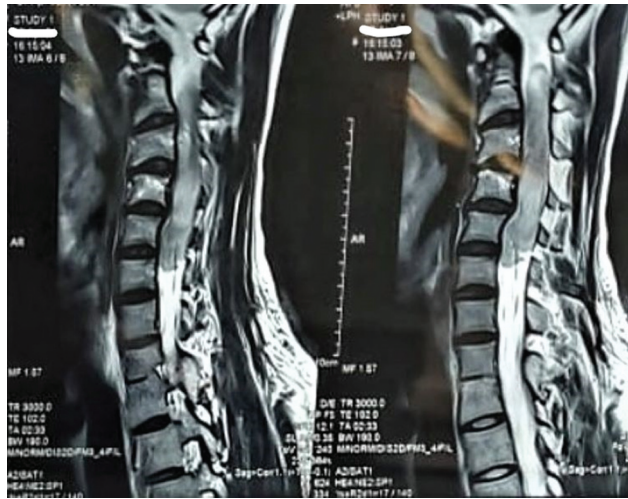

Fig. 3 Pre-op magnetic resonance imaging (MRI).

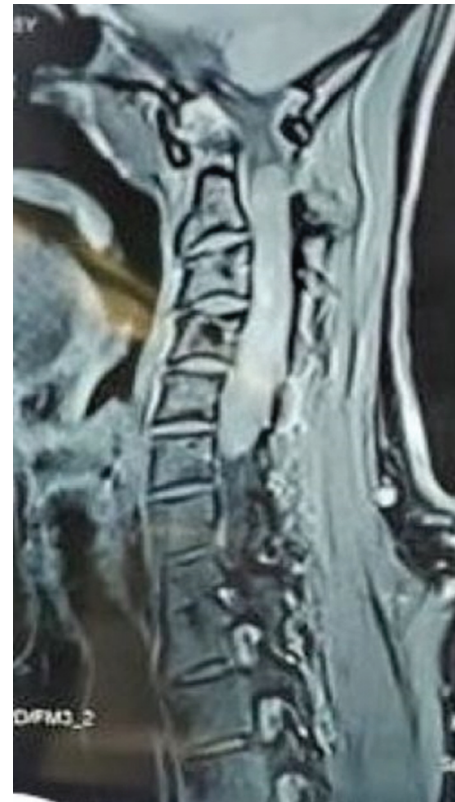

Fig. 4 Pre-op magnetic resonance imaging (MRI).

the fourth and fifth decades of life.⁶ The spinal canal diameter is quite narrow and its close proximity to vertebral artery (VA) ranks cervical SNFs as a technically arduous and demanding surgery. McCormick described dumbbell SNFs as tumors with a contiguous intraspinal, foraminal, or extra-foraminal spread.⁷ The term “dumbbell tumors” does not refer to the dumbbell shape, but it is a conceptual term

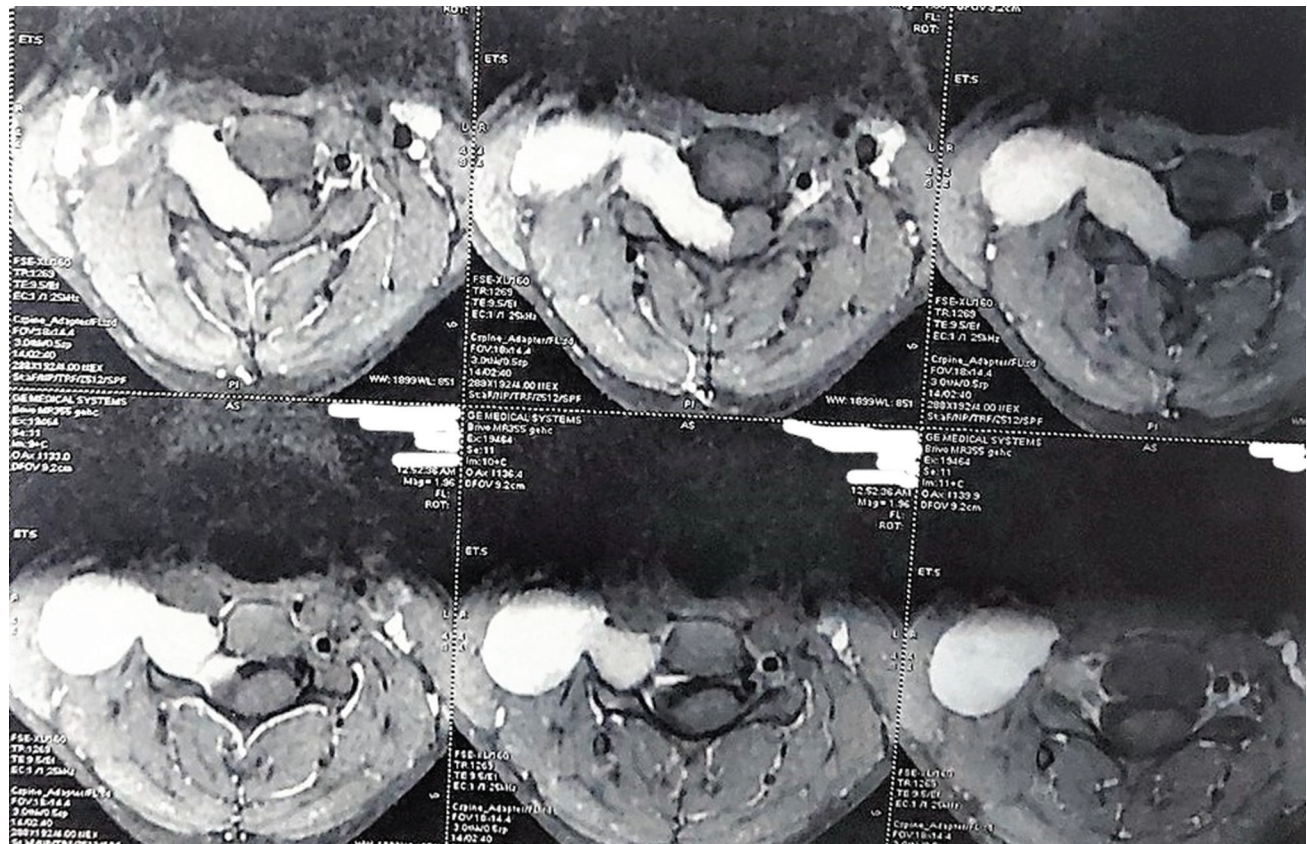


Fig. 5 Pre-op magnetic resonance imaging (MRI) showing extension along the root up to the neck muscle.

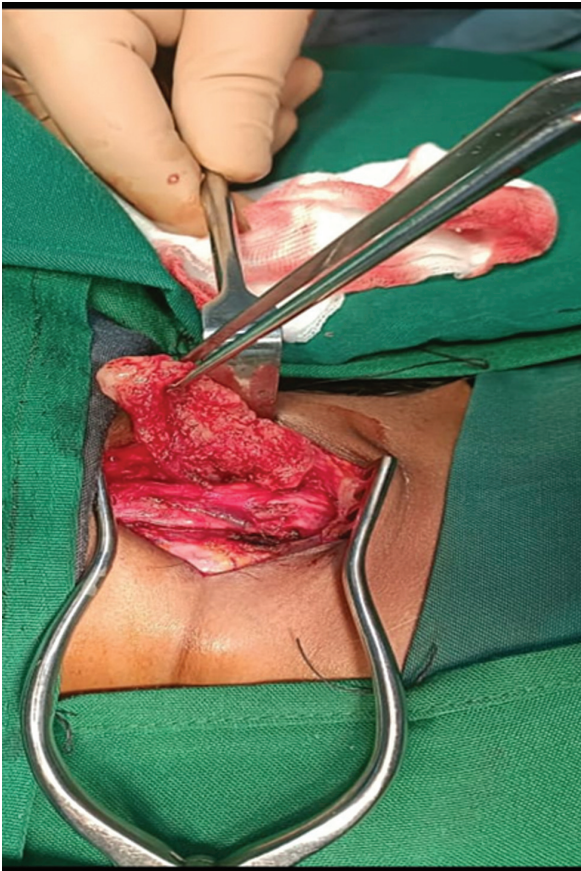


Fig. 6 Intraoperative photograph showing excision of the neck part.

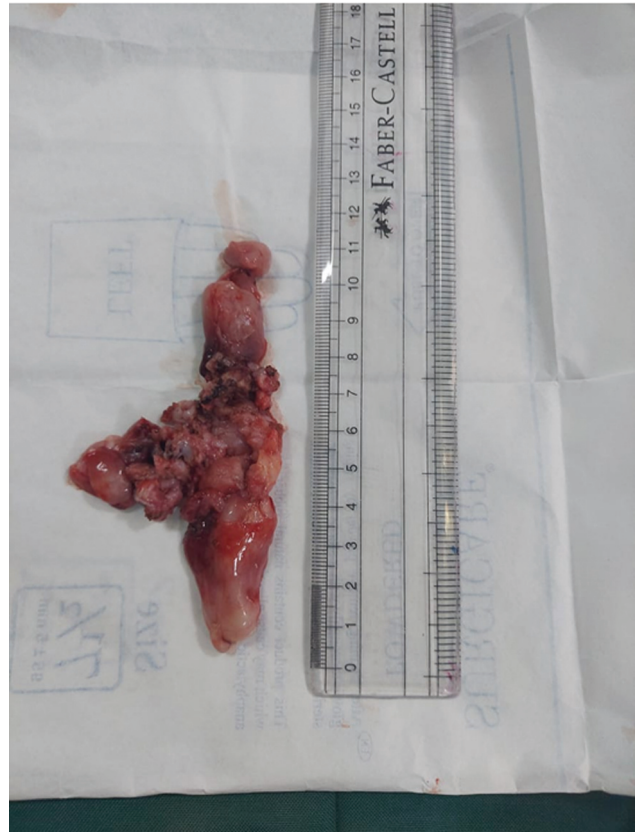

Fig. 8 Trident-shaped excised tumor of length 10.5 cm.

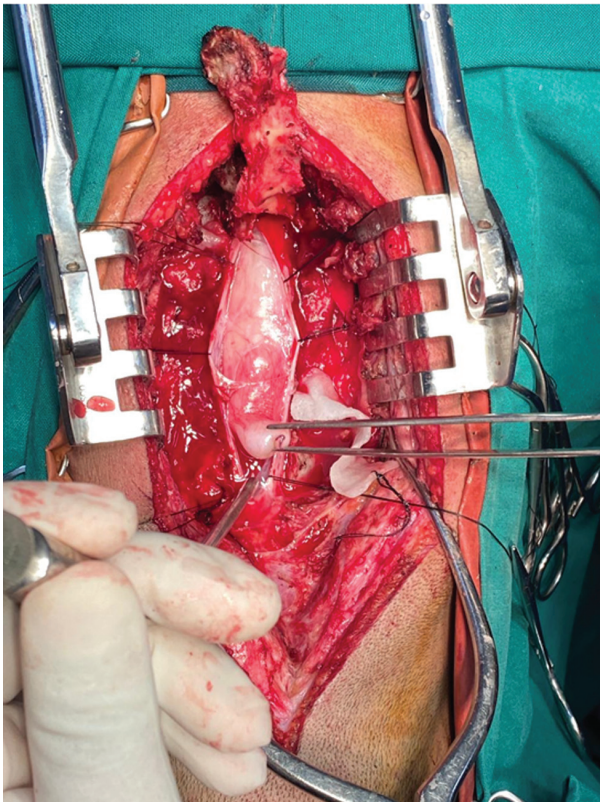


Fig. 7 Intraoperative photograph showing the intradural tumor.

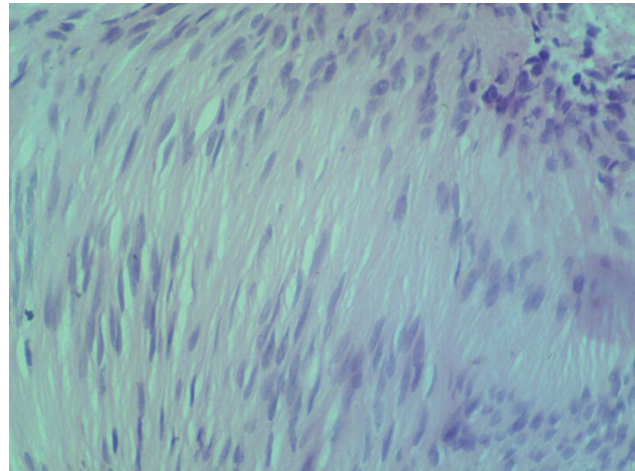


Fig. 9 Histopathology slide.

meaning tumors that connect two or more separate regions, such as intradural, epidural, and paravertebral spaces. Therefore, tumors with intradural and intraforaminal involvement and with intraforaminal and paravertebral involvement are thus considered dumbbell tumors as described by Eden.^{8,9} Nearly 80 to 85% of these tumors remain intradural, but an unfavorable subset spreads extradurally and forms a

dumbbell-shaped mass.⁴ For asymptomatic SNFs that do not create pressure on the spinal cord and important nerve roots, a close clinical and radiological follow-up is suggested. But surgical tumor resection is preferred in the tumors showing rapid growth and/or causing progressive neurodeficit.¹⁰ The gold standard treatment for NFs continues to be surgery. In the head and neck, this often presents a challenge because complete excision of these benign tumors may result in

greater morbidity due to the complicated anatomy. In some cases, complete excision may require sacrifice of the nerves, causing significant functional and locoregional deficits, or result in substantial cosmetic deformity.^{2,3,11} The surgical strategy for an NF located in the middle or lower cervical spine is more complicated, and selection of the most appropriate approach remains controversial.¹² Difficulties have often been encountered with complete resection of

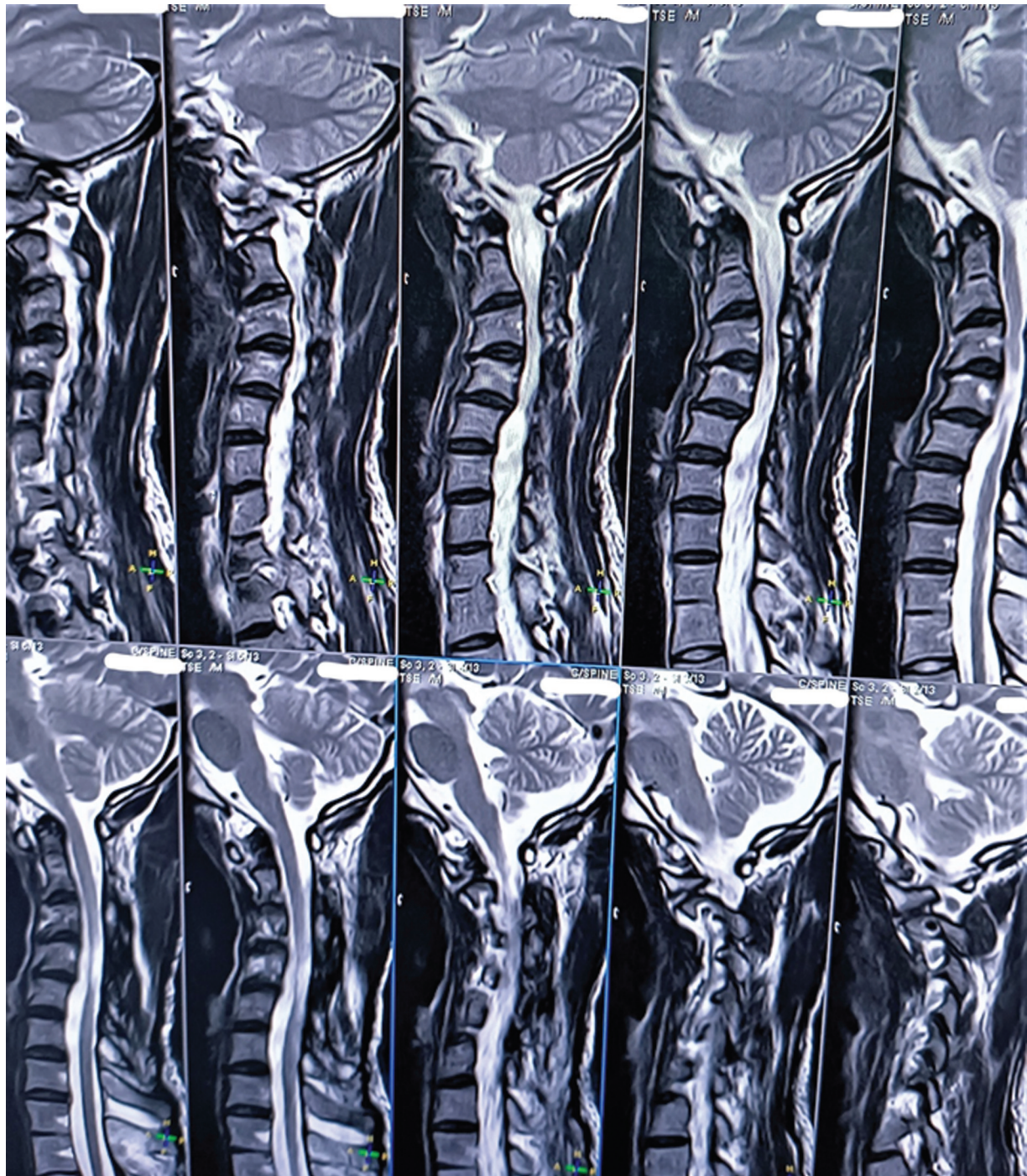


Fig. 10 Post-op magnetic resonance imaging (MRI).

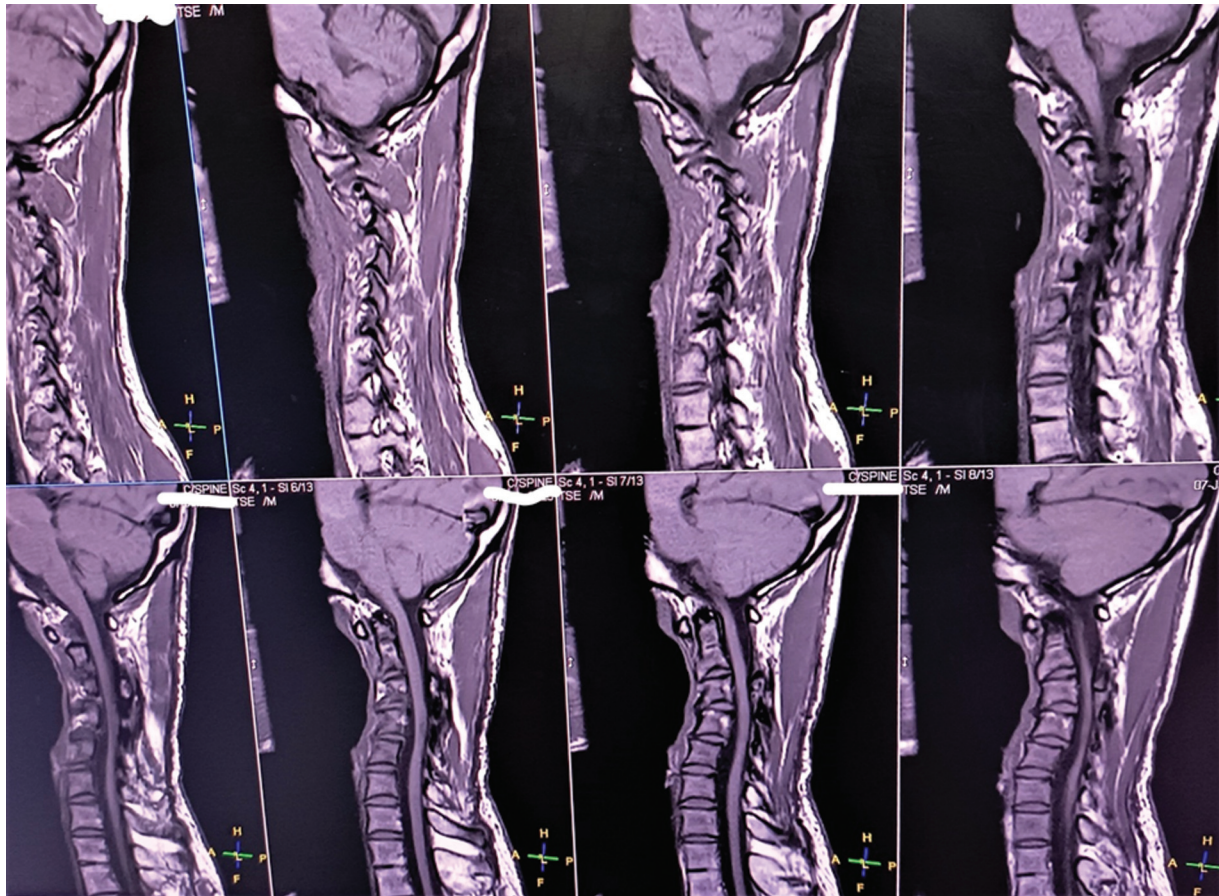


Fig. 11 Post-op magnetic resonance imaging.

dumbbell-shaped tumors extending into the intervertebral foramen of the middle and lower cervical spine. In case of large extraspinal component extending to the neck, a double approach through the neck and other through the lamina is needed, which may be done in a single stage or two stages. The surgical strategy for cervical trident-shaped (dumbbell variant) SNFs located in the middle and lower cervical spine (the C2–C6 region) opted here was the single-stage excision of the neck component followed by laminoplasty and exci-

sion of the intradural part (→ **Figs. 10, 11**). Complete resection of the lesion was performed without any complication (→ **Figs. 12, 13**). After a vigorous survey of the literature, the case presented here seems to represent the first ever case of a solitary trident-shaped spinal neurofibroma, which was excised without any complications. The objective of this study was to present and advocate the optimal practices for such unique lesions that will help provide the best care to the patients.

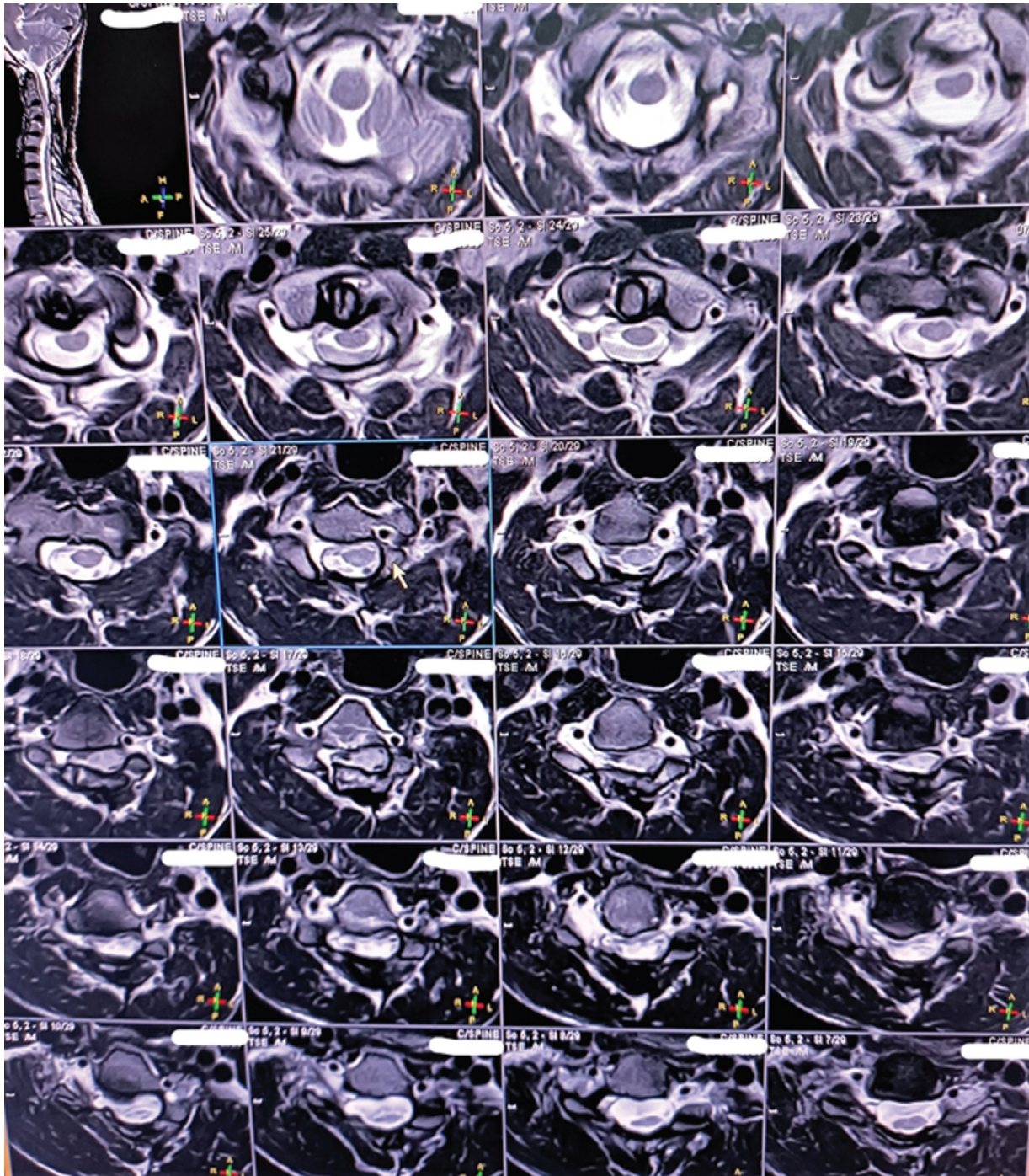


Fig. 12 Post-op magnetic resonance imaging.

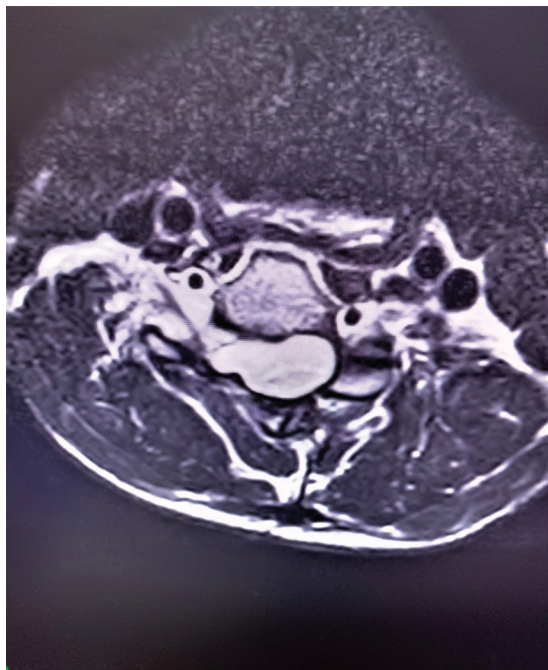


Fig. 13 Post-op magnetic resonance imaging.

Conflict of Interest
None declared.

References

- 1 Leonard JR, Ferner RE, Thomas N, Gutmann DH. Cervical cord compression from plexiform neurofibromas in neurofibromatosis 1. *J Neurol Neurosurg Psychiatry* 2007;78(12):1404–1406
- 2 Hamdoon Z, Jerjes W, Al-Delayme R, Hopper C. Solitary giant neurofibroma of the neck subjected to photodynamic therapy: case study. *Head Neck Oncol* 2012;4:30
- 3 Marocchio LS, Oliveira DT, Pereira MC, Soares CT, Fleury RN. Sporadic and multiple neurofibromas in the head and neck region: a retrospective study of 33 years. *Clin Oral Investig* 2007;11(02):165–169
- 4 Singh S, Mehrotra A, Shankar R, et al. Revisiting the surgical corridors for cervical type IIb-c dumbbell neurofibroma: A series of two unconventional approaches and review of literature. *J Craniovertebr Junction Spine* 2020;11(02):111–117
- 5 Asazuma T, Toyama Y, Maruiwa H, Fujimura Y, Hirabayashi K. Surgical strategy for cervical dumbbell tumors based on a three-dimensional classification. *Spine* 2004;29(01):E10–E14
- 6 Lenzi J, Anichini G, Landi A, et al. Spinal nerves schwannomas: experience on 367 cases—historic overview on how clinical, radiological, and surgical practices have changed over a course of 60 years. *Neurol Res Int* 2017;2017:3568359
- 7 McCormick PC. Surgical management of dumbbell tumors of the cervical spine. *Neurosurgery* 1996;38(02):294–300
- 8 Ozawa H, Kokubun S, Aizawa T, Hoshikawa T, Kawahara C. Spinal dumbbell tumors: an analysis of a series of 118 cases. *J Neurosurg Spine* 2007;7(06):587–593
- 9 Eden K. The dumb-bell tumors of the spine. *Br J Surg* 1941; 28:549–570
- 10 Sarica FB. Surgical principles for spinal and paraspinal neurofibromas. In: Morgan LR, Sarica FB, eds. *Brain and Spinal Tumors: Primary and Secondary*. London: Intech Open; 2019:85760
- 11 Hanabusa K, Morikawa A, Murata T, Taki W. Acoustic neuroma with malignant transformation. Case report. *J Neurosurg* 2001;95(03):518–521
- 12 Ito K, Aoyama T, Miyaoka Y, Horiuchi T, Hongo K. Surgical strategies for cervical spinal neurinomas. *Neurol Med Chir (Tokyo)* 2015;55(07):557–563