



REVIEW ARTICLE

# Efficacy of bone graft as monotherapy and in combination with platelet concentrates in grade II furcation defect – A systematic review and meta-analysis

Vinisha Ashok Bajaj, Abhay Pandurang Kolte \*, Rajashri Abhay Kolte

Department of Periodontology and Implant Dentistry, VSPM Dental College and Research Centre, Nagpur, India

Received 29 May 2022; revised 28 September 2022; accepted 2 October 2022  
Available online 7 October 2022

## KEYWORDS

Platelet concentrates;  
Grade II furcation defect;  
Bone graft;  
Bone regeneration

**Abstract** *Background:* The use of autologous platelet concentrates (PC) in addition to bone graft (BG) in open flap debridement (OFD) has been investigated to improve the efficacy and outcomes of regenerative therapy for furcation defects. This systematic review evaluated efficacy of added benefits of PC to bone grafts in treatment of grade II furcation defects.

*Methods:* A thorough literature search on PubMed, Cochrane Library and Google Scholar databases was conducted. Data on outcomes were extracted only from randomized controlled clinical trials on humans with a minimum follow up of 6 months comparing BG alone and BG + PC in treatment of mandibular grade II furcation defect.

*Results:* 36 of the 518 screened articles and abstracts were read in full-text, nine of which have been included in the meta-analysis. The addition of PC to BG has resulted in improvement in PD, GR (with smaller effect); V-DBD and H-DBD showed smaller change in experimental group whereas VCAL and HCAL exhibited overall larger changes with smaller effect.

*Conclusion:* Bone regeneration in terms of defect fill with the addition of platelet concentrates to bone graft remains debatable considering the minimal benefits in the treatment of grade II mandibular furcation defect.

© 2022 The Authors. Production and hosting by Elsevier B.V. on behalf of King Saud University. This is an open access article under the CC BY-NC-ND license (<http://creativecommons.org/licenses/by-nc-nd/4.0/>).

\* Corresponding author at: 104, Department of Periodontics and Implant Dentistry VSPM Dental College and Research Centre, Digidoh Hills, Hingna Road, Nagpur, India. Tel.: +91 9011071467.

E-mail addresses: [itsvinisha@gmail.com](mailto:itsvinisha@gmail.com) (V.A. Bajaj), [drabhaypkolte@gmail.com](mailto:drabhaypkolte@gmail.com) (A.P. Kolte), [drrajashrikolte@gmail.com](mailto:drrajashrikolte@gmail.com) (R.A. Kolte).  
Peer review under responsibility of King Saud University. Production and hosting by Elsevier.



Production and hosting by Elsevier

## Contents

1. Introduction . . . . .	638
2. Materials and methods . . . . .	639
2.1. Protocol . . . . .	639
2.2. Eligibility . . . . .	639
2.3. Search strategy . . . . .	639
2.4. Quality assessment of included studies . . . . .	639
2.5. Risk of bias assessment in individual studies . . . . .	639
3. Statistical methods . . . . .	640
4. Metanalysis . . . . .	640
4.1. Probing depth (PD) . . . . .	640
4.2. Gingival recession (GR) . . . . .	641
4.3. Vertical depth of bone defect (V-DBD) . . . . .	643
4.4. Horizontal depth of bone defect (H-DBD) . . . . .	643
4.5. Vertical clinical attachment level (VCAL) . . . . .	643
4.6. Horizontal clinical attachment level (HCAL) . . . . .	643
5. Discussion . . . . .	644
6. Conclusion . . . . .	645
7. Clinical relevance . . . . .	645
Ethical statement . . . . .	645
Conflict of Interest Statement . . . . .	645
CRediT authorship contribution statement . . . . .	645
Acknowledgement . . . . .	645
References . . . . .	645

## 1. Introduction

Due to the position of the furcation and also the irregular anatomy of the roots, which makes the biofilm virtually inaccessible for oral hygiene measures, clinical management of furcation defects which is a typical sequelae of disease, remains a critical issue. The degree of furcation involvement may be a risk factor for tooth loss in itself, with a high relative weight, alongside several well-known patient-related factors like age, gender, smoking habit, and diabetes. These areas could also be surgically treated employing a style of reconstructive periodontal surgical techniques and materials as suggested by [Tarallo et al. \(2020\)](#). [Mellonig et al. \(1976\)](#) attempted regenerative treatment for furcation defects in humans for the first time, that was histologically confirmed with the application of the principle of guided tissue regeneration (GTR). The amount of periodontal regeneration achieved with bone grafts (BG) was discovered to be highly variable and dependent on a range of things including root and defect morphology, defect volume, furcal anatomy, tooth mobility, and gingival tissue thickness as shown by [Agarwal et al. \(2019\)](#) and [Swami et al. \(2021\)](#). The most typically used materials during this context are bone substitutes (autologous, allogenic, xenogenic, or synthetic in origin) alone or in combination with membranes (either resorbable or non-resorbable). However, the utilization of membranes necessitates additional considerations like a more invasive flap, an extra surgery to get rid of the membrane (in the case of non-resorbable membranes), and therefore the possibility of membrane exposure, which can jeopardise the results. Given these considerations, the present trend is to prefer minimally invasive surgical procedures and to hunt out highly performant materials to limit the utilization of synthetic membranes, particularly when treating

contentious defects. The employment of PC together with BG has been investigated so as to enhance the efficacy and outcomes of regenerative therapy. The rationale for such an approach stems from PC's ability to enhance wound healing in both hard and soft tissues by inducing the differentiation of human periodontal ligament stem cells and fibroblasts into osteoblast-like cells and improving fibroblast and osteoblast migration and proliferation. These effects appear to be associated with the high concentrations of growth factors and other plasma proteins (fibrin, fibronectin, and vitronectin) found in platelet granules. Platelet-derived growth factor (PDGF) modulated guided tissue regenerative therapy when combined with common methods show more bone-fill compared to GTR therapy alone. Introduction of the platelet-rich plasma (PRP) as a source of growth factors like PDGF, TGF- $\beta$  and IGF-I prompted its use as an autogenic and safe material in the enhancement of regeneration process. Growth factors can speed up the healing process of tissues. PRGF (Plasma rich growth factors) may be a source of autologous growth factors, consisting of PDGF and transforming growth factor- $\beta$  (TGF- $\beta$ ). According to [Chang and Zhao \(2011\)](#), [Creepier et al. \(2009\)](#), [Giannobile \(1996\)](#), [Lafzi et al. \(2013\)](#), [Mansouri et al. \(2012\)](#), and [Nikolidakis & Jansen \(2008\)](#), applying a combined technique using BPBM (bovine porous bone mineral) and PRGF results in greater healing—though not significantly so—when treating mandibular class II furcation defects.

Intra-oral surgical sites may benefit from the use of Platelet Rich Fibrin (PRF), a second-generation platelet concentrate, as a stand-alone, additive, or a combination therapy. By offering a sturdy fibrin scaffold and major growth factors like transforming growth factor  $\beta$  (TGF- $\beta$ ), platelet-derived growth factor (PDGF), insulin-like growth factor 1 (IGF1),

vascular endothelial growth factor (VEGF), and epidermal growth factor (EGF); it is frequently utilised in conjunction with biomaterials as a graft material or barrier membrane (Hamzacebi et al., 2015) to activate and facilitate the host tissue's ability to repair and regenerate. In addition to the above properties it also protects bone graft sites from contamination when applied as a protective barrier. This helps to avoid perforations of the fragile gingival tissues.

Furthermore, it's unclear whether the addition of PC to a bone graft can improve clinical outcomes for the regenerative treatment of this anatomical area. Given these considerations, the rationale for a brand new review of the literature focusing solely on the utilization of BG alone or together with PC in grade II furcation treatment appears to emerge.

As a result, the objective of this systematic review and meta-analysis was to evaluate the strength of the evidence in favour of using BG alone or in combination with PC to treat grade II furcation defects.

## 2. Materials and methods

### 2.1. Protocol

This systematic review was carried out in accordance with the "Cochrane Handbook for Systematic Reviews of Interventions" guidelines and is reported in accordance with the PRISMA guidelines (Liberati et al., 2009) and has answered the subsequent focused question: "What is the efficacy of bone

graft in combination with platelet concentrates in grade II furcation defect.?" The University of York's Center for Reviews and Dissemination employed an individual PROSPERO ID to pre-specify the analysis processes and inclusion criteria in the International Prospective Register of Systematic Reviews (CRD42021295416).

### 2.2. Eligibility

According to the 'PICO' question formulation, a framework developed to facilitate the literature search, this systematic review focused on all types of human studies (studies), on young and adult periodontal patients with grade II furcation defects in first and second molars who received the additional application of PC to a BG treatment (intervention), evaluating the amount of soft and hard tissue regeneration (outcome), compared to subjects treated with BG alone (comparator). Randomized controlled trials, and studies on adults or adolescents using PC in conjunction with BG for grade II furcation defect treatment and with a minimum follow-up period of 6 months were included. According to the exclusion criteria, all in vitro studies, animal studies, meta-analyses, case reports, mini reviews, conference proceedings and previous systematic reviews on the use of PC in conjunction with BG in the treatment of furcation defects were not considered.

### 2.3. Search strategy

On PubMed, Cochrane Library, and Google Scholar, a thorough electronic search for articles published up to February 2022 was performed. The following search criteria were applied individually and in combination to guarantee that all studies on grade II furcation defect that involved bone grafts and platelet concentrates were included: ("furcation defect" [MeSH Terms] OR "periodontal regeneration" [All Fields] AND "furcation involvement" [All Fields] OR "furcation" [All Fields] OR "Class II furcation defect" [All Fields] OR "Degree II furcation defect" OR "Grade II furcation defect" AND "bone graft" OR "bone substitute" "Clinical Study" AND "Clinico-Radiographic Study" OR "Clinico-Radiographic Study" AND CBCT [Cone Beam Computed Tomography] [All Fields] OR "CBCT").

### 2.4. Quality assessment of included studies

The articles were initially screened by two independent reviewers (V.B. and A.K.) based on their titles and abstracts. Disagreement about whether to include or exclude were resolved through discussion and, if necessary, the involvement of a third examiner (R.K.). The kappa coefficient was used to assess inter-rater agreement once more and for extracting the data from the groups of interest if a study compared more than two arms that met the inclusion criteria.

### 2.5. Risk of bias assessment in individual studies

The Cochrane Collaboration technique was used to assess the risk of bias in the studies that were included. Each study was assessed using six criteria: proper sequence creation, allocation sequence concealment, participant blinding, inadequate out-

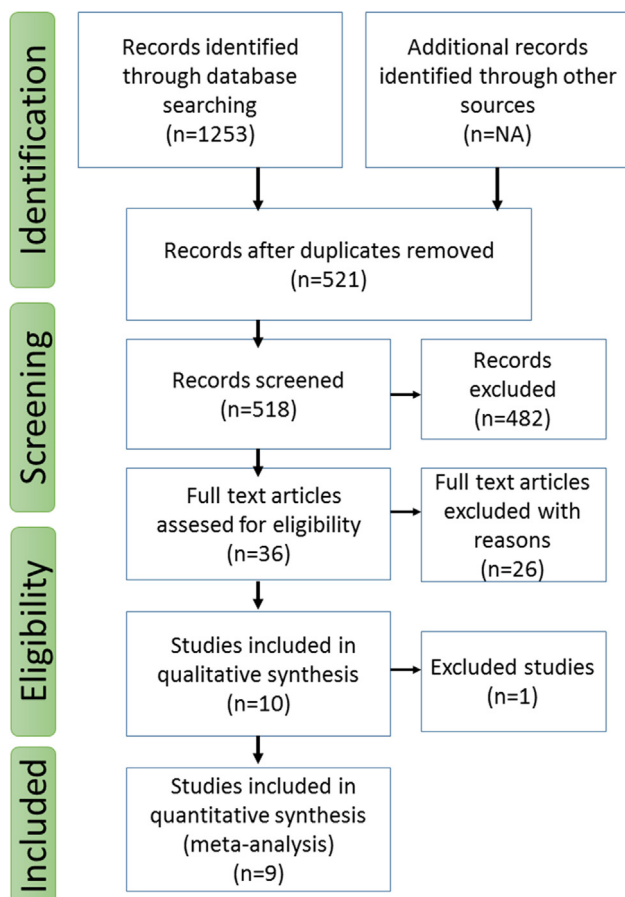


Fig. 1 Flow diagram of the article selection process.

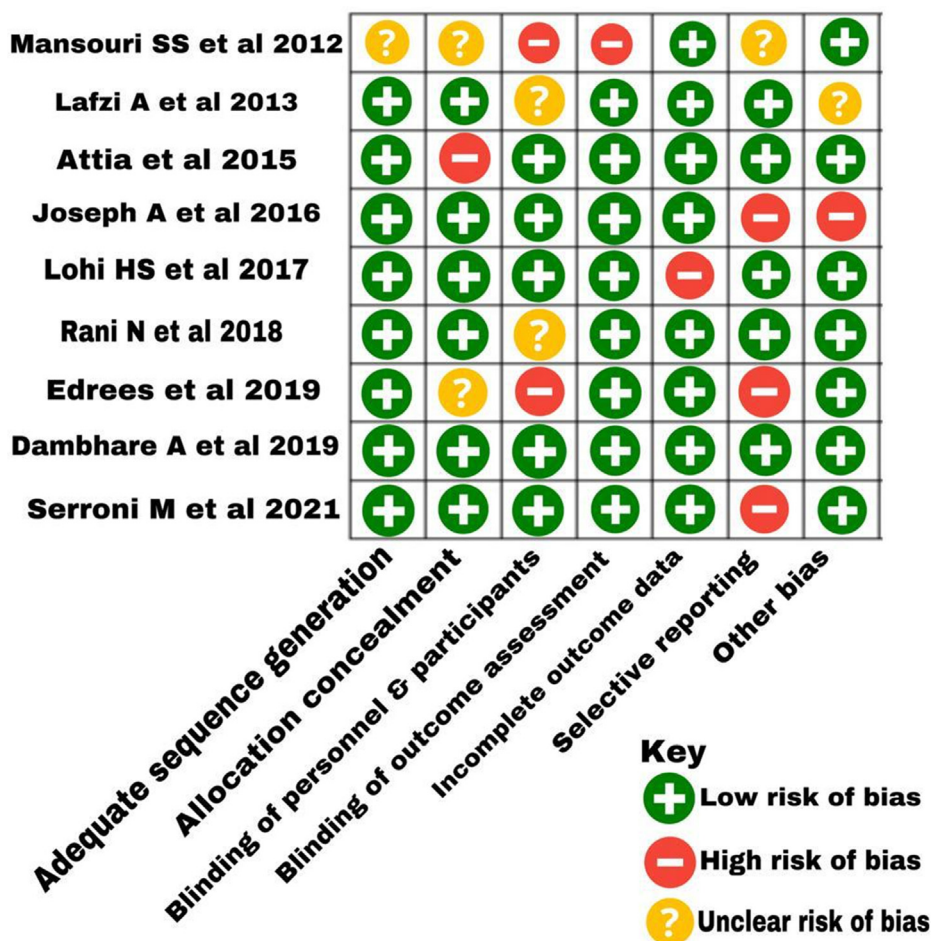


Fig. 2 Risk of bias summary.

come data, selective outcome reporting, and additional sources of bias as given in Fig. 2 (Higgins et al., 2011).

3. Statistical methods

The data on various parameters at baseline and after six months follow up was collated from various studies as described in Table 1. The mean and standard deviation at two time points, along with sample size and statistical significance were reported for each parameter. The data was referred to estimate the mean change in the parameter value between two time points. To determine the standard deviation for change in parameter value, an estimate of correlation coefficient was obtained by referring to respective p-values. The standard deviation for change in values was obtained using.

$$sd_c = \sqrt{sd_1^2 + sd_2^2 - 2rsd_1sd_2}$$

The data was used to obtain the standardized mean difference (SMD), and measures of heterogeneity of outcome across studies. A typical measure of inconsistency i.e. I<sup>2</sup> along with statistical significance was obtained for each study parameter. The weights for different studies were obtained for fixed and

random effects model. Forest plot was obtained for visualization of the effect size was obtained. All the analyses were performed using meta library from R-3.4.3 programming tool and statistical significance was tested at 5% level.

4. Metanalysis

4.1. Probing depth (PD)

Fig. 3 provides the forest plot for standardized mean difference according to study for PD. The weights under fixed and random effects model corresponding to each study are also shown. The maximum fixed weight (19.1%) and random weight (13.4%) was assigned to study by Serroni et al. (2021). The analysis of heterogeneity of parameter shows statistically significant heterogeneity with p < 0.01. The I<sup>2</sup> value of 65% suggests substantial inconsistency of parameter across studies. The combined fixed effect is 0.58 [95% CI: 0.29, 0.87], while the combined random effects is 0.69 [95% CI: 0.20, 1.18], and both the confidence intervals do not include zero, suggesting that there is good evidence that the parameter PD shows substantial change in experimental samples as compared to control samples.

**Table 1** Studies included for systematic review and meta-analysis;

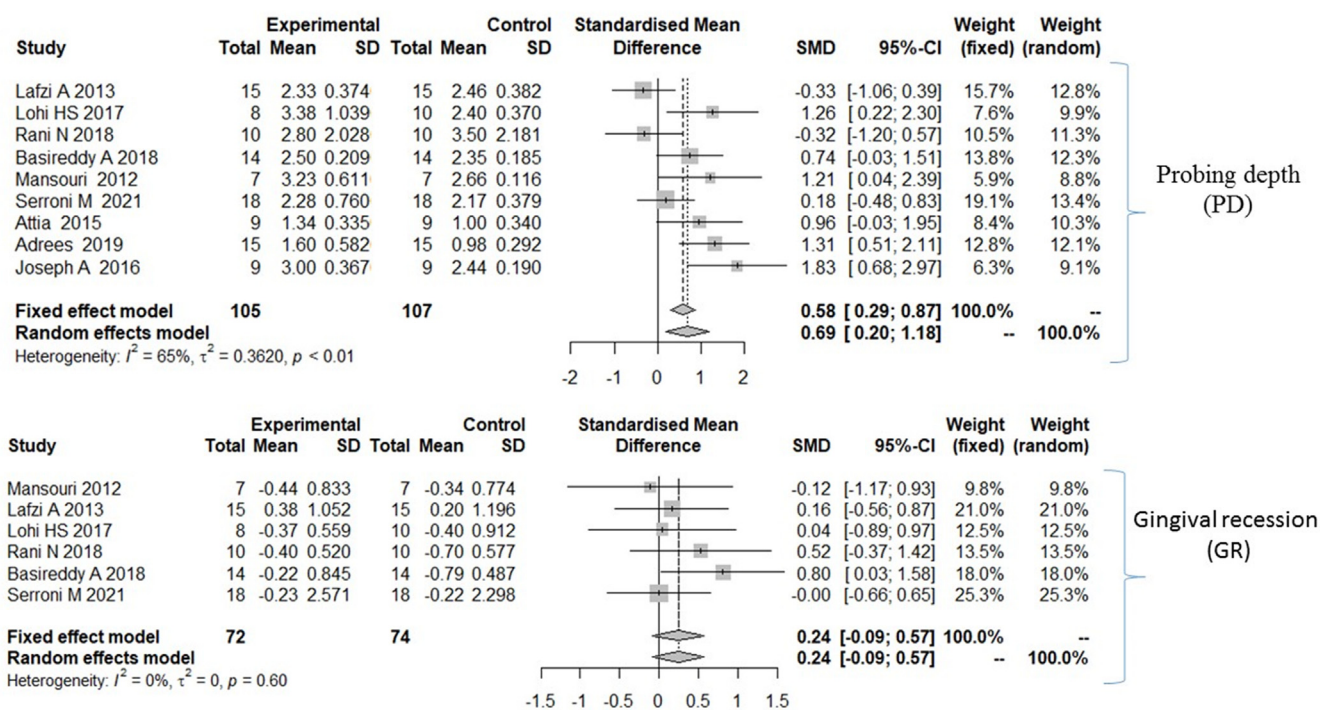
Study	Intervention	Number of patient/ defects	Follow-up period	Conclusions
Mansouri et al. 2012	-BPBM -BPBM + PRGF	7/14 (splitmouth study)	Baseline 6 months	Despite the statistically insignificant results, it appeared that PRGF combined with graft materials is effective in the treatment of furcation defects, resulting in a larger PD reduction and CAL gain than graft materials alone. Larger sample numbers and histological examinations are advised in future research.
Lafzi et al. 2013	-ABG -ABG + PRGF	30/30	Baseline 6 months	When baseline and 6-month data were analysed, there were clinically significant improvements in all soft and hard tissue measures. Nonetheless, there were no significant differences between these approaches in the treatment of mandibular molars with grade II furcation involvement.
Attia 2016	-NcHA -NcHA + PRF	18/18	Baseline 6 months 12 months	Both NcHA and NcHA + PRF significantly improved clinical metrics and bone density. In terms of PD reduction, VCAL gain, HCAL gain, and increased alveolar bone density, the adjunctive use of PRF paired with NcHA bone graft was clinically, radiographically, and statistically significant compared to NcHA bone graft alone.
Joseph 2016	-Novabone - Novabone + PRF	9/18 (splitmouth study)	Baseline 6 months	In the treatment of grade II furcation problems, both bioactive glass alone and bioactive glass + PRF are effective. Adding PRF to Novabone putty resulted in an increase in CAL, indicating regeneration, while radiographic proof of bone fill could not be obtained.
Lohi et al. 2017	-BCCG -BCCG + PRF	16/18	Baseline 6 months	In the treatment of mandibular Class II furcation deformities, supplementary use of PRF with BCCG is preferred to BCCG alone.
Rani et al. 2018	- $\beta$ -TCP - $\beta$ -TCP + PRF	20/20	Baseline 6 months	The natural fibrin biomaterial PRF has enormous potential for surgical wound healing due to its unique characteristics. PRF + bone graft demonstrated to be an effective regenerating material in the treatment of Grade II furcation, resulting in a decrease in vertical and HDD as well as an increase in clinical attachments. Histological examination of the regenerated tissue as well as strategies to enhance growth factor supply when employing PRF could be incorporated in further research.
Edrees et al. 2019	-NcHA -NcHA + PRF	30/30	Baseline 6 months 12 months	Both NcHA and NcHA with PRF improved clinical parameters and bone density considerably. When PRF was used in conjunction with NcHA, the results were clinically and radiographically significant when compared to NcHA bone graft alone.
Dambhare et al. 2019***	-HA + $\beta$ -TCP -HA + $\beta$ -TCP + PRF	24/24	Baseline 12 months	In the $\beta$ -TCP + PRF group, the number of class II furcation defects that closed or converted to class I was greater than in the $\beta$ -TCP alone group. The difference in Gingival recession between the two groups was not significant. Although the favourable clinical outcomes obtained in this study require further confirmation from histologic investigations to establish the quality of the regenerated tissue, the use of PRF in conjunction with -TCP appeared to be a viable technique for the treatment of class II furcation defect.
Basireddy et al. 2019	-DFDBA -DFDBA + PRF	14/28 (splitmouth study)	Baseline 6 months	The addition of PRF to DFDBA appears to promote soft tissue healing while having little effect on bone fill. From a clinical standpoint, the most ideal outcome is the complete elimination of the interradicular defect. In the current investigation, however, none of the defects were completely closed.
Serroni et al. 2021	-ABG -ABG + L-PRF	54/54	Baseline 6 months	When compared to ABG alone, ABG + L-PRF therapy resulted in a considerably higher HCAL gain. Because the L-PRF + ABG combination is totally autogenous, there is no risk of transmitting infectious organisms that are known or possibly unknown.

\*\*\* Study excluded from meta-analysis.

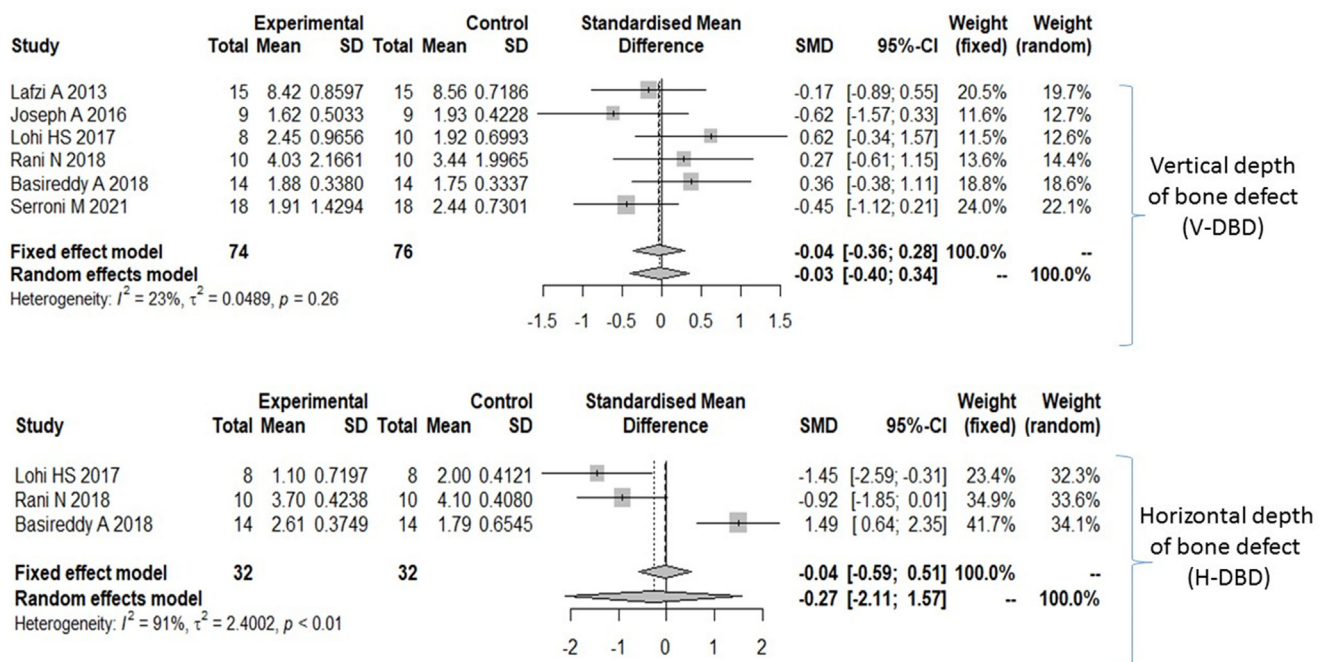
#### 4.2. Gingival recession (GR)

Fig. 3 provides the forest plot for standardized mean difference according to study for GR. The maximum fixed and random weight (25.3%) was assigned to study by Serroni et al. (2021). The analysis of heterogeneity of parameter shows sta-

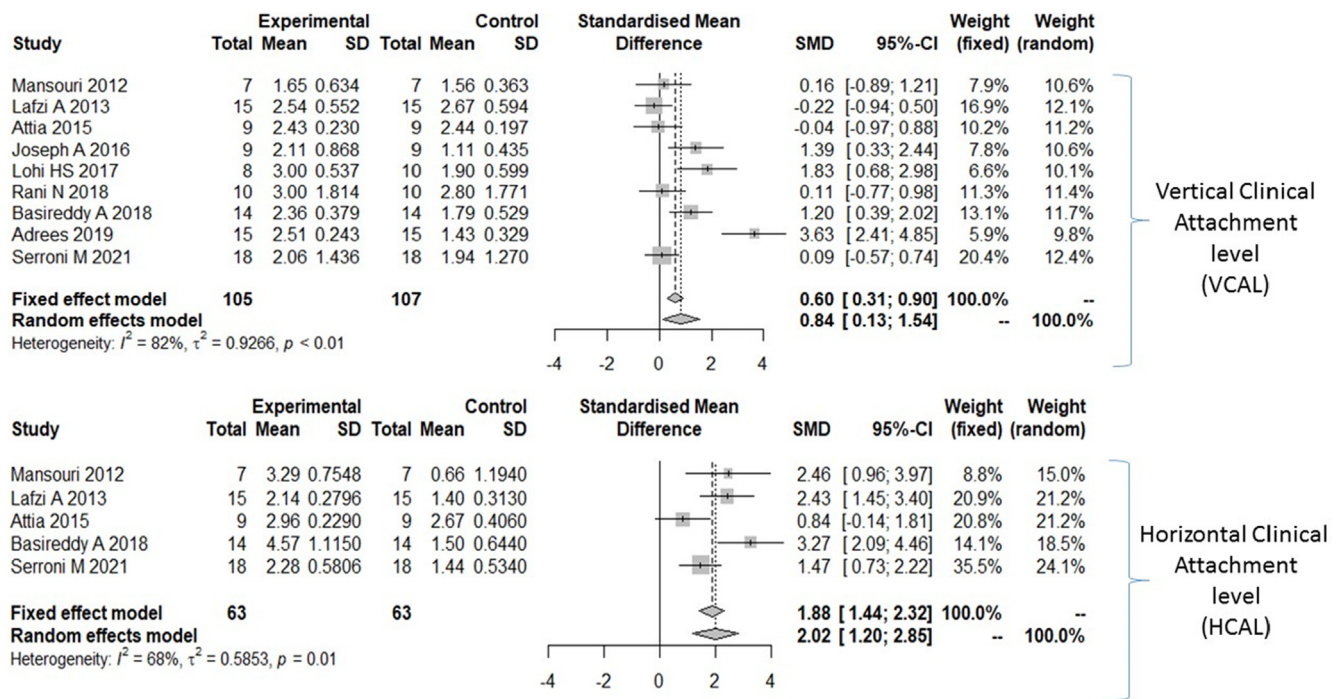
tistically insignificant heterogeneity with  $p = 0.60$ . The  $I^2$  value of 0% suggests that the variability in studies is entirely due to chance. Since the heterogeneity is absent and there is only within study variance, the random effects model coincides with fixed effect model with common combined effect size of 0.24 [95% CI: -0.09, 0.57], suggesting that the overall change



**Fig. 3** Forest plot for standardized mean difference for Probing depth (PD) and Gingival Recession (GR) SD: Standard deviation; CI: Confidence interval; %: Percentage;  $I^2$ : Variation across studies due to heterogeneity;  $\tau^2$ : Estimated standard deviation of underlying effects across studies; p: probability of obtaining the observed effect.



**Fig. 4** Forest plot for standardized mean difference for Vertical depth of bone defect (V-DBD) and Horizontal depth of bone defect (H-DBD) SD: Standard deviation; CI: Confidence interval; %: Percentage;  $I^2$ : Variation across studies due to heterogeneity;  $\tau^2$ : Estimated standard deviation of underlying effects across studies; p: probability of obtaining the observed effect.



**Fig. 5** Forest plot for standardized mean difference for Vertical Clinical Attachment level (VCAL) and Horizontal Clinical Attachment level (HCAL) SD: Standard deviation; CI: Confidence interval; %: Percentage;  $I^2$ : Variation across studies due to heterogeneity;  $\tau^2$ : Estimated standard deviation of underlying effects across studies; p: probability of obtaining the observed effect.

in GR from baseline to 6 months is higher in experimental samples as compared to control samples, although the effect is insignificant as the confidence interval includes zero.

4.3. Vertical depth of bone defect (V-DBD)

Fig. 4 provides the forest plot for standardized mean difference according to study for parameter V-DBD. The maximum fixed weight (24.0%) and random weight (22.1%) was assigned to study by Serroni et al. (2021). The analysis of heterogeneity of parameter shows statistically insignificant heterogeneity with  $p = 0.26$ . The  $I^2$  value of 23% suggests marginal inconsistency of parameter across studies. The combined fixed effect is  $-0.04$  [95% CI:  $-0.36, 0.28$ ], while the combined random effects is  $-0.03$  [95% CI:  $-0.40, 0.34$ ], and both the confidence intervals include zero, suggesting that the parameter V-DBD shows overall smaller change in experimental samples as compared to control samples.

4.4. Horizontal depth of bone defect (H-DBD)

Fig. 4 provides the forest plot for standardized mean difference according to study for parameter H-DBD. The maximum fixed weight (41.7%) and random weight (34.1%) was assigned to study by Basireddy et al. (2019). The analysis of heterogeneity of parameter shows statistically significant heterogeneity with  $p < 0.01$ . The  $I^2$  value of 91% suggests considerable inconsistency of parameter across studies. The combined fixed effect is  $-0.04$  [95% CI:  $-0.59, 0.51$ ], while the combined random effects is  $-0.27$  [95% CI:  $-2.11, 1.57$ ], and both the confidence

intervals include zero, suggesting that the parameter H-DBD shows overall smaller change in experimental samples as compared to control samples.

4.5. Vertical clinical attachment level (VCAL)

Fig. 5 provides the forest plot for standardized mean difference according to study for parameter VCAL. The maximum fixed weight (20.4%) and random weight (12.4%) was assigned to study by Serroni et al. (2021). The analysis of heterogeneity of parameter shows statistically significant heterogeneity with  $p < 0.01$ . The  $I^2$  value of 82% suggests considerable inconsistency of parameter across studies. The combined fixed effect is  $0.60$  [95% CI:  $0.31, 0.90$ ], while the combined random effects is  $0.84$  [95% CI:  $0.13, 1.54$ ], and both the confidence intervals does not include zero, suggesting that the parameter VCAL shows overall larger change in experimental samples as compared to control samples.

4.6. Horizontal clinical attachment level (HCAL)

Fig. 5 provides the forest plot for standardized mean difference according to study for parameter HCAL. The maximum fixed weight (35.5%) and random weight (24.1%) was assigned to study by Serroni et al. (2021). The analysis of heterogeneity of parameter shows statistically significant heterogeneity with  $p = 0.01$ . The  $I^2$  value of 68% suggests substantial inconsistency of parameter across studies. The combined fixed effect is  $1.88$  [95% CI:  $1.44, 2.32$ ], while the combined random effects is  $2.02$  [95% CI:  $1.20, 2.85$ ], and both the confidence intervals

does not include zero, suggesting that the parameter HCAL shows overall larger change in experimental samples as compared to control samples.

## 5. Discussion

Periodontal surgery wounds are complex to heal, and numerous cells and growth factors are involved in the healing process. Platelets assist in clot formation and release a series of growth factors involved in cell division and differentiation, resulting in wound repair and tissue formation and so can be employed to aid in tissue healing process.

Both treatment techniques resulted in similar results when [Mansouri et al. \(2012\)](#) compared Bovine Porous Bone Mineral (BPBM) in Combination with Plasma Rich in Growth Factors (PRGF) (i.e a mixture of BPBM and coagulated PRGF gel) for the treatment of mandibular class II furcation defects. The probing depth and relative vertical clinical attachment level decreased significantly. In both groups, changes in gingival recession was not significant. The control group had a mean probing depth decrease of  $2.67 \pm 0.87$  mm, whereas the test group had a mean probing depth reduction of  $3.22 \pm 1.56$  mm ( $p = 0.001$ ). In the control and test groups, the mean relative vertical clinical attachment level increases were  $1.57 \pm 0.96$  mm ( $p = 0.001$ ) and  $1.65 \pm 1.24$  mm ( $p = 0.004$ ), respectively. The relative horizontal clinical attachment level in the test group decreased from  $5.87 \pm 0.96$  mm to  $4.58 \pm 1.02$  mm ( $p = 0.02$ ). Six months after surgery, no significant changes in the clinical indicators were found between the two groups. In the regeneration of grade II furcation involvement of human mandibular molars, [Lafzi et al. \(2013\)](#) compared the clinical outcomes achieved by combining autogenous bone grafts (ABG) and plasma rich in growth factors (PRGF) with those obtained by ABG. To infuse growth factors into the bone in the combination group, autogenous bone chips were immersed in the prepared PRGF. Both intra-group differences were statistically significant ( $p = 0.001$ ), however the intergroup differences at 6 months were not significant ( $p = 0.68$ ). Treatments with ABG along with PRGF and ABG alone resulted in probing depth reductions of 2.33 mm and 2.64 mm, respectively, indicating that both treatments were successful in reducing probing depths.

Mixture of Nanocrystalline hydroxyapatite (NcHA) and platelet rich fibrin (PRF) was compared with NcHA alone by [Attia \(2016\)](#) and [Edrees et al. \(2019\)](#) in treatment of class II furcation defects where they found that the PRF in conjunction with the NcHA bone graft demonstrated clinical benefits that were greater than those achieved by the NcHA alone at 12 months' follow-up. Furthermore, PRF's adjunctive impact has been found to be a promising and effective therapy for class II furcation defects.

The use of Novabone putty and PRF membrane by [Joseph \(2016\)](#) resulted in a considerable reduction in probing pocket depth from 6.00 mm to 3.00 mm, as well as a significant gain in clinical attachment level from 6.11 mm at baseline to 4.00 mm at 6 months. The results of a study by [Chang and Zhao \(2011\)](#) revealed that Platelet rich fibrin increases the extracellular signal related protein kinase (p-ERK), osteoprotegerin (OPG) and alkaline phosphatase activity (ALP). They have concluded that p-ERK, OPG and ALP expression by Platelet rich fibrin provides benefits for periodontal regeneration

and the application of Platelet rich fibrin in intrabony defects showed significant clinical and radiographic improvement suggesting the use of Platelet rich fibrin as an effective treatment modality for periodontal intrabony defects.

In a study arm of the systematic review by [Reynolds et al. \(2003\)](#), comparing bone graft alone to bone graft with ePTFE barrier for the treatment of mandibular furcation defects, following observations were made: mean horizontal furcation defect fill ranged from 1.1 mm to 3.3 mm for combination therapy and from 1.0 mm to 1.8 mm for grafting alone.

[Lohi et al. \(2017\)](#) reported statistically significant reduction in PD, CAL, vertical defect fill was observed in test group (Bioactive Ceramic Composite Granules i.e BCCG + PRF mixture and PRF membrane) when compared to control group (BCCG alone) at six months. In the test and control groups, the percentage of vertical defects filled was 40.68% and 20%, respectively. In the test and control groups, the percentage of horizontal defects filled was 47.06% and 24.44%, respectively. In addition, a comparison between the two groups at six months later showed a significant increase in radiographic bone density at the defect at the furcation. Both groups ( $\beta$ -TCP in conjunction with PRF- Group I and  $\beta$ -TCP alone- Group II in treatment of grade II furcation defects) demonstrated statistically significant results from their baseline value for all measurements at 6 months, while intergroup variations were statistically insignificant in a study by [Rani et al. \(2018\)](#). The increase in CAL was  $2.80 \pm 1.40$  mm in Group I and  $3.00 \pm 1.44$  mm in Group II. VDD ( $3.50 \pm 2.12$  mm) and HDD ( $3.70 \pm 0.67$  mm) were found in Group I, whereas VDD ( $3.70 \pm 1.57$  mm) and HDD ( $4.0 \pm 0.88$  mm) were found in Group II. For reduction of PD Group I ( $3.50 \pm 2.27$  mm) had a better score than Group II ( $2.80 \pm 1.93$  mm). When GR was established at reentry, Group I had a greater GR ( $0.70 \pm 0.67$  mm) while Group II had a lower GR ( $0.70 \pm 0.67$  mm) than Group I.

In a study by [Dhambare et al. \(2019\)](#) both the test (Hydroxyapatite i.e HA and Beta tricalcium phosphate i.e  $\beta$ -TCP + PRF (wherein one part of PRF was mixed with  $\beta$ -TCP and the other part served as a membrane to the same) and control (HA and  $\beta$ -TCP) groups showed significantly greater mean PD reduction of  $2.0 \pm 0.73$  mm and  $0.50 \pm 0.52$  mm respectively at 12 months compared to baseline. However, there was no statistically significant difference between the test and control groups when it came to gingival recession ( $0.34 \pm 1.43$  mm). Due to discrepancies in follow-up lengths and the use of two bone graft materials in the control group, the study by [Dhambare et al. \(2019\)](#) was excluded from the meta-analysis.

As per [Basireddy et al. \(2019\)](#) there was a statistically significant difference in HCAL ( $<0.001$ ) and Gingival marginal level (0.014) in the intergroup comparison of mean change in the parameters, but no significant difference in the other parameters and so according they concluded PRF used as a membrane appears to favour soft-tissue healing while providing no further advantage in bone regeneration when combined with DFDBA.

In the recent clinical trial by [Serroni et al. \(2021\)](#) added benefit of L-PRF to autogenous bone grafts was evaluated in the treatment of degree II furcation involvement in mandibular molars where they found that GR changes showed no significant differences within groups, but statistically significant improvements in HCAL, VCAL, PD, and vertical bone loss



(VBL) were seen in all groups, with the exception of VBL in the OFD group. L-PRF was divided into fragments and combined with autogenous bone and was also used as a membrane to cover the defects. The ABG + L-PRF group had a mean HCALgain of  $2.29 \pm 0.18$  mm in at 6 months, which was considerably higher than the ABG ( $1.61 \pm 0.18$  mm) group. Both ABG + L-PRF and ABG treatments improved clinical and radiographic outcomes much more than Open flap debridement (OFD) alone.

Due to the small number of investigations, the asymmetry analysis was not carried out. It should also be acknowledged that research on patient-centered outcome assessments is scarce.

## 6. Conclusion

The addition of autologous platelet concentrates to bone grafts may enhance clinical parameters (HCAL, VCAL, PD) in the treatment of mandibular grade II furcation defects, within the constraints of the study. Despite the high heterogeneity of reported studies and the small effect size, no definitive conclusion about the added benefit of PC to BG in bone regeneration could be reached. However, PCs appear to improve healing characteristics, reduce probing pocket depth, and result in clinical attachment gain to a certain level as an added benefit to bone grafting. Nonetheless, more randomised controlled studies with longer follow-ups would be able to assess the therapeutic effectiveness of PCs when added to BG for clinical and radiographic evaluation of a three dimensional bone fill in grade II furcation defects.

## 7. Clinical relevance

The widespread use of autologous platelet concentrates to enhance the regenerative capacities of the periodontal tissues has necessitated the assessment of the available evidence in terms of the published data with regards to their efficacy in the treatment of Grade II furcation defects when used in combination with bone grafts. The principal findings based on the existing literature indicates that platelet concentrates lead to a substantial reduction in PPD and gain in clinical attachment levels. However, the influence of platelet concentrates in enhancing the bone regeneration is still not predictable and needs further examinations.

### Ethical statement

The systematic review has been registered in PROSPERO and has been mentioned in the title page.

The review was conducted as per PRISMA guidelines with detailed information given in the manuscript and as Fig. 1.

### Conflict of Interest Statement

The authors declare no conflicts of interest.

### CRedit authorship contribution statement

**Vinisha Ashok Bajaj:** Conceptualization, Data curation, Formal analysis, Investigation, Methodology, Project administra-

tion, Writing – original draft. **Abhay Pandurang Kolte:** Conceptualization, Data curation, Formal analysis, Project administration, Supervision, Validation, Writing – original draft. **Rajashri Abhay Kolte:** Formal analysis, Project administration, Supervision, Validation.

### Acknowledgement

None.

### References

- Agarwal, A., Manjunath, R.G.S., Sethi, P., Shankar, G.S., 2019. Platelet-rich fibrin in combination with decalcified freeze-dried bone allograft for the management of mandibular degree II furcation defect: A randomised controlled clinical trial. *Singapore Dent. J.* 39 (1), 33–40. <https://doi.org/10.1142/S2214607519500032>.
- Attia, A.M., 2016. Platelet rich fibrin and nanocrystalline hydroxyapatite in treatment of periodontal class II furcation defects: clinical and radiographic study. *E.D.J.* 61, 5049–5063.
- Basireddy, A., Prathypaty, S.K., Yendluri, D.B., Potharaju, S.P., 2019. May–June). Demineralized freeze-dried bone allograft with or without platelet-rich fibrin in the treatment of mandibular Degree II furcation defects: A clinical and cone beam computed tomography study. *J. Indian Soc. Periodontol.* 23 (3), 242–248. [https://doi.org/10.4103/jisp.jisp\\_465\\_18](https://doi.org/10.4103/jisp.jisp_465_18).
- Chang, Y.C., Zhao, J.H., 2011. Effects of platelet-rich fibrin on human periodontal ligament fibroblasts and application for periodontal infrabony defects. *Aust. Dent. J.* 56 (4), 365–371. <https://doi.org/10.1111/j.1834-7819.2011.01362.x>.
- Creeper, F., Lichanska, A.M., Marshall, R.I., Seymour, G.J., Ivanovski, S., 2009. The effect of platelet-rich plasma on osteoblast and periodontal ligament cell migration, proliferation and differentiation. *J. Periodontal. Res.* 44 (2), 258–265. <https://doi.org/10.1111/j.1600-0765.2008.01125.x>.
- Dambhare, A., Bhongade, M.L., Dhadse, P.V., Sehdev, B., Ganji, K. K., Thakare, K., Murakami, H., Sugita, Y., Maeda, H., Alam, M. K., 2019. A randomized controlled clinical study of autologous platelet rich fibrin (PRF) in combination with HA and beta-TCP or HA and beta-TCP alone for treatment of furcation defects. *J. Hard Tissue Biol.* 28 (2), 185–190. <https://doi.org/10.2485/jhtb.28.185>.
- Edrees, M., Maher, M., Hassan, K., 2019. Platelet rich fibrin combined with nanocrystalline Hydroxyapatite in treatment of Grade II mandibular furcation defect. *Al-Azhar Assiut. Dent. J.* 2 (1), 85–91.
- Giannobile, W.V., 1996. Periodontal tissue engineering by growth factors. *Bone* 19 (1, Suppl), 23S–37S. [https://doi.org/10.1016/s8756-3282\(96\)00127-5](https://doi.org/10.1016/s8756-3282(96)00127-5).
- Hamzacebi, B., Oduncuoglu, B., Alaaddinoglu, E.E., 2015. Treatment of Peri-implant Bone Defects with Platelet-Rich Fibrin. *Int. J. Periodontics Restorative Dent.* 35 (3), 415–422. <https://doi.org/10.11607/prd.1861>. PMID: 25909530.
- Higgins, J.P., Altman, D.G., Gotzsche, P.C., Jüni, P., Moher, D., Oxman, A.D., Savovic, J., Schulz, K.F., Weeks, L., Sterne, J.A., Cochrane Bias Methods Group, & Cochrane Statistical Methods Group, 2011. The Cochrane Collaboration's tool for assessing risk of bias in randomised trials. *BMJ* 343,. <https://doi.org/10.1136/bmj.d5928> d5928.
- Joseph, A., 2016. Clinical and Radiological Evaluation of Novabone Putty with PRF Membrane for the Treatment of Grade II Furcation Involvement: A Randomized Controlled Trial. Retrieved from [http://repository-tnmgrmu.ac.in/5151/1/240219616ajesh\\_joseph.pdf](http://repository-tnmgrmu.ac.in/5151/1/240219616ajesh_joseph.pdf).
- Lafzi, A., Shirmohammadi, A., Faramarzi, M., Jabali, S., Shayan, A., 2013. winter). Clinical comparison of autogenous bone graft with and without plasma rich in growth factors in the treatment of Grade II furcation involvement of mandibular molars. *J. Dent.*

- Res., Dent. Clinics, Dent. Prospects 7 (1), 22–29. <https://doi.org/10.5681/joddd.2013.004>.
- Liberati, A., Altman, D.G., Tetzlaff, J., Mulrow, C., Gøtzsche, P.C., Ioannidis, J.P., Clarke, M., Devereaux, P.J., Kleijnen, J., Moher, D., 2009 October. The PRISMA statement for reporting systematic reviews and meta-analyses of studies that evaluate health care interventions: Explanation and elaboration. *J. Clin. Epidemiol.* 62 (10), e1–e34. <https://doi.org/10.1016/j.jclinepi.2009.06.006>.
- Lohi, H.S., Nayak, D.G., Uppoor, A.S., 2017. Comparative evaluation of the efficacy of bioactive ceramic composite granules alone and in combination with platelet rich fibrin in the treatment of mandibular Class II furcation defects: A clinical and radiographic study. *J. Clin. Diagn. Res.* 11 (7), ZC76–ZC80. <https://doi.org/10.7860/JCDR/2017/23113.10255>.
- Mansouri, S.S., Ghasemi, M., Darmian, S.S., Pourseyediyani, T., 2012. winter). Treatment of mandibular molar Class II furcation defects in humans with bovine porous bone mineral in combination with plasma rich in growth factors. *J. Dent.* 9 (1), 41–49. PubMed: 22924101.
- Mellonig, J.T., Bowers, G.M., Bright, R.W., Lawrence, J.J., 1976. Clinical evaluation of freeze-dried bone allografts in periodontal osseous defects. *J. Periodontol.* 47 (3), 125–131. <https://doi.org/10.1902/jop.1976.47.3.125>.
- Nikolidakis, D., Jansen, J.A., 2008. The biology of platelet-rich plasma and its application in oral surgery: Literature review. *Tissue Eng. Part B, Rev.* 14 (3), 249–258. <https://doi.org/10.1089/ten.teb.2008.0062>.
- Rani, N., Kaushal, S., Singh, S., Nandlal, K.M.A., Khan, M.A., Pathak, A.K., 2018. Evaluation of the relative efficacy of autologous platelet-rich fibrin membrane in combination with  $\beta$ -tricalcium phosphate (septodont-resorbable tissue replacement)<sup>TM</sup> alloplast versus  $\beta$ -TCP alloplast alone in the treatment of grade II furcation defects. *National J. Maxillofac. Surg.* 9 (2), 196–204. [https://doi.org/10.4103/njms.NJMS\\_68\\_17](https://doi.org/10.4103/njms.NJMS_68_17).
- Reynolds, M.A., Aichelmann-Reidy, M.E., Branch-Mays, G.L., Gunsolley, J.C., 2003. The efficacy of bone replacement grafts in the treatment of periodontal osseous defects. A systematic review. *Ann. Periodontol.* 8 (1), 227–265. <https://doi.org/10.1902/annals.2003.8.1.227>.
- Serroni, M., Paolantonio, M., Romano, L., Santamaria, P., Rexhepi, I., Sinjari, B., Paolantonio, G., Secondi, L., De Ninis, P., Femminella, B., 2021. Added benefit of L-PRF to autogenous bone grafts in the treatment of degree II furcation involvement in mandibular molars. *J. Periodontol.* <https://doi.org/10.1002/JPER.21-0369>.
- Swami, R.K., Kolte, A.P., Bodhare, G.H., Kolte, R.A., 2021. Bone replacement grafts with guided tissue regeneration in treatment of grade II furcation defects: A systematic review and meta-analysis. *Clin. Oral Investig.* 25 (3), 807–821. <https://doi.org/10.1007/s00784-021-03776-0>.
- Tarallo, F., Mancini, L., Pitzurra, L., Bizzarro, S., Tepedino, M., Marchetti, E., 2020. Use of platelet-rich fibrin in the treatment of Grade 2 furcation defects: Systematic review and meta-analysis. *J. Clin. Med.* 9 (7), 2104. <https://doi.org/10.3390/jcm9072104>.