

# Intraoperative Neuromonitoring During Periacetabular Osteotomy Provides Actionable Alerts

Lukas G. Keil, MD, James D. Bomar, MPH, Carolyn R. Bower, AUD, CNIM, BCS-IOM,  
Melanie H. Venne, AUD, CNIM, BCS-IOM, Patrick F. Curran, MD, and Vidyadhar V. Upasani, MD, FAOA

*Investigation performed at Rady Children's Hospital, San Diego, California*

**Background:** Bernese periacetabular osteotomy (PAO) for symptomatic acetabular dysplasia and femoroacetabular impingement has become increasingly common, with a corresponding increase in the incidence of adverse outcomes. The rate of major neurological injury (excluding lateral femoral cutaneous nerve injury) during PAO has been reported to be around 2%. Previous publications have recommended the use of intraoperative neuromonitoring (IONM) to mitigate risk of major neurological injury during PAO, but its use has not become universal among PAO surgeons as it has among spine surgeons. The purpose of this study was to report the incidence and clinical significance of IONM alerts in a single-surgeon, consecutive cohort of patients treated with Bernese PAO.

**Methods:** After a permanent peripheral nerve injury during a PAO without IONM, IONM has been used at our institution in every PAO. Motor evoked potentials and somatosensory monitoring are performed throughout the procedure. We conducted a retrospective review of all PAOs performed after this practice change between 2017 and 2023. Medical records were reviewed for all IONM alerts, surgical team responses to alerts, and postoperative neurological status.

**Results:** All 94 PAOs performed with IONM in 82 patients during the study period were included. The mean age was 19 years (range 11-38). Significant IONM alerts occurred in 10 of 94 PAOs (11%) in 10 patients. Of these 10 alerts, 6 resulted in action taken by the surgical team including adjustment of acetabular fragment correction, leg repositioning, or stockinette or boot loosening. The remaining 4 alerts were due to anesthetic or systemic causes or technical issues with the neuromonitoring electrodes. No patients had a detectable neurological deficit postoperatively.

**Conclusions:** IONM may produce alerts in approximately 1 in 9 periacetabular osteotomies. These alerts are actionable and may improve patient safety and minimize the non-negligible risk of major nerve injury. This study provides additional evidence to support the utility of IONM in PAO.

**Level of Evidence:** Level III—retrospective cohort study. See Instructions for Authors for a complete description of levels of evidence.

## Take Home Points

11% of our cohort had significant IONM alerts.

IONM alerts led to action taken by the surgical team including adjustment of the acetabular fragment, limb repositioning, and bandage/traction boot loosening.

IONM alerts might have prevented nerve injuries in 2% of our study cohort.

## Introduction

Bernese periacetabular osteotomy (PAO) for symptomatic acetabular dysplasia and femoroacetabular impingement

has become increasingly common, with a corresponding increase in the incidence of adverse outcomes<sup>1</sup>. The rate of major neurological injury (excluding lateral femoral cutaneous nerve injury) during PAO has been reported to be between 0% and 15%, with the best estimate of major nerve injury of approximately 2%<sup>2-5</sup>. Pioneers of hip preservation have recommended the use of intraoperative neuromonitoring (IONM) to mitigate risk of major neurological injury during PAO and other major hip surgery for 30 years<sup>6-8</sup>. While Ganz has reported not using IONM in his practice, he has also specifically noted the potential utility of IONM in preventing traction nerve injuries during

**Disclosure:** The **Disclosure of Potential Conflicts of Interest** forms are provided with the online version of the article (<http://links.lww.com/JBJSOA/A747>).

Copyright © 2025 The Authors. Published by The Journal of Bone and Joint Surgery, Incorporated. All rights reserved. This is an open access article distributed under the terms of the [Creative Commons Attribution-Non Commercial-No Derivatives License 4.0](https://creativecommons.org/licenses/by-nc-nd/4.0/) (CCBY-NC-ND), where it is permissible to download and share the work provided it is properly cited. The work cannot be changed in any way or used commercially without permission from the journal.

revision PAO<sup>9</sup>. Soto et al.<sup>10</sup> described a readily reproducible technique for IONM during PAO without sacrificing sterility or mobility of the leg. Novais et al. noted multimodal IONM changes in the sciatic nerve in 15% of PAOs and used these to identify key steps at risk of causing nerve injury including retractor placement, osteotomies, acetabular fragment manipulation, and fixation. Of note, Novais et al.<sup>11</sup> did not advocate for routine use of IONM in this article. The alert rate in their series is comparable with rates of IONM alerts reported during spinal deformity surgery<sup>12</sup>, but use of IONM has not become universal among PAO surgeons as it has among spine surgeons.

In 2017, a patient with a history of previous pelvic osteotomy and overcoverage underwent reverse PAO without IONM and suffered a permanent sciatic nerve injury. Exploration showed that the nerve was in continuity with a suspected traction injury because of acetabular fragment correction. Before this event, the senior author had performed 38 PAOs in practice. Since then, IONM has been used at our institution in every PAO. The purpose of this study was to report the incidence and clinical significance of IONM alerts in a single-surgeon, consecutive cohort of patients treated with Bernese PAO.

## Materials and Methods

### Study Design

After institutional review board approval, a single-center, retrospective review was performed between 2017 and 2023. This retrospective cohort study was conducted in accordance with Strengthening the Reporting of Observational Studies in Epidemiology guidelines<sup>13</sup>. All PAOs performed for any diagnosis at any age were included. We excluded hip surgeries other than Bernese PAO performed with the use of IONM during the study period (triple innominate osteotomy, surgical hip dislocation, acetabular fracture dislocation, and conversion total hip arthroplasty). Medical records were reviewed for patient demographics, concomitant procedures, IONM alerts, surgical team responses to alerts, and postoperative neurological status. Basic descriptive statistics are reported.

### Neuromonitoring Technique

The IONM technique used in this series is similar to that described by Soto et al.<sup>10</sup> and Novais et al.<sup>11</sup>, with slight differences. All patients were monitored with transcranial motor evoked potentials (TcMEPs), somatosensory evoked potentials (SSEPs), and electromyography (EMG) throughout the operation. Two- or 4-channel electroencephalogram was recorded to monitor anesthetic depth. A Medtronic Eclipse acquisition system was used (Program version 4.2.423). Volatile anesthetics were typically used as total intravenous anesthesia is not standard at our institution for spinal deformity surgery with use of IONM. Use of volatile anesthetics in conjunction with IONM is controversial<sup>14,15</sup>. Intraoperative hypotension beyond that normally caused by anesthesia was not routinely used to minimize blood loss. Nondepolarizing neuromuscular blocking agents were not routinely used in this cohort to facilitate exposure. Four patients received rocuronium at the time of induction, and one additional patient received rocuronium 40 minutes after in-

duction. Skeletal muscle relaxation was confirmed to have worn off (via train-of-4) or was reversed before performing osteotomies.

After induction, IONM leads were placed in bilateral upper extremities and the contralateral lower extremity. Satisfactory baseline tracings were confirmed, and anesthetic technique was adjusted if needed. Two approaches were used for placement of IONM leads in the operative extremity depending on the need for traction boots for concomitant arthroscopy. If no traction was needed, then after positioning, prepping, and draping, IONM leads were placed sterilely in the operative extremity at symmetric locations previously marked with indelible ink before prep and secured with adhesive incised drape. The leg was then covered with an impervious stockinette and cohesive bandage, with wires passed through the cut end of the stockinette and off the field (Fig. 1). If traction was needed, leads were placed in an unsterile fashion before traction boot placement and then the boot and leads were draped out of the surgical field (Fig. 2). Of note, it is also possible to place the leads described below proximal to the traction boot to avoid spurious alerts from transient tissue hypoxia caused by compression in the boot.

TcMEP stimulating electrodes were placed in a quadripolar manner, overlying the motor cortex at scalp sites denoted C1, C2, C3, and C4. Trains of 10 stimulus, with a pulse duration of 75  $\mu$ sec and a train rate of 333 per second, were used with stimulation intensities ranging from 200 to 600 V. The time base for recording was set at 10 ms/division. The low frequency filter was set to 30 Hz, and the high frequency filter to 1,500 Hz. Subdermal needle electrodes for EMG and TcMEP recordings were positioned in the bilateral quadriceps, tibialis anterior, gastrocnemius, extensor hallucis longus, and the abductor hallucis muscles. TcMEPs were acquired on direct notification from the surgeon. The criterion for alert was a 50% or greater reduction in TcMEP signal amplitude from the baseline recordings in any muscle group. SSEPs were elicited by stimulation of the posterior tibial nerve at the ankle. SSEP recording electrodes were positioned on the scalp at points denoted FPz, CPz, CP3, CP4, and Cv. Stimulus intensities used to elicit lower extremity SSEPs ranged from 40 to 60 mA. The repetition rates ranged from 1.33 to 2.79 stimulations per second, and the pulse width was set at 200  $\mu$ sec. The low frequency filters were set at 30 Hz, and the high frequency filters were set at 500 Hz. The amplifier input was set to 1,600  $\mu$ V. The recording time base was set at 10 ms/division. Throughout the surgical procedure, SSEPs were averaged continuously, except for times inhibited by electrocautery. Criteria for alert were a 50% or greater decrease in SSEP amplitude and/or a 10% or greater increase in latency. Spontaneous electromyography (sEMG) was recorded from the quadriceps, tibialis anterior, gastrocnemius, and extensor hallucis longus continuously throughout the surgical procedure, except for times inhibited by electrocautery and/or anesthetic components. The time base for sEMG was set to 500 ms/division. The low-frequency filter setting was 30 Hz, and the high-frequency filter setting was 1,500 Hz. The surgeon was notified of any continuous, repetitive EMG discharges and/or changes in waveform morphology. In the event of persistent neurotonic discharges, TcMEP stimulation was conducted.

### Surgical Technique

The surgical technique for Bernese PAO has been published widely with numerous variations and is not the focus of this study. An oblique incision distal to the iliac crest was made, and the Smith-Peterson interval was exploited. Adequate exposure was developed, and osteotomies of the superior pubic ramus, ischium, ilium, and posterior column were made sequentially. The acetabular fragment was manipulated using a Schanz pin and secured provisionally using three 2.4-mm K-wires ultimately replaced with 3.5-mm cortical screws. Of note, recommendations by Kalhor and Ganz et al. to prevent nerve injury including instrument selection, retractor placement, and leg positioning during osteotomies were routinely used in this series, apart from iliopsoas release performed in selected cases<sup>9</sup>.

### Results

#### Patient Characteristics

All 94 PAOs in 82 patients performed by the senior author during the study period were included, with IONM used in all cases. The mean age was 19 years (range 11-38). Seventy-seven PAOs were performed in females (82%), and 17 (18%) in males. Fifty-four PAOs were performed on the right (57%). Fifteen hips (16%) had undergone previous surgery. Concomitant procedures were performed in 59 hips (63%). These included labral repair or debridement in 38 hips (40%), arthroscopic osteochondroplasty in 9 hips (10%), open osteochondroplasty in 2 hips (2%), femoral osteotomy in 19 hips (20%), and open reduction and/or capsulorrhaphy in 5 hips (5%).

In the 14 PAOs performed in 2023, the mean time in the operating room was 282 minutes (range 200-488 minutes), the estimated blood loss was 486 mL (range 100-1,000 mL), and no allogeneic blood transfusions were administered perioperatively. No postoperative neurological deficits were observed.

#### Summary of Neuromonitoring Alerts

Significant IONM alerts occurred in 10 of 94 PAOs (11%) in 10 patients. Cases in which alerts occurred were distributed throughout the study period and did not meaningfully decrease in frequency over time. Of these 10 alerts, 6 resulted in action taken by the surgical team including adjustment of acetabular fragment correction (2), leg repositioning (2), or stockinette cohesive bandage or traction boot loosening (2). The remaining 4 alerts were due to anesthetic or systemic causes or technical issues with the neuromonitoring electrodes. IONM alerts were dispersed throughout the study period and did not become less common with increasing experience. No patients had a detectable neurological deficit postoperatively (excluding the lateral femoral cutaneous nerve).

#### Representative Cases

Two patients presented here highlight the utility of IONM in PAO. Both patients underwent PAO and had significant IONM alerts corresponding to divisions of the sciatic nerve, resulting in adjustment of acetabular fragment correction before final screw fixation (Figs. 3 and 4).

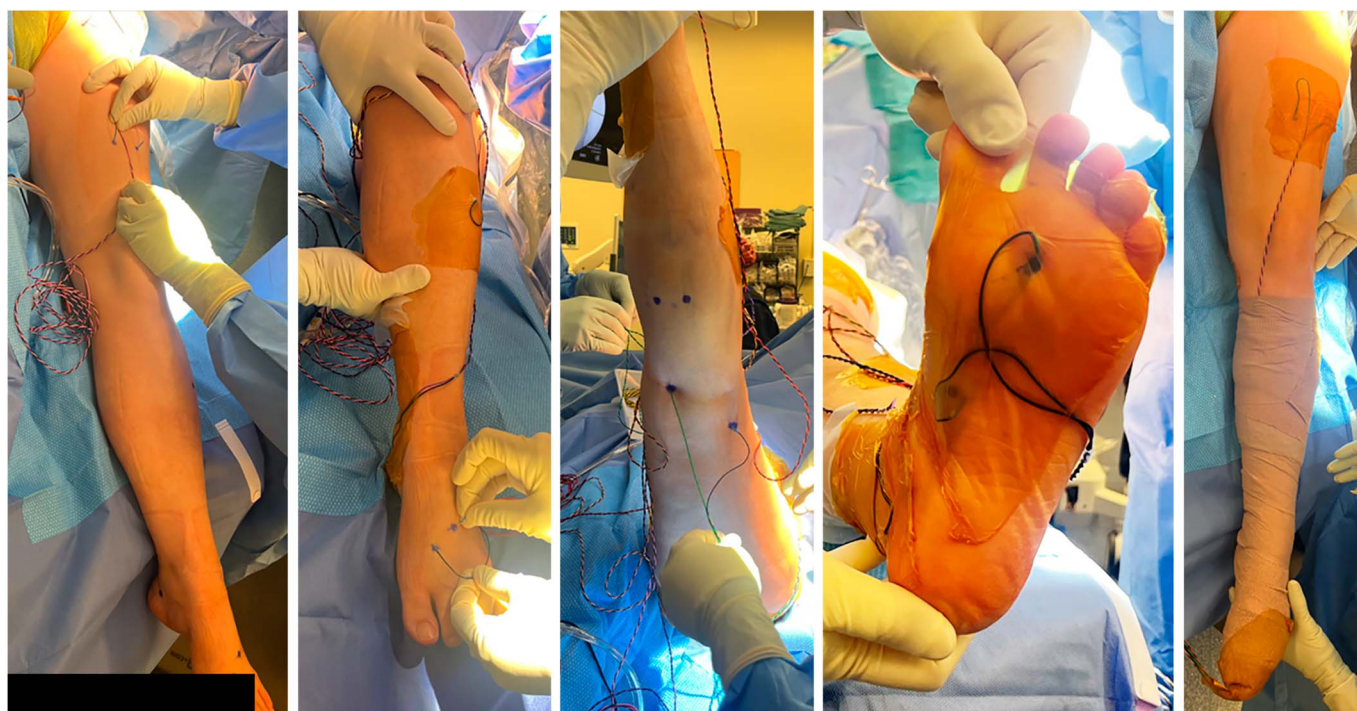


Fig. 1  
Sterile lead placement for neuromonitoring when a traction table was not used.



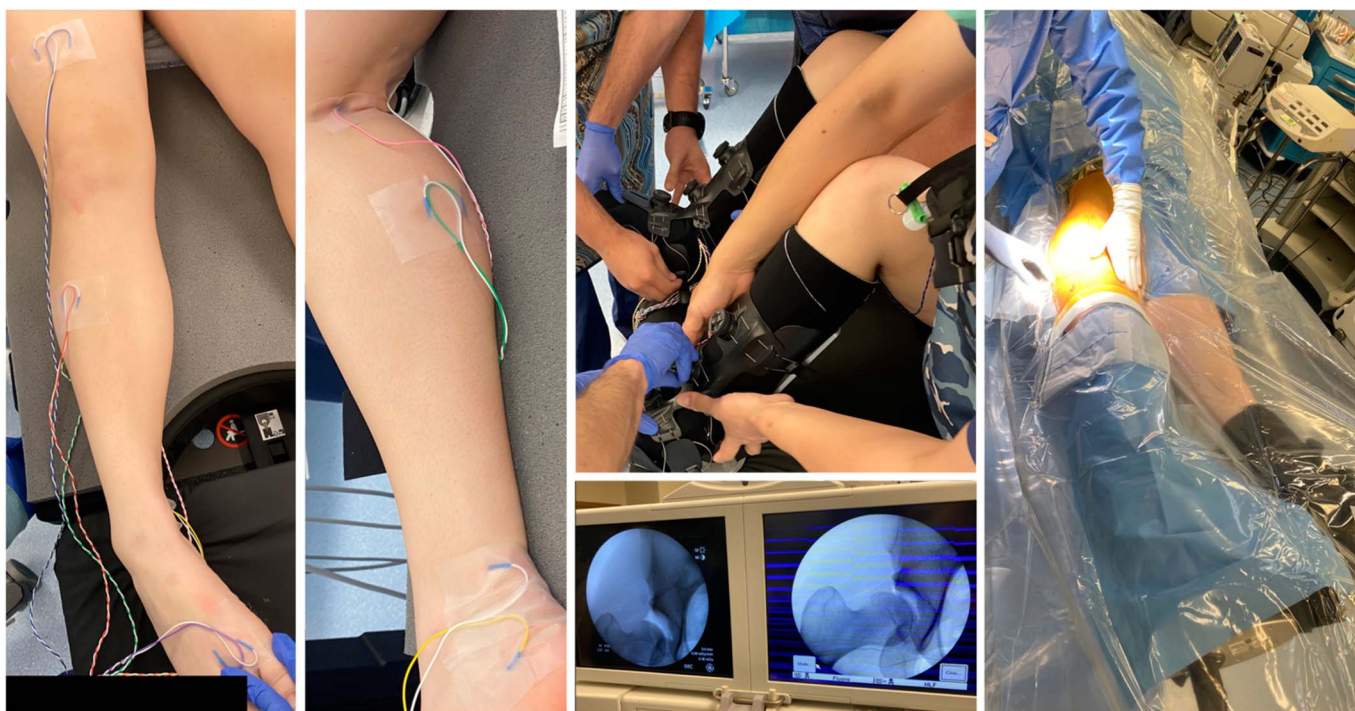

Fig. 2  
Unsterile lead placement for neuromonitoring when a traction table was used.

## Discussion

In this cohort of 94 periacetabular osteotomies, we found that IONM provided alerts in approximately 1 in 9 patients, often resulting in action taken by the surgical team with subsequent improvement in tracings. No patients in this cohort of 94 PAOs experienced a postoperative neurological deficit (excluding the lateral femoral cutaneous nerve). It can be argued that the effects of leg positioning or a tight traction boot will resolve after the case, with or without IONM. However, 2 patients had significant IONM alerts corresponding to divisions of the sciatic nerve (Figs. 1 and 2), resulting in adjustment of acetabular fragment correction before final screw fixation. It is plausible that if correction had not been adjusted, traction on the sciatic nerve might have produced a preventable postoperative neurological deficit in 2% of patients. This suggests that use of IONM might have spared 2% of patients in this cohort the same type of nerve injury that our patient suffered before this study.

Different types of nerve injuries may lead to less prominent instantaneous IONM changes (e.g., crush, laceration, traction). However, if nerve fibers are meaningfully compromised, one can reasonably expect decreases in TcMEP and/or SSEP signals, regardless of the mechanism.

Our study adds to the recommendations of numerous hip preservation surgeons over the past 3 decades, suggesting that IONM may improve safety in PAO<sup>6-9</sup>. Our technique is similar to what has been published previously by Soto et al.<sup>10</sup>, and we find that the additional cost and time required are offset by the added safety afforded to the patient. Our results are in

line with those in the study by Novais et al.<sup>11</sup>, showing that acetabular fragment manipulation is one of the highest risk portions of the procedure. Pring et al. reported that IONM during PAO is helpful in identifying nerve injuries but imperfect, with 5 of 7 immediate postoperative deficits identified intraoperatively. IONM did identify the only persistent neurological deficit in this cohort<sup>7</sup>. In addition, Haidukewych et al. reported no difference in rates of neurological injury during acetabular fracture surgery performed with and without IONM<sup>16</sup>. In our experience, IONM affords the surgeon peace of mind about sciatic and femoral nerve function during acetabular fragment manipulation, allowing undivided attention on mobilization of the fragment and obtaining the desired correction. It is reasonable to think that IONM may be of greatest utility early in a surgeon's PAO experience; however, we think that many surgeons who become accustomed to the IONM workflow and additional barrier to neurological injury may be disinclined to stop using IONM mid-career. It is also reasonable to consider IONM use for only PAOs with higher risk of nerve injury such as revision and reverse PAOs. However, we suggest that any surgeon considering IONM use become familiar with it in the primary PAO setting.

We would also like to highlight the contrast in IONM use between PAO surgeons and spinal deformity surgeons. The rate of major neurological injury (excluding lateral femoral cutaneous nerve injury) during PAO has been reported between 0% and 15%, with improvement as surgical technique has been refined<sup>2-5</sup>. We contend that major peripheral nerve injury and spinal nerve root injury are similarly debilitating, with either

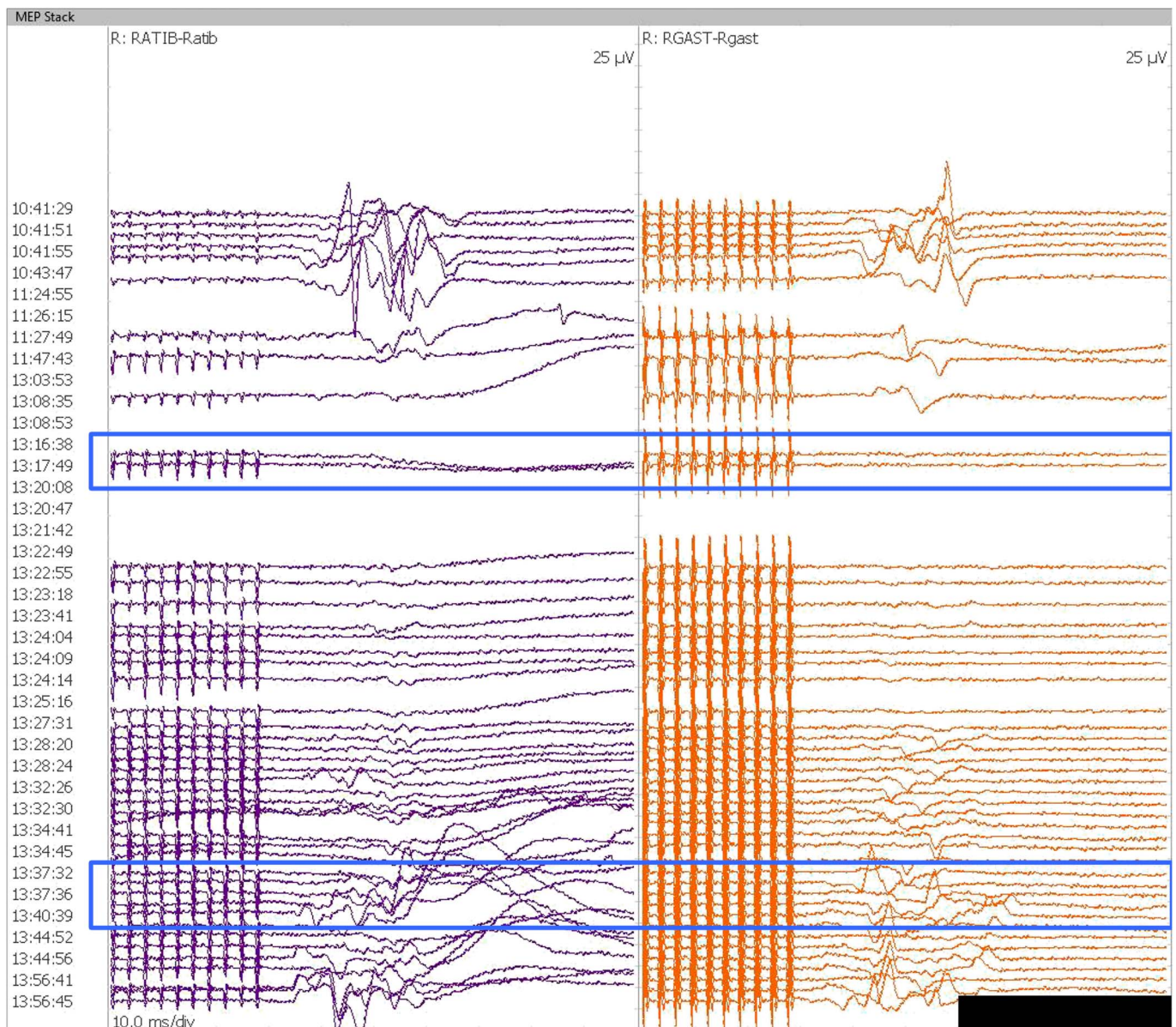


Fig. 3  
IONM tracings during right PAO with revision proximal femoral varus osteotomy in an 18-year-old female with Trisomy 21 and painful acetabular dysplasia with hip subluxation. During the acetabular fragment corrective maneuver, ipsilateral tibialis anterior and gastrocnemius TcMEPs were lost (13:15). Correction was adjusted, and TcMEPs returned to baseline (13:40). IONM = intraoperative neuromonitoring, PAO = periacetabular osteotomy, and TcMEPs = transcranial motor evoked potential.

being less debilitating than spinal cord injury. Of note, rates of sciatic or femoral nerve injury in PAO are comparable with rates of neurological injury reported after vertebral column resection, during which IONM is the standard of care<sup>17,18</sup>. In our series, 4 of 10 alerts could be considered “false positives,” but the same is true in spinal deformity surgery in which IONM is deemed worth some false positives and associated operative time. Postoperative neurological examination is the logical reference standard in PAO or spinal deformity, but this underestimates the utility of IONM. Its purpose is an “early

warning system” such that alerts lead to intraoperative interventions and resolution of IONM changes, in many cases obviating the need for a wake-up test and avoiding a postoperative deficit that would confirm the validity of the alert. A recent systematic review of IONM in spinal deformity surgery by Alvi et al. concluded that “all neuromonitoring modalities have diagnostic utility in successfully detecting impending or incident intraoperative neurologic injuries among patients undergoing spine surgery for any condition, although it is clear that the accuracy of each modality differs”<sup>19</sup>. Based on



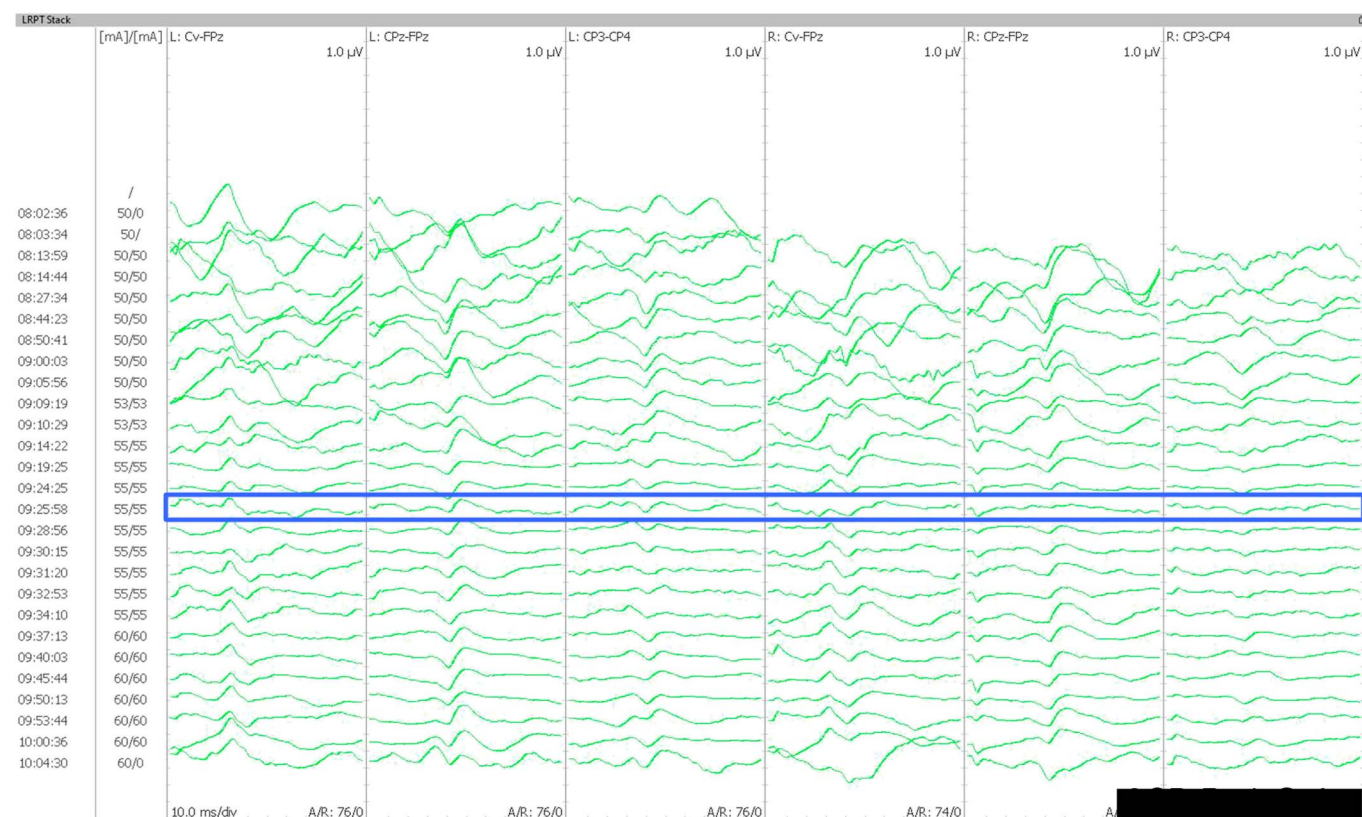


Fig. 4 IONM tracings during right PAO in an otherwise healthy 21-year-old female with painful acetabular dysplasia. After postinduction variability, baselines can be seen. During the acetabular fragment corrective maneuver, ipsilateral tibial nerve SSEPs showed a greater-than 50% decrease in amplitude (09:25). Correction was adjusted, and SSEPs returned to baseline. IONM = intraoperative neuromonitoring, PAO = periacetabular osteotomy, and SSEPs = somatosensory evoked potentials.

our results, we posit that the same is true for IONM in PAO. It is possible that early in the learning curve of IONM use in PAO, “false positives” may be more common. We recommend collaboration with an experienced neurophysiologist and open communication between the surgeon and the neurophysiologist to refine the IONM technique. As in spine surgery, the common causes of “false-positive” neuromonitoring findings need to be evaluated, including equipment failure of the electrodes and connections, anesthetic changes, limb position, or systemic considerations of hypotension or hypothermia.

This study has important limitations. It is a relatively small, retrospective case series from a single mid-career surgeon. Because of the design of this study as a cohort beginning after IONM was implemented, we do not have data regarding any overall increase in operative time. However, in our experience, the preoperative setup time is less than that for spinal deformity surgery and intraoperative time is not meaningfully increased. A prospective study of PAO with and without IONM comparing preparatory and operative time, blood loss, and complications is a necessary next step in research on this topic. These results may not be generalizable to all surgeons depending on PAO volume, technical details, and experience level. However, we think that these results may be particularly

important for surgeons early in their PAO learning curve, reported to be at least 40 cases and potentially lasting years depending on surgical volume<sup>20</sup>. In addition, differences in the IONM technique may produce different alert rates for the same case. We present our technique for surgeons and neurophysiologists wishing to implement IONM during PAO, but these teams may wish to adjust their technique as they gain experience working together. Finally, a cost-effectiveness analysis is beyond the scope of this study. However, in 2023, insurance approval was obtained for all patients, and no patient was charged more than \$325 coinsurance for IONM. The cost of consumables is absorbed by the neurophysiologist in our practice setting. The primary indirect cost associated with implementation is the up-front increase in operating room time to refine workflow, which is highly variable depending on the existing familiarity of the surgeon and team with IONM. We think that a necessary future study would weigh the personnel, training, time, and consumables required for IONM against the potential costs and morbidity of nerve injuries avoided.

In conclusion, Bernese PAO has become one of the most common major elective orthopedic surgeries in the United States, a trend that is likely to continue. IONM produces alerts in 1 in 9 PAOs. These alerts are often actionable and may

improve patient safety and minimize the non-negligible risk of major nerve injury. ■

Lukas G. Keil, MD<sup>1</sup>  
James D. Bomar, MPH<sup>1</sup>  
Carolyn R. Bower, AUD, CNIM, BCS-IOM<sup>2</sup>

Melanie H. Venne, AUD, CNIM, BCS-IOM<sup>2</sup>  
Patrick F. Curran, MD<sup>1</sup>  
Vidyadhar V. Upasani, MD, FAOA<sup>1</sup>

<sup>1</sup>Department of Orthopedics, Rady Children's Hospital, San Diego, California

<sup>2</sup>Neurodynamics, Inc., San Diego, California

E-mail address for V.V. Upasani: vupasani@rchsd.org

## References

- Basques BA, Lukasiewicz AM, Samuel AM, Webb ML, Bohl DD, Smith BG, Grauer JN. Which pediatric orthopaedic procedures have the greatest risk of adverse outcomes? *J Pediatr Orthop*. 2017;37(6):429-34.
- Siebenrock KA, Schöll E, Lottenbach M, Ganz R. Bernese periacetabular osteotomy. *Clin Orthop Relat Res*. 1999;363:9-20.
- Crockarell J Jr, Trousdale RT, Cabanela ME, Berry DJ. Early experience and results with the periacetabular osteotomy: the Mayo Clinic experience. *Clin Orthop Relat Res*. 1999;363:45-53.
- Clohisey JC, Schutz AL, St John L, Schoenecker PL, Wright RW. Periacetabular osteotomy: a systematic literature review. *Clin Orthop Relat Res*. 2009;467(8):2041-52.
- Sierra RJ, Beaulé P, Zaltz I, Millis MB, Clohisey JC, Trousdale RT, ANCHOR group. Prevention of nerve injury after periacetabular osteotomy. *Clin Orthop Relat Res*. 2012;470(8):2209-19.
- McGrory BJ, Trousdale RT. Sterile electromyographic monitoring during hip and pelvis surgery. *Orthop Rev*. 1994;23(3):274-6.
- Pring ME, Trousdale RT, Cabanela ME, Harper CM. Intraoperative electromyographic monitoring during periacetabular osteotomy. *Clin Orthop Relat Res*. 2002;400(400):158-64.
- Trousdale RT, Cabanela ME. Lessons learned after more than 250 periacetabular osteotomies. *Acta Orthop Scand*. 2003;74(2):119-26.
- Kalhor M, Collado D, Leunig IM, Rego P, Ganz R. Recommendations to reduce risk of nerve injury during bernese periacetabular osteotomy (PAO). *JBJS Essent Surg Tech*. 2017;7(4):e34.
- Soto A, Haidar LA, Crosby S, Orozco E, Mansour A 3rd. Technique for intraoperative neuromonitoring during periacetabular osteotomy after concomitant hip arthroscopy. *Arthrosc Tech*. 2020;9(11):e1825-e1829.
- Novais EN, Heare T, Kestel L, Oliver P, Boucharel W, Koerner J, Strupp K. Multimodal nerve monitoring during periacetabular osteotomy identifies surgical steps associated with risk of injury. *Int Orthop*. 2017;41(8):1543-51.
- Zuccaro M, Zuccaro J, Samdani AF, Pahys JM, Hwang SW. Intraoperative neuromonitoring alerts in a pediatric deformity center. *Neurosurg Focus*. 2017;43(4):E8.
- Von Elm E, Altman DG, Egger M, Pocock SJ, Gøtzsche PC, Vandenbroucke JP, STROBE Initiative. Strengthening the Reporting of Observational Studies in Epidemiology (STROBE) statement: guidelines for reporting observational studies. *BMJ*. 2007;335(7624):806-8.
- Deiner S. Highlights of anesthetic considerations for intraoperative neuromonitoring. *Semin Cardiothorac Vasc Anesth*. 2010;14(1):51-3.
- Gunter A, Ruskin KJ. Intraoperative neurophysiologic monitoring: utility and anesthetic implications. *Curr Opin Anaesthesiol*. 2016;29(5):539-43.
- Haidukewych GJ, Scaduto J, Herscovici D Jr, Sanders RW, DiPasquale T. Iatrogenic nerve injury in acetabular fracture surgery: a comparison of monitored and unmonitored procedures. *J Orthop Trauma*. 2002;16(5):297-301.
- Xie JM, Zhang Y, Wang YS, Bi N, Zhao Z, Li T, Yang H. The risk factors of neurologic deficits of one-stage posterior vertebral column resection for patients with severe and rigid spinal deformities. *Eur Spine J*. 2014;23(1):149-56.
- Yang C, Zheng Z, Liu H, Wang J, Kim YJ, Cho S. Posterior vertebral column resection in spinal deformity: a systematic review. *Eur Spine J*. 2016;25(8):2368-75.
- Alvi MA, Kwon BK, Hejrati N, Tetreault LA, Evaniew N, Skelly AC, Fehlings MG. Accuracy of intraoperative neuromonitoring in the diagnosis of intraoperative neurological decline in the setting of spinal surgery—a systematic review and meta-analysis. *Glob Spine J*. 2024;14(3 suppl):105S-149S.
- Novais EN, Carry PM, Kestel LA, Ketterman B, Brusalis CM, Sankar WN. Does surgeon experience impact the risk of complications after bernese periacetabular osteotomy? *Clin Orthop Relat Res*. 2017;475(4):1110-7.