

ORIGINAL ARTICLE

# An *in vitro* study on the efficacy of removing calcium hydroxide from curved root canal systems in root canal therapy

Ying Wang<sup>1,2,\*</sup>, Li-Yang Guo<sup>1,\*</sup>, Hong-Zhi Fang<sup>3</sup>, Wen-Ling Zou<sup>1</sup>, Ying-Ming Yang<sup>4</sup>, Yuan Gao<sup>1</sup>, Hui Yang<sup>5</sup> and Tao Hu<sup>1,4</sup>

To compare the efficacy of various irrigants (citric acid, ethylenediaminetetraacetic acid (EDTA) and NaOCl) and techniques in removing Ca(OH)<sub>2</sub> in two types of curved root canal systems, simulated root canals with specific curvatures were used to investigate the effects of different irrigants and instruments on Ca(OH)<sub>2</sub> removal. The optimal methods were verified on extracted human teeth. Simulated root canals were assigned to one of two groups based on the irrigation solution: 10% citric acid or 2.5% NaOCl. Each group was divided into four subgroups according to the technique used to remove Ca(OH)<sub>2</sub>. The percentage of Ca(OH)<sub>2</sub> removal in different sections of root canals was calculated. On the basis of the results obtained for the simulated canals, 10% citric acid and 17% EDTA were applied to remove Ca(OH)<sub>2</sub> from the extracted human teeth with curved root canal systems. The teeth were scanned by micro computed tomography to calculate the percentage of Ca(OH)<sub>2</sub> removal in the canals. In simulated root canals, we found that 10% citric acid removed more Ca(OH)<sub>2</sub> than 2.5% NaOCl in the 0–1 mm group from the apex level ( $P < 0.05$ ). Ultrasonic and EndoActivator activation significantly removed more Ca(OH)<sub>2</sub> than a size 30 K file in the apical third ( $P < 0.05$ ). However, there were no significant differences in any sections of the canals for 10% citric acid or 17% EDTA in removing Ca(OH)<sub>2</sub> in extracted human teeth. We concluded that it was effective to remove residual Ca(OH)<sub>2</sub> using the decalcifying solution with EndoActivator or Passive Ultrasonic Irrigation in a curved root canal system. A protocol for Ca(OH)<sub>2</sub> removal was provided based on the conclusions of this study and the methods recommended in previous studies.

*International Journal of Oral Science* (2017) 9, 110–116; doi:10.1038/ijos.2017.14; published online 23 June 2017

**Keywords:** calcium hydroxide; curved root canal system; irrigation; removal

## INTRODUCTION

Overwhelming evidence indicates that microorganisms have a fundamental role in the pathogenesis of periradicular diseases.<sup>1</sup> To eliminate the remaining microbes after root canal preparation and to prevent an interappointment reinfection of the root canal system, intracanal medications are recommended.<sup>2</sup> Calcium hydroxide [Ca(OH)<sub>2</sub>] has been widely used as an intracanal medication owing to its good antibacterial properties and biocompatibility.<sup>2</sup> However, some studies have indicated that Ca(OH)<sub>2</sub> inactivates endotoxin<sup>3</sup> and impedes the increase in cytokine chemical inflammatory mediators<sup>4–5</sup> to inhibit periapical inflammation after a root canal cleaning procedure.

The antibacterial effect of Ca(OH)<sub>2</sub> is most effective after direct contact with microorganisms.<sup>2,6</sup> Therefore, it is important to obtain a compact and homogenous filling of Ca(OH)<sub>2</sub> in the entire root canal system.<sup>6</sup> Before obturation, Ca(OH)<sub>2</sub> should be completely removed from the root canal system to avoid any possible negative influence on treatment. Residual Ca(OH)<sub>2</sub> might lead to apical leakage<sup>7</sup> and reduced sealer adaptation,<sup>8</sup> and might interact with zinc oxide eugenol<sup>9</sup> and decrease the dentin bond strength.<sup>10</sup> Therefore, any Ca(OH)<sub>2</sub> that is placed in the root canal system as an intracanal medication must be completely removed before root canal obturation.

The most frequently described method for removing Ca(OH)<sub>2</sub> from the root canal is the instrumentation of the root canal with the master

<sup>1</sup>State Key Laboratory of Oral Disease, National Clinical Research Center for Oral Diseases, West China Hospital of Stomatology, Sichuan University, Chengdu, China; <sup>2</sup>Department of Endodontics, The Affiliated Stomatology Hospital, School of Medicine, Zhejiang University, Hangzhou, China; <sup>3</sup>Department of Stomatology, The Third People's Hospital of Chengdu, Chengdu, China; <sup>4</sup>State Key Laboratory of Oral Disease, National Clinical Research Center for Oral Diseases, Department of Preventive Dentistry, West China Hospital of Stomatology, Sichuan University, Chengdu, China and <sup>5</sup>State Key Laboratory of Oral Disease, National Clinical Research Center for Oral Diseases, Department of General Dentistry, West China Hospital of Stomatology, Sichuan University, Chengdu, China

\*These authors contributed equally to this work.

Correspondence: Dr H Yang, State Key Laboratory of Oral Diseases, National Clinical Research Center for Oral Diseases, Department of General Dentistry, West China Hospital of Stomatology, Sichuan University, No. 14, 3rd Section, Renmin South Road, Chengdu 610041, China

E-mail: yanghui09@scu.edu.cn

Professor T Hu, State Key Laboratory of Oral Diseases, National Clinical Research Center for Oral Diseases, Department of Preventive Dentistry, West China Hospital of Stomatology, Sichuan University, No. 14, 3rd Section, Renmin South Road, Chengdu 610041, China

E-mail: hutao@scu.edu.cn

Accepted 28 March 2017

apical file in combination with copious irrigation.<sup>2,11</sup> Previous studies have investigated the efficacy of Ca(OH)<sub>2</sub> removal with different irrigants, equipment and techniques. Rödiger *et al.*<sup>12</sup> indicated that decalcifying solution, such as citric acid and ethylenediaminetetraacetic acid (EDTA), was significantly more effective than sodium hypochlorite and water. Decalcifying solutions in endodontics comprise chelators and acid.<sup>13</sup> Rotary instruments, the self-adjusting file system and high-efficiency irrigation systems, such as passive ultrasonic irrigation and the EndoVac system, were significantly more effective than conventional syringes.<sup>14–16</sup> However, none of these methods completely removed the Ca(OH)<sub>2</sub> intracanal medication. Although more techniques have been proposed to remove Ca(OH)<sub>2</sub>, an effective and systematic Ca(OH)<sub>2</sub> removal strategy is not available.

Most studies of Ca(OH)<sub>2</sub> removal have used extracted human teeth with straight root canals.<sup>12</sup> Some researchers have established artificial standardized grooves in root canal apices to study Ca(OH)<sub>2</sub> removal for irregular parts of the root canal system.<sup>14–16</sup> To evaluate the quantity of Ca(OH)<sub>2</sub> remaining after removal with various techniques in curved root canal systems, extracted human teeth with curved root canals with a certain range of curvature were selected in previous studies.<sup>17</sup> Because canal anatomy is one of the main confounding factors affecting the experimental results,<sup>18</sup> especially in complicated root canal systems, the experimental groups should be anatomically comparable to maintain a consistent baseline for the validity of experimental results. It is difficult for extracted human teeth to meet this condition as experimental specimens because of their heterogeneity. To research the shaping ability of rotary instruments in severely curved canals, Schäfer attempted to ensure standardization of the experimental groups by balancing them with respect to the root canal angle and the radius of canal curvature. The homogeneity of the groups was examined using statistical methods.<sup>19</sup> Simulated root canal models were proposed to create an undifferentiated experimental group in studies regarding a certain curvature. Some researchers used simulated root canals to mimic the actual curved canal system.<sup>20</sup> This *in vitro* model ensures standardization, provides a consistent baseline for each experimental group and avoids the confounding factors from root canal anatomy, such as the isthmus, length, curvature and radius. The curved root canal models used in previous studies offer a new choice to establish a more rational model for Ca(OH)<sub>2</sub> removal research in curved root canal systems.

The objective of the present study was to compare the efficacy of different irrigants (citric acid, EDTA and NaOCl) and techniques (rotary instrumentation, sonic and passive ultrasonic irrigation) in removing Ca(OH)<sub>2</sub> in two curved root canal models: simulated root canals and extracted human teeth.

## MATERIALS AND METHODS

### Sample preparation for simulated curved root canals

This experiment consisted of 20 simulated curved root canals (Endo Training Block; DentsplyMaillefer, Ballaigues, Switzerland) that were 16.5 mm long. The degree of curvature was 45.2°, and the radius of canal curvature was 6.1 mm, according to Schneider's method.<sup>21</sup> The canals were prepared to F3 (apical size 30 with a 0.09 taper) by the same operator using a ProTaperNiTi Rotary System (DentsplyMaillefer, Ballaigues, Switzerland) according to the manufacturer's instructions.<sup>22</sup> 5 mL of 2.5% NaOCl was used after each instrument, and 5 mL of distilled water was used as the final rinse. The simulated root canals were dried with paper points. The apical foramen was then filled with wax from the outside.<sup>22</sup> Canals were filled with Ca(OH)<sub>2</sub> paste (UltracalXSOptident, International) using a 30-gauge NaviTip (Ultradent products Inc., South

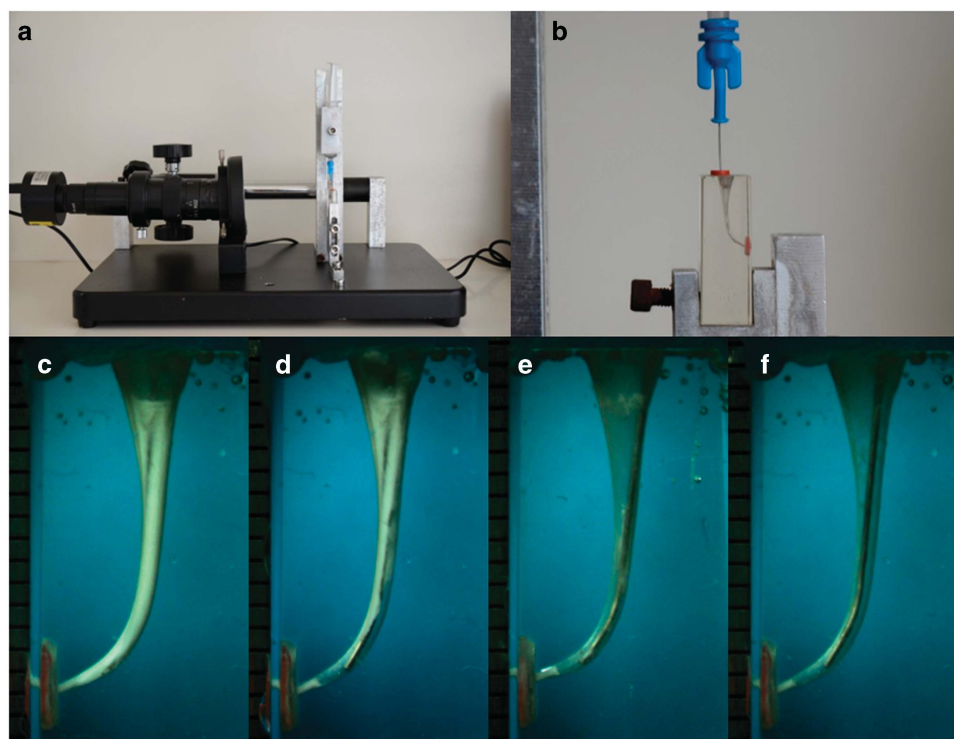
Jordan, UT, USA) starting from the apical aspect with the needle slowly advancing coronally until the paste was visualized at the canal orifice.<sup>6</sup> The access cavities were sealed with a cotton pellet and temporary filling material (GC corporation, Tokyo, Japan). The root canals were stored at 37 °C and 100% relative humidity for 7 days.

### Different irrigants and different instruments in calcium hydroxide removal in simulated curved root canals

Before the experiment, the temporary filling material was removed, and the Ca(OH)<sub>2</sub> in the simulated canals was loosened using a 15 K file. There were two experimental groups based on the irrigation solutions used to remove Ca(OH)<sub>2</sub>. In group 1, the canals were irrigated with 10% citric acid. In group 2, the canals were irrigated with 2.5% NaOCl. All canals were irrigated following a standardized protocol. The operating cycle included 5 mL of irrigant and different techniques, and the final rinse was performed after two operating cycles. A 30-gauge NaviTip (Ultradent) needle was used at a length that was 2 mm shorter than working length,<sup>17</sup> and the pressure applied to the plunger was standardized to 19.6 N using the device designed for this experiment (Figure 1a and 1b). Each group was divided into four subgroups according to the technique used to remove Ca(OH)<sub>2</sub>. In subgroup 1 ( $n=10$ ), canals were filed manually with a 30 K file in a circumferential filing action at working length for 10 s. In subgroup 2 ( $n=10$ ), canals were filed with a size F3 instrument with a rotating-lifting action at working length for 10 s. In subgroup 3 ( $n=10$ ), ultrasonic activation was delivered for 30 s with a stainless steel ultrasonic file 15/0.2 (Irri-Safe Satelec; Acteon Group, Merignac, France) mounted on a Suprasson P5 Booster ultrasonic unit (Satelec, Acteon Group, Merignac, France) with the power setting at 5.<sup>17</sup> In subgroup 4 ( $n=10$ ), sonic activation was delivered for 30 s between each irrigant using the EndoActivator (Advanced Endodontics, Santa Barbara, CA, USA) set at 10 000 cycles per minute with a 35/0.04 tip according to the manufacturer's instructions. The final rinse was performed with 3 mL of distilled water after two cycles of irrigation. The transparent blocks were covered with adhesive tape during the instrumentation phase. After ensuring that the residues in each root canal were adequately cleaned, the simulated root canals were reused. Each canal was reused three times.

### Efficacy of calcium hydroxide removal in simulated curved root canals

The Ca(OH)<sub>2</sub> removal process was recorded by a camcorder (ScopeTek DCM 310; ScopeTek, Hang Zhou, China) operated in macro mode (Figure 1a). A ring light was fixed on the camcorder to ensure the images were obtained with a standard light source. After the removal of Ca(OH)<sub>2</sub>, the images were obtained using a camcorder. The images were analysed using Image-Pro Plus 6.0 (Media Cybernetics, Rockville, MD, USA) on a laptop computer (HP, Palo Alto, CA, USA) with a 1366 × 768 screen pixel resolution to quantify the proportion of pixels for residual Ca(OH)<sub>2</sub> compared with the total area of the root canal wall. The software identified the residual area according to the different grey level between the residual area and the clear area. Then, the percentage of the Ca(OH)<sub>2</sub> removal area was calculated. The apical third was re-divided into three portions according to their distance from the apex: 0–1 mm, 1–3 mm and 3–5 mm. The percentage of Ca(OH)<sub>2</sub> removal in the apical, middle and coronary thirds together with the three portions in the apical part of the root canal was calculated. Two endodontists independently evaluated the images. When there were disagreements about the image, another endodontist was asked to perform a third evaluation to



**Figure 1** The experimental apparatus and operational process of Ca(OH)<sub>2</sub> removal. (a) The experimental set-up, including a camcorder and fixing device. (b) Simulated curved root canals and syringe needle. (c–f) Images after 0 mL, 5 mL, 10 mL and 15 mL of irrigation. Syringe needle inserted 2 mm from the apex. Between each 5-mL irrigation, different instruments were applied to remove Ca(OH)<sub>2</sub>.

**Table 1** Characteristics of curved root canals

Group	Curvature/°			Radius/mm		
	Mean ± s.d.	Maximum	Minimum	Mean ± s.d.	Maximum	Minimum
Group 1 (n=12)	34.61 ± 7.97	47.7	25.2	7.53 ± 2.27	10.1	3.5
Group 2 (n=12)	35.26 ± 7.30	46.2	28.0	7.66 ± 2.01	9.5	4.9
P-value	0.465			0.901		

s.d., standard deviations.

achieve a final consensus. The presence of Ca(OH)<sub>2</sub> in the apical third was scored (absence was scored as “0”, and presence was scored as “1”) according to the three portions determined in the apical part.

#### Sample preparation for the extracted teeth

A total of 24 recently extracted human teeth with at least one curved root and curved root canal were selected. These teeth were obtained from the Oral Surgery Department of West China Hospital of Stomatology, and this study was approved by the Ethics Committee of West China Hospital of Stomatology. The degree of curvature was measured according to Schneider’s technique with CBCT,<sup>23</sup> and the radius of canal curvature was calculated. Teeth with a radius of curvature ranging from 3.5 to 10.1 mm and a degree of curvature ranging from 25.2° to 47.7° were included (Table 1). Two similar groups were established with respect to the degree and the radius of curvature. The homogeneity of the two groups was assessed using the paired *t*-test (Table 1).

The working length was established as 1 mm less than the length of the initial instrument (size 10) at the apical foramen. Root canals were

prepared to F3. The preparation and Ca(OH)<sub>2</sub> application procedures were the same as mentioned above. Teeth were stored at 37 °C and 100% relative humidity for 7 days.

#### Different irrigants and different instruments in calcium hydroxide removal in the curved root canals of extracted teeth

The results from the simulated curved root canals indicated that decalcifying solution was more effective in removing Ca(OH)<sub>2</sub>. To verify the efficacy of commonly used decalcifying solution in removing Ca(OH)<sub>2</sub>, 10% citric acid (group 1) and 17% EDTA (group 2) were applied in the two groups. EndoActivator was used for 30 s between each 5-mL irrigation. A final rinse was performed with 2 mL of irrigant and 3 mL of distilled water after two cycles of irrigation. The total activation time was 60 s. Root canals were dried with paper points after the Ca(OH)<sub>2</sub> removal procedure. Other operations followed the procedure of the simulated root canals mentioned above.

**Micro-computed tomography scanning**

The teeth were scanned by micro-computed tomography (micro-CT;  $\mu$ CT 5.0, SCANCO Medical AG, Brüttisellen, Switzerland) with an isotropic voxel size of 38  $\mu$ m at the following time points: after root canal instrumentation, after Ca(OH)<sub>2</sub> application and after Ca(OH)<sub>2</sub> removal. All cross-sections obtained were roughly perpendicular to the long axis of the root. The image serials were analysed using ImageJ. The volume of residual Ca(OH)<sub>2</sub> was measured. Then, the percentage of Ca(OH)<sub>2</sub> removal in the canals was calculated according to the method described in Ma's research.<sup>24</sup>

**Statistical analysis**

Data were presented as the mean  $\pm$  standard deviations (s.d.). Differences between the groups were determined using an unpaired Student's *t*-test. ANOVA with *post hoc* Tukey's test was used for

statistical analysis at a 95% confidence level. Statistical significance was established at *P*-values less than 0.05.

**RESULTS**

The percentages of Ca(OH)<sub>2</sub> removal in simulated root canals are shown in Table 2 and Table 3 and Figure 2. The scores of the residual Ca(OH)<sub>2</sub> are shown in Figure 3.

In each group, Ca(OH)<sub>2</sub> was almost completely removed in the middle and coronal thirds. For the apical third, ultrasonic irrigation and EndoActivator removed more Ca(OH)<sub>2</sub> than the size 30 K file in the 10% citric acid group, but the difference was not significant (*P*>0.05). In the 2.5% NaOCl group, the 30 K file removed less Ca(OH)<sub>2</sub> than ultrasonic irrigation and the EndoActivator (*P*<0.05). There were no significant differences between the groups in the apical third (*P*>0.05).

**Table 2 Mean percentage of Ca(OH)<sub>2</sub> removal with different techniques from simulated root canals in the coronal, middle and apical sections**

Group	Group 1 (10% citric acid, n=10)				Group 2 (2.5% NaOCl, n=10)			
	Whole canal	Cervical 1/3	Middle 1/3	Apical 1/3	Whole canal	Cervical 1/3	Middle 1/3	Apical 1/3
SG1	99.44% $\pm$ 0.46%	100% $\pm$ 0%	100% $\pm$ 0%	96.76% $\pm$ 2.64%	98.89% $\pm$ 0.72%	100% $\pm$ 0%	99.52% $\pm$ 1.00%	94.34% $\pm$ 3.61%
SG2	99.67% $\pm$ 0.29%	100% $\pm$ 0%	100% $\pm$ 0%	98.10% $\pm$ 1.68%	99.37% $\pm$ 0.41%	100% $\pm$ 0%	100% $\pm$ 0%	96.43% $\pm$ 2.33%
SG3	99.79% $\pm$ 0.23%	100% $\pm$ 0%	100% $\pm$ 0%	98.82% $\pm$ 1.34%	99.69% $\pm$ 0.28%	100% $\pm$ 0%	100% $\pm$ 0%	98.25% $\pm$ 1.61%
SG4	99.83% $\pm$ 0.22%	100% $\pm$ 0%	100% $\pm$ 0%	99.02% $\pm$ 1.26%	99.72% $\pm$ 0.26%	100% $\pm$ 0%	100% $\pm$ 0%	98.43% $\pm$ 1.50%

SG1, 30 K file; SG2, F3 instrument; SG3, passive ultrasonic irrigation; SG4, EndoActivator. Values represent mean  $\pm$  standard deviations.

**Table 3 Mean percentage of Ca(OH)<sub>2</sub> removal with different techniques from simulated root canals in three sections in the apical 1/3**

Group	10% citric acid (n=10)			2.5% NaOCl (n=10)		
	0-1 mm	1-3 mm	3-5 mm	0-1 mm	1-3 mm	3-5 mm
SG1	87.81% $\pm$ 11.46%	96.48% $\pm$ 4.90%	99.42% $\pm$ 1.28%	73.86% $\pm$ 12.84%	95.30% $\pm$ 5.58%	99.21% $\pm$ 1.36%
SG2	87.85% $\pm$ 9.82%	99.29% $\pm$ 1.50%	100% $\pm$ 0%	79.37% $\pm$ 10.30%	99.21% $\pm$ 1.41%	98.96% $\pm$ 3.28%
SG3	91.22% $\pm$ 9.95%	100% $\pm$ 0%	100% $\pm$ 0%	87.01% $\pm$ 11.95%	100% $\pm$ 0%	100% $\pm$ 0%
SG4	92.73% $\pm$ 9.37%	100% $\pm$ 0%	100% $\pm$ 0%	82.15% $\pm$ 12.75%	100% $\pm$ 0%	100% $\pm$ 0%

SG1, 30 K file; SG2, F3 instrument; SG3, passive ultrasonic irrigation; SG4, EndoActivator. Values represent mean  $\pm$  standard deviations.

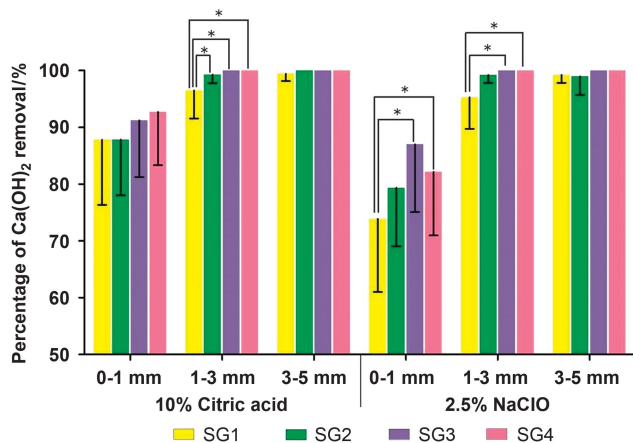


Figure 2 The percentage of Ca(OH)<sub>2</sub> removal in each region of the apical third with 10% citric acid or 2.5% NaOCl combined with different instruments (\**P*<0.05).

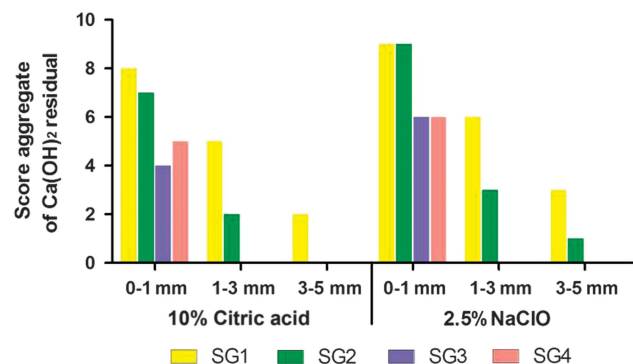


Figure 3 Score distribution for the three regions in the apical third with 10% citric acid and 2.5% NaOCl.



In the apical 1–3 mm region, 10% citric acid with a 30 K file (96.48% ± 4.90%) was not as effective as rotary instrumentation (99.29% ± 1.50%), ultrasonic (100% ± 0%) or EndoActivator activation (100% ± 0%;  $P < 0.05$ ). However, there were no significant differences in other root canal regions ( $P > 0.05$ ). For the 2.5% NaOCl

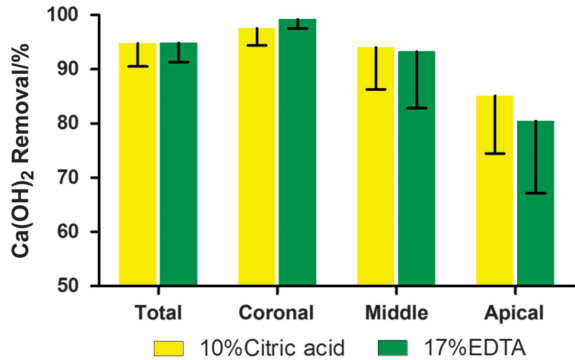


Figure 4 The percentage of Ca(OH)<sub>2</sub> removal for the entire canal and each third of the root canal system.

group, ultrasonic and EndoActivator activation significantly removed more Ca(OH)<sub>2</sub> than the size 30 K file in the apical one-third and the apical 0–1 mm and apical 1–3 mm groups ( $P < 0.05$ ). For the two groups, Ca(OH)<sub>2</sub> was completely removed at the 1–5 mm level using ultrasonic irrigation and the EndoActivator. At the apical 0–1 mm level, the 10% citric acid group removed significantly more Ca(OH)<sub>2</sub> than 2.5% NaOCl when using a 30 K file ( $P < 0.05$ ). No significant differences were noted for other subgroups at the 0–1 mm level ( $P > 0.05$ ), but the 10% citric acid group removed more Ca(OH)<sub>2</sub>. On the basis of the results of the scores in different segments, we found that residual Ca(OH)<sub>2</sub> frequently remained in the apical 0–1 mm segment. Ultrasonic and EndoActivator activation could improve the Ca(OH)<sub>2</sub> removal in the apical 1–3 mm and 3–5 mm sections.

In human extracted teeth, the effect of two decalcifying solutions in removing Ca(OH)<sub>2</sub> is illustrated in Figure 4. There were no significant differences in any sections of the canal irrigated either with 10% citric acid or with 17% EDTA in removing Ca(OH)<sub>2</sub> ( $P > 0.05$ ). For 33% of the samples, Ca(OH)<sub>2</sub> was completely removed by 10% citric acid. Residual Ca(OH)<sub>2</sub> was found in the apical one-third, isthmus and irregular parts (Figure 5).




Figure 5 Micro-CT reconstructed images of extracted teeth. (a1–a3) Reconstructed images after root canal preparation, Ca(OH)<sub>2</sub> medication and removal with 10% citric acid. (b1–b3) Reconstructed images after root canal preparation, Ca(OH)<sub>2</sub> medication and removal with 17% EDTA. EDTA, ethylenediaminetetraacetic acid; micro-CT, micro-computed tomography.

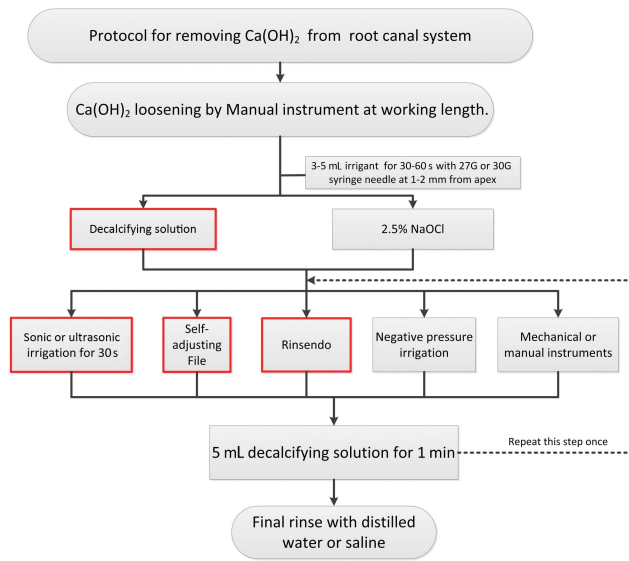


Figure 6 Recommended protocol for Ca(OH)<sub>2</sub> removal (the red box indicates the preferred method).

## DISCUSSION

This study investigated the effect of decalcifying solution and NaOCl on the removal of Ca(OH)<sub>2</sub> in simulated curved root canals with different instruments. Ca(OH)<sub>2</sub> could not be completely removed in all groups. However, decalcifying solution combined with sonic or ultrasonic agitation was the most effective method for removing Ca(OH)<sub>2</sub> in curved root canal systems. Sonic or ultrasonic irrigation enhanced the agitation and shearing stress of irrigants in the root canal wall, which was effective in removing debris in root canals.<sup>16,25</sup> In a previous study, the use of citric acid as a decalcifying solution was more effective than NaOCl in Ca(OH)<sub>2</sub> removal,<sup>12</sup> and similar results were found in the present study. This finding might be explained by the fact that citric acid and Ca(OH)<sub>2</sub> underwent a neutralization reaction. In addition, citric acid is a good chelating agent for removing the smear layer. However, NaOCl had a limited ability to dissolve inorganic substances, such as calcium.<sup>17,26</sup>

Residual Ca(OH)<sub>2</sub> mainly remained in the apical part of the curved root canal. Residual Ca(OH)<sub>2</sub> was frequently located at the 0–1 mm region from the apex, followed by a 1–3 mm region from the apex. The result was similar to previous studies in which more Ca(OH)<sub>2</sub> remained in the apical one-third.<sup>15,24</sup> Investigations that used passive ultrasonic irrigation and a master apical file to remove Ca(OH)<sub>2</sub> found that there were no significant differences in the apical one-third.<sup>15</sup> In this study, significant differences appeared between the 30 K file and sonic and ultrasonic irrigation groups when using 2.5% NaOCl. The findings might be explained by the differences in the experimental models and the curvature and morphology of the root canal. From there constructed images of micro-CT after Ca(OH)<sub>2</sub> removal, the residual easily appeared in the apical one-third, isthmus and irregular regions. Because of the complicated anatomy of the human root canal system, residual Ca(OH)<sub>2</sub> frequently remained in these regions.<sup>16,24,27–28</sup> Because the effectiveness of irrigation could depend on both the mechanical flushing action and the chemical ability to dissolve tissue,<sup>29</sup> it may be a good choice to apply the mechanical flushing action in combination with the decalcifying solution to remove Ca(OH)<sub>2</sub> in the various root canals.

There were two aspects important for choosing instruments to remove Ca(OH)<sub>2</sub>. First, the instruments should enhance the agitation or shearing stress of irrigants in the root canal wall, such as passive ultrasonic irrigation, EndoActivator and EndoVac.<sup>16,25,28,30</sup> The second aspect is mechanical removal realized by using instruments that fully contact the root canal wall.<sup>14,30–31</sup> Moreover, some researchers have used both mechanical removal and irrigant agitation to enhance the effects of removal.<sup>17,32</sup>

Determining the most appropriate and effective method for removing Ca(OH)<sub>2</sub> is important. The removal procedure has the potential to alter canal wall morphology. The decalcifying solution has the ability to demineralize dentin, and it takes more than 60 s to establish a trend of saturation.<sup>16,26</sup> For EDTA, if given sufficient time to soften, a 50- $\mu$ m depth is capable of decalcifying dentin.<sup>29</sup> Thus, the canal diameter would increase by 0.1 mm. With a final rinse of NaOCl after the decalcifying solution, dentin erosion increases.<sup>29</sup> The mechanical removal of Ca(OH)<sub>2</sub> with root canal preparation instruments may affect the shape of the prepared root canal.<sup>21</sup> Recently, a study showed that the file-to-wall contact during ultrasonic activation of the irrigant occurred in all case studies.<sup>33</sup> Therefore, the ultrasonic technique also has the potential to alter canal morphology unpredictably during root canal irrigation when removing Ca(OH)<sub>2</sub>. An investigation demonstrated that mechanical root canal preparation could generate high forces, resulting in dentinal defects and even dentin fractures.<sup>34</sup> It is still unknown whether the use of decalcifying solution and mechanical instruments to remove Ca(OH)<sub>2</sub> could increase the risk of dentinal defects, dentin fracture or root fracture. However, theoretically, the weak dentin wall could be a contributing factor to dentin fracture and root fracture. To prevent this scenario, some details must be highlighted, such as controlling the exposure time in decalcifying solution, using irrigants at the proper concentrations and sequence, and choosing instruments that are more gentle on the canal wall.

From previous studies, we found that many factors could affect the removal efficacy of Ca(OH)<sub>2</sub>, including the position of the syringe needle;<sup>35</sup> the type, dosage and proportion of irrigants;<sup>11,13</sup> and the application of instruments.<sup>14,16–17,24,28</sup> However, no recommended Ca(OH)<sub>2</sub> removal protocol is available that could be referenced in clinical practice. Therefore, on the basis of the conclusions of this study and the methods recommended in previous studies, a Ca(OH)<sub>2</sub> removal protocol for curved root canals was proposed (Figure 6). Considering the various factors affecting calcium hydroxide removal, this system is a stable and effective method to remove Ca(OH)<sub>2</sub> from the root canal system. This protocol uses more than 10 mL of irrigant. According to the clinical situation, the dosage of flushing fluid and times for instrument usage should be increased.

## CONCLUSION

In this study, Ca(OH)<sub>2</sub> could not be completely removed in most of the experimental groups. The decalcifying solution with the EndoActivator or passive ultrasonic irrigation effectively removes residual Ca(OH)<sub>2</sub> in a curved root canal system. An appropriate and effective method for removing Ca(OH)<sub>2</sub> is important, and our findings support our recommendation for such a procedure.

## ACKNOWLEDGEMENTS

This study was supported by projects from the Sichuan Science and Technology Department (Grant No. 2013JY0164) and the National Nature Science Foundation of China (Grant No. 81670980).

- 1 Provenzano JC, Rôças IN, Tavares LF *et al*. Short-chain fatty acids in infected root canals of teeth with apical periodontitis before and after treatment. *J Endod* 2015; **41** (6): 831–835.
- 2 Mohammadi Z, Dummer PM. Properties and applications of calcium hydroxide in endodontics and dental traumatology. *Int Endod J* 2011; **44** (8): 697–730.
- 3 Marinho AC, Polay AR, Gomes BP. Accuracy of turbidimetric limulus amoebocyte lysate assay for the recovery of endotoxin interacted with commonly used antimicrobial agents of endodontic therapy. *J Endod* 2015; **41** (10): 1653–1659.
- 4 Tavares WL, de Brito LC, Henriques LC *et al*. Effects of calcium hydroxide on cytokine expression in endodontic infections. *J Endod* 2012; **38** (10): 1368–1371.
- 5 Pereira MS, Rossi MA, Cardoso CR *et al*. Cellular and molecular tissue response to triple antibiotic intracanal dressing. *J Endod* 2014; **40** (4): 499–504.
- 6 Simcock RM, Hicks ML. Delivery of calcium hydroxide: comparison of four filling techniques. *J Endod* 2006; **32** (7): 680–682.
- 7 Kim SK, Kim YO. Influence of calcium hydroxide intracanal medication on apical seal. *Int Endod J* 2002; **35** (7): 623–628.
- 8 Calt S, Serper A. Dentinal tubule penetration of root canal sealers after root canal dressing with calcium hydroxide. *J Endod* 1999; **25** (6): 431–433.
- 9 Margelos J, Eliades G, Verdellis C *et al*. Interaction of calcium hydroxide with zinc oxide-eugenol type sealers: a potential clinical problem. *J Endod* 1997; **23** (1): 43–48.
- 10 Erdemir A, Hale Ari, Güngüneş H *et al*. Effect of medications for root canal treatment on bonding to root canal dentin. *J Endod* 2004; **30** (2): 113–116.
- 11 Zorzin J, Wießner J, Wießner T *et al*. Removal of radioactively marked calcium hydroxide from the root canal: influence of volume of irrigation and activation. *J Endod* 2016; **42** (4): 637–640.
- 12 Rödiger T, Vogel S, Zapf A *et al*. Efficacy of different irrigants in the removal of calcium hydroxide from root canals. *Int Endod J* 2010; **43** (6): 519–527.
- 13 Sağsın B, Ustün Y, Aslan T *et al*. The effect of peracetic acid on removing calcium hydroxide from the root canals. *J Endod* 2012; **38** (9): 1197–1201.
- 14 Capar ID, Özcan E, Arslan H *et al*. Effect of different final irrigation methods on the removal of calcium hydroxide from an artificial standardized groove in the apical third of root canals. *J Endod* 2014; **40** (3): 451–454.
- 15 Kuştaçarı A, Er K, Siso SH *et al*. Efficacy of laser-activated irrigants in calcium hydroxide removal from the artificial grooves in root canals: an *ex vivo* study. *Photomed Laser Surg* 2016; **34** (5): 205–210.
- 16 Wigler R, Dvir R, Weisman A *et al*. Efficacy of XP-endo finisher files in the removal of calcium hydroxide paste from artificial standardized grooves in the apical third of oval root canals. *Int Endod J* 2016; doi:10.1111/iej.12668 (Epub ahead of print).
- 17 Wiseman A, Cox TC, Paranjpe A *et al*. Efficacy of sonic and ultrasonic activation for removal of calcium hydroxide from mesial canals of mandibular molars: a microtomographic study. *J Endod* 2011; **37** (2): 235–238.
- 18 De-Deus G. Research that matters—root canal filling and leakage studies. *Int Endod J* 2012; **45** (12): 1063–1064.
- 19 Schäfer E, Eriş M, Dammaschke T. Comparative study on the shaping ability and cleaning efficiency of rotary two instruments. Part 2. Cleaning effectiveness and shaping ability in severely curved root canals of extracted teeth. *Int Endod J* 2006; **39** (3): 203–212.
- 20 Townsend C, Maki J. An *in vitro* comparison of new irrigation and agitation techniques to ultrasonic agitation in removing bacteria from a simulated root canal. *J Endod* 2009; **35** (7): 1040–1043.
- 21 Schneider SW. A comparison of canal preparations in straight and curved root canals. *Oral Surg Oral Med Oral Pathol* 1971; **32** (2): 271–275.
- 22 Gao Y, Haapasalo M, Shen Y *et al*. Development and validation of a three-dimensional computational fluid dynamics model of root canal irrigation. *J Endod* 2009; **35** (9): 1282–1287.
- 23 Elshierif SM, Zayet MK, Hamouda IM. Cone-beam computed tomography analysis of curved root canals after mechanical preparation with three nickel-titanium rotary instruments. *J Biomed Res* 2013; **27** (4): 326–335.
- 24 Ma JZ, Shen Y, Al-Ashaw AJ *et al*. Micro-computed tomography evaluation of the removal of calcium hydroxide medicament from C-shaped root canals of mandibular second molars. *Int Endod J* 2015; **48** (4): 333–341.
- 25 Goode N, Khan S, Eid AA *et al*. Wall shear stress effects of different endodontic irrigation techniques and systems. *J Dent* 2013; **41** (7): 636–641.
- 26 Ballal NV, Kumar SR, Laxmikanth HK *et al*. Comparative evaluation of different chelators in removal of calcium hydroxide preparations from root canals. *Aust Dent J* 2012; **57** (3): 344–348.
- 27 Rödiger T, Hirschleib M, Zapf A *et al*. Comparison of ultrasonic irrigation and RinsEndo for the removal of calcium hydroxide and Ledermix paste from root canals. *Int Endod J* 2011; **44** (12): 1155–1161.
- 28 Alturaiki S, Lamphon H, Edrees H *et al*. Efficacy of 3 different irrigation systems on removal of calcium hydroxide from the root canal: a scanning electron microscopic study. *J Endod* 2015; **41** (1): 97–101.
- 29 Basrani B, Haapasalo M. Update on endodontic irrigating solutions. *Endod Topics* 2012; **27** (1): 74–102.
- 30 Ethem Yaylali I, Kececi AD, Ureyen Kaya B. Ultrasonically activated irrigation to remove calcium hydroxide from apical third of human root canal system: a systematic review of *in vitro* studies. *J Endod* 2015; **41** (10): 1589–1599.
- 31 Ma JZ, Shen Y, Yang Y *et al*. *In vitro* study of calcium hydroxide removal from mandibular molar root canals. *J Endod* 2015; **41** (4): 553–558.
- 32 Topçuoğlu HS, Düzgün S, Ceyhanlı KT *et al*. Efficacy of different irrigation techniques in the removal of calcium hydroxide from a simulated internal root resorption cavity. *Int Endod J* 2015; **48** (4): 309–316.
- 33 Boutsioukis C, Verhaagen B, Walmsley AD *et al*. Measurement and visualization of file-to-wall contact during ultrasonically activated irrigation in simulated canals. *Int Endod J* 2013; **46** (11): 1046–1055.
- 34 Hülsmann M. Effects of mechanical instrumentation and chemical irrigation on the root canal dentin and surrounding tissues. *Endod Topics* 2013; **29** (1): 55–86.
- 35 Chou K, George R, Walsh LJ. Effectiveness of different intracanal irrigation techniques in removing intracanal paste medicaments. *Aust Endod J* 2014; **40** (1): 21–25.



This work is licensed under a Creative Commons Attribution 4.0 International License. The images or other third party material in this article are included in the article's Creative Commons license, unless indicated otherwise in the credit line; if the material is not included under the Creative Commons license, users will need to obtain permission from the license holder to reproduce the material. To view a copy of this license, visit <http://creativecommons.org/licenses/by/4.0/>

© The Author(s) 2017