

Pure spinal epidural cavernous hemangioma: A case series of seven cases

ABSTRACT

Introduction: Pure spinal epidural cavernous hemangiomas (PSECHs) are rare vascular lesions with about 100 cases reported. Herein, we present a case series of 7 PSECHs discussing their clinical presentation, radiological characteristics, surgical technique and intraoperative findings, pathological features, and functional outcome.

Materials and Methods: We retrieved from the retrospective databases of the senior authors, patients with pathologically confirmed PSECH operated between January 2002 and November 2015. From their medical records, the patients' sociodemographic, clinical, radiological, surgical, and histopathological data were retrieved and analyzed.

Results: The mean age of the seven cases was 50.3 years. Four were females. All the five cases (71.4%) in the thoracic spine had myelopathy and the 2 (28.6%) lumbar cases had sciatica. Local pain was present in all the cases. All the lesions were isointense on T1-weighted images, hyperintense on T2-weighted images, and in five cases there was strong homogeneous enhancement. In six cases (85.7%), classical laminectomy was done; lesions resected in one piece in five cases. Total excision was achieved in all the cases. Lesions were thin-walled dilated blood vessels, lined with endothelium, and engorged with blood and with scanty loose fibrous stroma. The median follow-up was 12 months (range: 1–144 months). All patients gradually improved neurologically and achieved a good outcome with no recurrence at the last follow-up.

Conclusion: PSECH although rare is increasing reported and ought to be included in the differential diagnosis of spinal epidural lesions. Early surgical treatment with total resection is recommended as would result in a good prognosis.

Key words: Cavernous hemangioma; epidural; functional outcome; pathology; spine; surgical findings.

Introduction


Cavernous hemangiomas (CH) although occur frequently in the intracranial structures are rare in the spine with “pure” primary epidural hemangiomas much more rare.^[1-6] Spinal CHs occur with an incidence of 0.22 cases/million/year accounting for 5–12% of the spinal vascular lesions, 51% of which are extradural; most of them being secondary extensions from the vertebral lesions. Pure or primary (nonvertebral origin) spinal epidural CHs are very rare and account for only 4% of all the epidural lesions.^[2] Till date, about 100 cases have been reported^[4] in four case series^[4-7] whereas the rest are case reports.^[3]

Herein, we present the fifth case series on seven pure spinal epidural CHs (PSECHs) and discuss their clinical presentation, radiological characteristics, surgical technique

IGNATIUS NGENE ESENE¹, AHMED M ASHOUR^{1,2}, ERIC MARVIN², MOHAMED NOSSEIR¹, ZEIAD Y FAYED¹, KHALED SEoud¹, KHALED EL BAHY¹

¹Department of Neurosurgery, Ain Shams University, Cairo, Egypt, ²Department of Neurosurgery, St. Louis University, St. Louis, Missouri, USA

Address for correspondence: Dr. Ignatius Ngene Esene, Department of Neurosurgery, Ain Shams University, Cairo, Egypt. E-mail: ignatiusesene@yahoo.co.uk

Access this article online	
Website: www.jcvjs.com	Quick Response Code 
DOI: 10.4103/0974-8237.188419	

This is an open access article distributed under the terms of the Creative Commons Attribution-NonCommercial-ShareAlike 3.0 License, which allows others to remix, tweak, and build upon the work non-commercially, as long as the author is credited and the new creations are licensed under the identical terms.

For reprints contact: reprints@medknow.com

How to cite this article: Esene IN, Ashour AM, Marvin E, Nosseir M, Fayed ZY, Seoud K, *et al.* Pure spinal epidural cavernous hemangioma: A case series of seven cases. *J Craniovert Jun Spine* 2016;7:176-83.

and intraoperative findings, pathological features, and functional outcome.

Materials and Methods

Study design

Case series – we retrieved from the personal retrospective electronic databases of the senior authors, patients with pathologically confirmed spinal epidural CHs operated between January 2002 and November 2015 in our aforementioned neurosurgical departments. From their medical records, the patients' sociodemographic, clinical, radiological, and histopathological data were retrieved and analyzed. Only cases of PSECHs were included in the study.

Clinical assessment

The patients' clinical features were local pain, neurologic status (initial presentation and before surgery), and myelopathy. The Frankel grading system^[8] was used to assess the patients' neurologic function from A to E. Clinical assessment was done preoperatively, postoperatively, and during routine follow-up visits.

Imaging assessment

The magnetic resonance imaging (MRI) images were evaluated by the authors, and the lesion was classified as having smooth, lobulated, or invasive contours.^[9]

Surgical technique and assessment

The extent of resection was considered total, subtotal, or partial.^[3] Subtotal resection was defined as "complete removal of the intracanalicular lesion and residual mass in the within or lateral to the intervertebral foramen."^[3] Partial removal if part of the intracanalicular lesion is left behind.^[3]

Histopathological assessment

A histopathological examination was done on all the specimens to confirm the diagnosis.

Follow-up

The follow-up was clinical and radiological in the immediate postoperative period, early (1–6 months postoperative), and late (> 1 years).

Results

Sociodemographic data and clinical data

A total of seven patients were included in our series. The mean age (\pm standard deviation) was 50.3 ± 13.7 years (minimum 30 maximum 75). The male: female sex ratio was 3:4 [Table 1]. Four cases (57.1%) had associated medical comorbidity in the form of hypertension.

The lesions were located in the dorsal spine [Figure 1] in five cases (71.4%) and lumbar in two cases (28.6%). Local pain was present in all the cases. Myelopathy was present in all the five cases (71.4%) with dorsal location of lesion. Bilateral lower limbs motor deficit was present in five cases (71.4%). Two patients had no motor deficit. Sensory deficit was present in all the cases (85.7%) in the form of paresthesia and/or hypoesthesia [Table 1]. Sphincteric disturbance in the form of urinary incontinence was present in three cases and urinary and fecal incontinence in one case [Case No. 1, Table 1].

Except for one patient (Case No. 3) with 2 days duration of symptoms, the rest of the five cases had a mean duration of 6.3 ± 3.0 months (minimum 4 maximum 12). The onset of the symptoms was acute (from hemorrhage) in one case and gradual (months) in six cases (85.7%). The clinical course was progressive in five cases (71.4%) and exacerbating within hours in two cases [Table 1].

Radiological

All the seven cases had a preoperative MRI with and without contrast and T2-weighted images [Table 2]. One case had a plain radiograph as the lesion was associated with a spondylolisthesis. None had a preoperative computed tomography scan nor angiography. In all the cases, the lesion was isointense on T1-weighted images and hyperintense on T2-weighted images. Enhanced MR images were available in all the cases, among them, five cases (71.4%) showed a strong homogeneous intensity after Gd-DTPA administration. One was nonenhancing and another mild enhancement because of intralesional hemorrhage. The lesion involved one spinal segment in six cases (85.7%) and two segments in one case. In six cases (85.7%), the lesion was located dorsal to the cord and lateral in one case. Foraminal extension was observed in five cases (71.4%). Cord signal was present in one case.

Preoperative diagnosis

The preoperative diagnosis was neurofibroma in five cases, meningioma in one, and synovial cyst in the other.

Surgical procedure and Findings

Surgery was performed on an elective basis in five cases (71.4%) and as an emergency due to hemorrhage and acuteness of the presentation in two cases. Classical laminectomy was done in six cases and hemilaminectomy in one case. Position was prone in six cases and lateral decubitus in one that was pregnant (Case No. 6).

The technique of excision was variable with five lesions (71.4%) removed in one piece and ≥ 2 pieces in two cases. Except for one case, the remaining cases were well circumscribed with good plane of cleavage. They were reddish, reddish

Table 1: Patients sociodemographic and clinical characteristics

Case No.	Age/sex	Local pain/site	Initial symptoms	Duration of symptoms/ months	Onset and course	Neurologic status (motor/ sensory) (on admission)	Myelopath (on admission)	Sphincters (incontinence) (admission)	Preoperative diagnosis	Surgery type	Degree of resection
1	46/male	Yes Dorsal	Urinary incontinence	12	Gradual Progressive	Paraparesis (right G1 and left G3) Hypothesia below T10	Yes	Yes	Neurofibroma	Elective	Total resection
2	44/female	Yes Lumbar	Severe left sciatica	6	Gradual Progressive	Sciatica left No weakness (G5) S1 hypothesia	No	None	Neurofibroma	Elective	Total resection
3	48/female	Yes Dorsal	Lower limbs paresis and paresthesias	0.07 (48 h)	Acute Exacerbating	Paraplegia (G0) Sensory level T6	Yes	Yes	Synovial cyst	Emergency	Total resection
4	54/male	Yes Lumbar	Low back pain and left sciatica	4	Gradual Progressive	Sciatica left No weakness (G5) Paresthesia	No	None	Neurofibroma	Elective	Total resection
5	55/male	Yes Dorsal	Mid-back pain	4	Gradual Exacerbating	Paraplegic (G0) Sensory level T4	Yes	Yes	Neurofibroma	Emergency	Total resection
6	30/female	Yes Dorsal	Back pain	7	Gradual Exacerbating	Paraplegia (G0) Sensory level T3	Yes	None	Neurofibroma	Emergency	Total resection
7	75/female	Yes Dorsal	Back pain	5	Gradual Progressive	Paraparesis (G4) Hypoesthesia below T10	Yes	None	Meningioma	Elective	Total resection

Case No. 3 - Intraoperatively; there was blue discoloration of the dura prompting a durotomy which revealed an acute subdural hematoma that was evacuated; Case No. 6 - Patient was pregnant

Table 2: Radiologic characteristics of cases

Case No.	Spinal level	Spinal segments involved	Intervertebral foramen Extension (yes/no)/side	T1	T2	T1 C+	Shape/contours
1	D6-D7	1	Yes Right	Isointense	Hyperintense	Hyperintense Homogeneous	Oval smooth
2	L5 to S1	1	Yes Left	Isointense	Hyperintense	Hyperintense Homogeneous	Oblong Mildly lobulated
3	T5-T6	1	No	Isointense	Hyperintense (heterogeneous)	Isointense NonEnhancing	Ovoid Smooth
4	L3-L4	1	Yes Right	Isointense	Hyperintense	Hyperintense Homogeneous	Rounded Smooth
5	T6-T7	1	Yes Right	Isointense	Hyperintense	Hyperintense Mild	Ovoid Smooth
6	T1-T2 and T2-T3	2	Yes Left	Isointense	Hyperintense	Hyperintense Homogeneous	Oblong Smooth
7	T8-T9	1	No	Isointense	Hyperintense	Hyperintense Homogeneous	Oval Smooth

gray, or dark reddish with a soft but solid consistency. The blood supply was moderate to rich, and the lesions easily bled when touched thus the surgical technique consisted of surface coagulation that led to shrinkage of the tumor facilitating dissection from the dura and nerve root. Total tumor resection was achieved in all the cases. Associated

subdural hemorrhage was seen with Case No. 3 and was evacuated after durotomy.

Pathological findings

Common to our cases was the presence of thin-walled dilated blood vessels, lined with endothelium, and engorged with

blood and thrombi with scanty loose fibrous stroma. For Case No. 1, EMA and S100 were done which were negative.

Follow-up and outcome

The median follow-up duration was 12 months (minimum 1 maximum 144). Glasgow outcome score (GOS) on discharge was 4/5 in five cases, 3 and 4 in the remaining two cases. All patients experienced a gradual neurological improvement and a good outcome (six cases) (GOS = 5/5) with no recurrence at the last follow-up [Table 3].

Discussion

Spinal CH is a rare vascular malformation. PSECHs (without vertebral involvement) are more rare.^[1-6]

In 2003, 54 cases of PSECHs were reported in a review^[3] and by 2006, 26 more had been added according to the reviewed of Hatiboglu *et al.* that dated back till 1929.^[10] Since then, 9 more cases were reported by Zhong *et al.*,^[5] 14 by Li *et al.*,^[4] and 33 others according to Khalatbari *et al.*^[6] including their reported series of nine cases; taking the total to above 100.

Age and sex

Most PSECHs occur in adult patients aged from 30 to 60 years (mean: 40 years)^[3-6] with a female predominance^[3,5,6] although there have been reports including patients with 23 months^[11] to 81 years^[12] and one series reported a slight male preponderance.^[4] In our series, the mean age was 50.3 years similar to the previous series^[4-6] and reports^[3] and with slight female predominance.

Etiopathogenesis

Although the origin of CH is still unknown, certain predisposing features such as excessive movement,^[4,5] anticoagulation therapy,^[4,5] pregnancy, trauma,^[4,5] and irradiation^[5] have been described. In our series, one case (Case No. 4) occurred in a setting of hypermobility and one occurred during pregnancy (Case No. 6). None of our patients admitted a history of trauma or irradiation. Associated skin findings such

as telangiectasia and/or pigmentation described elsewhere^[3] were not present in any of our cases.

While the natural history of epidural hemangiomas is still unknown,^[5] they usually present with a gradual onset and a slow progressive clinical course because of local pressure effect on the spinal cord/root^[13-15] as PSECHs are said to be benign hamartomatous vascular anomalies with a gradual increase in volume^[3] or due to small repeated episodes of bleeding.^[4,6] Sudden or intermittent clinical deterioration in the course of the disease might be caused by a more rapid increase of lesion volume due to thrombotic venous occlusion, neovascularization by estrogenic factor, or drainer compression by an enlarged pregnant uterus.^[3] However, some authors have reported that sudden onset due to intralesional hemorrhage or thrombosis is rarely noticed.^[13-15] In our series, the two cases (Cases Nos. 3 and 5) presented with acute deterioration were due to hemorrhage. Nonetheless, the clinical presentation of PSECHs depends on the location, growth rate, and biological behavior^[6] and consists of local spinal pain, radiculopathy, and myelopathy.^[16,17] Most studies have differentiated three modes of manifestation: Acute hemorrhage into the lesion, acute hemorrhage surrounding the lesion, and slow seeping hemorrhage.^[4]

Clinical presentation

Slowly progressive myelopathy is described as the most common clinical presentation of PSECHs.^[6] Myelopathy was present in five cases in our series with thoracic spine lesions (Cases Nos. 1, 3, 5, 6, and 7). Myelopathy might occur more frequent than radiculopathy because the nerve root can tolerate longterm soft compression much better than the spinal cord.^[4] Patients may present with radiculopathy due to either extension of the lesion into the intervertebral foramen, or into the ventral and lateral compartments mimicking the symptoms of disc herniation.^[6] Radiculopathy was the presentation in the two cases with lumbar lesions. Sphincter dysfunction cited as a late clinical finding of PSECHs^[10,18] was present in Cases Nos. 1, 3, and 5 of our series [Table 1].

Radiological presentation

PSECHs may occur anywhere along the spinal canal but appear to have a predilection for the thoracic levels,^[4-6] with decreasing frequency at the cervical, lumbar, and sacral levels.^[6] Khalatbari *et al.*^[6] suggested that the involvement of a specific region of the spine by PSECHs is thought to relate to the number of vertebrae contained therein. All our cases were located in the thoracic (five cases) and lumbar spine (two cases).

The higher incidence of CHs in the posterior thoracic spine is thought to be related with the following factors: The larger

Table 3: Functional outcome on discharge and last follow-up (Frankel grade)

Case No.	Frankel grade			Follow-up/ months	Recurrence
	Preoperative	Postoperative	Last follow-up		
1	C	E	E	8	No
2	E	E	E	14	No
3	A	C	E	12	No
4	E	E	E	36	No
5	A	E	E	6	No
6	A	D	E	144	No
7	D	D	D	1	No

available epidural space as well as plastic nature of the soft texture CH,^[4] the lower resistance in the posterior portion of the spinal canal,^[6] and their embryological origin were most are located in the dorsal or dorsolateral epidural space in which the venous plexus was abundant.^[5] The negative thoracic cavity pressure may facilitate the growth of the CH toward the pleural cavity.^[4] The former two hypotheses may also be explanations for the mainly posterolateral localization of the lesions in the spinal epidural space.^[6] One of our lesions was purely dorsolateral, whereas six cases were dorsally located with four of these cases extending laterally.

Foraminal extension was observed in five cases with significant widening of the foramen in one case (Case No. 6). This high incidence of intravertebral foramen extension has been reported in other series; however, pure foraminal and extraforaminal cavernous are extremely rare.^[5,7] Tumors growth into the intervertebral foramen could be due to the loose tissue structure inside the neural foramen^[5,19] while pure foraminal CHs may arise from the blood vessels of the nerve roots.^[5] PSECHs hardly erode the vertebra.^[5]

PSECHs usually have a multisegmental extension.^[7] Six of our cases involved a single spinal segment, whereas one case involved two. PSECHs have been reported to involve 2.5 vertebral segments on average; suggesting that they are more likely to grow laterally than longitudinally^[4] while some authors have stated that they are usually confined to two or more spinal levels.^[9,20]

PSECHs are usually lobulated-spindle^[7] or oval shaped, sometimes flattened toward the spinal cord rather than distorting it. They are well delineated and often have a capsule or pseudocapsule.^[18] All our cases were well circumscribed and more or less ovoid in shape, but with smooth borders. There was not any bony destruction in any of our cases.

MRI of PSECHs shows characteristic lobulated contour, which encircled the spinal cord^[7,17] although in our series, the contours were smooth in six cases and lobulated in one. The lesion is isointense with the spinal cord in T1-weighted and hyperintense in T2-weighted MR images and shows strong homogeneous enhancement after contrast material injection^[3-7,17,20] due to their slow blood flow of sinusoidal vessels.^[3,10] Five of our cases had a strong homogeneous enhancement. Tumors with hemorrhage, liquefaction of the hematoma, or intravascular thrombosis can have different signals on MRI or heterogeneous enhancement;^[5,10] slight global or peripheral enhancement patterns have been reported.^[17] Ring enhancement may be due to the necrosis

and degeneration at the center of the lesion.^[3,17] In our series, one case showed nonenhancement (Case No. 3) and another heterogeneous signal due to hemorrhage (Case No. 5).

Diagnosis and differential diagnosis

There are no clinical nor radiological features specific to epidural CHs^[5] making preoperative diagnosis difficult although a “wafting silk sign”^[17] has been described. None of our cases was diagnosed preoperatively as PSECH. The main differential diagnoses of PSECHs include neurogenic tumors, metastasis, lymphoma, meningioma, schwannomas, multiple myeloma, extraosseous Ewing’s sarcoma, disc fragment, and epidural angioliopoma.^[3-7,17,20]

The difference in the radiological characteristics between the intramedullary and epidural CHs have been described with the intramedullary CHs usually exhibiting a mixed signal with low hemosiderin signal ring periphery because of repeated bleeding on T2-weighted images.^[5,6]

Although PSECHs share many common imaging features with schwannomas and meningiomas, they can grow into multiple level or bilateral neuroforamina. When they do extend through the foramen as a dumbbellshaped lesion, they do not enlarge the neuroforamen as much as a schwannoma or neurofibroma of similar size, and they often have an irregular or lobulated contour with strong enhancement. Schwannomas enhance less after administration of contrast medium and frequently have cystic changes.^[4] Osteolytic or osteoblastic changes in the adjacent bone and signal voids due to calcification are the distinctive findings of meningioma, especially of the psammomatous type.^[3] Clinically, less radicular pain or spontaneously resolved radicular pain in the presence of a large intraforaminal lesion is a rule for epidural CH.^[4]

Lymphoma usually appears isointense on T2weighted images and exhibits less frequent paravertebral extension and intervertebral neural foraminal widening. An angioliopoma is typically hyperintense on T1weighted images because of its fat content, whereas the fat in a CH is usually absent.^[4]

Routine angiography is not a rule and does not provide the definitive diagnosis. However, digital subtraction angiography (DSA) can be done in patients with an acute symptom onset due to hemorrhage, to rule out other vascular malformations if the patient’s condition allows. However, in the face of acute paraplegia, an urgent exploratory laminectomy/decompression should be done, and DSA should not delay the surgery.^[21] DSA was done in one of our cases (Case No. 3) postsurgery and was even negative. The belief that the presence of spinal cord cavernous angiomas

warrants imaging of the entire neuraxis to exclude the relatively significant incidence of multiple lesions is thus unnecessary in patient with PSECHs.^[6,17,20]

Treatment

Complete surgical resection is the best treatment for epidural CHs^[4,6] with *en bloc* total excision being the goal during the first operation.^[6] However, severe intraoperative bleeding and anterior, foraminal, or intrathoracic extension of the lesion are the main trouble making factors that may limit complete resection.^[6] Only two of our cases were excised in more than two pieces because of size, foraminal extension; and bleeding was managed with Gelfoam and Surgicel hemostatic agents. The volume of tumor usually shrinks through bipolar coagulation of its surface^[3-6] as was in most of our cases. Complete surgical resection was achieved in all our cases confirmed intraoperatively and with a postoperative MRI. Li *et al.*^[4] stated that during surgery, whenever a hypervascular lesion encroaches onto the dura mater with a soft, purple tumor mass extending through the foramen, an epidural CH should be strongly suspected in which case tumor biopsy should be avoided.

No adjuvant therapy was needed in our cases although radiotherapy and radiosurgery have been advised in lesions with extension out of the spinal canal and some remnants after surgery.^[9,20] However, use of radiation therapy remains

a controversial issue since the natural history of epidural CH is still unclear.^[4]

Histopathology

Histopathologically, PSECHs are composed of dilated sinusoidal vascular spaces walled by thin endothelial cells^[5,6] as was with our cases [Figures 2 and 3]. Thrombosis and previous hemorrhage without neural tissue are sometimes noticed within caverns.^[9,22] In addition, for Case No. 1, epithelial membrane antigen (EMA) and S100 were done which were negative [Figure 2]. EMA was negative excluding the possibility of angiomatous meningioma and S100, excluding the possibility of schwannoma with vascular ectasia. Although PSECHs do not represent true neoplasms, and there is no evidence that they may grow by mitotic activity, they are dynamic lesions with the intralesional hemorrhage, thrombosis, organization, cyst formation, and involution of the caverns all contributing to the changes in size and nature of these lesions.^[6]

Follow-up

The median follow-up duration in our series was 12 months with four of the seven cases having a follow-up 1 year and above. All patients experienced a gradual neurological improvement and a good outcome (Frankel Grade E in six cases and Grade D in one case) with no recurrence at the last follow-up [Table 3].

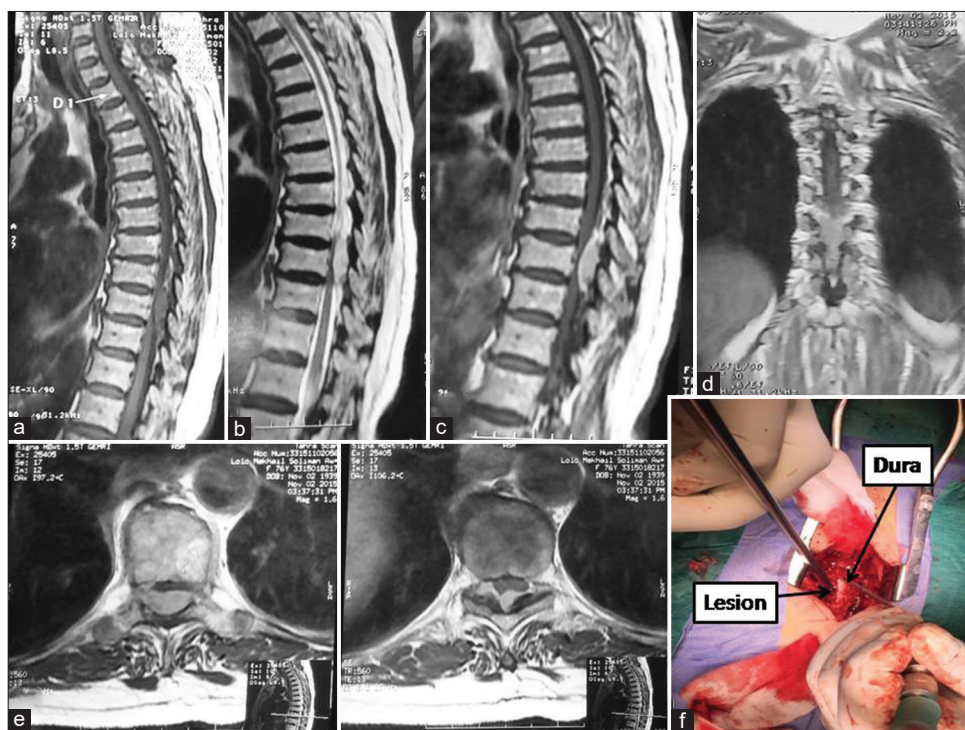


Figure 1: Case No. 1 (Patient No. 7): Magnetic resonance imaging thoracic spine: Well-defined ovoid lesion at T9 (3.2 cm × 1 cm × 1.8 cm). (a) T1-weighted 1 lesion isointense, (b) T2-hyperintensity, (c-e) T1-weighted 1 C+: Strong contrast enhancement, (f) intraoperative photograph: Lesion (reddish [left]) and dura (whitish on right)

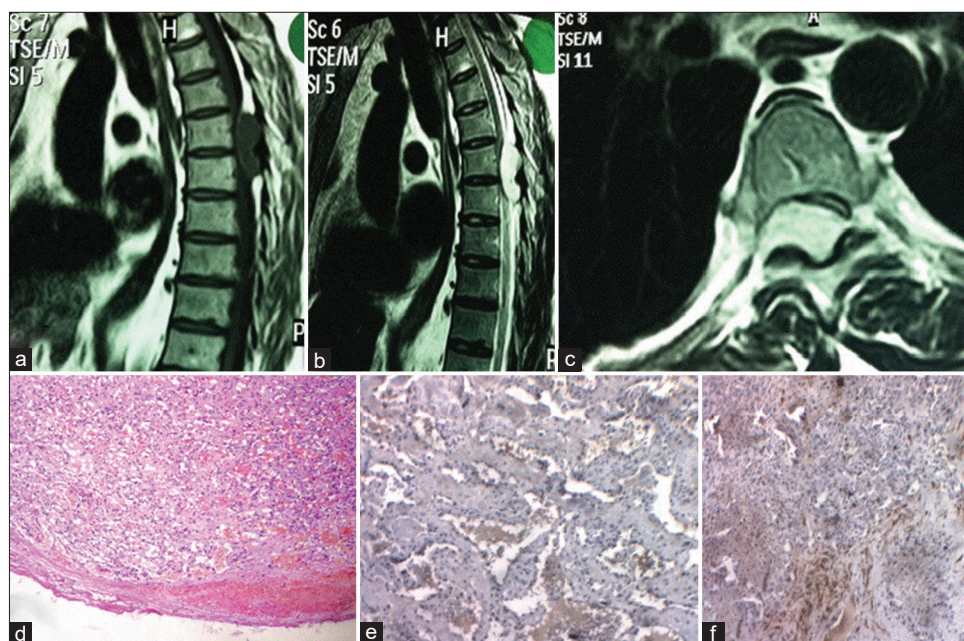


Figure 2: Case No. 2 (Patient No. 1): Magnetic resonance imaging dorsal spine: Epidural, oval, lesion at D6–D7 (2.6 cm × 2.0 cm × 0.5 cm): (a) T1-isointense, (b) T2-hyperintense, (c) homogeneous enhancement, (d) encapsulated lesion predominantly large vessels with cystically dilated lumina and thin walls, (e) epithelial membrane antigen negative, (f) S-100: Negative

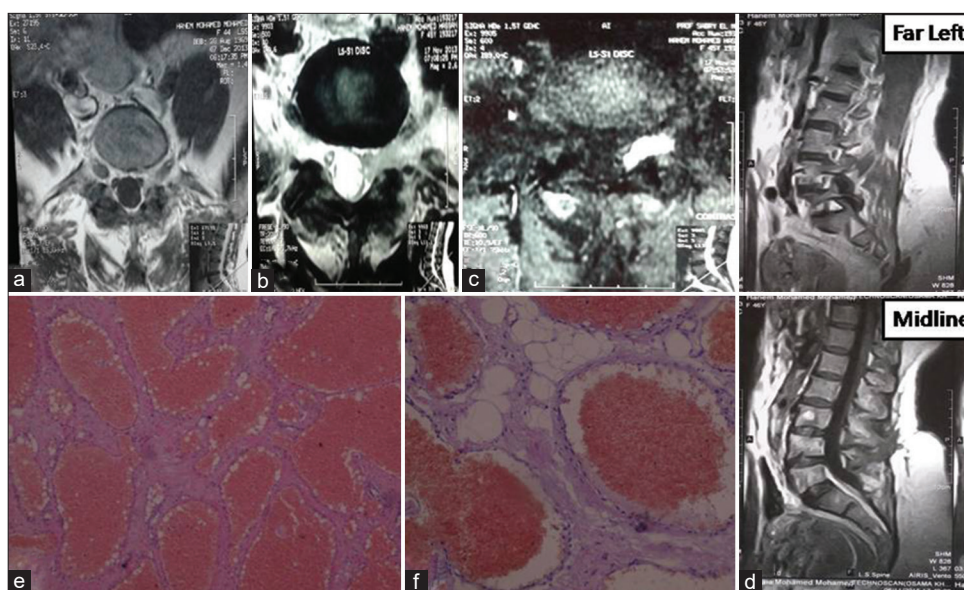


Figure 3: Case No. 2 (Patient No. 2): Magnetic resonance imaging of the lumbosacral spine: Elliptical epidural lesion at L5 (1 cm × 1 cm × 2 cm). (a) T1-isointense, (b) T2-hyperintense, (c) homogeneous enhancement, (d) postoperative contrasted (total excision) (e and f) histopathology: Dilated thin wall blood vessels engorged with blood with a scanty loose fibrous stroma

The severity of the preoperative neurologic status is the most important prognosis factor.^[3] Since surgery is safe and effective and paralysis due to acute hemorrhage is known to adversely affect the outcome,^[4] early surgical treatment is recommended to prevent irreversible neurological deficits,^[6] likewise it is worth considering surgical options in asymptomatic patients with large epidural CHs.^[4]

Study limitations

Short follow-up could explain the absence of recurrence in our series.

Conclusion

Spinal epidural CH although rare is increasing reported and ought to be included in the differential diagnosis of spinal

epidural lesions. Early surgical treatment with total resection is recommended as would result in a good prognosis.

Acknowledgment

Sincere appreciation to Dr. Iman Hewedi for providing the slides of the histopathologic examination.

Financial support and sponsorship

Nil.

Conflicts of interest

There are no conflicts of interest.

References

- Jang D, Kim C, Lee SJ, Ryu YJ, Kim J. Pure spinal epidural cavernous hemangioma with intralesional hemorrhage: A rare cause of thoracic myelopathy. *Korean J Spine* 2014;11:85-8.
- Hemalatha AL, Ravikumar T, Chamarthy NP, Puri K. A pure epidural spinal cavernous hemangioma-with an innocuous face but a perilous behaviour!! *J Clin Diagn Res* 2013;7:1434-5.
- Aoyagi N, Kojima K, Kasai H. Review of spinal epidural cavernous hemangioma. *Neurol Med Chir (Tokyo)* 2003;43:471-5.
- Li TY, Xu YL, Yang J, Wang J, Wang GH. Primary spinal epidural cavernous hemangioma: Clinical features and surgical outcome in 14 cases. *J Neurosurg Spine* 2015;22:39-46.
- Zhong W, Huang S, Chen H, Sun H, Cai B, Liu Y, *et al.* Pure spinal epidural cavernous hemangioma. *Acta Neurochir (Wien)* 2012;154:739-45.
- Khalatbari MR, Abbassioun K, Amirjmschidi A. Solitary spinal epidural cavernous angioma: Report of nine surgically treated cases and review of the literature. *Eur Spine J* 2013;22:542-7.
- Feng J, Xu YK, Li L, Yang RM, Ye XH, Zhang N, *et al.* MRI diagnosis and preoperative evaluation for pure epidural cavernous hemangiomas. *Neuroradiology* 2009;51:741-7.
- Frankel HL, Hancock DO, Hyslop G, Melzak J, Michaelis LS, Ungar GH, *et al.* The value of postural reduction in the initial management of closed injuries of the spine with paraplegia and tetraplegia. I. Paraplegia 1969;7:179-92.
- Nagi S, Megdiche H, Bouzaïdi K, Haouet S, Khouja N, Douira W, *et al.* Imaging features of spinal epidural cavernous malformations. *J Neuroradiol* 2004;31:208-13.
- Hatiboglu MA, Iplikcioglu AC, Ozcan D. Epidural spinal cavernous hemangioma. *Neurol Med Chir (Tokyo)* 2006;46:455-8.
- Cho JH, Chung YN, Wang KC, Cho BK. Spinal cavernous hemangioma causing sudden paraplegia in a 23-month-old kid. *J Korean Neurosurg Soc* 2006;40:273-6.
- Liou DC, Chou JM. MRI of primary spinal epidural lymphoma: Case report. *Chin J Radiol* 2007;32:147-51.
- Caruso G, Galarza M, Borghesi I, Pozzati E, Vitale M. Acute presentation of spinal epidural cavernous angiomas: Case report. *Neurosurgery* 2007;60:E575-6.
- Floeth F, Riemenschneider M, Herdmann J. Intralesional hemorrhage and thrombosis without rupture in a pure spinal epidural cavernous angioma: A rare cause of acute lumbal radiculopathy. *Eur Spine J* 2010;19 Suppl 2:S193-6.
- Inoue T, Koga H, Abe M, Tabuchi K. Solitary spinal epidural cavernous haemangioma presenting as acute epidural haematoma. *J Clin Neurosci* 1995;2:265-8.
- Minh NH. Cervicothoracic spinal epidural cavernous hemangioma: Case report and review of the literature. *Surg Neurol* 2005;64:83-5.
- Shin JH, Lee HK, Rhim SC, Park SH, Choi CG, Suh DC. Spinal epidural cavernous hemangioma: MR findings. *J Comput Assist Tomogr* 2001;25:257-61.
- Appiah GA, Knuckey NW, Robbins PD. Extradural spinal cavernous haemangioma: Case report and review of the literature. *J Clin Neurosci* 2001;8:176-9.
- Badinand B, Morel C, Kopp N, Tran Min VA, Cotton F. Dumbbell-shaped epidural capillary hemangioma. *AJNR Am J Neuroradiol* 2003;24:190-2.
- Talacchi A, Spinnato S, Alessandrini F, Iuzzolino P, Bricolo A. Radiologic and surgical aspects of pure spinal epidural cavernous angiomas. Report on 5 cases and review of the literature. *Surg Neurol* 1999;52:198-203.
- Sarikaya-Seiwert S, Gierga K, Wessalowski R, Steiger HJ, Hanggi D. Solitary spinal epidural cavernous angiomas in children presenting with acute neurological symptoms caused by hemorrhage. *J Neurosurg Pediatr* 2010;5:89-93.
- Shapiro GS, Millett PJ, DiCarlo EF, Mintz DN, Gamache FW, Rawlins BA. Spinal epidural hemangioma related to pregnancy. *Skeletal Radiol* 2001;30:290-4.