

# Selective Laparoscopic Approach in Suspected Gallbladder Malignancy

G. Paul Wright, MD, Arida Siripong, MD, Michael D. Winton, BS, Eric J. Mitchell, MD, Brent J. Goslin, MD, Mathew H. Chung, MD

## ABSTRACT

**Background and Objectives:** We examined patients with clinical findings that are concerning for gallbladder malignancy to determine the incidence of pathology-confirmed malignancy and to discover factors that may be used to determine which patients may be initially treated with a laparoscopic approach.

**Methods:** All patients referred to a surgical oncologist with preoperative findings that are concerning for gallbladder malignancy who had not undergone previous surgical resection from 2005 to 2011 were reviewed. Variables collected included demographics, imaging, operative findings, and final pathology. Patients were grouped into 3 categories based on preoperative findings: gallbladder mass, irregular wall thickening, and abnormal intraoperative findings on previous diagnostic laparoscopy.

**Results:** Twenty-nine of 4474 patients evaluated for gallbladder pathology during the study period met the inclusion criteria. Preoperative imaging included computed tomography, ultrasonography, and magnetic resonance imaging. Twelve patients had multiple imaging studies. Eight patients were initially treated with a laparoscopic approach with 3 conversions to an open procedure. Forty-eight percent of patients had pathology-confirmed malignancy. Patients without a discrete mass on imaging were more likely to have benign disease ( $P = .04$ ).

**Conclusions:** Our results demonstrate that >50% of patients with suspicious preoperative findings had benign pathology, suggesting that the initial laparoscopic approach in selected patients may be appropriate.

**Key Words:** Gallbladder disease, Gallbladder neoplasm, Laparoscopy.

## INTRODUCTION

Gallbladder cancer (GBCA) is the most common biliary tract malignancy worldwide.<sup>1</sup> Incidence rates show significant geographical variations and are higher in women, which is likely due to the link between cholelithiasis and GBCA.<sup>2</sup> While early diagnosis is beneficial, symptoms are usually indicative of advanced disease. The overall 5-year survival rate remains dismal at 5% and improves to only 20% in patients who are candidates for surgical resection.<sup>3</sup>

Approximately 50% of GBCA cases are discovered incidentally either during or following laparoscopic cholecystectomy for suspected benign gallbladder disease.<sup>4</sup> The remaining cases are classified as nonincidental GBCA and may be identified by a variety of imaging modalities. Ultrasonographic (US) findings that are concerning for malignancy include irregular wall thickening >1 cm, polypoid lesions >1 cm, or the presence of a mass that does not change with movement. Computed tomography (CT) offers the added benefit of assessing hepatic invasion, metastatic disease, and regional lymphadenopathy to serve as an aid in treatment planning. Despite their common uses, the positive predictive value for malignancy detection in suspected GBCA for US and CT have been reported to be only 63.4% and 67.7%, respectively.<sup>5</sup> Magnetic resonance imaging (MRI) may provide some additional benefit in determining hepatic invasion.<sup>6</sup> Modalities such as positron emission tomography and endoscopic US are other potential options in the diagnostic workup of GBCA.

When patients are referred for evaluation of suspected gallbladder neoplasms, the management is often not straightforward. A standardized approach for nonincidental suspicious lesions on preoperative imaging is not well defined. A definitive preoperative diagnosis is usually unavailable due to the risk of tumor seeding with percutaneous needle biopsy. Therefore, traditional teaching suggests an open exploration with the extent of surgery being based on the operative findings. The open approach involves, at minimum, cholecystectomy with fro-

Grand Rapids Medical Education Partners/Michigan State University General Surgery Residency Program, Grand Rapids, MI, USA (Drs. Wright, Siripong, Mitchell, Goslin, and Chung).

Michigan State University College of Human Medicine, Grand Rapids, MI, USA (all authors).

Spectrum Health Medical Group, Grand Rapids, MI, USA (Drs. Mitchell and Chung).

Address correspondence to: G. Paul Wright, MD, GRMEP/MSU General Surgery Residency Program, 1000 Monroe NW, Grand Rapids, MI 49503. Telephone: 616-732-6223, Fax: 616-732-6275, E-mail: paul.wright@grmep.com

DOI: 10.4293/108680813X13693422519352

© 2013 by JSLS, *Journal of the Society of Laparoendoscopic Surgeons*. Published by the Society of Laparoendoscopic Surgeons, Inc.

zen section analysis or formal radical cholecystectomy. This, however, may subject patients with benign disease to a more extensive resection than is necessary. While we continue to use an open approach to gallbladder neoplasms with suspected hepatic invasion, our contemporary practice has been a laparoscopic approach in patients where hepatic invasion is not apparent. Thus, we sought to examine patients with preoperative findings that are concerning for gallbladder malignancy who had not undergone previous surgical resection to determine the rate of pathology-confirmed malignancy and to identify predictive factors for patients who may benefit from an initial laparoscopic approach.

### MATERIALS AND METHODS

This study used a retrospective cohort design. The study period was from July 1, 2005, to June 30, 2011, at a university-affiliated community hospital that serves as a tertiary referral center for the region. All patients referred to a single hepatobiliary-focused surgical oncologist for suspected gallbladder malignancy who had not undergone previous surgical resection were reviewed. All procedures were performed in a single stage by the study surgeon. Three patients who underwent previous diagnostic laparoscopy by a community general surgeon without surgical resection were included. In all 3 cases, a grossly abnormal gallbladder was observed, and subsequently a referral was made to the study surgeon. Consecutive patients without signs of hepatic invasion were treated with a laparoscopic approach and use of intraoperative US. Operative notes were reviewed including the techniques for surgery and intraoperative findings. Additionally, imaging results from the eligible patients were reviewed in detail.

Patients with findings that are concerning for gallbladder malignancy according to interpretation by a radiologist in the formal report were included for study. Variables recorded for these patients included demographics, types of imaging used, descriptions of the suspicious findings, surgical approaches, operative findings, and final pathologic diagnoses. Preoperative suspicious findings were grouped into 3 categories: gallbladder mass, irregular wall thickening, and grossly abnormal intraoperative findings on a previous diagnostic laparoscopy. Staging of malignant lesions was determined based on the *AJCC Cancer Staging Manual* (seventh edition). The primary outcome measure was defined as the incidence of pathology-confirmed malignancy. Statistical significance for respective variables was determined by  $P < .05$  using 2-tailed Fisher exact tests.

### RESULTS

A total of 4474 patients underwent cholecystectomy at our institution during the study period. Twenty-nine patients met the study inclusion criteria. Patient demographics and preoperative information are listed in **Table 1**. Most patients were referred for a gallbladder mass or irregular wall thickening. Three patients were referred after diagnostic laparoscopy that was performed by a community general surgeon demonstrated abnormal gross appearance of the gallbladder. One patient had a biopsy performed during the diagnostic laparoscopy that was negative for malignancy, while the other 2 patients had no intervention performed prior to referral. Most patients were evaluated with CT and 33% had MRI studies. Twelve patients had more than one type of imaging study performed, and 4 patients had all 3 studies.

All patients underwent definitive surgical treatment by the study surgeon alone. Details of the surgical procedures performed can be found in **Figure 1**. Seventy-two percent of patients were treated initially with an open surgical approach. Of this group, 4 patients were found to have unresectable disease intraoperatively and were treated with biopsy and palliation as indicated.

Patients treated with an initial laparoscopic approach are detailed in **Table 2**. Of the 8 patients treated with an initial laparoscopic approach, 3 were converted to an open

**Table 1.**  
Patient Characteristics

	n	Median (range)
Age, y		70 (23–90)
Sex		
M	14	
F	15	
BMI, kg/m <sup>2</sup>		28.8 (19.1–40.5)
Reason for referral		
Gallbladder mass	21	
Irregular wall thickening	5	
Previous intraoperative abnormality	3	
Imaging		
CT	25	
Ultrasound	11	
MRI	9	

CT, computed tomography; F, female; M, male; MRI, magnetic resonance imaging.

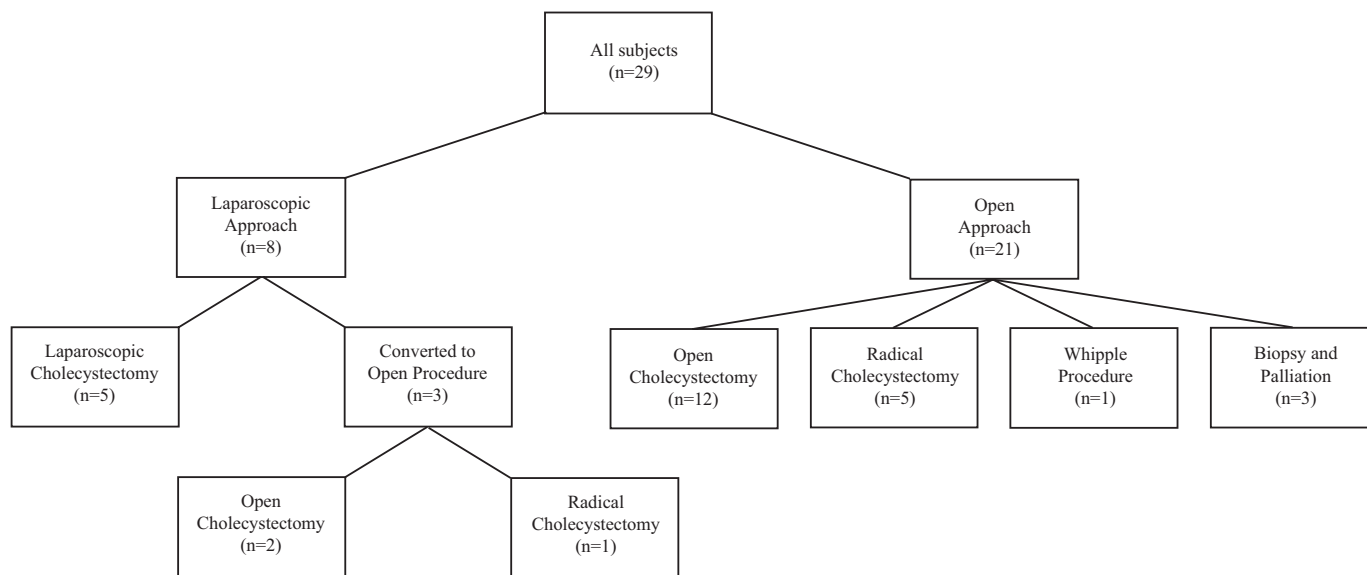


Figure 1. Surgical details.

Table 2. Patients Treated With Initial Laparoscopic Approach

Patient	Age, y	Sex	Preoperative Findings	Final Procedure	Pathology	Stage
1	76	M	Gallbladder mass	Palliative	Adenocarcinoma	IIIA
2	59	F	Gallbladder mass	OC	Xanthogranulomatous cholecystitis	—
3	70	F	Gallbladder mass	RC	Chronic cholecystitis	—
4	51	F	Gallbladder mass	LC	Adenomyoma	—
5	87	M	Gallbladder mass	LC	Chronic cholecystitis	—
6	67	M	Gallbladder mass	LC	Metastatic melanoma	IV
7	80	F	Irregular wall thickening	LC	Adenomyoma	—
8	23	F	Abnormal intraoperative findings	LC	Chronic cholecystitis with pseudocyst	—

LC, laparoscopic cholecystectomy; OC, open cholecystectomy; RC, radical cholecystectomy; other abbreviations as in Table 1.

procedure. Two conversions were due to a severe inflammatory reaction, making safe dissection difficult, while one conversion was performed over concern for hepatic invasion on intraoperative US. This patient had locally advanced disease that was unresectable and a palliative procedure was performed.

Patient diagnoses are found in Table 3, with 14 malignant and 15 benign findings following surgical treatment. Most the malignant findings were adenocarcinomas, and further breakdown including staging is listed in Table 4. The most common benign finding was chronic cholecystitis.

Variables analyzed to determine predictive factors of benign pathologic findings were age, body mass index, sex,

and performance of MRI. None of these factors demonstrated a significant impact. Due to the small sample size, patients who presented with either irregular wall thickening or abnormal intraoperative findings on diagnostic laparoscopy were grouped and compared against those with a discrete mass. Lack of a discrete mass on preoperative imaging was a significant predictor of benign disease on final pathology ( $P = .04$ ).

### DISCUSSION

The standard initial radiologic examination in patients with symptoms of right upper quadrant pain or jaundice is US. This relatively inexpensive study has been demon-

**Table 3.**  
Final Surgical Pathology

	n
Classification	
Malignant	14
Benign	15
Malignant diagnoses	
Adenocarcinoma	11
Neuroendocrine carcinoma	2
Malignant melanoma	1
Benign diagnoses	
Chronic cholecystitis	9
Adenomyoma	3
Diverticulosis	2
Xanthogranulomatous cholecystitis	1

strated to have a sensitivity of 85% and accuracy of 80% for the diagnosis of GBCA, though the positive predictive value remains much lower. CT offers the added benefit of assessing local invasion, metastatic disease, and the regional lymph node basin.<sup>6</sup> Though nearly all patients had preoperative analysis with CT, >50% had benign disease. MRI has also been shown to be useful in assessing biliary tract malignancies. At our institution, it has been primarily used for lesions that are difficult to define with the use of other conventional modalities. However, the performance of MRI among our patients did not correlate with final pathologic findings ( $P = .25$ ).

This study reviewed 29 patients referred to a single hepatobiliary-focused surgical oncologist with clinical findings that are concerning for GBCA who had not undergone previous surgical resection. Over 50% of these patients had benign findings on final pathology. In total, 8 patients underwent an initial laparoscopic approach. Three were converted to an open procedure due to either suspicion for hepatic invasion on intraoperative US or significant inflammation surrounding the gallbladder precluding a safe dissection. Five patients had a completed laparoscopic procedure as intraoperative US revealed no signs of local invasion. Four of these 5 patients had benign disease on final pathology. One patient had metastatic melanoma that was suspected preoperatively, and a cholecystectomy was performed as a palliative procedure. Another patient had a locally advanced GBCA with hepatic invasion, extension proximally onto the common bile duct, and involvement of the hepatic flexure. An en bloc resection was performed that included a Whipple

procedure, segmental colon resection, and standard radical cholecystectomy to achieve an R0 resection without tumor spillage.

A low threshold must be used for identifying potentially malignant findings as a missed or incorrect diagnosis can bring significant harm to the patient. In our study, 13 of 21 patients with a discrete mass seen on imaging were found to have a malignancy. Five patients had irregular gallbladder wall thickening, and all of these were found to have benign disease on final pathology (4 with chronic cholecystitis, 1 with adenomyoma). Three patients were referred for a grossly abnormal gallbladder on previous diagnostic laparoscopy, and only one was found to have malignant disease on pathology following surgical resection, a neuroendocrine carcinoma. Despite the low number of subjects in our study, reasonable suspicion of benign disease should be considered in patients presenting with irregular gallbladder wall thickening.

The management of incidental GBCA has been well defined in large series.<sup>7-9</sup> In patients with T1a lesions, cholecystectomy is considered curative treatment. While the management of T1b lesions remains controversial, patients with T2 or greater lesions that are amenable to resection should be taken for completion radical cholecystectomy with lymph node dissection.<sup>10</sup>

The treatment of patients with nonincidental, abnormal preoperative findings that are concerning for gallbladder malignancy is not as clear. The practice at our institution had been a traditional open procedure. After several open procedures based on surgeon preference early in our experience, however, many patients had benign findings leading to questions regarding the most appropriate initial technique. Following this, 8 consecutive patients without obvious hepatic invasion on preoperative imaging were treated with a laparoscopic approach safely and successfully. Our practice now includes diagnostic laparoscopy with intraoperative US on all patients with preoperative imaging findings that are suspicious for gallbladder malignancy. There is little evidence in the surgical literature to suggest a uniform approach.

Cho et al<sup>11</sup> performed a single-institution prospective study to determine the safety and feasibility of using a laparoscopic approach in 36 patients with suspected early-stage gallbladder carcinomas. Intraoperative US was used to assess for liver invasion, and in 6 cases, the procedure was converted to open once invasion was detected. A complete laparoscopic approach was used in 83% of patients. Twelve patients had benign findings on frozen sections, and treatment was halted at a cholecystectomy.

**Table 4.**  
Malignant Diagnoses

	Age, y	Sex	Preoperative Finding	Surgery	Pathology	Pathologic Stage
1	67	M	Gallbladder mass	LC	Malignant melanoma	IV
2	77	M	Gallbladder mass	OC	Adenocarcinoma	II
3	53	M	Gallbladder mass	RC	Neuroendocrine carcinoma	—
4	60	F	Gallbladder mass	RC	Adenocarcinoma	IIIB
5	75	F	Gallbladder mass	RC	Adenocarcinoma	IIIB
6	82	F	Gallbladder mass	RC	Adenocarcinoma	IVB
7	68	F	Gallbladder mass	RC	Adenocarcinoma	0
8	71	F	Gallbladder mass	Extended Whipple	Adenocarcinoma	IIIB
9	76	M	Gallbladder mass	Palliative	Adenocarcinoma	IIIA
10	59	M	Gallbladder mass	Palliative	Adenocarcinoma	IIIA
11	90	M	Gallbladder mass	Palliative	Adenocarcinoma	—
12	82	F	Gallbladder mass	Palliative	Adenocarcinoma	—
13	67	M	Gallbladder mass	Palliative	Adenocarcinoma	—
14	70	F	Intraoperative abnormality	OC	Neuroendocrine carcinoma	—

Abbreviations as in Tables 1 and 2.

For the remaining 18 patients who had a malignancy confirmed on frozen section, a laparoscopic lymph node dissection was performed. Resection of hepatic segments IVB and V was not performed in patients with T2 tumors. Their excellent preliminary results for disease-free survival pose an interesting contrast to the current treatment paradigm.

The results of the current study and that of Cho et al<sup>11</sup> suggest that many patients with suspicious findings on preoperative imaging have benign disease. An open cholecystectomy in these patients is unnecessary and is associated with increased pain, hospital length of stay, and wound complications.<sup>12,13</sup> We sought to define factors that indicated the likelihood of benign disease to determine which patients may be safely approached laparoscopically. Our data suggest that patients presenting with findings other than a discrete mass on preoperative evaluation at our institution demonstrate an increased likelihood of benign disease. In patients where hepatic invasion is confirmed or highly suspected on preoperative imaging or intraoperative US, an open approach should be the procedure of choice.

Laparoscopic treatment of suspected GBCA is not without potential complications. Biliary spillage from gallbladder perforation in the setting of a carcinoma may result in dissemination of a potentially curable lesion.<sup>14</sup> In addition,

port site recurrence has been documented in up to 20% of patients with GBCA discovered following laparoscopic cholecystectomy.<sup>15,16</sup> However, more recent data have demonstrated that this is less of a concern, especially when the specimen is removed with an endoscopic retrieval bag. We have found in our experience that this is not a significant clinical entity and do not routinely perform port site resection in patients with incidental GBCA. Another concern for wide adoption of a laparoscopic approach is the advanced laparoscopic expertise necessary to perform intraoperative US as suggested by Cho et al,<sup>11</sup> something that is not a part of every surgeon's armamentarium. Pursuit of a minimally invasive approach should not have priority over safety or performance of an adequate oncologic resection. Further data regarding the safety and efficacy of laparoscopic radical cholecystectomy may impact this management strategy in the future.<sup>17,18</sup>

This study is not without limitations. The small sample size at a single institution limits the conclusions that can be ascertained. While a laparoscopic approach in suspected gallbladder malignancy is not novel, this study provides further support to supplement the existing evidence on this rare issue. Radiologic interpretation is examiner-dependent, as is the acquisition of the images from US technicians. Each respective imaging study may

not convey the same level of suspicion by the radiologist or surgeon, something that is difficult to quantify. Furthermore, a retrospective model magnifies these limitations. With the growing body of evidence demonstrating the utility of laparoscopic intraoperative US in suspected gallbladder malignancy, a systematic review and meta-analysis would help add further clarity to this topic.

## CONCLUSIONS

An initial laparoscopic approach is a safe alternative to the traditional standard procedure in select patients with preoperative findings that are concerning for gallbladder malignancy where suspicion for hepatic invasion is low. This series highlights the benefit of this approach in patients presenting with irregular gallbladder wall thickening, as most will have cholecystitis, thereby allowing a safe laparoscopic cholecystectomy without the concern for tumor spillage. In patients with a discrete mass, this approach may be used but with a very low threshold for conversion to an open procedure as there remains a higher likelihood of malignancy. Future studies using a multi-institutional prospective model may be required to definitively answer the questions posed by these results.

## References:

1. Eslick G. Epidemiology of gallbladder cancer. *Gastroenterol Clin N Am*. 2010;39(2):307–330.
2. Gourgiotis S, Kocher HM, Solaini L, Yarollahi A, Tsiambas E, Salemis NS. Gallbladder cancer. *Am J Surg*. 2008;196(2):252–264.
3. Mayo SC, Shore AD, Nathan H, et al. National trends in the management and survival of surgically managed gallbladder adenocarcinoma over 15 years: a population-based analysis. *J Gastrointest Surg*. 2010;14(10):1578–1591.
4. Duffy A, Capanu M, Abou-Alfa GK, et al. Gallbladder cancer (GBC): 10-year experience at Memorial Sloan-Kettering Cancer Centre (MSKCC). *J Surg Oncol*. 2008;98(7):485–489.
5. Jang JY, Kim SW, Lee SE, et al. Differential diagnostic and staging accuracies of high resolution ultrasonography, endoscopic ultrasonography, and multidetector computed tomography for gallbladder polypoid lesions and gallbladder cancer. *Ann Surg*. 2009;250(6):943–949.
6. Rodríguez-Fernandez A, Gómez-Río M, Medina-Benítez A, et al. Application of modern imaging methods in diagnosis of gallbladder cancer. *J Surg Oncol*. 2006;93(8):650–664.
7. Kwon AH, Imamura A, Kitade H, Kamiyama Y. Unsuspected gallbladder cancer diagnosed during or after laparoscopic cholecystectomy. *J Surg Oncol*. 2008;97(3):241–245.

8. Vollmer CM. Unexpected identification of gallbladder carcinoma during cholecystectomy. *J Gastrointest Surg*. 2009;13(11):2034–2036.
9. Downing SR, Cadogan KA, Ortega G, et al. Early-stage gallbladder cancer in the Surveillance, Epidemiology, and End Results database: effect of extended surgical resection. *Arch Surg*. 2011;146(6):734–738.
10. Glauser PM, Strub D, Käser SA, Mattiello D, Rieben F, Maurer CA. Incidence, management, and outcome of incidental gallbladder carcinoma: analysis of the database of the Swiss Association of Laparoscopic and Thoracoscopic Surgery. *Surg Endosc*. 2010;24:2281–2286.
11. Cho JY, Han HS, Yoon YS, Ahn KS, Kim YH, Lee KH. Laparoscopic approach for suspected early-stage gallbladder carcinoma. *Arch Surg*. 2010;145(2):128–133.
12. Barkun JS, Barkun AN, Meakins JL. Laparoscopic versus open cholecystectomy: the Canadian experience. The McGill Gallstone Treatment Group. *Am J Surg*. 1993;165(4):455–458.
13. Berggren U, Gordh T, Grama D, Haglund U, Rastad J, Arvidsson D. Laparoscopic versus open cholecystectomy: hospitalization, sick leave, analgesia, and trauma responses. *Br J Surg*. 1994;81(9):1362–1365.
14. Wibbenmeyer LA, Wade TP, Chen RC, Meyer RC, Turgeon RP, Andrus CH. Laparoscopic cholecystectomy can disseminate in situ carcinoma of the gallbladder. *J Am Coll Surg*. 1995;181(6):504–510.
15. Z'graggen K, Birrer S, Maurer CA, Wehrli H, Klaiber C, Baer HU. Incidence of port site recurrence after laparoscopic cholecystectomy for preoperatively unsuspected gallbladder carcinoma. *Surgery*. 1998;124(5):831–838.
16. Paolucci V, Schaeff B, Schneider M, Gutt C. Tumor seeding following laparoscopy: international survey. *World J Surg*. 1999;23:989–995.
17. Gumbs AA, Hoffman JP. Laparoscopic radical cholecystectomy and Roux-en-Y choledochojejunostomy for gallbladder cancer. *Surg Endosc*. 2010;24(7):1766–1768.
18. Gumbs AA, Hoffman JP. Laparoscopic completion radical cholecystectomy for T2 gallbladder cancer. *Surg Endosc*. 2010;24(12):3221–3223.