



European Association of Urology

## Surgery in Motion: Open Science

# Functional and Oncological Outcomes of Female Pelvic Organ-preserving Robot-assisted Radical Cystectomy

Etienne Lavallée<sup>a,b,\*</sup>, Zach Dovey<sup>a</sup>, Prachee Pathak<sup>a</sup>, Linda Dey<sup>c,d</sup>, Lotta Renström Koskela<sup>c,d</sup>, Arad Hosseini<sup>c</sup>, Nikhil Waingankar<sup>a</sup>, Reza Mehrazin<sup>a</sup>, John Sfakianos<sup>a</sup>, Abolfazl Hosseini<sup>c,d</sup>, Peter Wiklund<sup>a,c,d</sup>

<sup>a</sup> Department of Urology, Icahn School of Medicine at Mount Sinai Hospital, New York, NY, USA; <sup>b</sup> Department of Surgery, Faculty of Medicine, Laval University, Québec, Canada; <sup>c</sup> Department of Pelvic Cancer, Karolinska University Hospital, Stockholm, Sweden; <sup>d</sup> Department of Molecular Medicine and Surgery, Karolinska Institutet, Stockholm, Sweden

### Article info

#### Article history:

Accepted November 8, 2021

#### Associate Editor:

Guillaume Ploussard

#### Keywords:

Bladder cancer  
Cystectomy  
Female cystectomy  
Neobladder  
Sexual function  
Urinary diversion  
Urinary function

### Abstract

**Background:** For females undergoing cystectomy and urinary diversion, decreases in sexual and urinary functions can have a significant impact on quality of life. Pelvic organ-preserving (POP) radical cystectomy (RC) has been proposed as an approach to improve postoperative functional outcomes.

**Objective:** To evaluate postoperative functional outcomes of a robotic approach for female POP RC with intracorporeal urinary diversion.

**Design, setting, and participants:** This was a multicenter retrospective study evaluating sexual, urinary, and oncological outcomes for sexually active females undergoing POP robot-assisted RC for  $\leq T2$  bladder cancer. Exclusion criteria included multifocal, trigonal, or locally advanced tumors.

**Surgical procedure:** We describe a step-by-step technique for POP robot-assisted RC with intracorporeal urinary diversion.

**Measurements:** The primary outcome of the study was evaluation of sexual and urinary functions following surgery. Oncological outcomes were evaluated as a secondary endpoint.

**Results and limitations:** Our study included 23 females who underwent POP robot-assisted RC between 2008 and 2020 with intracorporeal neobladder (87%) or ileal conduit (13%) reconstruction. The median follow-up was 20 mo. A postoperative sexual function questionnaire was completed by 15 patients (65%). Of those, 13 (87%) resumed sexual activity at a median of 6 mo after surgery. Of the patients with a neobladder, 14 (70%) achieved daytime continence and 16 (80%) achieved nighttime continence. Cancer-specific and overall survival were both 91%. The results are limited by their retrospective nature.

**Conclusions:** POP robot-assisted RC with orthotopic neobladder allows a majority of female patients to return to sexual activity after surgery. This approach should be considered for selected sexually active women.

\* Corresponding author. Department of Surgery, Faculty of Medicine, Laval University, 11, côte du Palais, Québec G1R 2J6, Canada. Tel. +1 418 9989638.  
E-mail address: [etienne.lavallee.2@ulaval.ca](mailto:etienne.lavallee.2@ulaval.ca) (E. Lavallée).



**Patient summary:** We evaluated 23 women with bladder cancer who underwent surgical removal of the bladder with preservation of their reproductive organs. Following this surgery, a majority of patients resumed sexual activity. For selected patients, this technique can be performed without compromising cancer control.

© 2021 The Authors. Published by Elsevier B.V. on behalf of European Association of Urology. This is an open access article under the CC BY-NC-ND license (<http://creativecommons.org/licenses/by-nc-nd/4.0/>).

## 1. Introduction

Cystectomy with urinary diversion is the standard treatment for muscle-invasive and for some high-risk non-muscle-invasive bladder cancers. The advances in minimally invasive robotic surgery mean that many urooncology centers now perform robot-assisted radical cystectomy (RARC) as opposed to the open technique. Bladder cancer is less common among women, but the incidence for females is still nearly 75 000 patients worldwide each year, and the cancer is often more advanced at the time of diagnosis [1,2]. The classic technique for women requires anterior exenteration, with removal of the anterior vagina, uterus, and ovaries in addition to the cystectomy and extended pelvic lymphadenectomy. Variations may include sparing of the urethra and the autonomic innervation via the pelvic nerves, as well as the genital or pelvic organs. In keeping with the principles of surgical oncology, the ultimate goal is removal of the primary tumor to maximize oncological outcomes with minimal detriment to functional outcomes [2]. Sexual dysfunction affecting health-related quality-of-life outcomes after female RARC is common, especially among younger patients, and pelvic organ-preserving RARC with orthotopic neobladder has become an increasingly common surgical option in order to preserve both postoperative sexual function and body image [3]. Pelvic organ-preserving RARC with ileal conduit diversion can also be a desirable option for certain patients. The oncological concerns associated with pelvic organ preservation relate to the risk of preoperative understaging with the potential for microscopic invasion of pelvic organs, the risk of positive margins, and the risk of local recurrence. However, a systematic review commissioned by European Association of Urology (EAU) Muscle-invasive Bladder Cancer (MIBC) Guideline Panel as part of its guideline update for 2016 demonstrated that preservation of the female pelvic organs at the time of RC with orthotopic neobladder had comparable oncological outcomes to standard RC, with better sexual and urinary functions. The limitation of the studies reviewed was their retrospective nature and relatively short-term follow-up [3]. The current version of the EAU guideline states that organ-preserving techniques can be considered for selected patients who are motivated to retain their sexual function [4]. As the technique for pelvic organ-preserving RARC evolves, the aim of this study was to describe a modern robotic approach to pelvic organ-preserving RARC with intracorporeal orthotopic neobladder and to present postoperative functional and oncological outcomes.

## 2. Patients and methods

This was a multicenter retrospective study of 23 patients undergoing pelvic organ-preserving RARC performed by two high-volume surgeons (A.H. and P.W.) from two institutions between 2008 and 2020. The inclusion criteria were sexually active females with  $\leq$ pT2, N0, M0 urothelial cancer, assessed via examination, imaging, and pathological staging, with a unifocal tumor away from the bladder base. The exclusion criteria were multifocal, trigonal, or locally advanced tumors with potential involvement of the internal genital organs. The standard exclusion for neobladder also included a positive frozen section of the urethral margin intraoperatively.

Postoperative follow-up included oncological and functional assessment every 3 mo for the first year, and every 6 mo thereafter up to year 5. Oncological surveillance included computed tomography of the chest, abdomen, and pelvis with contrast ever 6 mo in year 1, and annually thereafter. Postoperatively, patients were asked to complete a sexual function questionnaire and to rate their sexual satisfaction on a scale from 1 (unsatisfied) to 10 (very satisfied). Scores of 1–3, 4–7, and 8–10 were considered to represent low, moderate, and high levels of sexual satisfaction, respectively. Similarly, patients were asked to rate how much impact the surgery had on their body image on a scale from 1 (a lot) to 10 (not at all). Scores of 1–3, 4–7, and 8–10 were considered to represent high, moderate, and low impact on body image, respectively. Urinary function was documented in the patient record on follow-up visits. Daytime and nighttime continence were defined as the need for  $\leq$ 1 protection pad per day and  $\leq$ 1 protection pad per night, respectively.

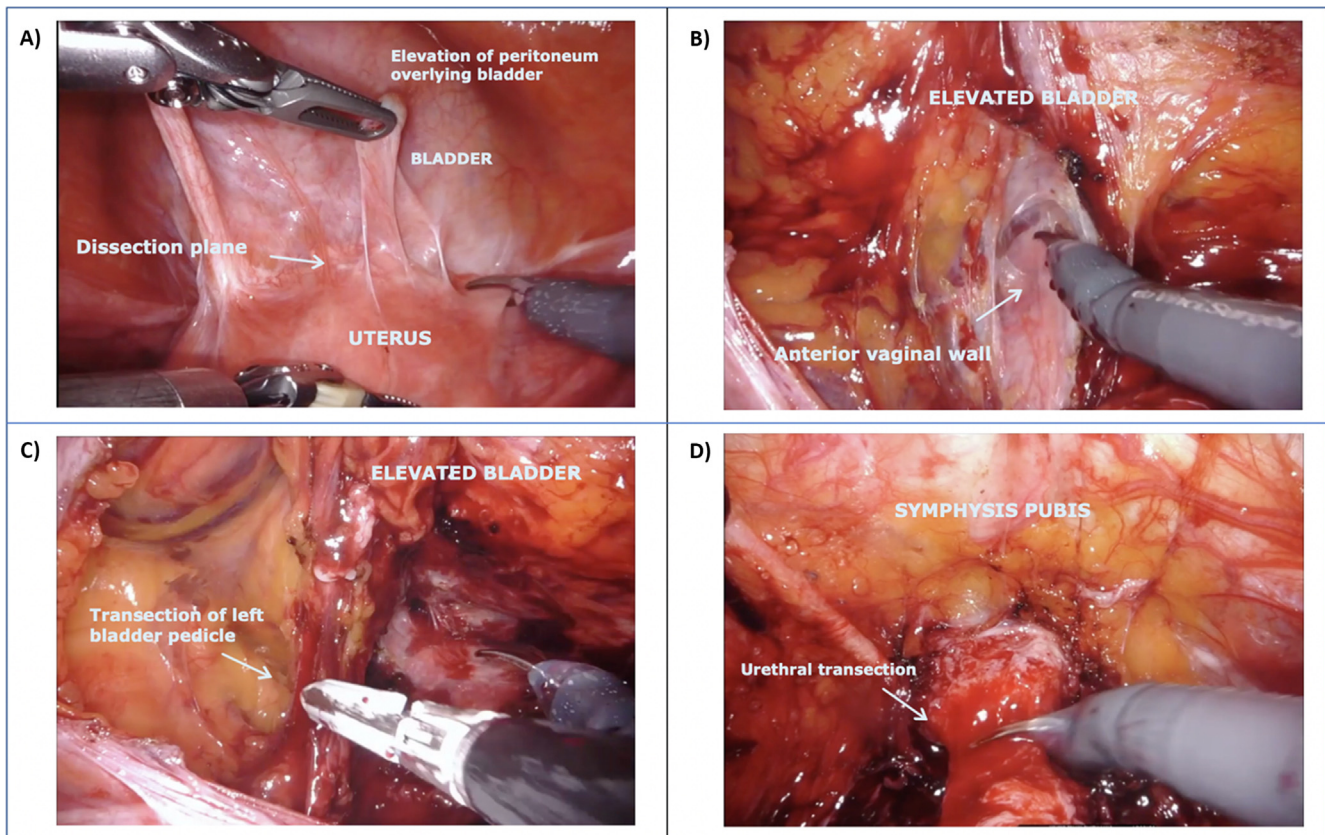
### 2.1. Surgical technique

#### 2.1.1. Patient positioning and trocar placement

After induction of general anesthesia, endotracheal intubation, and nasogastric tube placement, the patient is placed in a full Trendelenburg position, with the legs in the lithotomy position and the arms adducted. Appropriate pads are placed for limb protection. The camera port is placed 5 cm above the umbilicus using either an open Hasson [5] or a Veress needle technique. The left and right robotic ports are placed at the level of the umbilicus approximately 8 cm away from the midline. The fourth port is placed two fingerbreadths above and medial to the left anterior superior iliac spine, with a 15-mm trocar through which an 8-mm robotic port is placed. This allows removal of the fourth arm at the time of bowel stapling and introduction of the laparoscopic stapler through the 15-mm port. Assistant ports are placed between the camera and the right robotic port, laterally on the right side, two fingerbreadths above and medial to the right anterior superior iliac spine.

#### 2.1.2. Pelvic organ-preserving RARC

Figure 1 shows the steps involved. The ureters are identified and dissected distally along the side wall of the pelvis to the vesicoureteric junction, ensuring minimal handling and maintaining the blood supply intact. These are then divided between two Hem-o-lok clips. For preservation of the reproductive organs, the uterus is identified and placed



**Fig. 1 – Pelvic organ–preserving robot-assisted radical cystectomy. (A) Incision of the peritoneum at the junction between the bladder and the vagina. (B) Dissection of the plane between the bladder and the vagina. (C) Transection of the left bladder pedicle with preservation of the lateral aspect of the vagina. (D) Transection of the proximal urethra.**

under traction proximally with the fourth arm to reveal the junction between the vagina and uterus, which may be made clearer by putting a sponge in the vagina. The anterior vaginal wall is then dissected off the posterior wall of the bladder distally towards the pelvic floor. The lateral aspect of the bladder is dissected and the umbilical artery is clipped and divided near its junction with the internal iliac artery. The pedicles of the bladder are isolated and divided and the dissection is carried out distally along the lateral walls of the vagina to the proximal urethra. Care is taken to spare the endopelvic fascia. We find that partially filling the bladder with approximately 100 ml of saline during these steps can help to delineate the borders of the bladder and facilitate the dissection. Once the lateral dissection is complete, the urachus and the medial abdominal ligaments are divided near the umbilicus. The bladder is dissected off the under surface of the anterior abdominal wall down to the dorsal vein of the clitoris beneath the pubis. This is then fulgurated with bipolar forceps and divided, making sure to preserve the pubourethral ligaments. The urethra is dissected circumferentially and ligated proximally with a barbed suture in order to avoid urine spillage in the abdomen. The urethra is incised and the cystectomy specimen is placed in a bag. Before moving on to the reconstruction phase of the surgery, bilateral extended pelvic lymphadenectomy is performed and the left ureter is tunneled under the sigmoid mesentery to the right side.

### 2.1.3. Neobladder

Figure 2 shows the steps for neobladder construction.

**2.1.3.1. Urethroileal anastomosis.** The technique for neobladder begins with the urethroileal anastomosis. The ileum is mobilized and brought down into the pelvis at least 25–30 cm from the ileocecal junction. Anal-

ogous to the posterior urethral reconstruction commonly performed in prostatectomy referred to as the “Rocco stitch”, some ileal serosa close to the mesenteric border is sutured to the suburethral tissues to approximate the ileum and the urethra, thus allowing for a tension-free anastomosis [6,7]. A 1-cm sharp incision is then made in the ileum and the urethroileal anastomosis is completed in a running fashion with a resorbable barbed suture.

**2.1.3.2. Isolation of limbs for the ileal neobladder and detubularization.** The next step is isolation of 50 cm of ileum with the laparoscopic stapler, 10 cm distal the urethroileal anastomosis on the right side of the pelvis, and 40 cm proximal to the urethroileal anastomosis on the left side of the pelvis. Bowel continuity is then restored using a stapled side-to-side anastomosis. The 10-cm segment of ileum on the right side of the pelvis and the 30 cm of ileum immediately proximal to the urethroileal anastomosis are then detubularized on the anti-mesenteric border, leaving an intact 10-cm “chimney” at the proximal end of the left ileal limb.

**2.1.3.3. Orthotopic neobladder formation with ureteric anastomoses and neobladder closure.** At this point in the reconstruction, the left limb now has a 10-cm chimney proximally and 30 cm of detubularized bowel distally, while the 10-cm right limb is completely detubularized. Seroserosus stay sutures are initially placed to position the ileal segments and facilitate neobladder reconstruction. Three stay sutures are placed to approximate both detubularized ileal limbs while creating a “dog ear” with the excess ileum on the left side near the anastomosis. The first stay suture is placed to join the distal end of the right limb and the left limb just distal to the chimney. A second set of stay sutures is then placed on the adjoining serosa after folding the distal 20 cm of the left

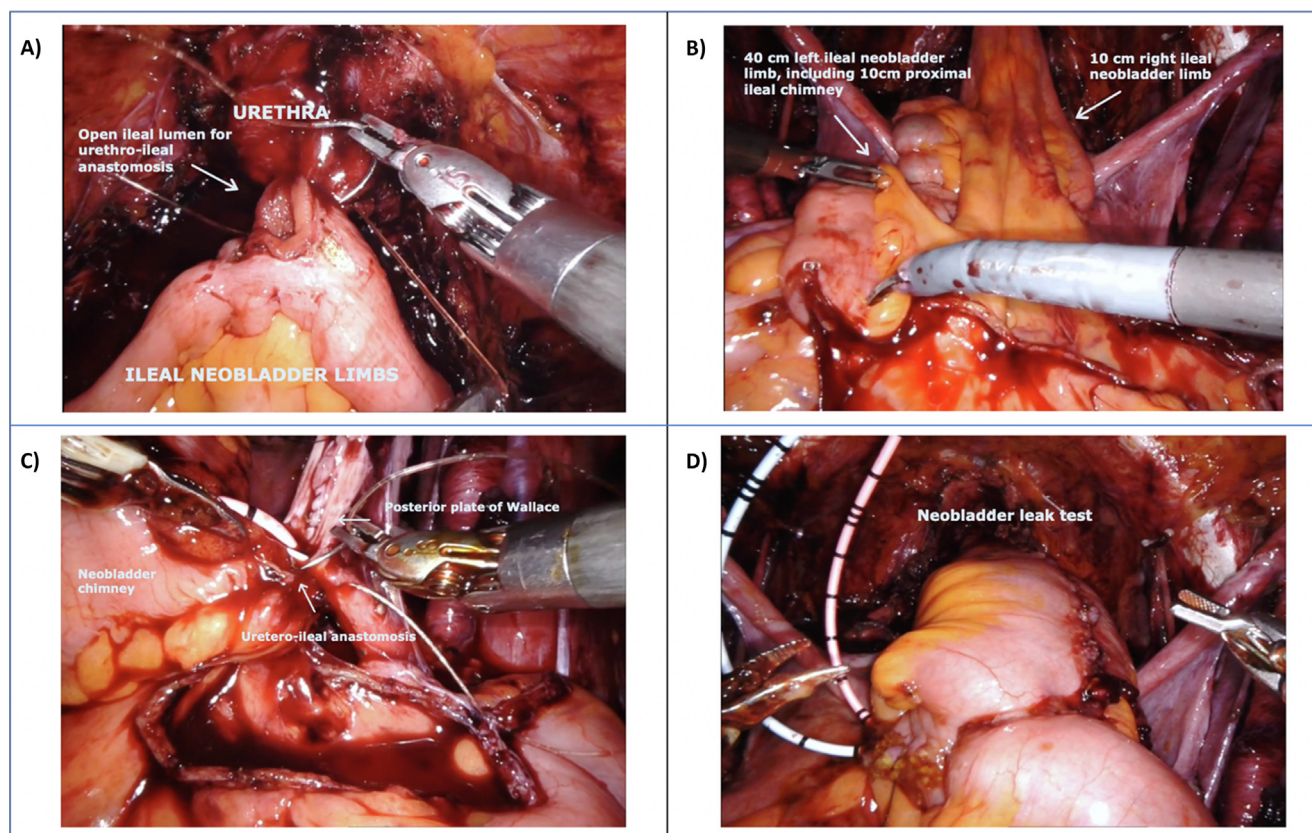
ileal neobladder limb laterally, creating two lateral limbs near the urethroileal anastomosis that will form the “dog ear”. The third stay suture is placed at the apex of the “dog ear”. Running barbed sutures are then used to close the posterior plates through the seromuscular tissue, avoiding the mucosa. The two left-lower 10-cm limbs are then folded up to create a spherical neobladder. A urethral catheter is installed under direct vision before the anterior wall of the neobladder is closed to ensure that it is adequately positioned. Before completing the ureteroenteric anastomosis, ureteral stents are placed in each ureter and brought out transcutaneously in the suprapubic region. The ureteroenteric anastomosis is performed between the open end of the neobladder “chimney” and both ureters in a Wallace-type anastomosis [8]. Closure of the anterior surface of the neobladder is completed and the neobladder is filled to approximately 100 ml to test for leaking.

### 3. Results

We reviewed the results for 23 female patients who underwent pelvic organ–preserving RARC between 2008 and 2020 at the authors’ institutions. Of those, 20 patients (87%) underwent pelvic organ–preserving RARC with orthotopic neobladder and three (13%) underwent pelvic organ–preserving RARC with ileal conduit. The median patient age at the time of surgery was 54 yr and the median follow-up was 20 mo. The median operative time was 300 min and the median estimated blood loss was 100 ml. Complete clinical patient characteristics are presented in Table 1.

Patients were asked to complete a sexual function survey at last follow-up and results were available for 15 patients (65%). Of the respondents, 14 (93%) reported having at least intermittent thoughts about sex and 13 (87%) were sexually active after surgery either with self-stimulation or penetrative intercourse. Of the 13 patients who were sexually active after surgery, one (8%), seven (54%), and five (38%) had a low, moderate, and high level of sexual satisfaction, respectively. All sexually active patients after surgery were able to have orgasms during sexual activity. The median time to resumption of sexual activity after surgery was 6 mo, with three patients (25%) resuming activity within 3 mo postoperatively. The frequency of sexual activity after surgery is presented in Figure 3. Of the ten patients engaging in penetrative intercourse, nine (90%) either never (70%) or rarely (20%) experienced pain during penetration, while one patient (10%) experienced occasional pain. Patients with neobladder reconstruction were asked about the impact of surgery on their body image. Of the 13 patients who responded, nine (69%), three (23%), and one (8%) indicated that the surgery had a low, moderate, and high impact on their body image, respectively.

Urinary function was evaluated for the 20 patients who underwent orthotopic neobladder. The results are presented in Table 2. Of note, 14 patients (70%) achieved daytime continence (0–1 pad per day) and 16 (80%) achieved nighttime continence (0–1 pads per night). Half of the



**Fig. 2** – Orthotopic neobladder reconstruction. (A) Posterior aspect of the urethroileal anastomosis. (B) Isolation of a segment of ileum extending 40 cm proximal and 10 cm distal to the urethroileal anastomosis. Preserved round ligaments can be seen extending outwards bilaterally. (C) Wallace ureteroileal anastomosis at the proximal end of the neobladder chimney. (D) Leak test performed on the completed neobladder.

**Table 1 – Patient characteristics**

Parameter	Result	N
Median age at surgery, yr (range)	54 (34–79)	23
Median body mass index, kg/m <sup>2</sup> (range)	23.6 (18.2–33.1)	
Smoking status, n (%)		23
Never smoked	4 (17)	
Former smoker	7 (30)	
Current smoker	12 (52)	
American Society of Anesthesiologists score, n (%)		23
1	5 (22)	
2	13 (57)	
3	5 (22)	
Prior bacillus Calmette–Guérin therapy, n (%)	7 (30)	23
Clinical stage, n (%)		23
Tis/Ta/T1	10 (43)	
T2	13 (57)	
T3	0	
T4	0	
Neoadjuvant chemotherapy, n (%)	13 (57)	23
pT stage, n (%)		23
T0	11 (48)	
Tis/Ta/T1	2 (9)	
T2	7 (30)	
T3	3 (13)	
T4	0	
pN stage, n (%)		22
pN0	19 (86)	
pN1	3 (14)	
Positive margin, n (%)	1 (4) <sup>a</sup>	23
Median operating time, min (range)	300 (250–390)	21
Median blood loss, ml (range)	100 (10–600)	23
Urinary diversion, n (%)		23
Ileal conduit	3 (13)	
Neobladder	20 (87)	
Median hospital stay, d (range)	6 (3–16)	23
Surgical complications, n (%)		23
Grade 2	8 (35)	
Grade 3–5	0 (0)	
Median follow-up, mo (range)	20 (7–151)	23
Disease recurrence, n (%)	4 (17)	23
Median time to disease recurrence, mo (range)	13 (11–28)	4
Disease-specific mortality, n (%)	2 (9) <sup>b</sup>	23

<sup>a</sup> One patient had a positive left ureteral margin.

<sup>b</sup> Two patients died of recurrent bladder cancer, one at 20 mo and one at 36 mo after surgery.

**Table 2 – Urinary function following surgery for the 20 patients with neobladder reconstruction**

Parameter	Patients, n (%)
Pad use per day	
0–1 pads	14 (70)
2–4 pads	4 (20)
≥5 pads	2 (10)
Nighttime continence <sup>a</sup>	
Yes	16 (80)
No	4 (20)
Need for clean intermittent catheterization	
Yes	10 (50)
No	10 (50)

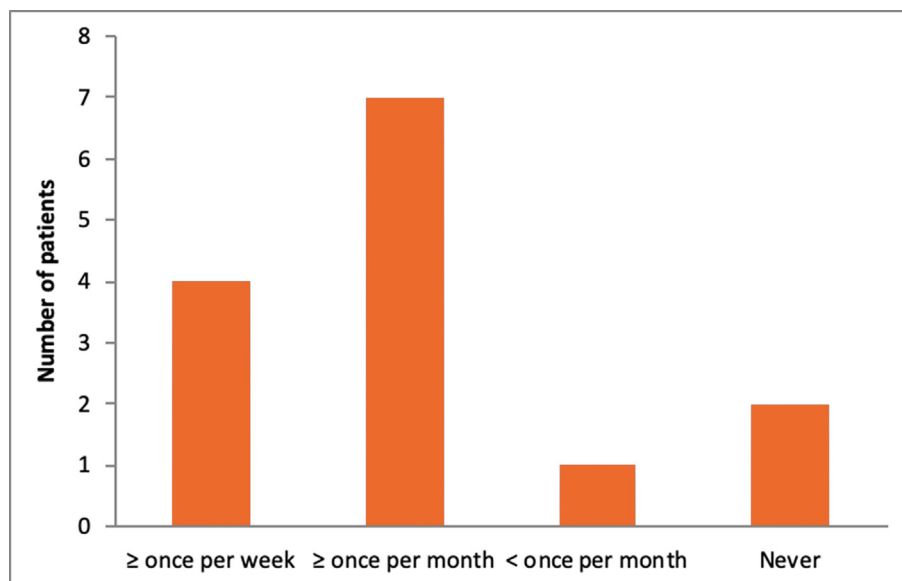
<sup>a</sup> Nighttime continence was defined as ≤1 protection pads per night.

patients had to perform daily clean intermittent catheterization.

One patient had a positive surgical margin that was identified at the left ureteral margin. This was not felt to be related to pelvic organ preservation. The median hospital stay was 6 d and eight patients (35%) had grade 1 or grade 2 complications. No patient experienced a grade 3–5 complication. Four patients (17%) eventually developed disease recurrence at a median of 13 mo after surgery and two patients died of recurrent bladder cancer 20 and 36 mo after surgery. Recurrence-free survival, cancer-specific survival, and overall survival were 83%, 91%, and 91%, respectively. Complete postoperative clinical information is presented in [Table 1](#).

#### 4. Discussion

Sexual dysfunction after standard RC can have a negative impact on a patient's quality of life. Although this has been deemed particularly relevant to younger patients, older women may also wish to remain sexually active. This study has demonstrated the use of a modern robotic technique for pelvic organ-preserving RARC that can allow women of all



**Fig. 3 – Frequency of sexual activity (penetration or self-stimulation) reported following surgery.**

ages to remain sexually active. The combination of pelvic organ-preserving RARC with intracorporeal orthotopic neobladder also confers satisfactory urinary function.

Patient selection and adequate preoperative clinical staging are important to limit the risk of positive surgical margins. Previous studies of women undergoing neobladder have shown urethral recurrence rates of 0.6–4.3% [9–11]. A more recent systematic review specifically assessing pelvic organ-preserving RC and orthotopic neobladder found a local recurrence rate of 0–13% [3]. Preoperative exclusion criteria for this patient cohort included tumors of the bladder base, the presence of carcinoma in situ, clinical stage cT3 with or without hydronephrosis, and suspicion of positive nodal disease. Previous multicenter studies on standard RC in nearly 900 patients have shown 5-yr recurrence-free survival and cancer-specific survival of 58% and 66%, respectively [12]. In the review by Veskimäe et al [3] of pelvic organ-preserving RARC for a pool of 197 patients, albeit with shorter follow-up (3 yr), recurrence-free survival and cancer-specific survival were 87–100% and 70–100%, respectively. Our cohort again compares favorably, with recurrence-free survival of 83% and cancer-specific survival of 91%. In our cohort, one patient had a positive surgical margin that was identified at the level of the left ureteral margin. The ureteral dissection is not influenced by the decision to perform an organ-preserving procedure, as it is done in the exact same manner as in a standard cystectomy; hence, it is felt that this was not a consequence of organ preservation.

Technically, leaving the vagina intact with nerve and vascular preservation has been suggested as a factor motivating patients to return to sexual activity [10], with maintenance of body image being a contributing factor. This is in line with the postoperative sexual function observed in our cohort.

We acknowledge that our analysis has some limitations. The retrospective nature of the study and the small number of patients evaluated are inherent limitations. The lack of a formal preoperative sexual function assessment using standardized questionnaires and the possibility of selection bias represent other limitations.

## 5. Conclusions

The results of this study confirm that in selected patients, pelvic organ-preserving RARC with orthotopic neobladder or ileal conduit allows a return to sexual activity after surgery while not compromising oncological outcomes. This approach should be considered for sexually active females undergoing cystectomy for a unifocal bladder tumor not involving the trigone and without clinical signs of extravascular extension.

**Author contributions:** Etienne Lavallée had full access to all the data in the study and takes responsibility for the integrity of the data and the accuracy of the data analysis.

*Study concept and design:* Wiklund, Pathak, Dovey, Mehrazin, Sfakianos, Hosseini, Lavallée, Wainganskar.

*Acquisition of data:* Pathak, Dey, Renström Koskela, Lavallée, Hosseini.

*Analysis and interpretation of data:* Lavallée, Wiklund.

*Drafting of the manuscript:* Lavallée.

*Critical revision of the manuscript for important intellectual content:* Wiklund, Hosseini, Sfakianos, Mehrazin, Wainganskar, Renström Koskela.

*Statistical analysis:* Lavallée.

*Obtaining funding:* None.

*Administrative, technical, or material support:* None.

*Supervision:* Wiklund.

*Other (video editing):* Dovey.

**Financial disclosures:** Etienne Lavallée certifies that all conflicts of interest, including specific financial interests and relationships and affiliations relevant to the subject matter or materials discussed in the manuscript (eg, employment/affiliation, grants or funding, consultancies, honoraria, stock ownership or options, expert testimony, royalties, or patents filed, received, or pending), are the following: None.

**Funding/Support and role of the sponsor:** None.

## Appendix A. Supplementary data

Supplementary data to this article can be found online at <https://doi.org/10.1016/j.euro.2021.11.010>.

## References

- [1] Burger M, Catto JW, Dalbagni G, et al. Epidemiology and risk factors of urothelial bladder cancer. *Eur Urol* 2013;63:234–41. <https://doi.org/10.1016/j.eururo.2012.07.033>.
- [2] Smith AB, Crowell K, Woods ME, et al. Functional outcomes following radical cystectomy in women with bladder cancer: a systematic review. *Eur Urol Focus* 2017;3:136–43. <https://doi.org/10.1016/j.euf.2016.05.005>.
- [3] Veskimäe E, Neuzillet Y, Rouanne M, et al. Systematic review of the oncological and functional outcomes of pelvic organ-preserving radical cystectomy (RC) compared with standard RC in women who undergo curative surgery and orthotopic neobladder substitution for bladder cancer. *BJU Int* 2017;120:12–24. <https://doi.org/10.1111/bju.13819>.
- [4] Witjes JA, Bruins HM, Cathomas R, et al. European Association of Urology guidelines on muscle-invasive and metastatic bladder cancer: summary of the 2020 guidelines. *Eur Urol* 2021;79:82–104. <https://doi.org/10.1016/j.eururo.2020.03.055>.
- [5] Hasson HM. Open laparoscopy vs. closed laparoscopy: a comparison of complication rates. *Adv Plan Parent* 1978;13:41–50. <https://www.ncbi.nlm.nih.gov/pubmed/153865>.
- [6] Rocco B, Luciani LG, Collins J, et al. Posterior reconstruction during robotic-assisted radical cystectomy with intracorporeal orthotopic ileal neobladder: description and outcomes of a simple step. *J Robot Surg* 2021;15:355–61. <https://doi.org/10.1007/s11701-020-01108-0>.
- [7] Rocco F, Carmignani L, Acquati P, et al. Restoration of posterior aspect of rhabdosphincter shortens continence time after radical retropublic prostatectomy. *J Urol* 2006;175:2201–6. [https://doi.org/10.1016/S0022-5347\(06\)00262-X](https://doi.org/10.1016/S0022-5347(06)00262-X).
- [8] Wallace DM. Uretero-ileostomy. *Br J Urol* 1970;42:529–34. <https://doi.org/10.1111/j.1464-410x.1970.tb04498.x>.
- [9] Akkad T, Gozzi C, Deibl M, et al. Tumor recurrence in the remnant urothelium of females undergoing radical cystectomy for transitional cell carcinoma of the bladder: long-term results from a single center. *J Urol* 2006;175:1268–71. [https://doi.org/10.1016/S0022-5347\(05\)00643-9](https://doi.org/10.1016/S0022-5347(05)00643-9).
- [10] Ali-el-Dein B, Abdel-Latif M, Ashamallah A, Abdel-Rahim M, Ghoneim M. Local urethral recurrence after radical cystectomy and orthotopic bladder substitution in women: a prospective study. *J Urol* 2004;171:275–8. <https://doi.org/10.1097/01.ju.0000101184.50051.6f>.
- [11] Gakis G, Ali-El-Dein B, Babjuk M, et al. Urethral recurrence in women with orthotopic bladder substitutes: a multi-institutional study. *Urol*

Oncol 2015;33:204.e217–23. <https://doi.org/10.1016/j.urolonc.2015.01.020>.

- [12] Shariat SF, Karakiewicz PI, Palapattu GS, et al. Outcomes of radical cystectomy for transitional cell carcinoma of the bladder: a

contemporary series from the Bladder Cancer Research Consortium. J Urol 2006;176:2414–22. <https://doi.org/10.1016/j.juro.2006.08.004>.