



# Reconstruction of third-degree perineal lacerations in female camels (*Camelus dromedarius*) using a modified Goetz one-stage repair technique

El-Sayed EL-SHAFAEY<sup>1,2</sup>\*

<sup>1</sup>Department of Veterinary Medicine, College of Agriculture and Veterinary Medicine, Qassim University, Qassim, P.O. Box 51452, Saudi Arabia

<sup>2</sup>Department of Surgery, Anesthesiology and Radiology, Faculty of Veterinary Medicine, Mansoura University, Mansoura-city, Dakahlia 35516, Egypt

**ABSTRACT.** This study was designed to evaluate the modified Goetz-one-stage repair technique for reconstruction of third-degree perineal lacerations (TDPLs) in female camels. Fifteen female dromedary camels with TDPL were surgically reconstructed using the modified Goetz one-stage repair using the three-line closure technique. The surgical outcomes, the interval between repair and breeding, and the postoperative conception of the operated female camels were recorded and analyzed. During the 12-month postoperative follow-up period, TDPLs in 14 female camels (93.33%) healed completely by the first intention with mild inflammatory edema and infection in 2 female camels. One camel (6.67%) had a rectovaginal fistula, which was successfully repaired with suturing through the vaginal approach. Of the 15 female camels, 13 (86.67%) subsequently became pregnant through natural mating within 3 to 6 months postoperatively; however, 2 (13.33%) were one was immature and the other was barren which referred for gynecological treatment. The modified Goetz one-stage repair technique was successful in 14 of the 15 female camels after a single surgery, with a low incidence of postoperative complications. This technique is efficient for the repair of TDPLs in female camels, with promising results for subsequent fertility.

**KEY WORDS:** camel, fertility, one-stage repair, perineal lacerations, reconstruction

*J. Vet. Med. Sci.*

83(2): 195–200, 2021

doi: 10.1292/jvms.20-0417

Received: 9 July 2020

Accepted: 19 October 2020

Advanced Epub:

29 October 2020

Third-degree perineal lacerations (TDPLs) commonly occur during parturition in primiparous females and involve the dorsal commissure of the vulva and vaginal vestibule through to the rectum [3]. TDPL results in the disruption of the perineal body, anal sphincter, floor of the rectum, and ceiling of the vestibule, resulting in an abnormal connection between the vestibule and rectum [12]. This eventually causes endometritis and leads to infertility detrimental to milk production, reproductive efficiency, and productive lifespan of the affected animal [14]. TDPLs are usually related to rapid extractive delivery, abnormally positioned or large-sized fetuses, delayed parturition, and inappropriate manual manipulation. All of these factors exert undue pressure on the lateral and dorsal walls of the birth canal, resulting in TDPLs [7, 17].

TDPLs are more common in mares than in cattle, camels, and other domesticated animals [1, 9, 15, 16]. Reconstruction of TDPLs is necessary to quickly return the affected animal to breeding soundness and for cosmetic reasons. Reports on the surgical corrections of TDPLs in camels are rare and are usually based on the standard Goetz one-stage technique [1, 16]. Therefore, this study was designed to investigate the effect of the modified Goetz one-stage repair using a three-line closure technique for reconstruction of TDPLs in female camels.

## MATERIALS AND METHODS

### Camels

Fifteen dromedary female camels of different breeds (4 Mejhem, 7 Wadeh, 3 Ashaal, 1 Asfar) ranging in age from 1 to 10 years (SEM, 5.0 ± 0.6 years) were admitted to the Veterinary Teaching Hospital, College of Agriculture and Veterinary Medicine, Qassim University, Saudi Arabia, between 2017 and 2019. These camels were included in this study based on the clinical evidence of TDPLs. The breed, parity, age, cause, and sex of the delivered calf for the included female camels were assessed and analyzed

\*Correspondence to: El-Shafaey E.-S.: sayedelshafaey@yahoo.com

©2021 The Japanese Society of Veterinary Science



This is an open-access article distributed under the terms of the Creative Commons Attribution Non-Commercial No Derivatives (by-nc-nd) License. (CC-BY-NC-ND 4.0: <https://creativecommons.org/licenses/by-nc-nd/4.0/>)

**Table 1.** Pre- and postoperative case record for third degree perineal lacerations (TDPLs) in 15 female dromedary camels

Case no.	Breed	Parity	Age (y)	Cause	Sex of delivered calf	Interval between laceration and repair (mo)	Outcome	Postoperative mating (mo)	Postoperative conception
1	Mejhem	First	6	Camel bite	Male	6	Recovered	3	Pregnant
2	Wadeh	None	1	Fox bite	None	3	Inflammatory edema	None	None
3	Wadeh	First	7	Forceful extraction of fetus	Male	1	Recovered	3	Pregnant
4	Ashaal	First	6	Episiotomy	Male	5	Recovered	4	Pregnant
5	Wadeh	First	6	Episiotomy	Male	2	Recovered	3	Pregnant
6	Mejhem	First	6	Episiotomy	Male	3	Recovered	6	Pregnant
7	Ashaal	First	6	Episiotomy	Male	5	Recovered	3	Pregnant
8	Wadeh	First	6	Episiotomy	Male	6	Recovered	3	Pregnant
9	Asfar	Second	8	Forceful extraction of fetus	Female	4	Recovered	4	Pregnant
10	Wadeh	First	7	Episiotomy	Male	18	Recovered	3	Pregnant
11	Mejhem	Fourth	10	Forceful extraction of fetus	Female	7	Rectovaginal fistula	6	Pregnant
12	Wadeh	Third	9	Forceful extraction of fetus	Male	11	Recovered	3	Pregnant
13	Ashaal	Third	9	Forceful extraction of fetus	Female	6	Infection	4	Barren
14	Wadeh	Fourth	10	Forceful extraction of fetus	Female	60	Recovered	3	Pregnant
15	Mejhem	First	8	Forceful extraction of fetus	Male	6	Recovered	5	Pregnant

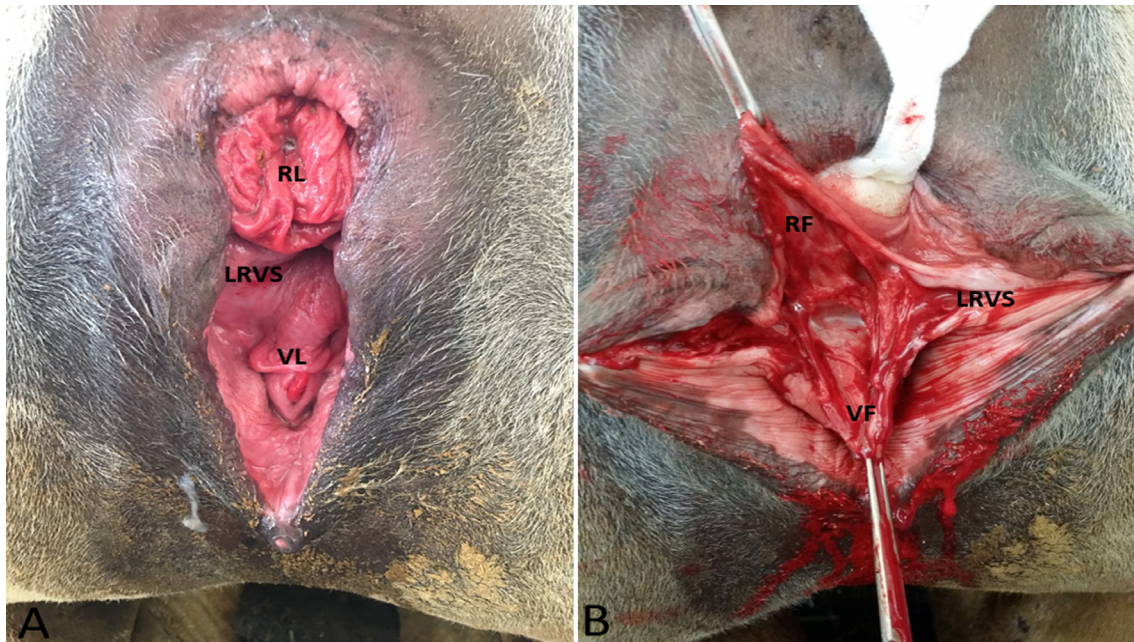
(Table 1). The research procedure was conducted in compliance with the Scientific Research Deanship's Handbook for Animal Care and Use Committee rules, Qassim University, Saudi Arabia.

#### Preoperative preparations

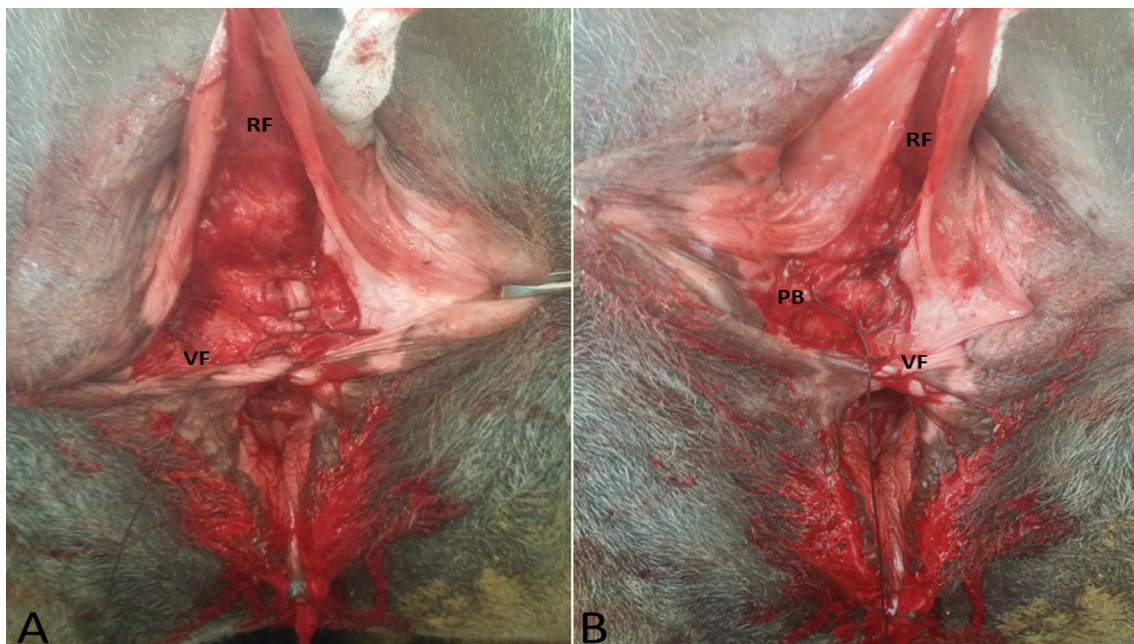
All affected female camels with TDPL were subjected to an approximately 4- to 6-week preoperative regimen beginning with the initial referral to control vaginal and uterine infection. This regimen included manual removal of the feces and thorough lavage of the vulva, vagina, anus, rectum, and perineal region with 5% diluted povidone-iodine solution and topical antibiotic of chlortetracycline HCl (Orondo spray, Invesa; Industrial Veterinaria, S.A, Barcelona, Spain) twice daily until complete mucosal healing. In addition, prophylactic doses of broad-spectrum antibiotic (a combination of gentamicin sulfate, sulfadimethoxine, and trimethoprim (Gentaprim, Industrial Veterinaria, Esmeralda, Spain) were intramuscularly administered at 1 ml per 10 kg of body weight for 5 days, and flunixin meglumine (Finadyin; Schering-Plough, Kenilworth, NJ, USA) at 1.1 mg/kg was injected intravenously (IV) for 5 days. After satisfactory resolution of inflammation and complete mucosal healing of the perineum were attained, surgical reconstruction of the perineum was established (Fig. 1A). During this period, the owners were informed to feed laxatives or green grass to facilitate defecation with minimal tension on the laceration site.

#### Repair technique

For all operated female camels, food was withheld for 72 hr, and water was withheld for 24 hr before surgery to minimize fecal contamination during surgery. Preoperative antibiotics, penicillin-streptomycin (Norbrook Laboratories, Newry, UK) injected IV at a dose rate of 30,000 IU/kg (penicillin) and 10 mg/kg (streptomycin) and flunixin meglumine at 1.1 mg/kg. The camels were restrained in sternal recumbency and were lightly sedated by IV injection of 0.2 mg/kg of xylazine hydrochloride (Seton 2%; Laboratorios Calier, S.A., Barcelona, Spain), along with intercocygeal epidural administration of 0.3 mg/kg of lidocaine hydrochloride (2%; Norbrook Laboratories) at the first intercocygeal space. The tail, buttocks, and perineum were prepared for aseptic surgery. The tail was wrapped and held upward. Back racking of the rectum was performed, and the perineal region and vagina were repeatedly flushed with diluted povidone-iodine solution and thoroughly dried. A rectal cotton and gauze plug coated with zinc oxide ointment joined with a long gauze tape were cranially embedded into the rectum to protect against surgical site contamination. Two Allis tissue forceps were placed on each side of the disrupted dorsal commissure of the vulva to open the lips of the vulva to the buttocks for better exposure of the operative area and surgical access. The free edge of the rectovestibular septum shelf was horizontally incised along the scar tissue line and extended laterally and caudally on each side of the vulva using a scalpel and scissors. The remaining rectovestibular shelf was split cranially in a transverse plane for a distance of 3 to 5 cm between the ventral aspect of the rectum and the dorsal aspect of the vagina, leaving two rectal and vestibular structures of adequate thickness and strength to enable suturing without tension (Fig. 1B). The rectovestibular shelf was reconstructed using the modified Goetz one-stage repair three-line closure technique using coated polyglactin 910 No. 2 (Vicryl; United Medical Industries Co., Ltd., Riyadh, Saudi Arabia) swaged on 48-mm half-circle rounded needle and starting at the deepest cranial part and continuing caudally, according to the procedure described by Mosbah [9]. First, the vestibular flaps were sutured using a continuous horizontal mattress suture (Fig. 2A). Subsequently, the perineal body was approximately closed with the Ford interlocking suture (Fig. 2B). The rectal flap was the third line and was sutured by a continuous horizontal mattress pattern with the mucosa everted in the rectal lumen (Fig. 3A). The perineal skin was sutured using polyglactin 910 No. 2 with interrupted vertical mattress sutures (Fig. 3B).



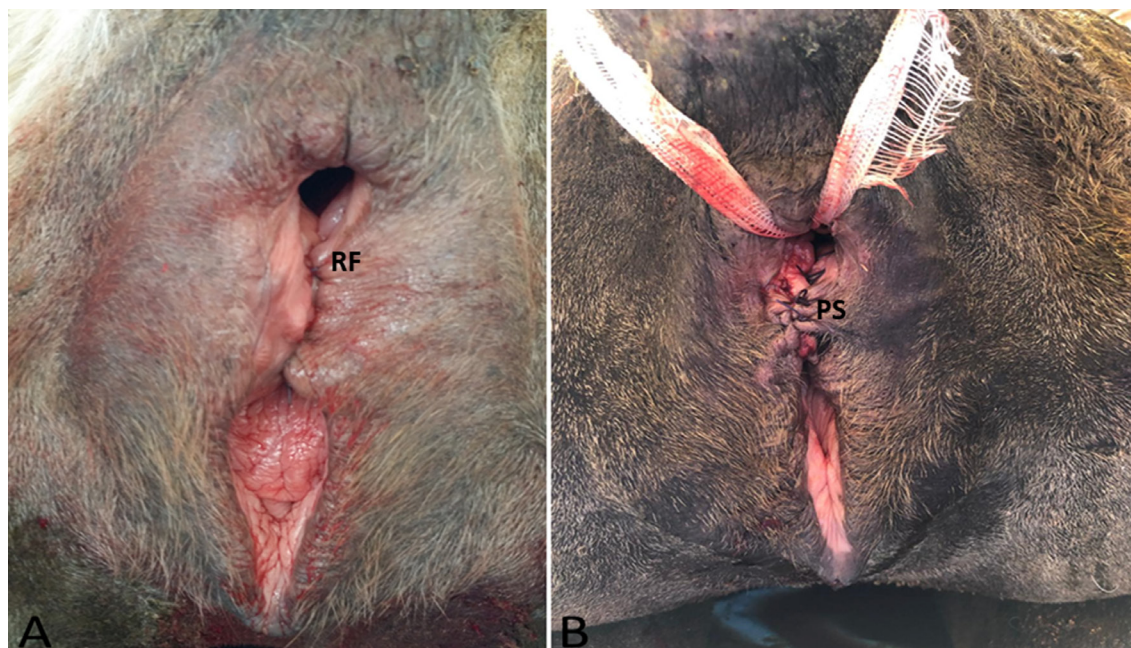
**Fig. 1.** A, Third degree perineal laceration (TDPL) in a primiparous dromedary female camel at 6 weeks postinjury is showing the edges of the rectal lumen, lacerated rectovestibular shelf (LRVS), and vaginal lumen with complete mucosal healing and absence of inflammatory edema. B, The LRVS was incised horizontally along the line of scar tissue and then extended laterally and caudally through sharp and blunt dissection. The dissection was continued cranially for a distance of 3 to 5 cm, creating equally thick and large rectal (RF) and vestibular flaps (VF)



**Fig. 2.** Reconstruction of the rectovestibular shelf using the modified Goetz one-stage repair technique. A, The vestibular flap (VF) was sutured first using a continuous horizontal mattress suture. B, The perineal body between the vestibular flap (VF) and the rectal flap (RF) was approximated with the Ford interlocking suture

*Postoperative care and follow-up*

After surgery, the preoperative antibiotic was continued for 10 days and anti-inflammatory treatment was continued for 5 successive days. In addition, the preoperative diet was continued for at least 2 weeks postoperatively. The reconstructed perineum was cleaned daily with topical povidone-iodine antiseptic spray. The perineal skin sutures were removed after 10 to 14 days postoperatively. The operated female camels were confined in a stall to rest for 4 weeks and were frequently monitored throughout



**Fig. 3.** A, The rectal flap (RF) was sutured using a continuous horizontal mattress pattern. B, The perineal skin was closed with interrupted vertical mattress sutures

the postoperative period for evidence of straining or constipation. Manual evacuation of the rectum was performed, if required. The surgical outcomes, the interval between repair and breeding, and postoperative conception of the operated female camels were obtained by a telephone conversation with the owner and were recorded and analyzed (Table 1).

## RESULTS

All TDPL cases reported in this study occurred during parturition as a result of forceful extraction (7 out of 15, 46.66%) of oversized or malpositioned fetuses or by episiotomy (6 out of 15, 40%) as a result of dystocia except 2 cases that occurred as a result of camel bite (1 out of 15, 6.67%) and fox bite (1 out of 15, 6.67%). With regard to the sex of the delivered calves, ten (66.67%) of the affected camels had delivered male calves when the laceration occurred, and the other four (26.66%) had delivered female calves, although one (6.67%) was immature and the laceration was induced by a fox bite. Nine (66.67%) of the delivered female camels were primiparous, whereas the others were in the second ( $n=1$ , 6.67%), third ( $n=2$ , 13.34%), and fourth ( $n=2$ , 13.34%) parities. The mean average time interval between the incidence of TDPL and surgical interference was 9 months (range, 1 month–5 years). During the 12-month postoperative follow-up period, TDPLs completely healed by the first intention in 14 female camels (93.33%), with mild inflammatory edema and infection in 2 camels. One (6.67%) had a rectovaginal fistula, which was successfully repaired with suturing through the vaginal approach. Thirteen of the female camels (86.67%) subsequently became pregnant through natural mating within 3–6 months postoperatively. However, two (13.33%) were one was immature and the other was barren which referred for gynecological treatment (Table 1).

## DISCUSSION

Dystocia resulting from oversized or malpositioned fetuses contributes the highest percentage to the total causes of TDPLs in farm animals. Subsequently, dystocia leads to obstetrical trauma through forceful extraction, episiotomy, or fetotomy when assisting the delivery. Thus, proper handling in parturition has a considerable effect in reducing the incidence of TDPLs. Our results revealed that all TDPL cases occurred during parturition as a result of dystocia (13 out of 15, 86.66%), except 2 cases that occurred as a result of camel bite (1 out of 15, 6.67%) and fox bite (1 out of 15, 6.67%). These findings were in agreement with those of Anwar and Purohit [1], McKinnon and Vasey [8], and Mosbah [9].

In this study, all included perineal laceration cases mostly occurred at parturition in primiparous female camels (9 vs. 14, 66.67%). This could be attributed to dystocia related to the narrow birth canal of primiparous female camels and the forceful extraction of the oversized or malpositioned calves, which can predispose them for perineal lacerations. Similar findings were reported by Anwar and Purohit [1] and Kazemi *et al.* [6].

The sex of the delivered calf has been considered as a possible risk factor for TDPLs, especially in primiparous female camels. This may be related to the slightly longer gestation period in camels carrying male fetuses, which are typically heavier and oversized, causing delayed parturition and dystocia at delivery [10]. In this study, ten (71.43%) of the affected female camels

had delivered male calves, compared with four that delivered female calves, when the laceration occurred. These findings were in accordance with those of McKinnon and Vasey [8] and Mosbah [9], who mentioned that primiparous mares and cows that delivered male calves more often experienced TDPLs at parturition.

A preoperative treatment regimen is strongly recommended to aid with successful reconstruction of perineal lacerations. Such a regimen reduces local tissue inflammation, edema, and infection of the urinary and reproductive tracts, which could induce failure of the immediate surgical repair [2, 17]. In this study, surgical repair for all female camels was not applied on an emergency basis. Repair was delayed for 4 to 6 weeks for preoperative treatment with systemic and topical therapy. This protocol preserves the tissue integrity sufficiently to allow it to endure sectioning and suture placement to increase the success of surgical outcomes and reduce postoperative complications.

Many surgical techniques have been reported for the repair of TDPLs in mares and cattle, including one- or two-stage repair, or a modification of these methods [4, 8, 11, 13]. All of these techniques aim to reestablish the rectovestibular shelf to restore the perineal body function and to prevent fecal leakage into the vagina to maintain the reproductive performance of the affected camel. However, to the author's best knowledge, this study is the first to use a modified Goetz one-stage repair technique for reconstruction of TDPLs in female camels.

TDPLs are a serious complication representing a challenge for breeding efficiency of the affected animal. Improper surgical repair or not adequately reconstructing the perineum results in complications that can cause infertility. The modified Goetz one-stage repair technique provides a thick rectovestibular shelf, increasing the potency of the perineum and guarding against gross contamination. In this study, we report the successful repair of TDPLs in 14 out of 15 treated female camels (93.33%) by using the modified Goetz one-stage repair technique with a conformational sound perineum and a high postmating conception rate (86.67%). Our findings compare favorably with a previously described one-stage repair method (6 out of 7, 85.71%, reported by Anwar and Purohit [1]). Only one female camel developed a rectovaginal fistula, which was repaired through vaginal approach suturing. The high success rate of the modified Goetz one-stage repair when compared with other techniques is reliant on a conjunction of the preoperative treatment regimen and a precise one-phase operation with less hospitalization. In addition, the three-line closure technique provides strength, a wide rectovestibular shelf, and a potent seal preventing fecal contamination. Similar findings have been reported in mares [5, 9] and cattle [13, 14] with TDPLs.

Sufficient deep dissection of the remnant rectovestibular shelf is essential for the success of the surgical repair of TDPL. This dissection resulted in thicker rectal and vestibular flaps that could be brought together in the midline without tension to avoid wound dehiscence or fistula formation in over-tensioning [9]. In this study, the rectovestibular shelf in all operated female camels was dissected cranially to a 3- to 5-cm depth, leaving rectal and vestibular flaps of sufficient thickness and strength to allow suturing without tension.

Optimal control of the fecal amount and hardness pre- and postoperatively is a critical consideration affecting the surgical success of TDPL surgery. The persistent fecal passage delays wound healing and allows for suture line breakdown. However, soft feces pass smoothly without tension on the reconstruction suture line, which improves the surgical outcomes. In this study, we used a 72-hr preoperative fasting period and 2 weeks of green grass postoperatively to decrease gastrointestinal content and fecal passage. Similar recommendations have been reported by Kazemi *et al.* [6] and Sato *et al.* [7].

In conclusion, the modified Goetz one-stage repair technique was successful in 14 out of 15 female camels after a single surgery, with a low incidence of postoperative complications. This technique can be efficiently used for the repair of TDPLs in female camels, with promising results for subsequent fertility.

CONFLICT OF INTEREST. No potential conflict of interest was reported by the author.

## REFERENCES

1. Anwar, S. and Purohit, G. N. 2013. Occurrence and surgical repair of third degree perineal lacerations in adult female camels (*Camelus dromedarius*) by one-stage (Goetz) technique. *Open Vet. J.* **3**: 75–79. [Medline]
2. Climent, F., Ribera, T., Argüelles, D., Nomen, C. and Prades, M. 2009. Modified technique for the repair of third-degree rectovaginal lacerations in mares. *Vet. Rec.* **164**: 393–396. [Medline] [CrossRef]
3. Frazer, G. S., Perkins, N. R. and Embertson, R. M. 1999. Normal parturition and evaluation of the mare in dystocia. *Equine Vet. Educ.* **11**: 41–46. [CrossRef]
4. Ghamsari, S. M., Nejad, M. M. and Moradi, O. 2008. Evaluation of modified surgical technique in repair of third-grade perineal lacerations in mare. *Iran. J. Vet. Surg.* **3**: 71–76.
5. Kaşıkçı, G., Horoz, H., Alkan, S., Düzgün, O. and Aktaş, M. 2005. A modified surgical technique for repairing third-degree perineal lacerations in mares. *Acta Vet. Hung.* **53**: 257–264. [Medline] [CrossRef]
6. Kazemi, M. H., Sardari, K. and Emami, M. R. 2010. Surgical repair of third-degree perineal laceration by Goetz technique in the mare: 7 cases (2000–2005). *Majallah-i Tahqiqat-i Dampizishki-i Iran* **11**: 184–188.
7. LeBlanc, M. M. 1999. Diseases of the vagina, vestibule and vulva. pp. 1175–1193. In: *Equine Medicine and Surgery*, 5th ed. (Colahan, P. T., Mayhew, I. G., Merritt, A. M. and Moore, J. N. eds.), Mosby, St. Louis.
8. McKinnon, A. O. and Vasey, T. R. 2007. Selected reproductive surgery of the broodmare. pp. 146–160. In: *Current Therapy in Equine Reproduction*, (Samper, J. C., Pycock, J. F., McKinnon, A. O. eds.), Mosby, St. Louis.
9. Mosbah, E. 2012. A modified one-stage repair of third-degree rectovestibular lacerations in mares. *J. Equine Vet. Sci.* **32**: 211–215. [CrossRef]
10. O'Rielly, J. L., Mac Lean, A. A. and Lowis, T. C. 1998. Repair of third degree perineal laceration by a modified Goetz technique in 20 mares. *Equine Vet. Educ.* **10**: 2–7. [CrossRef]
11. Phillips, T. N. and Foerner, J. J. 1998. Semitransverse closure technique for the repair of perineal lacerations in the mare. *Proc. Ann. Conv. Am.*

- Assoc. Equi. Pract.* **44**: 191–193.
12. Purohit, G. N. 2011. Intrapartum conditions and their management in the mare: A review. *J. Livest. Sci.* **2**: 20–37.
  13. Rizk, A. and Mosbah, E. 2016. Occurrence and surgical reconstruction of perineal lacerations and rectovaginal fistulae in dairy cows. *J. Adv. Vet. Res.* **6**: 123–129.
  14. Sato, R., Kamimura, N. and Kaneko, K. 2019. Surgical repair of third-degree perineal lacerations with rectovestibular fistulae in dairy cattle: a series of four cases (2010–2018). *J. Vet. Med. Sci.* **81**: 703–706. [[Medline](#)] [[CrossRef](#)]
  15. Siddiqui, M. I. and Telfah, M. N. 2010. Perineal laceration. pp. 117–119. In: A Guide Book of Camel Surgery, 1st ed., Abu Dhabi Food Control Authority (ADFCA), Abu Dhabi.
  16. Tibary, A. and Anouassi, A. 2000. Reproductive disorders in the female camelidae. In: Recent Advances in Camelid Reproduction (Skidmore, J. A. and Adams, G. P. eds.), International Veterinary Information Service. [www.ivis.org](http://www.ivis.org), Ithaca.
  17. Woodie, B. 2006. The vulva, vestibule, vagina and cervix. pp. 845–852. In: Equine Surgery (Auer, J. A. and Stick, J. A. 3rd eds.), W.B. Saunders Co., Philadelphia.