

Treatment of intertrochanteric femur fracture with closed external fixation in high-risk geriatric patients: can it be the most reliable method that reduces mortality to minimum compared to proximal femoral nail and hemiarthroplasty?

Akar Bedrettin, MD^{a,*} , Fatih Sahin, MD^b, Mucahid Osman Yucel, MD^a

Abstract

The optimal surgical treatment of intertrochanteric femur fractures (ITF) to minimize the increased mortality in geriatric patients with high anesthetic risk was investigated by comparing closed external fixation (EF), a minimal invasive and biological osteosynthesis technique, proximal femoral nail (PFN) and hemiarthroplasty (HA) methods.

Three different surgical methods were performed to 167 patients who were admitted to our clinic for ITF between 2014 and 2020 and considered at high risk (American Society of Anesthesiologists III – American Society of Anesthesiologists IV) by the Anesthesiology and Reanimation Department. Patients with multi-trauma, osteoarthritis, those with malignancies and developmental hip dysplasia were excluded from the study. Group I included patients who underwent closed reduction - external fixation (n=46), Group II included patients who underwent partial arthroplasty (n=77), and Group III included those who received PFN (n=44). All fractures were classified according to the Modified Evans (Kyle) method and divided into 2 categories as type 1-2 (stable) and type 3-4 (unstable).

The mean operation duration was 23 minutes and follow-up time was 14 months in Group 1, in which there was no in-hospital mortality. Five patients died due to non-operative reasons within 1 year. The mean operation duration and follow-up time in Group 2 were 40 minutes and 12 months, respectively. Six patients (7.8%) died during the operation or hospitalization, while 17 patients died due to comorbidities within 1 year. In Group 3, the mean operation duration and follow-up time were 40 minutes and 13 months, respectively. One patient died during the operation and 1 patient (n=2, 4.5%), within 24 hours in the postoperative intensive care unit. Seven patients died due to comorbidities within 1 year. Statistical analysis revealed that the mean duration of operation, postoperative hospital stay, overall mortality and blood product transfusion amount were significantly lower in the EF group compared to other treatment methods.

Closed EF is the most reliable surgical method that can minimize mortality in geriatric patients compared to other surgical options, due to the short duration of the operation, no evacuation of the fracture hematoma, early mobilization, lack of blood transfusion requirement, and early union.

Abbreviations: DHS = dynamic hip screw, EF = external fixation, HA = hemiarthroplasty, ITF = intertrochanteric femur fracture, PFN = proximal femoral nail.

Keywords: external, femur, fixation devices, geriatrics, intertrochanteric fractures, mortality

1. Introduction

Intertrochanteric femur fracture (ITF) occurs with low-energy trauma because of decreased bone quality and deterioration of histological structure on the basis of osteoporosis.^[1–3] Factors such as the presence of systemic diseases in advanced ages,

decreased protective reflexes and muscle strength during falls are effective in the formation of fractures. Conservative treatment in ITF, which constitutes 8% to 10% of fractures over 65 years of age, is not preferred due to 60% mortality rate and cardiopulmonary complications that develop due to immobilization.^[3–7]

Editor: Arjun Ballal.

The authors have no funding and conflicts of interests to disclose.

All data generated or analyzed during this study are included in this published article [and its supplementary information files].

^a Sakarya Yenikent State Hospital, Department of Orthopedics and Traumatology, Sakarya, Turkey, ^b Sakarya University Training and Research Hospital, Department of Anesthesiology, Sakarya, Turkey.

* Correspondence: Akar Bedrettin, Sakarya Yenikent State Hospital, Department of Orthopedics and Traumatology, Sakarya, Turkey (e-mail: drbedrettin@gmail.com).

Copyright © 2022 the Author(s). Published by Wolters Kluwer Health, Inc.

This is an open access article distributed under the terms of the Creative Commons Attribution-Non Commercial License 4.0 (CCBY-NC), where it is permissible to download, share, remix, transform, and build upon the work provided it is properly cited. The work cannot be used commercially without permission from the journal.

How to cite this article: Bedrettin A, Sahin F, Yucel MO. Treatment of intertrochanteric femur fracture with closed external fixation in high-risk geriatric patients: can it be the most reliable method that reduces mortality to minimum compared to proximal femoral nail and hemiarthroplasty?. *Medicine* 2022;101:1(e28369).

Received: 26 July 2021 / Received in final form: 23 November 2021 / Accepted: 2 December 2021

<http://dx.doi.org/10.1097/MD.00000000000028369>

One-year mortality rate following the surgery is between 18% to 30%.^[1,5,8,9] While the union potential is high in ITF, 1200 to 1500 mL of bleeding can be observed.^[10–13]

The aim in surgery is to provide stable fixation and early mobilization by reducing the fracture anatomically. Because open reduction and internal osteosynthesis may cause increased risk of bleeding, implant failure based on osteoporosis, malunion, nonunion and tissue trauma, minimally invasive surgeries should be preferred in these fractures. External fixation (EF), a minimally invasive surgery with a short operation time, closed technique and provision of rigid fixation, may be preferred in ITF. The first EF in ITF was used by Scott in 1949, and the technique continued to be developed by researchers such as De Bastian in 1984, and Mitkovic and Girgin in 1988.^[2,3,9,10,14–16]

Proximal femoral nail (PFN), another minimally invasive surgery, is also used in the treatment of ITF. It allows early mobilization and weight bearing.^[3,10,17,18] Despite its minimally invasive nature, it includes risks that can be deemed unfavorable for geriatric patients, such as being performed with the open technique from the proximal femur, reamerization of the medulla, the need for frequent blood transfusion and relatively longer operation times.^[16,17,19,20]

Another method used in ITF treatment is hemiarthroplasty (HA). Although HA is not the ideal treatment option, it allows early mobilization by placing weight, as calcar supported cement endoprostheses are used. It is usually not preferred in geriatric patients due to factors such as open technique, damage to tissues, blasting of the femur, higher blood transfusion need due to perioperative and postoperative bleeding, long operation time, increased mortality, and dislocation of the prosthesis.^[14,21,22]

2. Methods

This study was conducted with the approval of the local ethics committee of Sakarya University Faculty of Medicine (E.20134-176). In this retrospective study, 167 high-risk American Society of Anesthesiologists 3-4 (American Society of Anesthesiologists 3-4) patients over the age of 65 years who were admitted to our clinic due to ITF underwent 3 different surgical procedures between February 2014 and October 2020. Patients with multi-trauma, osteoarthritis, those with malignancies and developmental hip dysplasia were excluded from the study. Modified Evans (Kyle) classification was used for fractures. Group I included patients who underwent closed reduction - external fixation (n=46), Group II included patients who underwent partial arthroplasty (n=77), and Group III included those who received PFN (n=44) (Consort diagram, Supplemental Digital Content, <http://links.lww.com/MD/G585>).

The mean operation duration and follow-up times in Groups 1 (EF), 2 (HA), and 3 (PFN) were 23 minutes and 14 months, 40 minutes and 13 months, and 33 minutes and 13 months, respectively. In Groups 1, 2, and 3, the number of patients with stable and unstable fractures were 30 and 16, 54, and 23, and 28 and 16, respectively. No patients were operated under emergency conditions. The comorbidities of the patients included ischemic heart disease, hypertension, Diabetes Mellitus, renal failure, and Chronic Obstructive Pulmonary Disease.

The patients were operated under peripheral block, short-term spinal anesthesia or mild sedation after evaluation by the Anesthesiology and Reanimation Department. Dyna EXTOR II (BK Meditech -Korea) fixators, which allow to send multidirectional angular nails on the traction table, were used in Group I

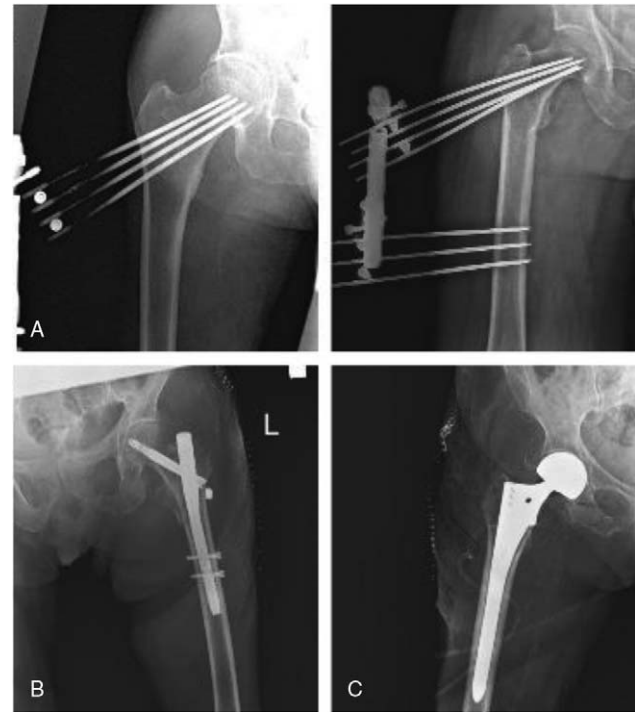

Figure 1. Postoperative X-ray images; (A): External Fixation, (B): PFN, (C): Hemiarthroplasty.

patients. During the operation, 3 to 4 self-threaded 6 mm shanz nails were placed in the femoral neck and 3 were placed distally. Care was taken to leave the longitudinal nails 1 cm away from the cartilaginous surface. Group II patients received bipolar partial prosthesis with bone cement replacement (Biomet, Tipsan, HipKnee brands), and Group III patients received PFN (Tipmed, Tipsan and Prosim brands) by replacing the fracture (Fig. 1). The patients were given erythrocyte transfusion based on their hemogram values, antibiotic prophylaxis with first generation cephalosporins and deep vein thrombosis prophylaxis. They were mobilized by partial or full-weight bearing starting on the first postoperative day.

2.1. Statistical analysis

Statistical analyses were performed using the Number Cruncher Statistical System 2007 Statistical Software (Utah, USA) package program. The distribution of variables was examined with the Shapiro - Wilk normality test as well as descriptive statistical methods (mean, standard deviation). One-way analysis of variance was used for comparisons between normally distributed groups, Tukey multiple comparison test was used for subgroup comparisons, and Chi-Squared test was preferred for comparisons of qualitative data. The results were evaluated at a significance level of $P < .05$.

3. Results

Group EF: Nail root infection was seen in 18 patients. All infections were superficial and responded well to antibiotherapy. In 3 patients, varus deformity varying between 10 and 25 degrees developed due to nail loosening, which resulted in a shortening of 1.5 to 2.5 cm. No in-hospital mortality was observed. None of the

Table 1
Evaluation of demographic and operative data.

	EF Group (n = 46)	HA Group (n = 77)	PFN Group (n:44)	P
Age	77,11 ± 7,49	79, 78 ± 8, 33	76, 86 ± 6, 54	066
Gender				
Male	21 (45, 65%)	32 (41, 56%)	15 (34, 09%)	525
Female	25 (54, 35%)	45 (58, 44%)	29 (65, 91%)	
Laterality				
Right	25 (54, 35%)	32 (41, 56%)	26 (59, 09%)	136
Left	21 (45, 65%)	45 (58, 44%)	18 (40, 91%)	
Modified evans classification				
Types 3-4 Unstable	16 (34, 78%)	23 (29, 87%)	16 (36, 36%)	729
Types 1-2 Stable	30 (65, 22%)	54 (70, 13%)	28 (63, 64%)	
Duration of operation	23, 26 ± 4, 97	40, 84 ± 8, 71	33, 07 ± 7, 01	0001
Reunion (Wks)	12, 59 ± 2, 27	-	15, 55 ± 2, 39	0001
Post-operative duration of hospitalization (Days)	3, 83 ± 1, 22	5, 04 ± 1, 51	4, 89 ± 1, 59	0001
Mean follow up time (Mo)	14, 52 ± 3, 72	12, 93 ± 5, 93	12, 46 ± 4, 44	117
Anesthesia risk				
ASA3	24 (52, 17%)	36 (46, 75%)	23 (52, 27%)	780
ASA4	22 (47, 83%)	41 (53, 25%)	21 (47, 73%)	
In hospital mortality	0 (0, 00%)	6 (7, 79%)	2 (4, 55%)	146
One year mortality	5 (10, 87%)	17 (23, 94%)	7 (16, 67%)	193
Overall mortality	5 (10, 87%)	23 (29, 87%)	9 (20, 45%)	047
Blood transfusion	0 (0, 00%)	75 (97, 40%)	9 (20, 45%)	0001
Blood transfusion (Units)	-	1, 81 ± 0, 51	1, 33 ± 0, 5	009
Pin root infection	18 (39, 13%)	4 (5, 19%)	2 (4, 55%)	0001

EF = external fixation, HA = Hemiarthroplasty, PFN = proximal femoral nail, ASA = American Society of Anesthesiologists, EF = external fixation, HA = Hemiarthroplasty, PFN = proximal femoral nail.

patients required blood transfusion. Five patients died within 1 year due to comorbidities. Fixators were removed at an average of 12 weeks (Table 1).

Group HA: Prosthesis infection was seen in 2 patients, who received specific antibiotherapy. In 1 unresponsive patient, the infected prosthesis was re-operated and Girdlestone operation was performed. Prosthetic dislocation was seen in 2 patients with a history of re-fall. One patient was operated with the closed technique and 1, with the open technique, and the hip was reduced. Six patients died in the hospital during or within the first 7 days of the operation. During 1-year follow-up, 17 patients died of non-surgical causes. The patients received an average of 1.8 units of blood transfusion during the operation and their hospitalization (Table 1).

Group PFN: One patient died during the operation; 1 patient died within the first 24 hours in the postoperative intensive care unit. During one-year follow-up, 7 patients died due to comorbidities. Fifteen degrees of varus deformity and 1.5 cm shortening were detected in 1 patient. Patients with hemoglobin values below 10 mg/dL received an average of 0.27 units of blood transfusion (Table 1).

The mean operation time in the HA group was significantly higher than that of the EF and PFN groups ($P = .0001$), and that of the PFN group was higher than that of the EF group ($P = .0001$).

The mean of the postoperative hospitalization duration (days) in the EF group was significantly lower than those of the HA and PFN groups ($P = .0001$, $P = .002$), (Table 2).

The EF, HA and PFN groups were similar in terms of operative ($P = .146$), and 1-year mortality ($P = .193$) rates. However, the groups differed with regards to overall mortality rates ($P = .047$). The overall mortality rate in the EF group was higher than those in the HA and PFN groups (Fig. 2).

The mean units of blood transfused was significantly lower in the EF group compared to the other 2 groups ($P = .0001$), and higher in the HA group compared to the PFN group ($P = .0001$).

4. Discussion

These fractures which develop on osteoporosis background and in advanced ages carry a high risk of morbidity and mortality due to the comorbidities of the patients. The aim of the treatment is to mobilize the patient as soon as possible, prevent possible complications and return the patient to his pre-fracture life.^[1,4,17,19,21,23,24] It is necessary to avoid treatment options that will further increase the already elevated mortality rates. Internal fixation with PFN continues to be the gold standard for these fractures.^[5,8,11,20,25,26]

The mortality rates of 3 different surgical methods in the treatment of American Society of Anesthesiologists 3-4 high-risk

Table 2
Comparison of external fixator group, hemiarthroplasty group and PFN Group.

	Operation duration, P value	Postoperative duration of hospitalization (days), P value
External fixator group/Hemiarthroplasty group	0001	0001
External fixator group/PFN Group	0001	002
Hemiarthroplasty group/PFN Group	0001	844

PFN = proximal femoral nail.

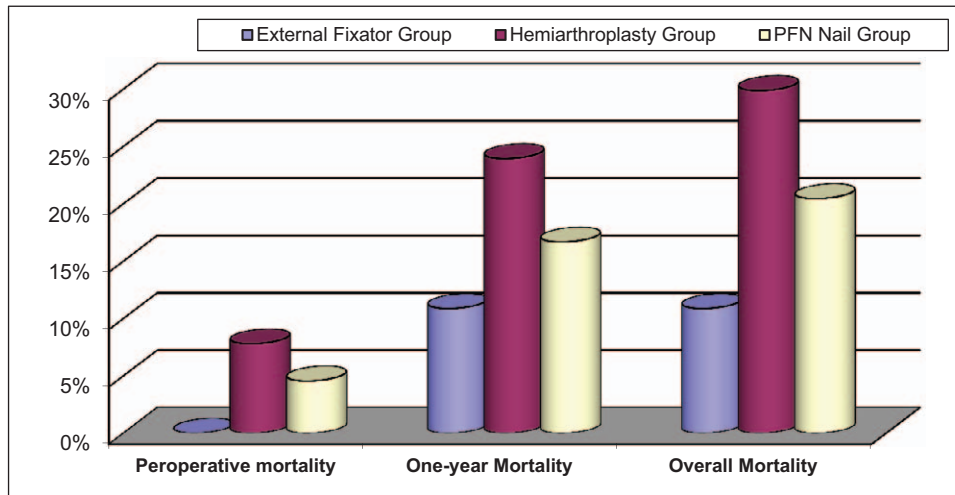


Figure 2. Mortality rates.

patients depend on many variables. Although fixation with EF is not widely used, it can be preferred as a minimally invasive option due to the short duration of the surgery, lack of tissue damage, provision of rigid stability and early post-operative mobilization. Postoperative pain is minimal in EF, and can be easily controlled.^[1,2,8,9,11,15]

PFN, an internal fixation method, is another minimally invasive surgery, which is considered the gold standard in ITF treatment in the recent years due to its highly robust material structure and theoretical advantages provided by the reduction of the distance between the hip joint and the implant and shortening of the lever arm, hence, aiming to protect the hip joint. However, it may not be a suitable choice for elderly patients with comorbidities.^[5,7,10,16–18,21,23,27,28]

Hemiarthroplasty, on the other hand, is not widely used due to its many complications and disadvantages that increase mortality, but it is sometimes preferred because it allows weight bearing immediately and prevents complications due to immobilization.^[7,14,20–22,27]

EF was performed by Navin et al in 50 patients with a mean age of 87 years,^[2] by Guo et al in 43 patients with a mean age of 80 years,^[11] by George et al in 100 patients over 75 years of age,^[23] by George et al in 40 patients with a mean age of 67.9 years,^[25] by Ahmet et al in 23 patients with a mean age of 70 years,^[17] by Aydin et al in 77 patients with a mean age of 83 years,^[4] by Atıcı et al in 23 patients with a mean age of 74 years,^[15] by Özdemir et al in 25 patients with a mean age of 70 years,^[3] and by Özkaya et al in 14 patients with a mean age of 75 years.^[9] No blood transfusion was needed in this method. Although the duration of the operation varies in different studies, it is generally between 15 to 25 minutes. The mean follow-up time is between 10 to 16 months, and the mean union time is between 9 and 14 weeks. Pin root infections are common in EF.^[1,3,8,10,21,23] These infections are generally superficial and heal completely after the removal of the pins.^[2,6,9,10,25] Pin root infections were seen by Navin in 30 patients (60%), by Ahmet in 18 patients (78%), by George in 13 patients (32.5%), by Aydin in 38 patients (55%), by Atıcı et al in 11 patients (47.8%), by Özdemir et al in 10 patients (40%), and by Özkaya et al in 5 patients (35%), all of which healed uneventfully by dressing and pin removal.^[2–4,11,15,17,23] In our study, pin root infection was observed in 18

patients, and they healed with the removal of the pins. Another complication in EF is varus deformity due to pin failure. Navin observed 5 degrees of varus in 10 patients, Ahmet observed 5 to 10 degrees varus in 12 patients, Guo et al encountered 5 degrees of varus in 2 patients, Özdemir et al observed 5 to 10 degrees of varus deformity in 3 patients, with a resulting mean shortness of 1 to 1.5 cm.^[1,5,7,17,29]

In EF, factors such as short operation time and lack of blood transfusion requirement reduce the operative mortality rates in geriatric patients despite their comorbidities.^[1,2,4,11] Mortality due to comorbidities were observed by Navin in 5 patients within 1 year,^[2] by Ahmet in 2 patients due to liver failure,^[17] and by Özkaya et al in 3 patients within 1 year.^[9] Guo et al, George et al, George, and Özdemir et al did not report any mortality in their studies.^[3,11,23,25] In our study, no surgery-related mortality was observed, but 5 patients died within 1 year due to comorbidities.

G.H et al and Jun-Yi et al compared patients treated with skeletal traction with those treated with EF in 2 separate studies, and both reported that long hospitalization in patients treated with traction increased the risk of cardiopulmonary insufficiency and pneumonia in these patients who already had comorbidities.^[6,26]

While PFN is considered the gold standard in the treatment of ITF, it carries some difficulties and risks in patients with comorbidities over the age of 65 years. Mortality risks increase for elderly patients as the tissues are more traumatized compared to EF and the medulla is reamerized. Internal fixation may not provide satisfactory results in osteoporotic bones.^[5,10,20,22,29] In their study, G. H et al performed dynamic hip screw (DHS) and EF on 60 patients with ITF and reported the mean operative time as 73 minutes in DHS and 15 minutes in EF. DHS patients required blood transfusion while EF patients did not.^[5] Factors such as fast and simple application, minimal blood loss, rigid fixation, and short postoperative hospitalization time make EF advantageous.^[1,4,7,8,13,14,25,28] Esat et al performed PFN to 159 patients. Some patients received blood transfusion. They reported early postoperative mortality in 3 patients, mortality due to fractures as 13.7%, and the first-year mortality rate as 15% to 20%.^[16]

In Geriatric ITF, the other less preferred treatment option is hemiarthroplasty. The biggest advantage of HA is that it enables

the patient to mobilize as soon as possible.^[14,21,22] However, while early mobilization provides an advantage in high-risk patients, mortality increases because of more tissue damage, prolonged operation time, the use of bone cement and blood transfusion requirement. Polat et al compared HA and EF and reported no difference in functional outcomes, length of hospital stays, and mortality.^[14] According to Kesmezacar et al, there was no difference between HA and internal fixation in the early postoperative period, prosthesis survival was short and mortality rate was high.^[21] Mutlu et al compared DHS with HA and stated that the mortality rate in DHS was higher than that in HA, the chosen surgical method did not affect mortality, and that mortality was related to advanced age and comorbidities.^[22] However, based on the results in our study and in the literature, we would like to state that the surgical method is very effective on mortality in these patients. Although advanced age and comorbidities affect mortality, perhaps more important than these factors are the risks that the surgical method will impose on the patient.

ITFs observed over the age of 65 years are risky fractures because patients have additional comorbidities. The mobilization of the patient and early return to her/his pre-fracture life should be aimed by choosing the surgical method that will affect the patient's hemodynamics the least. Protecting the patient's life should be the priority. If there were no additional inconveniences, our preference would be PFN. However, in these patients, factors such as shorter surgical time, not requiring blood transfusion, lack of tissue damage and rigid fixation make EF more advantageous in minimizing mortality compared to other surgical options, such as PFN and HA. We hope that this article, which we prepared with reference to the successful studies in the past, will guide the studies to be conducted in the coming years. We believe that studies in which comorbid factors are examined in more detail with larger patient series should be carried out.

Author contributions

Conceptualization: Bedrettin Akar, Mucahid Osman Yucel.

Data curation: Bedrettin Akar.

Formal analysis: Fatih Sahin.

Funding acquisition: Bedrettin Akar, Mucahid Osman Yucel.

Investigation: Bedrettin Akar, Fatih Sahin.

Methodology: Bedrettin Akar.

Project administration: Bedrettin Akar, Mucahid Osman Yucel.

Software: Bedrettin Akar.

Supervision: Fatih Sahin.

Validation: Bedrettin Akar.

Visualization: Fatih Sahin, Mucahid Osman Yucel.

Writing – original draft: Bedrettin Akar.

Writing – review & editing: Bedrettin Akar, Mucahid Osman Yucel.

References

- [1] Douša P, Řech O, Weissinger M, Džupa V. Trochanterické zlomeniny femuru [Trochanteric femoral fractures]. *Acta Chir Orthop Traumatol Cech* 2013;80:15–26.
- [2] Karn NK, Singh GK, Kumar P, Singh MP, Shrestha BP, Chaudhary P. Management of trochanteric fractures of the femur with external fixation in high-risk patients. *Int Orthop* 2008;33:785–8.
- [3] Özdemir H, Ürgüden M, Dabak TK, Söyüncü Y. Treatment of intertrochanteric femoral fractures with the use of a modular axial fixator device. *Acta Orthop Traumatol Turc* 2002;36:375–83.
- [4] Arslan A, Utkan A, Koca TT. Result of a compression pin alongwith trochanteric external fixation in management of high risk elderly intertrochanteric fractures. *Indian J Orthop* 2016;50:636–40.
- [5] Kazemian GH, Manafi AR, Najafi F, Najafi MA. Treatment of intertrochanteric fractures in elderly highrisk patients: dynamic hip screw vs. external fixation. *Injury* 2014;45:568–72.
- [6] Gholam HK, Emami M, Manafi A, Najafi F, Najafi MA. External fixation & skeletal traction for treatment of intertrochanteric fractures in the elderly. *J Truma Emerg Med* 2016;21:e15477.
- [7] Vossinakis IC, Badras LS. The external fixator compared with the sliding hip screw for pertrochanteric fractures of the femur. *J Bone Joint Surg Br* 2002;84:23–9.
- [8] Pathania V, Balakrishnan M, Khare R. External fixation of intertrochanteric fractures of femur in elderly. *Med J Armed Forces India* 1999;55:325–7.
- [9] Özkaya U, Parmaksızoğlu AS, Gül M, Kabukçuoğlu Y, Özkazanlı G, Basılğan S. Management of osteoporotic pertrochanteric fractures with external fixation in elderly patients. *Acta Orthop Traumatol Turc* 2008;42:246–51.
- [10] Yeganeh A, Taghavi R, Moghtadaei M. Comparing the intramedullary nailing method versus dynamic hip screw in treatment of unstable intertrochanteric fractures. *Med Arch* 2016;70:53–6.
- [11] Guo L, Wu-Fan S. Minimal invasion and closed reduction with external fixation for elderly femoral intertrochanteric fracture. *Zhongguo Gu Shang* 2015;28:1048–52.
- [12] Devgan A, Sangwan SS. External fixator in the management of trochanteric fractures in high risk geriatric patients—a friend to the elderly. *Indian J Med Sci* 2002;56:385–90.
- [13] Gotfried Y, Frish E, Mendes DG, Roffman M. Intertrochanteric fractures in high risk geriatric patients treated by external fixation. *Orthopedics* 1985;8:769–74.
- [14] Polat M, Arslan A, Utkan A. External fixation versus hemiarthroplasty in unstable intertrochanteric hip fractures of the elderly. *Acta Orthop Belg* 2017;83:351–9.
- [15] Atıcı T, Şahin N, Öztürk A, Yaray O. Treatment of intertrochanteric femur fractures in high- risk geriatric patients (>65 years)with external fixation. *Turkish J Trauma Emerg Surg* 2010;16:413–20.
- [16] Uygur E, Söylemez S, Aktaş B, Çarkçı E. Proximal femoral çivileme ile tedavi edilen intertrokhanterik femur kırığı olan yaşlı hastaların ameliyat sonrası sağ kalım oranları. *Medeniyet Med J* 2015;30:63–6.
- [17] Yousry AH, Chotai PN, El Ghazaly SA, Fayyad TA, Abdelgawad AA. Outcomes of trochanteric external fixation for geriatric inter-trochanteric hip fractures. *J Orthop* 2015;12:174–8.
- [18] Yuan X, Yao Q, Ni J, Peng L, Yu D. Proximal femoral nail antirotation versus dynamic hip screw for intertrochanteric fracture in elders: a meta-analysis. *Zhonghua Yi Xue Za Zhi* 2014;94:836–9.
- [19] Chua IT, Rajamoney GN, Kwek EB. Cephalomedullary nail versus sliding hip screw for unstable intertrochanteric fractures in elderly patients. *J Orthop Surg (Hong Kong)* 2013;21:308–12.
- [20] Han FS, Guo FX, Zeng XT, Zhang B, Ping J. Comments on “Anti-rotation proximal femoral nail versus dynamic hip screw for intertrochanteric fractures: a meta-analysis of randomized controlled studies” of L. Shen, Y. Zhang, Y. Shen, Z. Cui published in *Orthop Traumatol Surg Res.* 2013; 99: 377-83. *Orthop Traumatol Surg Res* 2014;100:259–60.
- [21] Kesmezacar H, Oğüt T, Bilgili MG, Gökay S, Tenekecioğlu Y. Treatment of intertrochanteric femur fractures in elderly patients: internal fixation or Hemiarthroplasty. *Acta Orthop Traumatol Turc* 2005;39:287–94.
- [22] Mutlu M, Bilgen MS, Durak K. Intertrochanterik femur kırıklarında kalkarlı parsiyel protez ile Dinamik Kalça vidadı uygulamalarının Karşılaştırmalı sonuçları. *Uludağ Üniversitesi tıp fak dergisi* 2008; 34:31–9.
- [23] Petsatodis G, Maliogas G, Karikis J, et al. External fixation for stable and unstable intertrochanteric fractures in patients older than 75 years of age: a prospective comparative study. *J Orthop Trauma* 2011;25:218–23.
- [24] Simmermacher RK, Ljungqvist J, Bail H, et al. The new proximal femoral nail antirotation (PFNA) in daily practice: results of a multicentre clinical study. *Injury* 2008;39:932–9.
- [25] Boghdady GW, Shalaby M. Safety and reliability of external fixation for basicervical and intertrochanteric fractures in high-risk elderly patients. *Strat Traum Limb Recon* 2007;2:83–9.

- [26] Wang JY. Treatment of intertrochanteric fractures in the advanced age patients by external fixators 2012;25:804–6.
- [27] Ma KL, Wang X, Luan F], et al. Proximal femoral nails antirotation, Gamma nails, and dynamic hip screws for fixation of intertrochanteric fractures of femur: a meta-analysis. *Orthop Traumatol Surg Res* 2014;100:859–66.
- [28] Evaniew N, Bhandari M. Cochrane in CORR (R): Intramedullary nails for extracapsular hip fractures in adults (review). *Clin Orthop Relat Res* 2015;473:767–74.
- [29] Krischak G, Durselen L, Roderer G. Treatment of peritrochanteric fractures: biomechanical considerations. *Unfallchirurg* 2011;114:485–90.