

# Long-term outcomes of Zenker's peroral endoscopic myotomy (Z-POEM) for treatment of Zenker's diverticulum




## Authors

Steven Steinway<sup>1</sup>, Linda Zhang<sup>1</sup>, Julia Amundson<sup>2</sup>, Jose Nieto<sup>3</sup>, Pankaj Desai<sup>4</sup>, Jeremie Jacques<sup>5</sup>, Michael Bejjani<sup>1</sup>, Mathieu Pioche<sup>6</sup>, Nikhil Kumta<sup>7</sup>, Oscar Hernandez-Mondragon<sup>8</sup>, Michael Ujiki<sup>9</sup>, Mouen Khashab<sup>1</sup>

## Institutions

- 1 Johns Hopkins Medicine, Gastroenterology and Hepatology, Baltimore, Maryland, United States
- 2 University of Chicago Pritzker School of Medicine, Chicago, Illinois, United States
- 3 University of Central Florida, Department of Gastroenterology, Orlando, Florida, United States
- 4 Surat Institute of Digestive Sciences, GI Endoscopy, Surat, India
- 5 CHU Dupuytren Limoges, Service d'Hépatogastro-entérologie, Limoges, France
- 6 Hôpital Edouard Herriot, Endoscopy Unit, Digestive Disease Department, Lyon, France
- 7 Icahn School of Medicine at Mount Sinai, Division of Gastroenterology, New York, New York, United States
- 8 IMSS, Digestive Endoscopy, Mexico City, Mexico
- 9 NorthShore University Health Systems, NorthShore Center for Simulation and Innovation, Evanston, Illinois, United States

7125B, Baltimore, MD 21287

Phone: 443-287-1960

mkhasha1@jhmi.edu

## ABSTRACT

**Background and study aims** Z-POEM is now an established therapy for symptomatic Zenker's diverticulum (ZD). Short-term follow-up of up to 1-year post Z-POEM suggests excellent efficacy and safety; however, long-term outcomes are not known. Thus, we sought to report on longer-term outcomes ( $\geq 2$  years) following Z-POEM for treatment of ZD.

**Patients and methods** This was an International multi-center retrospective study at eight institutions across North America, Europe, and Asia over a 5-year period (from December 3, 2015 to March 13, 2020) of patients who underwent Z-POEM for management of ZD with a minimum 2-year follow-up. The primary outcome was clinical success, defined as improvement in dysphagia score to  $\leq 1$  without need for further procedures during the first 6 months. Secondary outcomes included rate of recurrence in patients initially meeting clinical success, rate of reintervention, and adverse events (AEs).

**Results** A total of 89 patients (male 57.3%, mean age  $71 \pm 12$  years) underwent Z-POEM for treatment of ZD (mean diverticulum size was  $3.4 \pm 1.3$  cm). Technical success was achieved in 97.8% of patients ( $n=87$ ) with a mean procedure time of  $43.8 \pm 19.2$  minutes. The median post-procedure hospital stay was 1 day. There were eight AEs (9%) (3 mild, 5 moderate). Overall, clinical success was achieved in 84 patients (94%). Mean dysphagia, regurgitation, and respiratory scores all improved dramatically from  $2.1 \pm 0.8$ ,  $2.8 \pm 1.3$ , and  $1.8 \pm 1.6$  pre-procedure to  $0.13 \pm 0.5$ ,  $0.11 \pm 0.5$ , and  $0.05 \pm 0.4$ , respectively, post-procedure at most recent follow-up (all  $P < 0.0001$ ). Recurrence occurred in six patients (6.7%) during a mean length of follow-up of 37 months (range 24 to 63 months).

**Conclusions** Z-POEM is a highly safe and effective treatment for Zenker's diverticulum with durable treatment effect to at least 2 years.

submitted 28.12.2022

accepted after revision 30.3.2023

accepted manuscript online 3.4.2023

## Bibliography

Endosc Int Open 2023; 11: E607–E612

DOI 10.1055/a-2067-9105

ISSN 2364-3722

© 2023. The Author(s).

This is an open access article published by Thieme under the terms of the Creative Commons Attribution-NonDerivative-NonCommercial License, permitting copying and reproduction so long as the original work is given appropriate credit. Contents may not be used for commercial purposes, or adapted, remixed, transformed or built upon. (<https://creativecommons.org/licenses/by-nc-nd/4.0/>)

Georg Thieme Verlag KG, Rüdigerstraße 14,  
70469 Stuttgart, Germany

## Corresponding author

Mouen A. Khashab, MD, Professor of Medicine, Johns Hopkins Hospital, Division of Gastroenterology and Hepatology, 600 N. Wolfe St, Blalock 411, Baltimore, MD 21287, Director of Therapeutic Endoscopy, Johns Hopkins Hospital, Division of Gastroenterology and Hepatology, 1800 Orleans Street, Suite

## Introduction

Zenker's diverticulum (ZD) is a sac-like outpouching of the mucosa and submucosa of the esophagus through Killian's triangle, an area of muscular weakness in the inferior pharyngeal constrictor muscle of the hypopharynx between the cricopharyngeus and thyropharyngeus muscles [1].

Surgical diverticulotomy is the traditional management of ZD; however, it is associated with substantial morbidity and mortality, largely due to associated comorbidities in this patient population [2,3]. Endoscopic septotomy, which involves incision through the septum to connect the diverticulum and esophageal lumen, has been developed as a less invasive alternative to surgical management [4]. Compared to surgical intervention, septotomy has been shown to have lower morbidity and mortality, lower rates of adverse events (AEs), and shorter procedure and recovery time [5,6]. However, it has a high rate of recurrence with symptoms recurring in greater than 10% of patients largely attributed to incomplete division of the septum [5,7].

More recently, peroral endoscopic myotomy (POEM), originally developed for the treatment of achalasia, has been adapted to treatment of ZD (Z-POEM) [8,9]. POEM involves creation of a submucosal tunnel that results in complete exposure and division of the septum. Short-term follow-up of up to 1 year post Z-POEM suggests excellent efficacy and safety with technical and clinical success in more than 90% of patients [9–14]. However, long-term outcomes are unknown. Thus, we sought to report on longer-term outcomes ( $\geq 2$  years) following Z-POEM for treatment of ZD.

## Patients and methods

### Study population

This was an International multicenter retrospective observational cohort study at eight institutions across North America, Europe, and Asia including the United States, France, India, and Mexico, over a 5-year period (from March 3, 2015 to March 13, 2020) of 89 patients who underwent Z-POEM for management of ZD with a minimum 2-year follow-up. The diagnosis of ZD was made based on barium esophagram, computed tomography scan, magnetic resonance imaging, and/or endoscopy. Inclusion criteria included symptomatic Zenker's diverticulum managed with Z-POEM, with at least 2-year follow up in patients age  $\geq 18$  years old. A total of 104 Z-poem procedures were performed over this period (15 cases were not included). Cases not included were almost entirely due to loss to follow-up. Exclusion criteria included follow up duration  $< 2$  years and age  $< 18$  years old. Patients were identified using center-specific endoscopy or billing databases. Electronic medical records were reviewed to capture required variables. The study was approved by individual institutional review boards at participating centers. 75% ( $n=67$ ) of patients included in this study were included in prior Z-POEM studies [10,11,15]. These prior studies looked at short-term outcomes and outcome data in this study were not previously published.

### Study variables

Demographic data collected for each patient included age, physical status (American Society of Anesthesiologists [ASA] classification), anti-thrombotic agent use, prior interventions, preoperative severity of dysphagia, regurgitation, and respiratory symptoms, and diverticulum size. Procedural data collected included peri-procedural antibiotic use, anesthesia type, incisional tool used, site of mucosal incision, submucosal fibrosis presence, success of submucosal tunneling, use of hybrid POEM/septotomy, tunnel length, presence of additional mucosal flap incision, procedure length, intra-procedure AEs, their management and severity, closure technique. Post-procedure data collected included post-procedural AEs, presence of leak on post-procedural imaging and their management, and hospital length of stay. Follow-up data to at least 2 years were collected including severity of dysphagia, regurgitation, and respiratory symptoms as well as need for further treatment.

### Study outcomes

Dysphagia severity was measured pre- and post Z-POEM using the modified Dakkak and Bennett score (mDB), which grades dysphagia from 0 (no dysphagia) to 4 (total dysphagia/inability to eat) [16–18]. Regurgitation and respiratory symptoms (cough and aspiration) were graded with previously described numeric scales. Regurgitation was graded from 0 (no regurgitation) to 4 (daily regurgitation). Respiratory symptoms were graded from 0 (no cough or aspiration) to 4 (daily episodes of coughing or aspiration) (► **Table 1**) [17,18].

The primary outcome was clinical success, defined as improvement in mDB (dysphagia) score to  $\leq 1$  if the pre-procedure dysphagia score was  $> 1$  and 0 if the pre-procedure score was 1 without need for further procedures during the first 6 months. Secondary outcomes included technical success (complete myotomy as intended), rate of recurrence (dysphagia score  $\geq 2$  later than 6 months post procedure) in patients initially meeting clinical success, rate of reintervention, and AEs. AEs were graded based on their severity according to the American Society for Gastrointestinal Endoscopy (ASGE) lexicon [19].

### Statistical analysis

Statistical analysis was performed using Prism Graphpad, Version 9 (Graphpad Inc, San Diego, California, United States). For continuous data, results were reported as mean and standard deviation or median and interquartile range. Categorical data were reported as proportions. Student's *t*-test was used to compare response to treatment. The threshold for statistical significance was set at a  $P=0.05$ .

Categorical variables were reported as mean and standard deviation (SD) or median and interquartile range (IQR). Categorical variables were reported as proportions. A paired *t*-test was used to analyze post-treatment symptom response.  $P<0.05$  was considered statistically significant. Statistical analyses were performed using Stata 17.0 (StataCorp, College Station, Texas, United States).

► **Table 1** Scoring systems used to assess dysphagia severity.

Score	Dysphagia score (Modified Dakkak and Bennett Score; mDB)	Regurgitation score	Respiratory symptom score (cough or aspiration)
0	No dysphagia	Asymptomatic	Asymptomatic
1	Solid dysphagia	<once/week	<once/week
2	Semi-solid dysphagia	>once/week but <once/day	>once/week but <once/day
3	Liquid dysphagia	Once/day	Once/day
4	Complete dysphagia	Daily	Daily

## Results

### Baseline characteristics

Eighty-nine patients were included in this retrospective study. The mean age of the patients was 71.5 ± 12.4 years and 57.3% (n = 51) were men (► **Table 2**). The mean diverticulum size was 34 ± 13.5 mm (range 8 to 80).

The median ASA classification was 2. Nine percent of patients (n = 8) were ASA 1, 45% (n = 40) were ASA 2, 43% were ASA 3 (n = 38), 3% (n = 3) were ASA 4, and none were ASA 5. Fifty-three percent of patients (n = 47) were on a blood thinner: 42% (n = 38) were on antiplatelet medications and 11% (n = 10) were on an anticoagulant. This was the first intervention for ZD in 78.7% of patients (n = 70), 7.9% (n = 7) had prior open surgery, 7.9% (n = 7) had prior rigid diverticulotomy, 6.7% (n = 6) had prior flexible diverticulotomy, 2.2% (n = 2) had prior dilation, 1.1% (n = 1) had prior cricopharyngeal Botox injection, and 1.1% (n = 1) had prior Z-POEM.

### Procedural characteristics and technical outcomes

Antibiotic use was almost universal with 98.9% of patients (n = 88) receiving antibiotics. Most patients received both pre- and post-procedure antibiotics (64%, n = 57) and 35% (n = 31) received only pre-procedure antibiotics. Most patients received general anesthesia (n = 81, 91%). The most used endoscopic knife was the I-Type Hybrid Knife (Erbe, Marietta, Georgia, United States) which was used in 48.3% of cases (n = 43), followed by the SB knife (Olympus, Center Valley, Pennsylvania, United States) used in 20.2% of cases (n = 18). Less commonly the T-Type Hybrid Knife (Erbe, Marietta, Georgia, United States) and the Triangle Tip Knife (Olympus, Center Valley, Pennsylvania, United States) were used (13.5%, n = 12) cases (► **Table 3**).

Mucosal incision was predominantly made over the septum (66.3%, n = 59) rather than proximal to the septum (33.7%, n = 30). Submucosal fibrosis was encountered in 29.2% of cases (n = 26). Submucosal tunneling was successful in 96.6% of cases (n = 86) with failure only occurring in 3.4% of cases (n = 3). All the cases in which there was failure to tunnel had submucosal fibrosis. Two of the three cases had standard endoscopic septotomy completion during the same procedure, and overall achieved technical success (successful completion of myotomy) (► **Table 3**).

Eleven percent of cases (n = 10) used a hybrid technique combining standard endoscopic septotomy with tunneling ap-

► **Table 2** Demographic data for the included patients (n = 89).

Age (years)	
▪ Range	36–93
▪ Mean (SD)	71 (12)
Gender (number, %)	
▪ Male	51 (57.3)
▪ Female	38 (42.7)
ASA PS classification (number, %)	
▪ ASA 1	8 (9)
▪ ASA 2	40 (44.9)
▪ ASA 3	38 (42.7)
▪ ASA 4	3 (3.4)
▪ ASA 5	0 (0)
Diverticulum size (mm)	
▪ Range	8–80
▪ Mean (SD)	33.6 (13.5)
Previous therapies (number, %)	
▪ No prior procedure	70 (78.6)
▪ Surgery	7 (7.9)
▪ Rigid diverticulotomy	7 (7.9)
▪ Flexible diverticulotomy	6 (6.7)
▪ Z-POEM	1 (1.1)
ASA, American Society of Anesthesiologists; PS physical status; SD, standard deviation; Z-POEM, Zenker's peroral endoscopic myotomy.	

proach. The average tunnel length was 35 mm ± 14.1 mm. An additional mucosal flap incision following transection of the cricopharyngeus/septum was performed in 4.5% of cases (n = 4). Average ZD size in patients with additional mucosal flap incision with 55 mm. Average procedure time was 44 ± 19 minutes (► **Table 3**).

Technical success was achieved in 97.8% of patients (n = 87). Technical failure occurred in two patients and was due to submucosal fibrosis with inability to tunnel in one patient with a 5cm diverticulum and prior rigid diverticulotomy. The other pa-

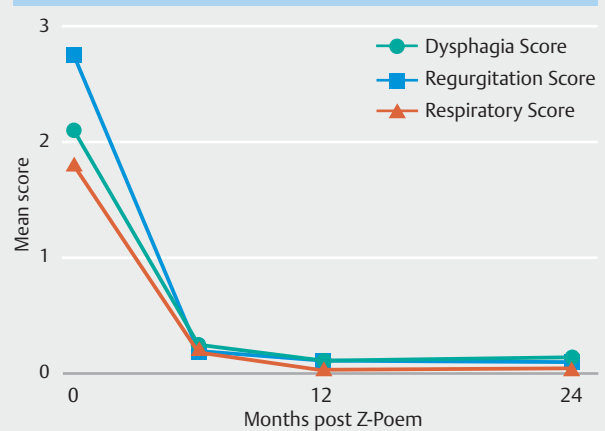
► **Table 3** Treatment outcomes.

Procedural characteristics	
Mucosal incision site (n, %)	
Over the septum	59 (66.3%)
Proximal to the septum	30 (33.7%)
Submucosal fibrosis (n, %)	26 (29.2%)
Submucosal tunneling success (n, %)	86 (96.6%)
Hybrid technique (n, %)	10 (11%)
Tunnel length, mm (mean ± SD)	35 ± 14.1
Incomplete septostomy (n, %)	2 (2.2%)
Procedure time minutes (mean ± SD)	44 ± 19
Technical success (n, %)	87 (97.8%)
Clinical outcomes	
Hospital length of stay, days (mean ± SD)	1.7 ± 1.5
Post-procedural adverse events (n, %)	8 (8.9%)
▪ Mild	3 (3.4%)
▪ Moderate	5 (5.6%)
▪ Severe	0
Mean dysphagia score (SD)	
Pre-procedure	2.1 (0.8)
Follow-up <sup>1</sup>	0.13 (0.5)
Mean regurgitation score (SD)	
▪ Pre-procedure	2.8 (1.3)
▪ Follow-up <sup>1</sup>	0.11 (0.5)
Mean respiratory score (SD)	
▪ Pre-procedure	1.8 (1.6)
▪ Follow-up <sup>1</sup>	0.05 (0.4)
Clinical success (n, %)	84 (94%)
Recurrence (n, %)	6 (6.7%)
Follow-up length (months)	
▪ Mean ± SD	37
▪ Range	24–63
SD, standard deviation.	
<sup>1</sup> Follow-up is most recent follow-up (minimum 2 years).	

tient with a 4.5-cm diverticulum had incomplete septotomy, and subsequently underwent standard flexible endoscopic septotomy (► **Table 3**).

Mild intra-procedure bleeding was noted in seven patients (7.8%) managed either conservatively or with endoscopic treatment during the index procedure. There were seven inadvertent mucosotomies (7.8%) noted during the index procedure that were managed during the index procedure. None of these events were considered AEs per ASGE lexicon because

Measures of Zenker's Diverticulum pre and post Z-PEOM



► **Fig. 1** Measures of Zenker's diverticulum severity pre- and post Z-PEOM. Dysphagia score, regurgitation score, and respiratory scores were calculated pre-Z-PEOM and at 6, 12, and 24 months post Z-PEOM. Mean score was calculated and plotted for each time point. All measures of ZD severity remain low throughout the study period. Dysphagia score: 4 = complete dysphagia, 3 = dysphagia to liquids, 2 = dysphagia to semi-solids, 1 = dysphagia to solids, and 0 = no dysphagia. Regurgitation score: Daily regurgitation = 4, once/day = 3, >once/week but <once/day = 2, <once/week = 1. None = 0. Respiratory score: daily respiratory symptoms = 4, once/day = 3, >once/week but <once/day = 2, <once/week = 1, asymptomatic = 0.

they were managed during the index procedure, did not require further treatment and did not result in prolongation of hospital stay.

### Clinical outcomes

The average post-procedure hospital stay was 1.7 ± 1.5 days. There were eight AEs (8.9% of patients) within 30 days post-procedure. For individuals who received an incision over the septum there were four recurrences (6.8% recurrence rate) and five AEs (8.5%). For individuals who received a proximal to the septum incision there were two recurrences (6.7% recurrence rate) and three AEs (10%). Based on Chi square analysis (Fisher's exact test), there was no statistically significant association between incision site and recurrence or incision site and AEs.

A post-procedure esophagram was obtained in 76% of cases (n = 68). Esophagram-detected leak was present in 3.4% of patients (n = 3), managed conservatively in one (graded as mild) and endoscopically in two (therefore graded as moderate). Post-procedure bleeding occurred in 3.4% of patients (n = 3) and was managed endoscopically in all (moderate severity AE). There was a single case each of aspiration pneumonia and pneumomediastinum, each managed conservatively (mild severity AE).

Overall, clinical success was achieved in 94% of patients (n = 84). There were three clinical failures in addition to the two technical failures described previously. Dysphagia, regurgita-

tion, and respiratory symptom scores all improved dramatically and remained low post Z-POEM (► Fig. 1).

The mean length of follow-up was  $37 \pm 11$  months (range 24 to 63). The primary outcome, mean dysphagia (mDB) score, improved significantly from  $2.1 \pm 0.8$  pre-procedure to  $0.13 \pm 0.5$  at most recent follow-up ( $P < 0.0001$ ). Mean regurgitation and respiratory scores also improved dramatically from  $2.8 \pm 1.3$ , and  $1.8 \pm 1.6$ , respectively, pre-procedure to  $0.11 \pm 0.5$ , and  $0.05 \pm 0.4$  respectively post-procedure at most recent follow-up ( $P < 0.0001$ ) (► Table 2). Recurrence occurred in 6.7% of patients ( $n = 6$ ). We evaluated several potential predictors of recurrence including pre-procedure symptom scores and diverticulum size but we were unable to identify any statistically significant predictors of dysphagia recurrence.

## Discussion

Z-POEM has become a standard treatment for ZD management both for treatment-naïve and previously treated patients. Previous studies have demonstrated safety and short-term efficacy of Z-POEM [10, 11, 15]. Our previous international retrospective study of 75 patients with ZD demonstrated high technical (97.3%) and clinical (92%) success rates and a low AE rate (6.7%) with median follow-up of 291.5 days and only one recurrence at 12-month follow-up [15]. A second smaller retrospective study of 24 patients showed no recurrence of clinical symptoms at 12 months although only 45.8% of patients remained in follow-up long enough to evaluate for recurrence [11]. A larger retrospective study of 245 patients which compared septotomy with Z-POEM demonstrated a similar high clinical success (92%), although with a higher recurrence rate of 14.7% during a mean follow-up of 282 days [10]. Overall, these studies demonstrate that Z-POEM is a highly successful procedure with variable recurrence between 0% and 14.7% with short follow-up periods of less than 12 months. Here, we aimed to evaluate the efficacy at longer-term follow-up, with a minimum of 2 years.

Our study represents the longest follow-up to date of patients after Z-POEM with a mean follow-up of over 3 years but with some patients with follow-up out to 5 years. In our cohort of 89 patients, we had a low incidence of clinical recurrence (6.7%). Difference in recurrence rates between studies may be due to individual proceduralist expertise or differences in the study populations in these various retrospective studies.

These results demonstrate the excellent treatment durability of Z-POEM.

Multiple studies have reported outcomes associated with endoscopic septotomy; success rates are typically between 56% and 100% with symptoms recurring in 10% to 35% of patients [7, 20]. The high rate of recurrence had been attributed to incomplete division of the septum [21, 22]. Our data suggest a lower recurrence rate for Z-POEM. Our results also recapitulate previous studies demonstrating excellent safety profile, high technical success, and clinical success. Our study includes both tertiary institutions as well as private practitioners and treatment outcomes appear similar across both types of practices.

Although these results are promising, there are limitations to this study. The estimated recurrence rate may also be underestimated by the short length of follow-up we have at hand because Z-POEM was only developed several years ago. Longer-term studies (i. e. with >5- or 10-year follow-up) may reveal a higher recurrence rate. Being a retrospective study, our study is at risk of bias in patient selection and procedure decisions. In addition, given that Z-POEM is a rather new technique, there may be variability in technical details across practitioners and institutions. On the other hand, endoscopic septotomy could be more technically accessible than Z-POEM and expertise needed for the POEM procedure can reduce its wider availability to patients. In addition, we suspect that the relatively small sample size is likely the reason why we were unable to identify any statistically significant predictors of recurrence. In the future, a larger patient cohort may allow this kind of information to be obtained. As the Z-POEM technique becomes more commonplace, we suspect we will have access to a larger cohort. Nonetheless, our findings make apparent the excellent treatment durability of Z-POEM.

## Conclusions

This international multicenter study demonstrated that Z-POEM is a highly safe and effective treatment for Zenker's diverticulum with durable treatment effect to at least 3 years, but likely longer. This is a safe, minimally invasive option for management of ZD, which afflicts a largely elderly and frail patient population. Future prospective studies with longer-term follow-up are required to determine even longer-term outcomes.

## Competing interests

Mouen A. Khashab is a consultant for Boston Scientific, Olympus America, Medtronic and GI Supply. Nikhil A. Kumta is a consultant for Apollo Endosurgery, Boston Scientific, Olympus, SafeHeal. Mathieu Pioche is a consultant for Boston scientific, Cook medical, Olympus, Pentax, Provepharm, Norgine. Jeremie Jacques is a consultant and is involved in training for Erbe, Fujifilm, Boston Scientific, Olympus. Jose M. Nieto is a Consultant for Boston Scientific and AbbVie Inc; honoraria from Erbe USA. Michael Ujiki is a Scientific board member for Boston Scientific, a Consultant for Cook, a Consultant for Olympus, a Consultant and speaker for WL Gore and Associates, and a Speaker for Medtronic. All other authors disclose no conflicts of interest.

## References

- [1] Bizzotto A, Iacopini F, Landi R et al. Zenker's diverticulum: exploring treatment options. *Acta Otorhinolaryngol Ital* 2013; 33: 219–229
- [2] Yuan Y, Zhao YF, Hu Y et al. Surgical treatment of Zenker's diverticulum. *Dig Surg* 2013; 30: 207–218
- [3] Keck T, Rozsasi A, Grün PM. Surgical treatment of hypopharyngeal diverticulum (Zenker's diverticulum). *Eur Arch Otorhinolaryngol* 2010; 267: 587–592
- [4] Case DJ, Baron TH. Flexible endoscopic management of Zenker diverticulum: the Mayo Clinic experience. *Mayo Clin Proc* 2010; 85: 719–722

- [5] Albers DV, Kondo A, Bernardo WM et al. Endoscopic versus surgical approach in the treatment of Zenker's diverticulum: systematic review and meta-analysis. *Endosc Int Open* 2016; 4: E678–E686
- [6] Calavas L, Brenet E, Rivory J et al. Zenker diverticulum treatment: retrospective comparison of flexible endoscopic window technique and surgical approaches. *Surg Endosc* 2021; 35: 3744–3752
- [7] Ishaq S, Hassan C, Antonello A et al. Flexible endoscopic treatment for Zenker's diverticulum: a systematic review and meta-analysis. *Gastrointest Endosc* 2016; 83: 1076–1089.e1075
- [8] Inoue H, Minami H, Kobayashi Y et al. Peroral endoscopic myotomy (POEM) for esophageal achalasia. *Endoscopy* 2010; 42: 265–271
- [9] Brieau B, Leblanc S, Bordacahar B et al. Submucosal tunneling endoscopic septum division for Zenker's diverticulum: a reproducible procedure for endoscopists who perform peroral endoscopic myotomy. *Endoscopy* 2017; 49: 613–614
- [10] Al Ghamdi SS, Farha J, Moran RA et al. Zenker's peroral endoscopic myotomy, or flexible or rigid septotomy for Zenker's diverticulum: a multicenter retrospective comparison. *Endoscopy* 2022; 54: 345–351
- [11] Elkholy S, El-Sherbiny M, Delano-Alonso R et al. Peroral endoscopic myotomy as treatment for Zenker's diverticulum (Z-POEM): a multicenter international study. *Esophagus* 2021; 18: 693–699
- [12] Balassone V, Pizzicannella M, Biasutto D et al. Submucosal per-oral endoscopic myotomy for a large Zenker's diverticulum with use of a hydrodissector knife and an over-the-scope clip closure. *VideoGIE* 2018; 3: 373–374
- [13] Hernández Mondragón OV, Solórzano Pineda MO, Blancas Valencia JM. Zenker's diverticulum: Submucosal tunneling endoscopic septum division (Z-POEM). *Dig Endosc* 2018; 30: 124
- [14] Brewer Gutierrez OI, Ichkhanian Y, Spadaccini M et al. Zenker's diverticulum per-oral endoscopic myotomy techniques: changing paradigms. *Gastroenterology* 2019; 156: 2134–2135
- [15] Yang J, Novak S, Ujiki M et al. An international study on the use of peroral endoscopic myotomy in the management of Zenker's diverticulum. *Gastrointest Endosc* 2020; 91: 163–168
- [16] Dakkak M, Bennett JR. A new dysphagia score with objective validation. *J Clin Gastroenterol* 1992; 14: 99–100
- [17] Battaglia G, Antonello A, Realdon S et al. Flexible endoscopic treatment for Zenker's diverticulum with the SB Knife. Preliminary results from a single-center experience. *Dig Endosc* 2015; 27: 728–733
- [18] Zhang LY, Wu PI, Szczesniak M et al. Clinical utility of cricopharyngeal distensibility measurements during endoscopic myotomy for Zenker's diverticulum. *Gastrointest Endosc* 2021; 93: 390–397
- [19] Cotton PB, Eisen GM, Aabakken L et al. A lexicon for endoscopic adverse events: report of an ASGE workshop. *Gastrointest Endosc* 2010; 71: 446–454
- [20] Halland M, Grooteman KV, Baron TH. Flexible endoscopic management of Zenker's diverticulum: characteristics and outcomes of 52 cases at a tertiary referral center. *Dis Esophagus* 2016; 29: 273–277
- [21] Verdonck J, Morton RP. Systematic review on treatment of Zenker's diverticulum. *Eur Arch Otorhinolaryngol* 2015; 272: 3095–3107
- [22] Repici A. Endoscopic treatment of zenker diverticulum. *Gastroenterol Hepatol (NY)* 2010; 6: 628–630