



## The association between clinical symptoms of lumbar spinal stenosis and MRI axial imaging findings

Yuki Fushimi, Koji Otani, Ryoji Tominaga, Masataka Nakamura, Miho Sekiguchi  
and Shin-ichi Konno

*Department of Orthopaedic Surgery, Fukushima Medical University School of Medicine, Fukushima, Japan*

(Received August 24, 2021, accepted October 27, 2021)

### Abstract

**Purpose :** In diagnosing lumbar spinal stenosis (LSS), Magnetic Resonance Imaging (MRI) is appropriate to confirm the presence of anatomical stenosis of the spinal canal or compression of the nerve roots. However, it is known that morphological LSS is often present in asymptomatic subjects. There is still controversy about the relationship between anatomical LSS and symptomatic LSS. The aim of this study was to assess the association between qualitative imaging findings on MRI of the lumbar spine and symptomatic LSS.

**Patients and methods :** This was a cross-sectional study of 239 volunteers from an epidemiological survey that included 1,862 participants in total. MRI of the lumbar spine was evaluated in four categories : morphological grading of central stenosis and lateral recess stenosis, presence of the sedimentation sign, and severity of facet joint effusion. The relationship between these morphological evaluations and typical LSS symptoms as assessed by the self-administered, self-reported history questionnaire for lumbar spinal stenosis (LSS-SSHQ) was investigated by multiple logistic regression analysis.

**Results :** The odds ratio of the most severe central stenosis to no stenosis was 15.5 (95%CI : 1.4-164.9). Only the most severe central stenosis was associated with typical LSS symptoms, but not all cases with typical LSS symptoms were due to severe central stenosis.

**Conclusion :** Extreme severe central stenosis was strongly related to typical LSS symptoms. However, although subjects with severe central stenosis showed symptoms suggestive of LSS, these subjects did not always show typical LSS symptoms.

**Key words :** cross-sectional study, central stenosis, lateral recess stenosis, sedimentation sign, facet joint effusion

### Introduction

Lumbar spinal stenosis (LSS) is characterized by narrowing of the spinal canal including the central spinal canal, in the area under the facet joints (sub-articular, lateral recess, or foraminal stenosis), or far laterally (extraforaminal stenosis)<sup>1-3)</sup>. The anatomical condition of LSS causes variable clinical symptoms, such as gluteal and/or lower extremity pain,

numbness, and/or neurogenic intermittent claudication. These symptoms are thought to be caused by the diminished space available for the neural and vascular elements. However, the pathogenesis of LSS is not fully clarified, and there is no definition with clear criteria for the imaging findings and clinical symptoms<sup>1,4)</sup>.

Magnetic resonance imaging (MRI) is appropriate to confirm the anatomical condition of the spinal

Corresponding author : Koji Otani E-mail : kotani@fmu.ac.jp

©2021 The Fukushima Society of Medical Science. This article is licensed under a Creative Commons [Attribution-NonCommercial-ShareAlike 4.0 International] license.

<https://creativecommons.org/licenses/by-nc-sa/4.0/>

canal or compression of the nerve roots. However, it is known that radiographic LSS is found in asymptomatic patients<sup>5</sup>. According to the North American Spine Society (NASS) Guideline of LSS, there is insufficient evidence for a correlation between clinical symptoms or function with the anatomic narrowing of the spinal canal on imaging<sup>4</sup>. One of the reasons for this might be variations in assessment methods due to the lack of clear criteria for the assessment of imaging findings.

In recent studies, the most commonly used method for evaluating anatomical spinal stenosis on imaging was dural sac cross-sectional area (DCSA)<sup>4,6-10</sup>. However, the correlation between DCSA and symptoms is still controversial. In addition, the measurement of DCSA is not easy in routine clinical settings; therefore, a well-defined and simple morphological classification for evaluating the severity of anatomical spinal stenosis would be useful. Moreover, DCSA is insufficient to evaluate nerve root impingement due to lateral recess stenosis (LRS), since DCSA does not include the lateral recess. LRS is most commonly caused by degenerative changes of the spine, such as facet joint osteoarthritis, ligamentum flavum hypertrophy, intervertebral disc degeneration, and endplate spurs<sup>2,11,12</sup>. Therefore, central stenosis and LRS should be evaluated separately for anatomical spinal stenosis. Furthermore, there are other findings associated with anatomical spinal stenosis, such as the sedimentation sign and facet joint effusion (FJE), which are considered to be related to symptomatic LSS<sup>13-17</sup>. However, evidence for a correlation between clinical symptoms and anatomic stenosis on imaging is still insufficient. Since most previous studies were hospital-based and their control groups

had diseases other than LSS, the results are unlikely to be generalizable. Therefore, there is a need for population-based studies with higher external validity. The main objective of this study was to evaluate the association between qualitative assessments of MRI axial images of the lumbar spine and symptomatic LSS in a community cohort.

## Materials and methods

This study was approved by the ethics committee of Fukushima Medical University School of Medicine (Approval No. 295). All participants gave their written informed consent to participate in the study.

### Participants

This cross-sectional study was based on an epidemiological survey from 2004, for which 1,862 people (697 males and 1,165 females) enrolled when a routine public health survey was conducted by their local governments in Tadami Town, Tateiwa Village, and Ina Village of Fukushima Prefecture. Their ages ranged from 19 to 93 years<sup>18</sup>. Of the 1,862 survey participants, 459 agreed to undergo lumbar spine MRI for additional assessment. Participants with no cerebral infarction or bleeding history who could walk independently were included. The exclusion criteria were if they were unable to walk independently, fill out questionnaires due to visual impairment, or had ever undergone brain or spinal surgery. Those without sufficient imaging findings in all classifications or those with missing questionnaire data were excluded, leaving 239 who were analysed in the present study (Figure 1).

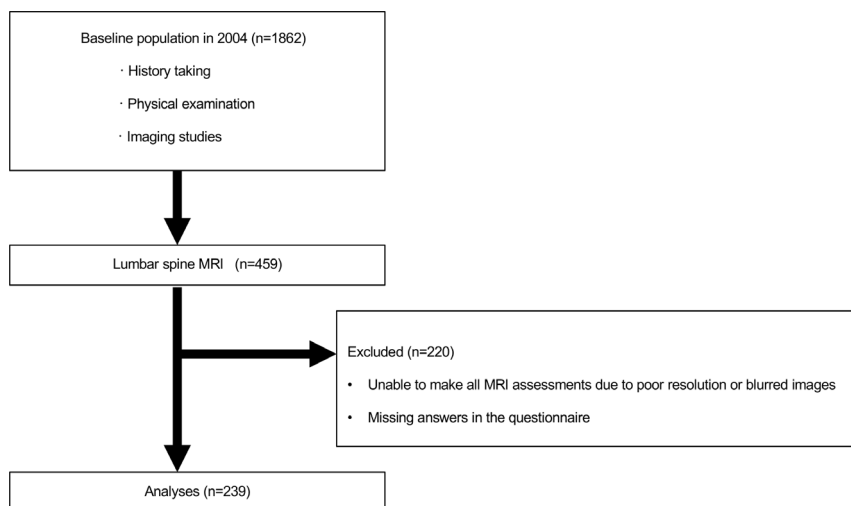


Fig. 1. Flow chart of the analysis for evaluation of MRI.

### Assessment of MRI

Axial T2-weighted images were obtained at each level of the vertebral bodies and intervertebral discs from L1 to S1. The details of the MRI imaging conditions are shown in Table 1.

The classifications of central stenosis, LRS, the sedimentation sign, and FJE were evaluated using MRI (Table 2)<sup>2,13,19,20</sup>. Central stenosis, nerve root compression by classification of LRS, and FJE were evaluated in the axial images of each intervertebral disc level from L1-2 to L5-S1. For all findings, the highest grade was used as representative for analysis. To evaluate the intra/inter-observer reliabilities of each classification, two orthopaedic surgeons (YF & MN) did independent evaluations two times every two weeks. According to the sample size calculation estimating  $\rho = 0.8$  with 0.4 of 95% confidence interval rated by two examiners, at least 20 subjects would be needed. Therefore, 30 subjects were randomly selected for determination using kappa analysis<sup>21</sup>. The *intra*-observer reliabilities were determined to be substantial for the assessment of central stenosis, the sedimentation sign, and

Table 1. MRI specifications and utilization

Manufacturer	Philips	Toshiba
Product name	Gyroscan Intera Power	EXCELART/P2 Pianissimo
Tesla	1.0 T	1.5 T
Slice thickness (mm)	5	5
Slice gap (mm)	0.5	1
TE (ms)	120	108
TR (ms)	4,500	4,000
No. of participants	170	69

**Abbreviations** : MRI, magnetic resonance imaging ; TE, echo time ; TR, repetition time.

FJE (0.68, 0.71, and 0.70, respectively) and moderate for the assessment of LRS (0.54). The *inter*-observer reliabilities were determined to be substantial for the assessment of central stenosis, the sedimentation sign, and FJE (0.65, 0.68, and 0.63, respectively) and fair for the assessment of LRS (0.31). Therefore, the *intra*-observer and *inter*-observer reliabilities were considered acceptable. Finally, one orthopaedic surgeon (YF) examined the images without any participants' information, includ-

Table 2. Classifications of MRI findings

<b>Central stenosis</b>	Schizas C <i>et al.</i> <sup>19</sup>
Grade A	There is clearly CSF visible inside the dural sac, but its distribution is inhomogeneous.
Grade B	The rootlets occupy the whole of the dural sac, but they can still be individualized. Some CSF is still present giving a grainy appearance to the sac.
Grade C	No rootlets can be recognized, the dural sac demonstrating a homogeneous gray signal with no CSF signal visible. There is epidural fat present posteriorly.
Grade D	In addition to no rootlets being recognizable, there is no epidural fat posteriorly.
<b>Lateral recess stenosis (LRS)</b>	Bartynski WS <i>et al.</i> <sup>2</sup>
Grade 0	Normal
Grade 1	Reduced size of the corner of the lateral canal or recess ; trefoil shape to the lateral recess, either congenital or acquired ; early acute angular narrowing of the corner of the canal and thecal sac ; nerve root is visualized and not widened, flattened, or altered.
Grade 2	Reduced size of the corner of the lateral canal or lateral recess, trefoil shape and narrowing of the lateral recess, angular pinch-like shape and narrowing of the lateral canal and thecal sac, nerve root judged compressed in the small trefoil recess or angled pinch but recess judged not totally obliterated, nerve root may be deviated medially.
Grade 3	Severe facet hypertrophy and disc/end plate changes, no CSF or space identified in the lateral recess or corner of the canal, severe angular pinch of the lateral corner of the canal, root may or may not be clearly visible, root may be seen coursing through the compressed lateral recess, root may be seen as medially displaced.
<b>Sedimentation sign</b>	Barz T <i>et al.</i> <sup>13</sup>
Positive	The absence of nerve root sedimentation.
<b>Facet joint effusion (FJE)</b>	Chaput C <i>et al.</i> <sup>20</sup>
Grade 0	No effusion
Grade 1	Measurable effusion < 1.5 mm
Grade 2	Large effusion > 1.5 mm

**Abbreviations** : CSF, cerebrospinal fluid.

ing their symptoms. The highest severity of each classification in individual subjects was used as the representative value in the analysis.

#### Assessment of clinical symptoms

The presence or absence of typical LSS symptoms was determined using the LSS-SSHQ to standardize self-reporting of symptoms. The LSS-SSHQ was developed for the identification of LSS based solely on self-reported patient information. This questionnaire is a just a screening tool for LSS, therefore not all symptomatic LSS cases could be detected. In order to identify symptomatic LSS by a self-reported questionnaire, a cut-off value is set even though false positive and negative cases were limitations for the diagnosis of LSS. "Symptomatic LSS as assessed by LSS-SSHQ" will be referred to as "typical LSS symptoms" in this study. LSS-SSHQ consists of 10 question items and has a sensitivity of 84%, specificity of 78%, positive likelihood ratio of 1.89, and negative likelihood ratio of 0.21 according to the validation study<sup>22)</sup>. Evidence grading has established that the SSHQ can be useful to assist with providing clinical evidence of lumbar spinal stenosis as level II diagnostic evidence by the Degenerative Lumbar Spinal Stenosis Work Group of the North American Spine Society's Evidence-Based Clinical Guideline Development Committee<sup>4)</sup>.

#### Statistical analysis

Baseline characteristics are described using appropriate summary statistics. Univariate analysis of the correlation between each MRI finding and typical LSS symptoms was performed using the chi-squared test and Cochran-Armitage's propensity test. Then, all MRI findings were tested for multicollinearity. After variables were removed if they showed a correlation of over  $r = 0.70$  with any other variables in the model<sup>23)</sup>, on multivariate analysis, adjusted odds ratios (ORs) were estimated using a logistic regression model with adjustments for age and sex. A two-sided  $p < 0.05$  was considered significant. Statistical analyses were performed using IBM SPSS Statistics for Windows, ver. 26 (IBM Corp., Armonk, NY, USA) and R ver. 3.5.3 (The R Foundation, Vienna, Austria).

## Results

#### Demographic data

The 239 participants consisted of 86 men and 153 women. Their mean age was 65.3 years, and most participants were aged over 70 years. The demographic data are shown in Table 3.

Central stenosis of grade B or higher was observed in 46% of the participants. LRS was observed in 96.7%, with Grade 2 the most common, at 41.0%. The sedimentation sign was positive in 33.5% of the participants. With regard to FJE, only 2.1% of participants were assessed as having no FJE, and 97.9% had FJE. There were no significant differences in MRI findings of all classification between the sexes (Table 3). The distribution of grades in three classifications are shown in Table 4 and the almost all of the severe MRI findings were observed at L3/4 or L4/5. Furthermore, grades of MRI findings progressed with age in all classifications (Figure 2).

Table 3. Demographic characteristics of participants

	Total <i>n</i> =239	Male <i>n</i> =86	Female <i>n</i> =153
<b>Age (y) (mean ±SD)</b>	65.3±11.0	65.4±11.3	65.3±10.9
<b>BMI (kg/m<sup>2</sup>)</b>	23.4±3.1	23.3±3.0	23.4±3.1
<b>Distribution of age (y) (<i>n</i> [%])</b>			
<50	18 (7.5)	7 (8.1)	11 (7.2)
50-59	46 (19.2)	17 (19.8)	29 (20.0)
60-69	78 (32.6)	26 (30.2)	52 (34.0)
≥70	97 (40.6)	36 (41.9)	61 (39.9)
<b>Classifications of MRI (<i>n</i> [%])</b>			
Central stenosis			
Grade A	129 (54.0)	44 (51.2)	85 (55.6)
Grade B	73 (30.5)	28 (32.6)	45 (29.4)
Grade C	30 (12.6)	11 (12.8)	19 (12.4)
Grade D	7 (2.9)	3 (3.5)	4 (2.6)
LRS			
Grade 0	8 (3.3)	3 (3.5)	5 (3.3)
Grade 1	67 (28.0)	25 (29.1)	42 (27.5)
Grade 2	98 (41.0)	30 (34.9)	68 (44.4)
Grade 3	66 (27.6)	28 (32.6)	38 (24.8)
Sedimentation sign			
Positive	80 (33.5)	28 (32.6)	52 (34.0)
Negative	159 (66.5)	58 (67.4)	101 (66.0)
FJE			
Grade 0	5 (2.1)	1 (1.2)	4 (2.6)
Grade 1	171 (71.5)	59 (68.6)	112 (73.2)
Grade 2	63 (26.4)	26 (30.2)	37 (24.2)

**Abbreviations** : LSS, lumbar spinal stenosis ; LRS, lateral recess stenosis ; FJE, facet joint effusion.

Table 4. Distribution of MRI findings

Classifications of MRI ( <i>n</i> [%])										
	L1/2	L2/3	L3/4	L4/5	L5/S1					
Central stenosis										
Grade A	212 (88.7)	200 (83.7)	171 (71.5)	158 (66.1)	233 (97.5)					
Grade B	26 (10.9)	34 (14.2)	51 (21.3)	55 (23.0)	2 (0.8)					
Grade C	1 (0.4)	5 (2.1)	16 (6.7)	20 (8.4)	3 (1.3)					
Grade D	0 (0.0)	0 (0.0)	1 (0.4)	6 (2.5)	1 (0.4)					
			<b>Left</b>		<b>Right</b>					
			L1/2	L2/3	L3/4	L4/5	L5/S1			
LRS										
Grade 0	180 (75.3)	113 (47.3)	56 (23.4)	23 (9.6)	107 (44.8)	176 (73.6)	113 (47.3)	58 (24.3)	25 (10.5)	113 (47.3)
Grade 1	49 (20.5)	89 (37.2)	111 (46.4)	110 (46.0)	91 (38.1)	42 (17.6)	82 (34.3)	105 (43.9)	104 (43.5)	89 (35.9)
Grade 2	10 (4.2)	32 (13.4)	58 (24.3)	60 (25.1)	32 (13.4)	21 (8.8)	35 (14.6)	56 (23.4)	70 (29.3)	29 (12.1)
Grade 3	0 (0.0)	5 (2.1)	14 (5.9)	46 (19.2)	9 (3.8)	0 (0.0)	9 (3.8)	20 (9.4)	40 (16.7)	8 (3.3)
FJE										
Grade 0	130 (54.4)	101 (42.3)	89 (37.2)	96 (40.2)	108 (45.2)	142 (59.4)	107 (44.8)	92 (38.5)	105 (43.9)	109 (45.6)
Grade 1	105 (43.9)	120 (50.2)	139 (58.2)	129 (54.0)	125 (52.3)	92 (38.5)	111 (46.4)	129 (54.0)	123 (51.5)	124 (51.9)
Grade 2	1 (1.7)	18 (7.5)	11 (4.6)	14 (5.9)	6 (2.5)	5 (2.1)	21 (8.8)	18 (7.5)	11 (4.6)	6 (2.5)

Abbreviations : LRS, lateral recess stenosis ; FJE.

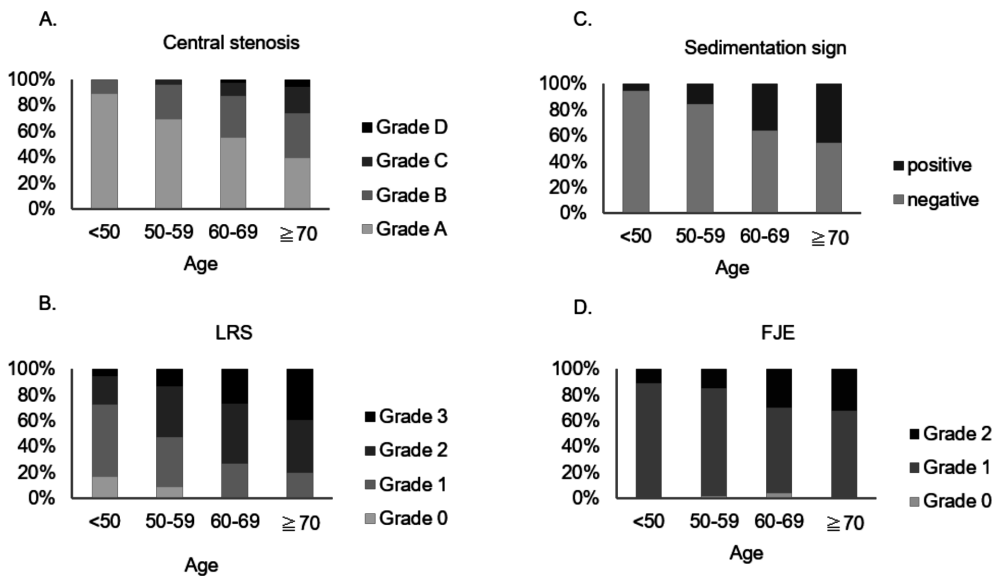


Fig. 2. The distribution of grades in each classification by age. (A) The rate of severe central stenosis increases with age. (B) The rate of severe LRS increases with age. (C) The sedimentation sign increases with age. (D) The rate of Grade 2 FJE increases with age.

### Association of grading on MRI findings and LSS symptoms in each classification

Comparison of characteristics with and without typical LSS symptoms as assessed by LSS-SSHQ are shown in Table 5. The prevalence of typical LSS symptoms was 58 of 239 participants (24.3%) and increased with age. The number of cases with typical LSS symptoms tended to increase significantly depending on the severity of central stenosis, LRS, and FJE, respectively ( $p < 0.001$ ). Among participants without typical LSS symptoms, the highest grade of severity was found in each classification: central stenosis 0.6%, LRS 22.1%, and FJE 21.5%. The most severe grades, in the combination of central stenosis (Grade D) and LRS (Grade

3), were only found significantly higher in the group with typical LSS symptoms, versus the group without typical LSS symptoms ( $p < 0.005$ ) (Table 6). The sedimentation sign was found in 27 of 58 participants (46.6%) in the group with typical LSS symptoms, significantly more than in the group without typical LSS symptoms ( $p = 0.015$ ) (Table 5). However, this sign was observed in 29.3% of the group without typical LSS symptoms.

According to multivariate analysis, LRS showed a strong correlation ( $r > 0.7$ ) with central stenosis, therefore, analyses with all explanatory variables, excluding LRS from the explanatory variables, are shown (Table 7). The odds ratio (OR) of Grade D in the central stenosis was 15.5 (95% confidence interval: 1.4-164.9), and it was the only significant

Table 5. Comparison of characteristics between participants with and without typical LSS symptoms as assessed by LSS-SSHQ

	Typical LSS symptoms (-) <i>n</i> = 181	Typical LSS symptoms (+) <i>n</i> = 58	<i>p</i>
<b>Distribution of age (y) (<i>n</i> [%])</b>			0.005
<50	18 (9.9)	0 (0.0)	
50-59	40 (22.1)	6 (19.3)	
60-69	58 (32.0)	20 (34.5)	
≥70	65 (35.9)	32 (55.2)	
<b>Sex (<i>n</i> [%])</b>			0.875
Male	66 (36.5)	20 (34.5)	
Female	115 (63.5)	38 (65.5)	
<b>Classifications of MRI (<i>n</i> [%])</b>			
Central stenosis			<0.001
Grade A	103 (56.9)	26 (44.8)	
Grade B	61 (33.7)	12 (20.7)	
Grade C	16 (8.8)	14 (24.1)	
Grade D	1 (0.6)	6 (10.3)	
LRS			<0.001
Grade 0	8 (4.4)	0 (0.0)	
Grade 1	52 (28.7)	15 (25.9)	
Grade 2	81 (44.8)	17 (29.3)	
Grade 3	40 (22.1)	26 (44.8)	
Sedimentation sign			0.015*
Positive	53 (29.3)	27 (46.6)	
Negative	128 (70.7)	31 (53.4)	
FJE			<0.001
Grade 0	4 (2.2)	1 (1.7)	
Grade 1	138 (76.2)	33 (56.9)	
Grade 2	39 (21.5)	24 (41.4)	

**Notes :** \* : Sex : The chi-squared test was used to compare between the typical LSS symptoms (+) and (-).

Others : The Cochran-Armitage's propensity test was used to compare between the typical LSS symptoms (+) and LSS (-).

**Abbreviations :** LSS, lumbar spinal stenosis ; LRS, lateral recess stenosis ; FJE, facet joint effusion.



Table 6. Distribution for combination of LRS and central stenosis with and without typical LSS symptoms as assessed by LSS-SSHQ

	Total (Typical LSS symptoms [-]/Typical LSS symptoms [+]) ( <i>n</i> =239)			
	Grade 0	Grade 1	Grade 2	Grade 3
Central stenosis				
Grade A	8 (8/0)	62 (50/12)	55 (42/13)	4 (3/1)
Grade B	0 (0/0)	4 (1/3)	41 (38/3)	28 (22/6)
Grade C	0 (0/0)	1 (1/0)	2 (1/1)	27 (14/13)
Grade D	0 (0/0)	0 (0/0)	0 (0/0)	7 (1/6)*

**Notes :** \**p*<0.05 : The chi-squared test was used to compare between the typical LSS symptoms (+) and (-).

**Abbreviations :** LSS, lumbar spinal stenosis ; LRS, lateral recess stenosis.

Table 7. Associations of MRI findings with the presence or absence of typical LSS symptoms as assessed by LSS-SSHQ in multivariate regression analysis

	Model 1			Model 2		
	OR	95% CI	<i>p</i> value	OR	95% CI	<i>p</i> value
<b>Sex (Female)</b>	1.262	0.629-2.530	0.513	1.211	0.609-2.405	0.585
<b>Age</b>	1.048	1.010-1.088	0.013	1.049	1.012-1.088	0.009
<b>Classifications of MRI findings</b>						
Central stenosis						
Grade A	Ref.			Ref.		
Grade B	0.561	0.207-1.523	0.257	0.561	0.234-1.346	0.195
Grade C	2.000	0.469-8.530	0.349	2.518	0.793-7.997	0.117
Grade D	11.885	0.919-153.74	0.058	15.453	1.448-164.94	0.023
LRS						
Grade 0	Ref.					
Grade 1	254965047	0.000	0.999	-	-	-
Grade 2	147471147	0.000	0.999	-	-	-
Grade 3	240462533	0.000	0.999	-	-	-
Sedimentation sign (Positive)	0.872	0.341-2.232	0.776	0.846	0.334-2.141	0.723
FJE						
Grade 0	Ref.			Ref.		
Grade 1	1.062	0.095-11.833	0.961	1.033	0.093-11.454	0.979
Grade 2	2.444	0.211-28.264	0.474	2.314	0.201-26.58	0.501
R2		0.235			0.209	

**Notes :** Model 1 : The results of the analysis with all MRI findings.

Model 2 : The results of the analysis adjusted LRS.

**Abbreviations :** LSS, lumbar spinal stenosis ; LRS, lateral recess stenosis ; OR, odds ratio ; CI, confidence interval ; FJE, facet joint effusion.

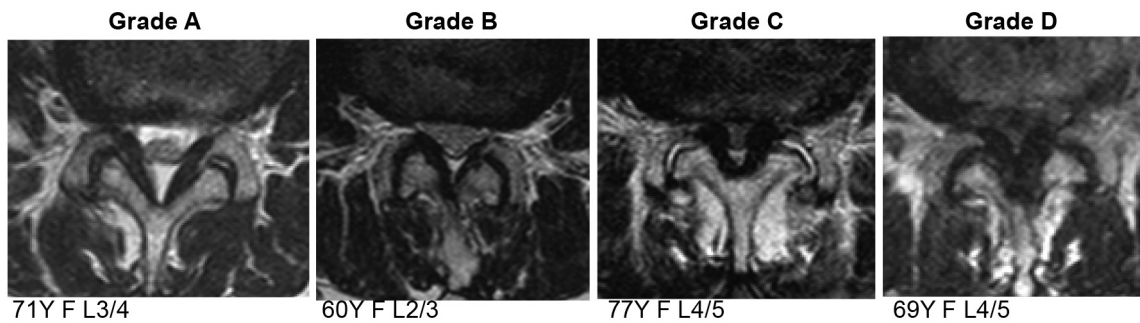
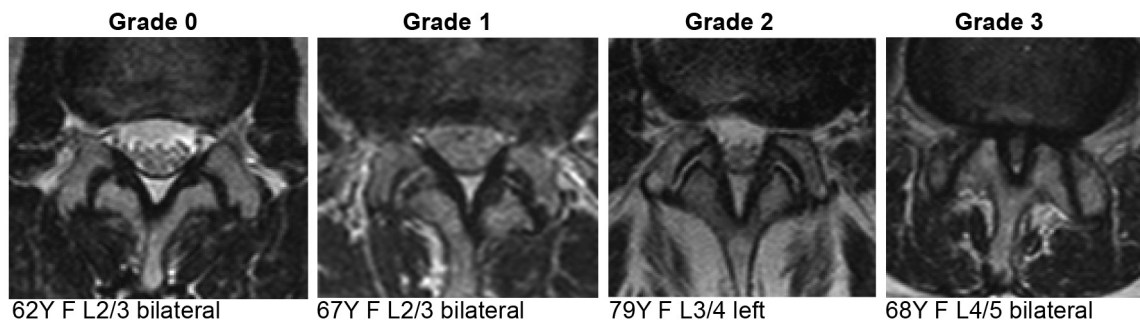
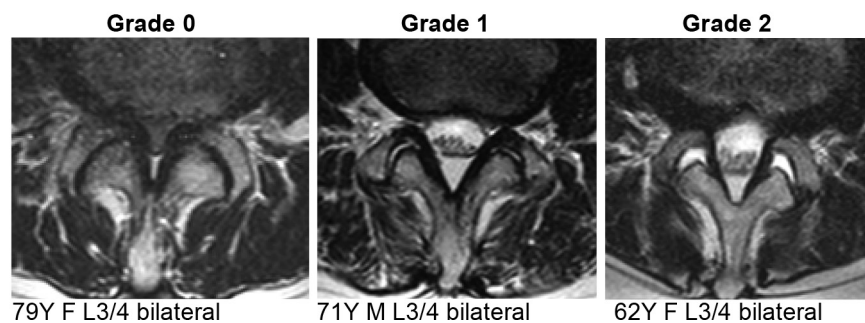
explanatory variable (*p*=0.023).

## Discussion

The present study evaluated correlations between the presence or absence of typical LSS symptoms and four classifications of lumbar MRI : morphological grading of central stenosis and of LRS, presence of the sedimentation sign, and severity of

FJE. It was found that only the most severe grade (D) of central stenosis was strongly associated with the presence of typical LSS symptoms.

Recent focus has been on the association between anatomical central stenosis on imaging and clinical symptoms. There are previous studies linking morphological stenosis with the LSS symptoms in hospital-based surveys<sup>7-10,24-26</sup>. According to these studies, it has remained controversial

**Supplementary data****Central stenosis****Lateral recess stenosis (LRS)****Facet joint effusion (FJE)**

Abbreviations : LRS, lateral recess stenosis ; FJE, facet joint effusion.

whether the morphological stenosis correlated with or without clinical LSS symptoms, even though various assessments of morphological stenosis, such as measurement of spinal canal area or diameter and each classification of stenosis grading, have been used for analyses<sup>27,28</sup>. In the general population study by Ishimoto *et al.*, the prevalence of clinical symptoms significantly increased with increasing severity of central stenosis<sup>27</sup>. In the present study, the prevalence of typical LSS symptoms tended to increase significantly according to the severity of central stenosis and LRS, respectively. In addition, the agreement between the two studies suggests

that the correlation between severe central stenosis and the presence of symptomatic LSS is more certain. Furthermore, to evaluate imaging findings for LSS, not only central canal stenosis but also lateral recess stenosis should be considered. It has been reported that the cross-sectional area of the lateral recesses was significantly smaller in the symptomatic LSS group than in the asymptomatic group<sup>28</sup>. Another study reported that there was a weak correlation between the Oswestry disability index and LRS grade in low back pain patients without central stenosis. However, the participants had low back pain, and it did not evaluate specific radicular symp-



toms<sup>11</sup>). In the present study, the prevalence of typical LSS symptoms increased significantly according to the severity of LRS compared with the group without typical LSS symptoms. It is known that degenerative spinal stenosis is primarily caused by age-related degeneration, such as protruding discs, osteophytes, hypertrophy of facet joints, and accompanying thickening of the ligamentum flavum<sup>1,12</sup>). Therefore, it is likely that advanced central stenosis is often associated with LRS. In the present study, the combination of higher severity grades of central stenosis (Grade C, D) and LRS (Grade 2, 3) was found in approximately 15%, and half of them were in the symptomatic LSS group. Since LRS showed a strong correlation ( $r > 0.7$ ) with central stenosis in the present study, it was considered inappropriate to include both central stenosis and LRS in the logistic regression analysis due to their multicollinearity; therefore, the correlation between LRS and central stenosis was not evaluated. The present study showed that only the most severe central stenosis was strongly related to the presence of typical LSS symptoms. Conversely, this and another study<sup>27</sup>) found that not all of the higher severity grades of MRI imaging cases presented with typical LSS symptoms. In the present study, the LSS-SSHQ score of one case with Grade D central stenosis, determined not to have typical LSS symptoms, was 2 points in questions 1-4 and 1 point in questions 5-10. This case showed some symptoms suggestive of LSS, but did not meet the defining criteria of the LSS-SSHQ. Moreover, the severity of stenosis on MRI was not associated with preoperative disability and pain, or clinical outcome at 1 year<sup>26</sup>). Furthermore, in the natural history of symptomatic LSS, it was shown that more than half of symptomatic LSS subjects improved their symptoms, whereas 10% of asymptomatic LSS subjects developed clinically diagnosed symptomatic LSS at 1 year follow up<sup>6</sup>). According to the abovementioned studies, morphological spinal stenosis might not be equal to the presence of typical LSS symptoms.

The sedimentation sign was first reported as a finding with high sensitivity and specificity for symptomatic LSS<sup>13</sup>). The presence of a positive sedimentation sign was greater depending on the severity of the morphological grade<sup>29</sup>). However, validation of the sedimentation sign is insufficient in patients with mild to moderate anatomical LSS<sup>29,30</sup>). Although the prevalence of the positive sedimentation sign was significantly higher in the group with typical LSS symptoms (46.4%) than in the group without typical symptoms (29.3%), logistic regression analy-

sis showed that the sedimentation sign was not a significant explanatory variable in the present study. These results suggest that the sedimentation sign itself was not associated with the presence or absence of typical LSS symptoms, just associated with the presence of anatomical central stenosis. This may be due to the fact that the present study involved a general population, and various degrees of anatomical LSS were included; therefore, these results might indicate a more generalized association between imaging findings and symptoms.

It has recently been reported that FJE may be associated with symptomatic LSS. In degenerative lumbar spinal disorders, high levels of inflammatory cytokines in facet joint tissue have been found to be released into the spinal canal, which is suspected to be the cause of pain<sup>11,16,17</sup>). In addition, increased facet fluid on MRI has been reported to be highly predictive of the dynamic reduction of DCSA detected on axial-loaded MRI in the clinical assessment of LSS<sup>14,15</sup>). In the present study, the severity of FJE was not associated with the presence or absence of typical LSS symptoms. However, in the present analysis, the highest severity was used as a representative value of the respective findings; the level and right/left sidedness of occurrence points were not taken into account. These factors might be useful to improve the accuracy of detecting symptomatic LSS.

The presence and severity of each MRI finding were often related to each other, suggesting a correlation between findings. Correlations strong enough to suggest multicollinearity were found only between central stenosis and LRS, but correlations between independent variables may have influenced the results of multivariate analysis. It was also necessary to evaluate whether combining each finding would result in a correlation with the presence or absence of symptoms; however, statistical analysis was difficult because the correlation between each finding resulted in a large bias in the distribution of the number of cases. A larger sample size may reduce the influence on multivariate analysis and allow us to analyze the association between the combination of findings and the presence of symptoms.

A strength of this study is that four different kinds of MRI evaluation items were performed in all participants. In addition, the distributions of each MRI item with and without typical LSS symptoms were evaluated and associations between them were analyzed using a logistic regression model. Therefore, various morphological findings were compared

for the possibility of pathogenesis in symptomatic LSS. A second strength is that the data were obtained from a large community-dwelling population on which various analyses have been performed, including the present study. Therefore, in contrast to a hospital-based survey, these results reflect a real-world setting and relevance for pathogenesis of LSS.

This study has several limitations. First, all participants in this study were volunteers, so it is possible that those participants who had any symptoms or more severe LSS symptoms might self-select for receiving MRI. However, each item from the MRI findings was distributed across all grades, and participants without symptoms also agreed to undergo MRI. Therefore, compared to a hospital-based study, the benefit of this study was that all grades of morphological stenosis, including mild stenosis and no stenosis, could be evaluated. Second, the most severe grade was taken as representative of each finding, therefore, detailed analyses for relationships between the responsible anatomical stenosis level inferred from the site of the symptoms or multiple level lesions were not considered. Because there is no established method of evaluation that takes into account multiple level lesions, and because it requires detailed grouping combined with the severity of the disease, a larger number of cases is considered necessary for the analysis. Third, since the research location was in a rural and mountainous area, one may not be completely able to extrapolate the findings to a more typical Japanese (urban) population. Finally, this was a cross-sectional study, therefore no causal relationships between morphological and symptomatic LSS could be established.

### Conclusion

The most severe central stenosis was found to be strongly related to typical LSS symptoms. However, although subjects with severe central stenosis showed symptoms suggestive of LSS, these subjects did not always show typical LSS symptoms. Moreover, mild central and lateral recess stenosis may or may not present with typical LSS symptoms. Further studies are needed to clarify the mechanism of onset and induction of LSS symptoms and its relationship to anatomical and radiological stenosis.

### Acknowledgments

The authors wish to thank Dr. Akira Onda, Dr. Kazuya Yamauchi, Dr. Yoshiaki Takeyachi, Dr. Ichiro

Takahashi, Dr. Hisayoshi Tachihara, and Dr. Bunji Takayama for participating in the data collection. The authors would also like to thank 5 public health nurses (Ms. Nobuko Fujita, Ms. Nakako Hoshi, Ms. Misako Hoshi, Ms. Naoko Imada, and Ms. Seiko Kanno) for their support in carrying out this study.

### Conflict of interest disclosure

The authors declare no conflicts of interest associated with this manuscript.

### References

1. Siebert E, Prüss H, Klingebiel R, *et al.* Lumbar spinal stenosis : syndrome, diagnostics and treatment. *Nat Rev Neurol*, **5** : 392-403, 2009.
2. Bartynski WS, Lin L. Lumbar root compression in the lateral recess : MR imaging, conventional myelography, and CT myelography comparison with surgical confirmation. *AJNR Am J Neuroradiol*, **24** : 348-360, 2003.
3. Kitamura M, Eguchi Y, Inoue G, *et al.* A case of symptomatic extra-foraminal lumbosacral stenosis ("far-out syndrome") diagnosed by diffusion tensor imaging. *Spine (Phila Pa 1976)*, **37** : E854-E857, 2012.
4. North American Spine Society Clinical Guidelines. III. Definition and Natural History of Degenerative Lumbar Spinal Stenosis [homepage on the Internet]. North American Spine Society ; 2011. Available from : <https://www.spine.org/Portals/0/Assets/Downloads/ResearchClinicalCare/Guidelines/LumbarStenosis.pdf> Accessed May 1, 2020.
5. Boden SD, Davis DO, Dina TS, *et al.* Abnormal magnetic-resonance scans of the lumbar spine in asymptomatic subjects. A prospective investigation. *J Bone Joint Surg Am*, **72** : 403-408, 1990.
6. Otani K, Kikuchi SI, Yabuki S, *et al.* Prospective one-year follow-up of lumbar spinal stenosis in a regional community. *J Pain Res*, **11** : 455-464, 2018.
7. Ogikubo O, Forsberg L, Hansson T. The relationship between the cross-sectional area of the cauda equina and the preoperative symptoms in central lumbar spinal stenosis. *Spine (Phila Pa 1976)*, **32** : 1423-1428 ; discussion 1429, 2007.
8. Kuittinen P, Sipola P, Saari T, *et al.* Visually assessed severity of lumbar spinal canal stenosis is paradoxically associated with leg pain and objective walking ability. *BMC Musculoskelet Disord*, **15** : 348, 2014.
9. Kim YU, Kong YG, Lee J, *et al.* Clinical symptoms of lumbar spinal stenosis associated with

- morphological parameters on magnetic resonance images. *Eur Spine J*, **24** : 2236-2243, 2015.
10. Andrasinova T, Adamova B, Buskova J, *et al.* Is there a Correlation Between Degree of Radiologic Lumbar Spinal Stenosis and its Clinical Manifestation? *Clin Spine Surg*, **31** : E403-E408, 2018.
  11. Splettstößer A, Khan MF, Zimmermann B, *et al.* Correlation of lumbar lateral recess stenosis in magnetic resonance imaging and clinical symptoms. *World J Radiol*, **9** : 223-229, 2017.
  12. Kushchayev SV, Glushko T, Jarraya M, *et al.* ABCs of the degenerative spine. *Insights Imaging*, **9** : 253-274, 2018.
  13. Barz T, Melloh M, Staub LP, *et al.* Nerve root sedimentation sign : evaluation of a new radiological sign in lumbar spinal stenosis. *Spine (Phila Pa 1976)*, **35** : 892-897, 2010.
  14. Kim YK, Lee JW, Kim HJ, *et al.* Diagnostic advancement of axial loaded lumbar spine MRI in patients with clinically suspected central spinal canal stenosis. *Spine (Phila Pa 1976)*, **38** : E1342-E1347, 2013.
  15. Kanno H, Ozawa H, Koizumi Y, *et al.* Increased Facet Fluid Predicts Dynamic Changes in the Dural Sac Size on Axial-Loaded MRI in Patients with Lumbar Spinal Canal Stenosis. *AJNR Am J Neuroradiol*, **37** : 730-735, 2016.
  16. Igarashi A, Kikuchi S, Konno S. Correlation between inflammatory cytokines released from the lumbar facet joint tissue and symptoms in degenerative lumbar spinal disorders. *J Orthop Sci*, **12** : 154-160, 2007.
  17. Vardeh D, Mannion RJ, Woolf CJ. Toward a Mechanism-Based Approach to Pain Diagnosis. *J Pain*, **17** : T50-T69, 2016.
  18. Otani K, Kikuchi S, Yabuki S, *et al.* Lumbar spinal stenosis has a negative impact on quality of life compared with other comorbidities : an epidemiological cross-sectional study of 1862 community-dwelling individuals. *ScientificWorldJournal*, **2013** : 590652, 2013.
  19. Schizas C, Theumann N, Burn A, *et al.* Qualitative grading of severity of lumbar spinal stenosis based on the morphology of the dural sac on magnetic resonance images. *Spine (Phila Pa 1976)*, **35** : 1919-1924, 2010.
  20. Chaput C, Padon D, Rush J, *et al.* The significance of increased fluid signal on magnetic resonance imaging in lumbar facets in relationship to degenerative spondylolisthesis. *Spine (Phila Pa 1976)*, **32** : 1883-1887, 2007.
  21. Landis JR, Koch GG. The measurement of observer agreement for categorical data. *Biometrics*, **33** : 159-174, 1977.
  22. Konno S, Kikuchi S, Tanaka Y, *et al.* A diagnostic support tool for lumbar spinal stenosis : a self-administered, self-reported history questionnaire. *BMC Musculoskelet Disord*, **8** : 102, 2007.
  23. Vatcheva KP, Lee M, McCormick JB, *et al.* Multicollinearity in Regression Analyses Conducted in Epidemiologic Studies. *Epidemiology (Sunnyvale)*, **6** : 227, 2016.
  24. Kapural L, Mekhail N, Bena J, *et al.* Value of the magnetic resonance imaging in patients with painful lumbar spinal stenosis (LSS) undergoing lumbar epidural steroid injections. *Clin J Pain*, **23** : 571-575, 2007.
  25. Sigmundsson FG, Kang XP, Jönsson B, *et al.* Correlation between disability and MRI findings in lumbar spinal stenosis : a prospective study of 109 patients operated on by decompression. *Acta Orthop*, **82** : 204-210, 2011.
  26. Weber C, Giannadakis C, Rao V, *et al.* Is There an Association Between Radiological Severity of Lumbar Spinal Stenosis and Disability, Pain, or Surgical Outcome? : A Multicenter Observational Study. *Spine (Phila Pa 1976)*, **41** : E78-E83, 2016.
  27. Ishimoto Y, Yoshimura N, Muraki S, *et al.* Associations between radiographic lumbar spinal stenosis and clinical symptoms in the general population : the Wakayama Spine Study. *Osteoarthritis Cartilage*, **21** : 783-738, 2013.
  28. Majidi H, Shafizad M, Niksolat F, *et al.* Relationship Between Magnetic Resonance Imaging Findings and Clinical Symptoms in Patients with Suspected Lumbar Spinal Canal Stenosis : a Case-control Study. *Acta Inform Med*, **27** : 229-233, 2019.
  29. Laudato PA, Kulik G, Schizas C. Relationship between sedimentation sign and morphological grade in symptomatic lumbar spinal stenosis. *Eur Spine J*, **24** : 2264-2268, 2015.
  30. Zhang L, Chen R, Xie P, *et al.* Diagnostic value of the nerve root sedimentation sign, a radiological sign using magnetic resonance imaging, for detecting lumbar spinal stenosis : a meta-analysis. *Skeletal Radiol*, **44** : 519-527, 2015.