

Right Ventricular Angiosarcoma Compressing the Left Ventricle



Lucy M. Safi, DO, Vipin Mehta, MD, George Tolis, Jr., MD, and Michael H. Picard, MD, FACC, FAHA, FASE,
Boston, Massachusetts

INTRODUCTION

Malignant tumors of the heart are rare and most commonly due to metastatic disease rather than primary cardiac tumors. Patient presentations vary and range from asymptomatic to heart failure from blood flow obstruction, valvular dysfunction, ventricular dysfunction, or arrhythmia. Echocardiography is an easily accessible imaging modality and usually the first test ordered. Although a definitive diagnosis cannot be made by echocardiography, the location within the heart and tissue characteristics assessed by ultrasound may help narrow the differential diagnosis. Usually once found, most cardiac tumors are removed surgically, but the prognosis of malignant cardiac tumors is poor.

CASE PRESENTATION

A 63-year-old woman with a history of tobacco use, severe osteoporosis, and vitamin D deficiency was seen in follow-up by her family physician for a 6-month history of weight loss. She noted that despite a normal appetite, she had lost about 5 pounds (from 78 to 73 lb). Initially her weight loss was attributed to multiple dental surgical procedures requiring a liquid diet. She also reported abdominal discomfort but denied constipation, diarrhea, and melena. Her family history was significant for bladder cancer in her father and a brother with sudden cardiac death. On examination, she was afebrile, her blood pressure was 102/72 mm Hg, and her heart rate was 88 beats/min. Cardiac examination revealed regular rate and rhythm, and no murmurs, rubs, or gallops were heard. Because of her abdominal pain and weight loss, she was referred for abdominal computed tomography (CT).

Diagnostic Testing

CT showed a benign abdomen. However, although not well visualized, there was concern for a filling defect in the heart (Figure 1). Transthoracic echocardiography (TTE) was then ordered to better evaluate this filling defect.

TTE revealed a small left ventricular chamber (27-mm end-diastolic diameter) but normal function. The right ventricle had a large, complexly shaped, intracavitary mass that filled the majority of the chamber, extending toward the right ventricular (RV) outflow tract and measuring at least $8 \times 6 \times 6$ cm. The characteristics of this mass were most consistent with tumor. On color and spectral Doppler imaging, there was evidence of mild tricuspid regurgitation,

and assuming a right atrial pressure of 10 mm Hg, RV systolic pressure was elevated and estimated at 47 mm Hg (Figure 2). Also seen was RV outflow obstruction (Figure 3) and diastolic and systolic flattening of the interventricular septum. The ultrasound characteristics of the mass were suggestive of a primary cardiac tumor such as myxoma or sarcoma (angiosarcoma or fibrosarcoma) or a secondary tumor such as metastatic lung, breast, or melanoma (Figure 4, Videos 1–6).

Cardiac magnetic resonance imaging (MRI) confirmed the presence of a large, lobulated, heterogeneously enhancing intracavitary mass that occupied the majority of the right ventricle and extended into the RV outflow tract, compromising blood flow in systole. The attachment of the mass appeared to be to the RV apex, and it was T1 isointense and T2 hyperintense to the myocardium (Figure 5). There was heterogeneous postcontrast enhancement of the mass with areas of hypoenhancement likely representing central hemorrhagic necrosis. The tissue characteristics were consistent with a neoplastic process, possibly sarcoma, although extension into the ventricular wall or pericardial space was not seen. Coronary CT excluded pulmonary embolus and showed mild atherosclerosis and normally sized pulmonary arteries and again confirmed the large mass in the right ventricle (see CT in the 3D Radiological Viewer).

Clinical Course

Given the concern for malignancy, the patient underwent a percutaneous biopsy of the mass by cardiac catheterization with intracardiac echocardiographic guidance. The pathology showed a high-grade spindle cell sarcoma consistent with angiosarcoma (Figure 6). She was referred to cardiothoracic surgery and oncology for consultation and treatment. It was recommended that she undergo systemic chemotherapy, and if after several cycles of chemotherapy there remained no evidence of metastatic disease, debulking surgery followed by definitive proton radiotherapy to treat residual tumor would be pursued. Her chemotherapy regimen (gemcitabine and docetaxel) was complicated by neutropenic fever, and her chemotherapy was switched to ifosfamide and etoposide. After several cycles of treatment, computed tomographic/positron emission tomographic imaging did not show any evidence of metastatic disease, and the patient underwent surgical resection of the mass (Figure 7). She required placement of a 31-mm tricuspid valve bioprosthesis (St. Jude Medical, St. Paul, MN) as well as a permanent pacemaker for postoperative complete heart block. The patient was discharged from the hospital with plans for proton radiotherapy treatment.

DISCUSSION

Although angiosarcoma is the most common type of malignant cardiac tumor in adults, the incidence is rare and in an autopsy series was estimated at about 0.0001%.¹ Angiosarcomas are made of malignant cells from vascular structures, and pathology shows infiltration of the myocardium by spindle cells.² The prognosis of cardiac sarcomas is very poor, with median survival in the absence of treatment of <10 months.^{3,4}

From Massachusetts General Hospital, Harvard Medical School, Boston, Massachusetts.

Keywords: Angiosarcoma, Tumor, Right ventricle

Conflicts of Interest: The authors reported no actual or potential conflicts of interest relative to this document.

Copyright 2017 by the American Society of Echocardiography. Published by Elsevier Inc. This is an open access article under the CC BY-NC-ND license (<http://creativecommons.org/licenses/by-nc-nd/4.0/>)

2468-6441

<http://dx.doi.org/10.1016/j.case.2016.11.003>

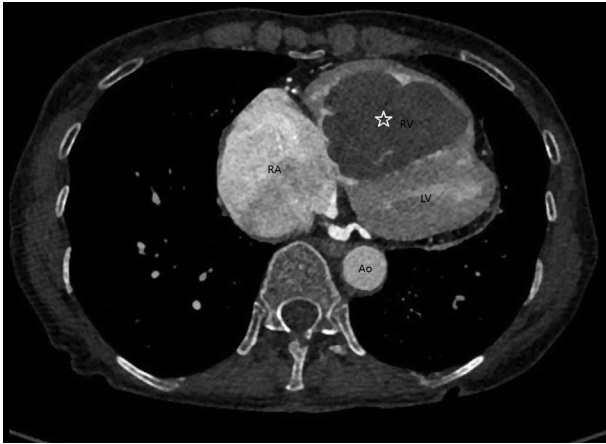


Figure 1 Computed tomographic imaging showing a filling defect (star) in the right ventricle (RV). Ao, aorta; LV, left ventricle; RA, right atrium.

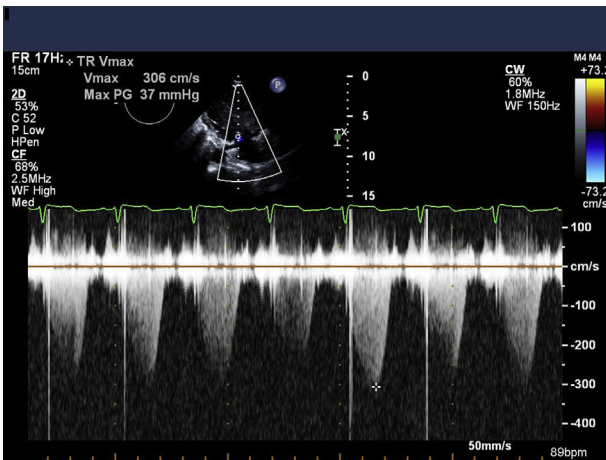


Figure 2 Doppler imaging across the tricuspid valve showing a peak trans-tricuspid valve gradient of approximately 47 mm Hg (assuming a right atrial pressure of 10 mm Hg).

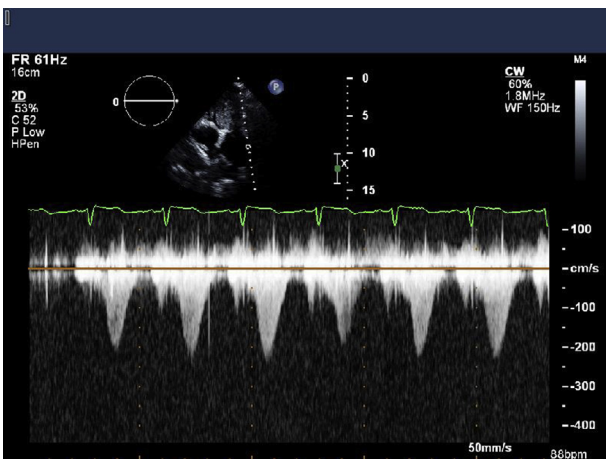


Figure 3 Doppler imaging across the pulmonic valve showing an increased gradient along the path of the Doppler beam, most likely due to tumor blood flow obstruction.

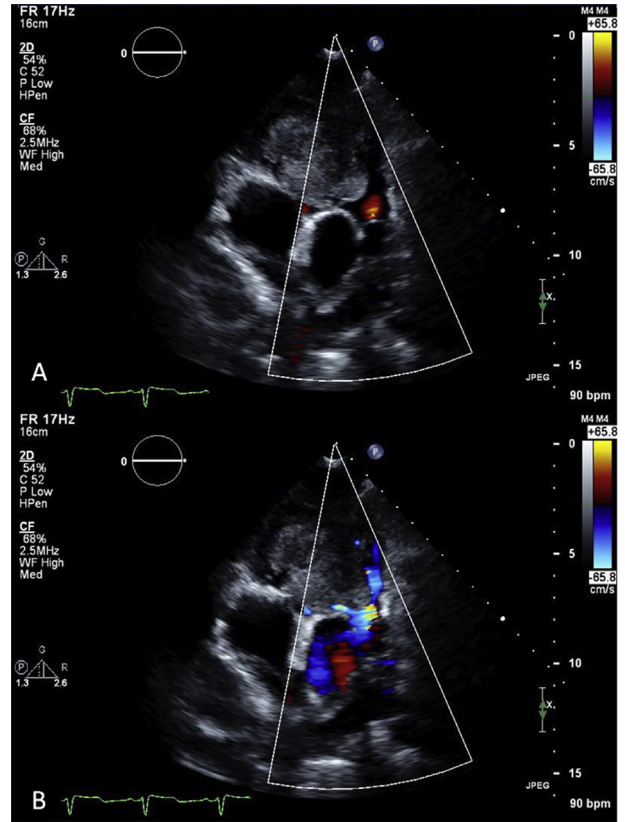


Figure 4 (A) RV outflow tract view showing tumor extension into outflow tract in diastole. (B) RV outflow obstruction in systole.

Angiosarcomas are usually found in the right heart, most frequently in the right atrium.⁵ On TTE, the mass appears lobulated with areas of possible necrosis or hemorrhage.⁶ Unlike other cardiac tumors such as myxomas, angiosarcomas do not have stalks. The tumors may extend into the pericardium, and pericardial effusions (with or without tamponade) may be seen.⁷ The proximity of the tumor to the tricuspid valve may cause tricuspid regurgitation or obstruction. Pericardial and myocardial involvement may lead to chest pain (from myocardial invasion) or dyspnea (from blood flow obstruction or valvular dysfunction).⁸

This patient's tumor filled the majority of the dilated RV cavity with no evidence of extension into the right atrium on imaging. The dilated right ventricle shifted the interventricular septum toward the left, thereby decreasing the overall left ventricular cavity size, but it did not affect overall left ventricular systolic function. There was a suggestion of elevated pulmonary artery pressure by both Doppler and two-dimensional imaging. However, because the tumor extended into the RV outflow tract and obstructed blood flow, it is probable that the pressure elevation was isolated to the right ventricle rather than at the level of the pulmonary arteries. Flattening of the interventricular septum may be due to increased RV pressures from blood flow obstruction or be related to the location of the mass in the right ventricle (compressing on the left ventricle). Also, the findings of normally sized pulmonary arteries and no pulmonary emboli on CT support probable normal pulmonary artery pressures.

Unintentional weight loss should raise concern as a constitutional symptom associated with malignancy. The patient's abdominal pain was a nonspecific symptom, and there were no

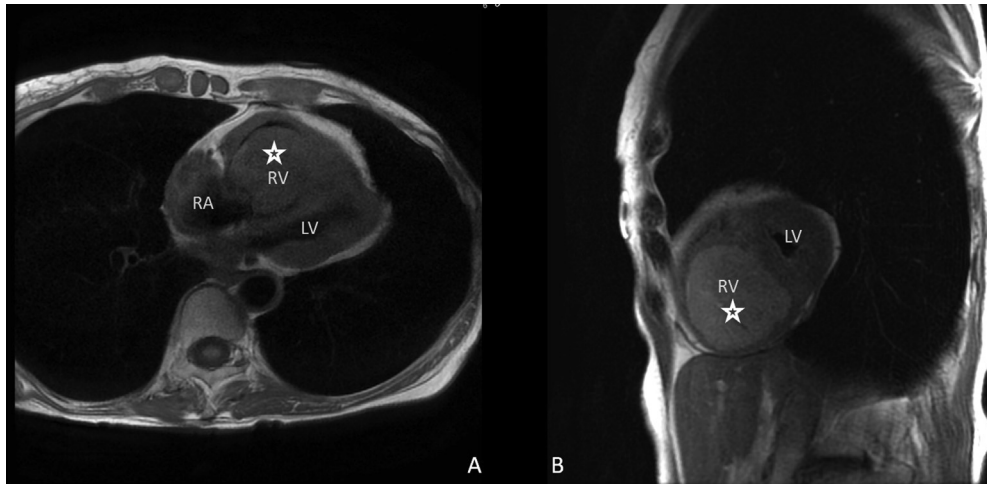


Figure 5 Cardiac MRI. **(A)** T1-weighted image showing isointense mass in the right ventricle and attachment site most likely near the right ventricular apex. **(B)** T2-weighted image, short axis, of the ventricles showing a hyperintense mass almost entirely filling the right ventricular chamber. The *star* indicates the mass. LV, Left ventricle; RA, right atrium; RV, right ventricle.

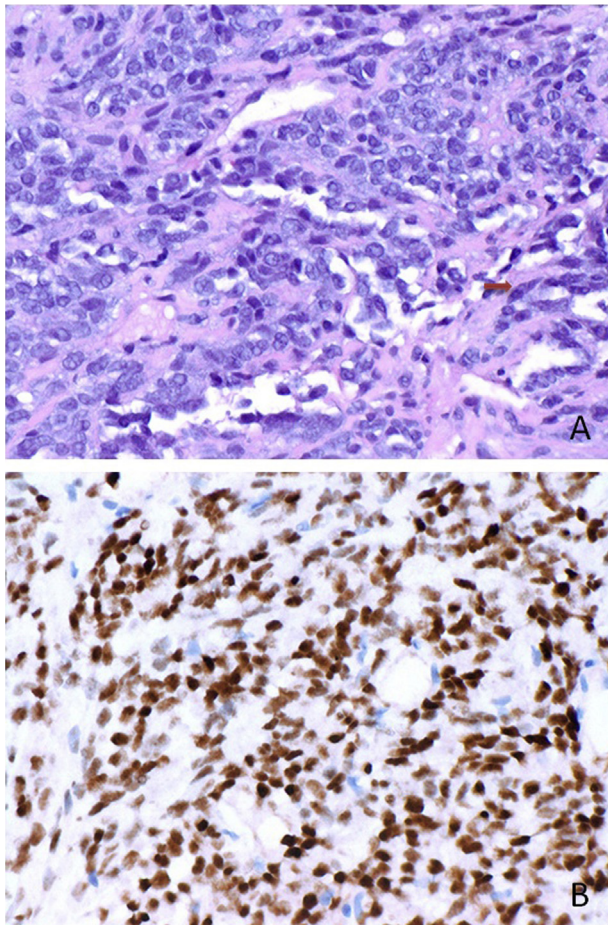


Figure 6 Histopathology of the RV mass obtained from endomyocardial biopsy showing a high-grade spindle cell sarcoma. **(A)** Hematoxylin and eosin staining (400× magnification). *Arrow* points to spindle cell. **(B)** Diffuse staining of tumor cells on an immunohistochemical stain for ERG (400× magnification).

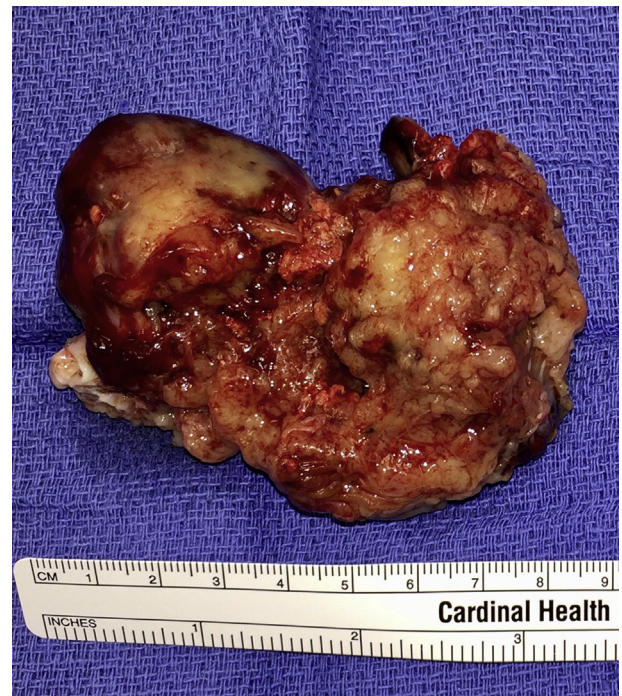

Figure 7 Gross pathology of angiosarcoma.

abnormalities on abdominal CT. As in this patient, results of cardiac examination may be normal or close to normal, with little to suggest cardiac tumor. Because of nonspecific symptoms, often cardiac sarcomas are found in later stages of the disease, when they have already metastasized.⁹ Despite the large size of this tumor, there was no evidence of metastasis on positron emission tomographic imaging.

Although TTE cannot define the histopathology of a mass, it can identify the presence, location, and tissue characteristics of the mass, which can thus narrow the differential diagnosis. For a definitive diagnosis, tissue is needed for a pathologic examination. TTE is also useful

in evaluating tumor sequelae such as blood flow obstruction, valvular regurgitation, and myocardial dysfunction. Tumors may obstruct blood flow, causing symptoms of valvular stenosis or regurgitation, or they may infiltrate into the myocardium, causing dysfunction. Also, pulmonary or systemic emboli may occur if a tumor is located on the right or left side of the heart (respectively) because of thrombus formation on the tumor or embolization of the tumor itself. Although the symptoms associated with cardiac tumors are usually related to their locations, some tumors may cause systemic or constitutional symptoms.¹⁰

Other imaging modalities, such as transesophageal echocardiography, cardiac MRI, and CT, may be ordered to evaluate cardiac masses. Transesophageal echocardiography offers better spatial resolution than TTE and may be able to better define a cardiac mass, particularly in patients whose masses are located posteriorly in the chest or are not well visualized with TTE. Cardiac MRI, although also unable to make a definitive diagnosis, is better able to define tissue characteristics of cardiac masses and can narrow the differential diagnosis to a great degree. The use of cardiac MRI may be limited because of patient contraindications (pacemakers, hardware, etc.) and not readily accessible at all institutions. Conversely, CT is more readily available and is able to define the tumor size as well as evaluate the surrounding tissues.

Because of the rarity of cardiac angiosarcomas, there are no guidelines available for management. Reports have been published regarding surgery, systemic chemotherapy, and radiotherapy, as well as heart transplantation.¹¹⁻¹³ Early diagnosis and complete resection may improve survival, although overall long-term prognosis remains poor.

CONCLUSIONS

In our patient, despite the large size of the tumor, there was no evidence of metastatic disease at the time of diagnosis. TTE aided in a timely diagnosis and referral for both oncology and surgical evaluation and treatment.

SUPPLEMENTARY DATA

Supplementary data related to this article can be found at <http://dx.doi.org/10.1016/j.case.2016.11.003>.

REFERENCES

1. Straus R, Merliss R. Primary tumor of the heart. *Arch Pathol* 1945;39:74-8.
2. Ge Y, Ro JY, Kim D, Kim CH, Reardon MJ, Blackmon S, et al. Clinicopathologic and immunohistochemical characteristics of adult primary cardiac angiosarcomas: analysis of 10 cases. *Ann Diagn Pathol* 2011;15:262-7.
3. Putnam JB Jr, Sweeney MS, Colon R, Lanza LA, Frazier OH, Cooley DA. Primary cardiac sarcomas. *Ann Thorac Surg* 1991;51:906-10.
4. Bear P, Moodie D. Malignant primary cardiac tumors: the Cleveland Clinic experience, 1956 to 1986. *Chest* 1987;92:860-2.
5. Janigan DT, Husain A, Robinson NA. Cardiac angiosarcomas. A review and case report. *Cancer* 1986;57:852-9.
6. Mankad R, Herrmann J. Cardiac tumors: echo assessment [published online September 6, 2016]. *Echo Res Pract* 2016; <http://dx.doi.org/10.1530/ERP-16-0035>.
7. Patel SD, Peterson A, Bartczak A, Lee S, Chojnowski S, Gajewski P, et al. Primary cardiac angiosarcoma – a review. *Med Sci Monit* 2014;20:103-9.
8. Burnside N, MacGowan SW. Malignant primary cardiac tumours. *Interact Cardiovasc Thorac Surg* 2012;15:1004-6.
9. Movsas B, Teruya-Feldstein J, Smith J, Glatstein E, Epstein AH. Primary cardiac sarcoma: a novel treatment approach. *Chest* 1998;114:648-52.
10. Vander Salm TJ. Unusual primary tumors of the heart. *Semin Thorac Cardiovasc Surg* 2000;12:89-100.
11. Blackmon SH, Reardon MJ. Surgical treatment of primary cardiac sarcomas. *Tex Heart Inst J* 2009;36:451-2.
12. Ravi V, Benjamin RS. Systemic therapy for cardiac sarcomas. *Methodist Debakey Cardiovasc J* 2010;6:57-60.
13. Li H, Yang S, Chen H, Yang Z, Hong T, Hou Y, et al. Survival after heart transplantation for non-metastatic primary cardiac sarcoma. *J Cardiothorac Surg* 2016;11:145.