

PSEUDARTHROSIS OF THE HUMERAL NECK: ANALYSIS OF THE RESULTS WHEN USING THE TECHNIQUE DESCRIBED BY WALCH ET AL

Sérgio Luis Checchia¹, Alberto Naoki Miyazaki², Marcelo Fregoneze³, Pedro Doneux Santos⁴,
Luciana Andrade da Silva⁴, Luís Gustavo Prata Nascimento⁵

ABSTRACT

Objective: To evaluate bone healing and the patient's outcome after open reduction and internal fixation, when using the technique described by Walch et al, in 1996, which uses conventional intramedullary corticocancellous bone graft and internal fixation with plate and screws added by a tricortical intramedullary bone graft, also autologous. **Methods:** From July 1997 to May 2005, 14 patients were treated by this technique, 14 of these diagnosed with pseudoarthrosis of the humeral proximal end. One died at the early postoperative period due to pulmonary thromboembolism; therefore, 13 patients were re-evaluated. **Results:** The mean follow-up time was 51.4 months (ranging from 12 to 130 months). Four

patients evolved with excellent results, four good and five fair results. Therefore, there were 61.5% of satisfactory results according to UCLA functional scale and no poor result. Twelve cases (92%) healed within 3.5 months in average. **Conclusion:** the surgical treatment of the nonunion of the surgical neck of the humerus using this technique showed an effective outcome with 92% of healing; excellent and good results in 61.5% of the cases, as well as satisfaction of all patients with their final results; nonunion resulting from two-part fractures had better results when compared with three-part fractures.

Keywords – Humerus/anatomy; Pseudoarthrosis; Fracture internal, fixation

INTRODUCTION

Fractures of the proximal humerus account for approximately 5% of fractures of the human skeleton^(1,2). Most of these are impacted fractures, with no or minimal deviation, that are usually treated conservatively and, in most cases, the fracture heals and the functional outcome is satisfactory⁽³⁻⁷⁾. However, infrequently^(1,4,5,7-11), it can progress to pseudoarthrosis, but its incidence has not been well-defined^(7,8,12).

Among fractures of the proximal humerus, the one which most often develops into pseudoarthrosis is classified by Neer as two parts of the surgical neck of the humerus^(3,4,10,11,13-15); they are usually incapacitating due to pain and loss of active movement of the shoulder joint^(1-3,8,10,11,16,17).

The treatment of this complication is hampered by local factors, such as osteopenia and bone resorption, both by age and by disuse of the affected limb, and cavitation in the proximal fragment, as well as communication of the fracture with the joint synovial fluid and capsuloligamentous and myotendinous retraction^(1,5,8,11,16).

Because of such difficulties, several types of treatment have been proposed for pseudoarthrosis of the surgical neck of the humerus, from the conservative, indicated in oligosymptomatic patients and those with serious medical problems^(1,3,5,13,17,18), to various surgical methods. Among these we can include fixation with intramedullary nails, initially unlocked and without a tension band, and later associated with this, interlocking nail fixation, internal osteosynthesis

1 – Assistant Professor, School of Medical Sciences, Santa Casa de São Paulo (FCMSCSP, Faculdade de Ciências Médicas da Santa Casa de São Paulo)

2 – Professor, FCMSCSP; Head, Shoulder and Elbow Group, DOT-FCMSCSP.

3 – Assistant Professor, FCMSCSP; Instructor, Shoulder and Elbow Group, DOT-FCMSCSP.

4 – Department Attending Physician; Instructor, Shoulder and Elbow Group, DOT-FCMSCSP.

5 – Physician, Master of Medicine from FCMSCSP – Shoulder and Elbow Group, DOT-FCMSCSP.

Study conducted at the Department of Orthopedics and Traumatology, School of Medical Sciences, Santa Casa de São Paulo, "Fernandinho Simonsen" Pavillion.
Correspondence: Rua Dr. Cesário Mota Jr., 112 – 01221-020 – São Paulo, SP. Tel/Fax: (011) 3222-6866. E-mail: ombro@ombro.med.br

We declare no conflict of interest in this article

(IO) with a plate and screws, with or without the use of an autologous bone graft, and hemiarthroplasties that provide functionally unsatisfactory results^(13,17,19-22).

Walch et al.⁽⁸⁾ described a technique in which IO is associated with a T-plate and intramedullary tricortical autologous bone graft, and autologous cancellous bone graft peripheral to the focus of the pseudarthrosis, obtaining 96% consolidation. Thus, in our cases we chose to use the same principle described by Walch et al.⁽⁸⁾; however, we modified the IO, performing it with the PFS 80[®] angled plate, based on their results for the fixation of fractures in two parts of the surgical neck of the humerus, which achieved 91.3% excellent and good results, according to the criteria defined by the University of California at Los Angeles (UCLA), and 97.8% consolidation⁽²³⁾.

The objective of this study is to evaluate the consolidation and functional results obtained in cases of pseudarthrosis of the surgical neck of the humerus treated with the technique described by Walch et al.⁽⁸⁾. IO was performed with the PFS 80[®] plate⁽²³⁾.

METHODS

Between July 1997 and May 2005, the Shoulder and Elbow Group of the Department of Orthopedics and Traumatology, School of Medical Sciences, Santa

Casa de São Paulo, treated 14 patients with pseudarthrosis of the surgical neck of the humerus.

All patients with pseudarthrosis of the surgical neck of the humerus with a minimum follow-up period of one year and those with the possibility of having undergone this technique, that is, cases of pseudarthrosis resulting from fractures in two parts of the surgical neck of the humerus or those with consolidation of the tubercles with a deviation of less than five millimeters were included in the study. Therefore, we excluded cases classified as complex, those with loss of fragments, or those with severe cavitation of the proximal fragment, preventing adequate IO. One patient who died during the immediate postoperative period from pulmonary thromboembolism was also excluded from the sample. Therefore, 13 patients were reevaluated, of whom nine were male and four females, with a mean age of 58.5 years, ranging from 25 to 79 years, and the dominant limb was affected in seven cases (Table 1).

The mechanisms of injury were: falls to the ground in eight cases, car accident in two cases, and a motorcycle accident, being run over, and direct trauma in one case each.

Regarding the type of fracture according to the Neer criteria⁽²⁴⁾, 10 cases were classified into two-part fractures involving the surgical neck and the

Table 1 – Clinical data of the patients, types of fracture, fracture treatment in the acute phase, time of diagnosis of pseudarthrosis, pseudarthrosis type, implants used in surgery, healing time, postoperative mobility, duration of follow-up, postoperative functional results (UCLA), and complications.

Case	Initials	Sex	Age	Dom.	Type of fracture	Fracture treatment	T diag. PSA	PSA type	Surgical implants	T cons.	PO Mob.	F-U P	UCLA	Complicações
1	DR	F	61	+	2 p (SN)	Wire	24 m	Low	PFS	5m	130/T ₆ /40	9y	29	Loosening of plate
2	CZM	F	79		2 p (SN)	Conservative	3 m	Low	PFS	4m	120/T ₅ /40	9y	27	
3	GML	F	54	+	2 p (SN)	Wire	3 m	Low	PFS	3m½	160/T ₃ /60	7y	35	
4	JFS	M	51		3 p (SN+GT)	Wire	4 m	Low	PFS	4m½	160/T ₆ /45	6y	35	
5	WA	M	70		2 p (SN)	Conservative	3 m	Low	PFS + 1 PFO	2m½	120/T ₁₂ /40	1y	32	
6	RS	M	25		3 p (SN+GT)	PFS	15 m	Low	PFS + 1 PFO	2m½	120/T ₉ /30	3y	28	Plate impingement
7	CHK	M	57	+	2 p (SN)	Conservative	8 m	Low	PFS + 2 PFO	4m	110/L ₁ /40	1y	26	
8	DB	M	66		2 p (SN)	Conservative	4 m	Low	PFS	2m	150/T ₁₂ /20	2y	32	
9	DMG	M	40	+	2 p (SN)	Conservative	6 m	High	PFS	2m½	150/T ₁₀ /20	2y	35	
10	RDN	M	69	+	3 p (SN+GT)	Conservative	7 m	Low	PFS	4m	90/L ₃ /45	4y 7m	27	
11	MC	F	77		2 p (SN)	Wire	5 m	Low	PFS + 2 PFO	5m	130/T ₁₂ /60	2y 10m	27	Plate impingement+broken graft
12	AT	M	65	+	2 p (SN)	PFS	11 m	Low	PFS + 1 PFO	3m	150/T ₁₂ /45	1y	34	
13	RAA	M	47	+	2 p (SN)	Conservative	3 m	High	PFS	5m	120/T ₆ /60	1y 3m	27	PO hematoma + cons. failure = reop.

Source: DOT-SCMSP

M – male, F – female, Dom. – dominance, p – parts, SN – surgical neck; GT – greater tubercle, PFS – PFS 80[®] angled plate, T – time, PSA – pseudarthrosis, m – months, PFO – PFO nut, T cons. – Time of consolidation, PO Mob. – postoperative mobility, F-U P – duration of follow-up period, y – years, Reop. – reoperation

other three cases as three-part fractures involving the surgical neck and the greater tubercle, two of them being anterior fracture-dislocation in three parts. All fractures were closed. With respect to the previous treatment of these fractures, seven were treated conservatively, four were treated through surgery with metallic wire, one of them having been operated twice, since it progressed to loss of reduction during the early postoperative period, and two with a PFS 80° angled plate⁽²³⁾. Pseudarthrosis was diagnosed on average 7.4 months after the fracture (ranging from three to 24 months) (Table 1).

The X-rays used for diagnosis and classification of this complication corresponded to the shoulder trauma series: true frontal plane in neutral rotation, axillary profile and scapular profile⁽²⁴⁾. We used the classification of pseudarthrosis of the surgical neck of the humerus proposed by Checchia et al.⁽¹⁾ (Figure 1); 11 cases were classified as the low type and two as the high type (cases 9 and 13) (Table 1).

Mobility was evaluated in the preoperative period; however, values did not correspond to the range of motion of the shoulder joint, but to the mobility at the site of the pseudarthrosis in such cases, which did not allow us to evaluate the actual movement of the joint.

The surgical method used was open reduction and IO with the PFS 80° angled plate⁽²³⁾, associated with the placement of intramedullary tricortical autologous bone graft taken from the ilium, as well as autologous cancellous bone graft peripheral to the site of the pseudarthrosis, as well as the technique of Walch et al.⁽⁸⁾ (Figure 2). We used the deltopectoral access in all cases and the anterior superior iliac crest as the source of the bone graft. The fibrous tissue at the site of the pseudarthrosis was resected and the bone ends were made to bleed to improve local blood circulation. IO with the PFS 80° angled plate⁽²³⁾ was performed after nailing the tricortical graft into the medullary canal of the diaphysis and the humeral head. In addition, autologous cancellous bone graft was added around the site of the pseudarthrosis in all cases (Figure 3). A bone fixation nut (PFO®)* (Figure 4), indicated in cases of localized advanced osteopenia in which the fixation with cortical screw is inadequate, was used in five cases (Table 1).

In the postoperative period, the patients remained in a sling until the consolidation of the pseudarthrosis was evidenced by the radiographs. Until then, only active exercises with the elbow, wrist, and hand of the affected limb were allowed. After consolidation,

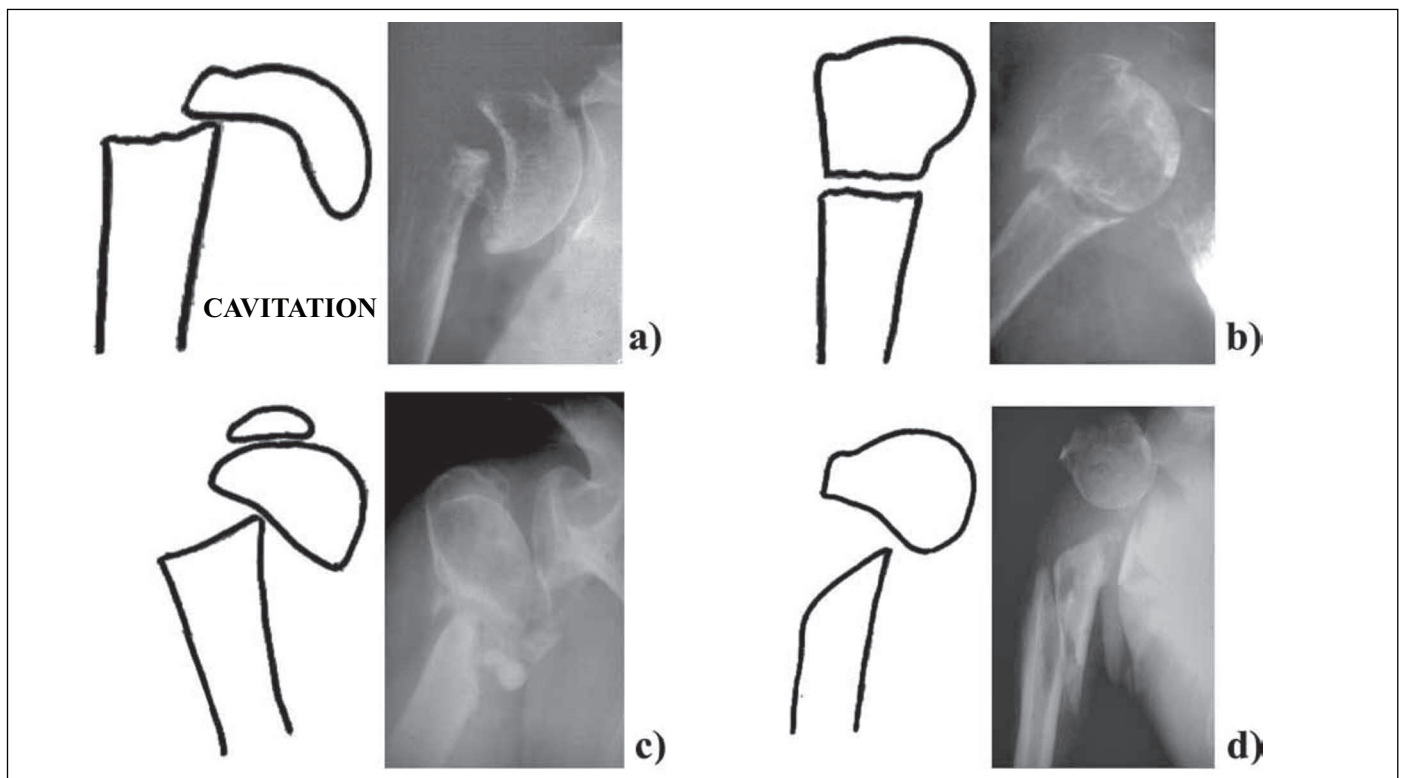


Figure 1 – Classification of pseudarthrosis of the proximal humerus into the four groups proposed by Checchia et al.: a) Group I – two parts HIGH TYPE, b) Group II – two parts LOW TYPE, c) Group III – COMPLEX, d) Group IV – with LOSS OF FRAGMENTS.

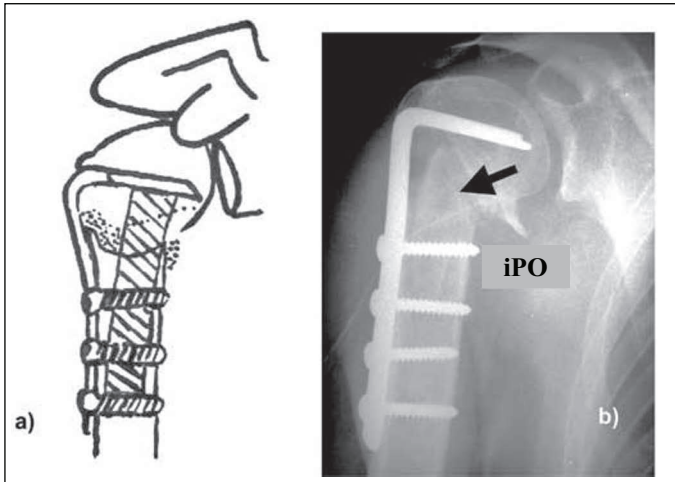


Figure 2 – a) Schematic illustration of open reduction and IO with a PFS 80° angled plate associated with nailing an autologous intramedullary tricortical graft removed from the iliac crest and peripheral cancellous bone graft to the focus of the pseudarthrosis. b) AP radiograph of the right shoulder with an arrow pointing to the intramedullary tricortical graft.

rehabilitation was initiated with passive and active assisted exercises for gaining range of motion, followed by muscle strengthening exercises.

The patients had their final functional results evaluated by the scoring system defined by the University of California at Los Angeles (UCLA)⁽²⁵⁾ and the ran-

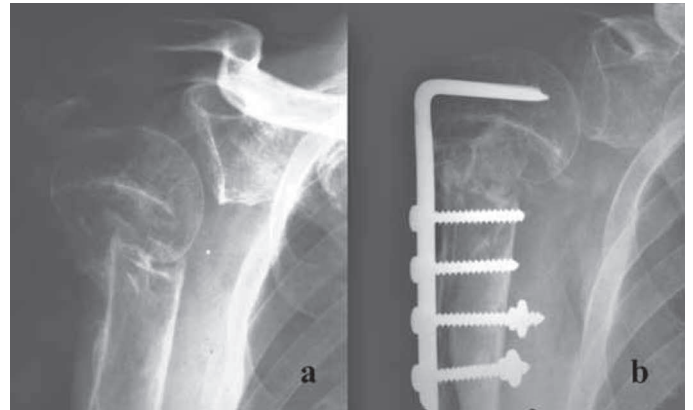


Figure 4 – a) Radiography in the anteroposterior position showing pseudarthrosis of the surgical neck of the humerus, b) radiography in the anteroposterior position illustrating the need to use the PFO nut to improve the quality of fixation in the distal fragment.

ge of motion was measured according to the criteria described by Hawkins and Bokor⁽²⁶⁾.

For statistical analysis, the Mann-Whitney test was used to compare the results according to gender, age, treatment of fracture in the acute phase, the initial fracture type, and the type of pseudarthrosis, according to the proposed classification⁽¹⁾. We used SPSS (Statistical Package for Social Sciences) and adopted a 5% significance level ($P < 0.05$).




Figure 3 – Illustration of the surgical technique: a) graft from the iliac crest; b) nailing of the graft (arrow) in the humeral shaft; c) nailing the tricortical graft on the humeral head and fixation with a PFS 80° plate associated with the use of a peripheral cancellous graft to the focus of pseudarthrosis (arrow).

* Checchia SL, Mercadante MT, Santos PD, Miyazaki NA, Roncetti R, Klausser RG, Waldrigues MG. Development and preliminary evaluation of a nut for bone fixation. Free topic presented at the 32nd Congress of the Brazilian Society of Orthopedics and Traumatology held from November 1 to 4, 2000, in Rio de Janeiro.

RESULTS

With a minimum follow-up period of 12 months and a maximum of 130 months (mean 51.4 months), four patients had excellent results, four good, and five fair, therefore we had 61.5% satisfactory results (Table 1). The average mobility in the postoperative period were 130° elevation (90° to 160°), 42° lateral rotation (20° to 60°), and a medial rotation of T10 (T5 to L5) (Table 1).

Comparing the results individually for age, we observed that patients under 60 years of age had 66% satisfactory results, while those over 60 years had 57% ($P = 0.735$), a difference without statistical significance. Regarding gender, 66% of men and 50% of women evolved with satisfactory results, without a significant difference ($P = 0.584$). Analyzing the previous treatment of the fracture in the acute phase, patients who were treated conservatively had 57% satisfactory results, whereas in cases treated surgically, 66% progressed satisfactorily ($P = 0.735$), a difference without statistical significance. Regarding the type of pseudarthrosis, 54% of the low type and 100% of the high type had a satisfactory outcome; however, the difference was not statistically significant ($P = 0.536$). Only with regard to type of fracture there was a statistically significant difference ($P = 0.025$), of which the two-part fractures had 70% satisfactory results, and the three-part fractures, 33%.

Twelve cases evolved to consolidation (92%), with

a mean time of 3.5 months (two to five months), and one patient (case 13) presented clinical and radiographic suspicion of absence of consolidation as a complication; he was re-operated and consolidation that was insufficient, that is, had only occurred in the lateral portion of the pseudarthrosis, was observed during surgery; he was treated with the addition of autologous cancellous bone graft in the medial bone defect, progressing to full consolidation and a UCLA score of 27 (Figure 5).

Other complications were observed in four patients: one case of partial loosening of the plate at its distal fixation diagnosed in the third postoperative month, but that was consolidated at the time of reassessment and without clinical complaint (UCLA = 29) (case 1) (Figures 6 and 7); subacromial impingement by the plate in two cases (6 and 11). In the first, the plate was removed two years and nine months into the postoperative period, resulting in good outcome (UCLA = 28). The second case of subacromial impingement had also had breakage of the tricortical graft as a complication during surgery, though it did not influence the final result, consolidating in five months. As for the impingement by the plate, the patient chose not to have it removed, remaining with the pain, which made the final result fair (UCLA = 27). Finally, there was one case diagnosed with hematoma (case 13) in the second week after surgery, which underwent drainage (Table 1).

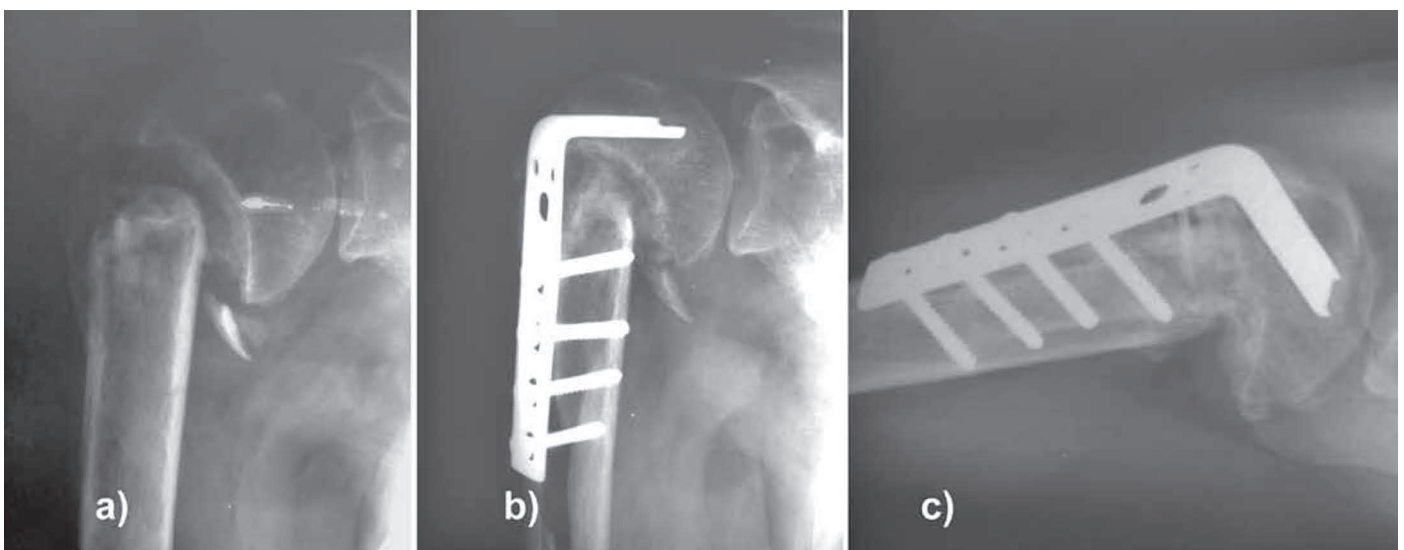


Figure 5 – Case 13 – AP X-ray of the right shoulder: a) showing the focus of the pseudarthrosis of the surgical neck of the humerus, b) image in the PO period three months after treatment of pseudarthrosis showing the absence of an osseous callus, c) axillary profile radiograph of the right shoulder, eight months in the PO (reoperation) with evidence of consolidation.

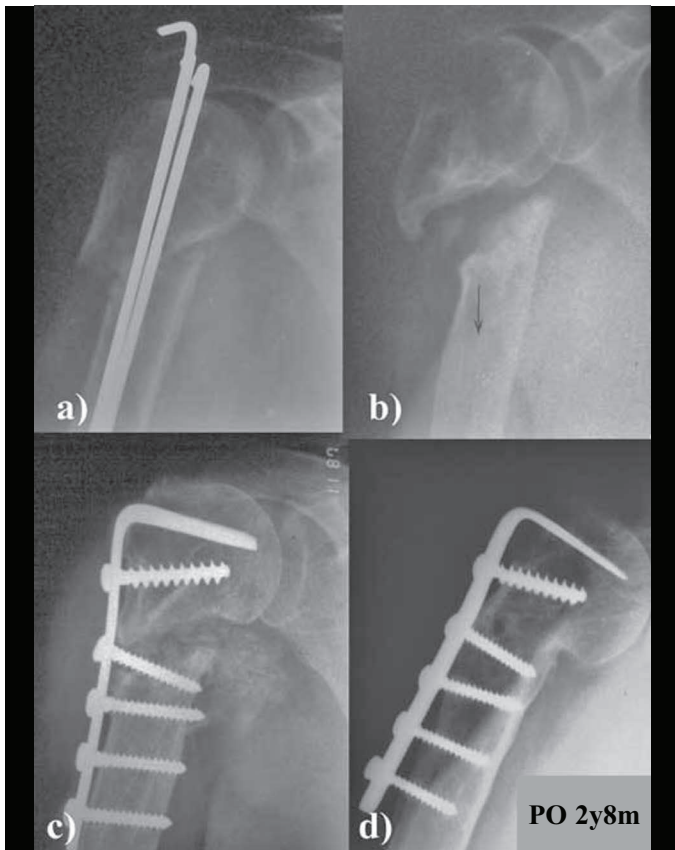


Figure 6 – Case 1 – anteroposterior radiographs: a) fracture fixation with smooth wires, b) pseudarthrosis of the surgical neck of the humerus, c) immediate postoperative period according to the technique described by Walch et al., d) Two years and eight months into the postoperative period showing distal loosening of the plate, which nonetheless progressed to consolidation.

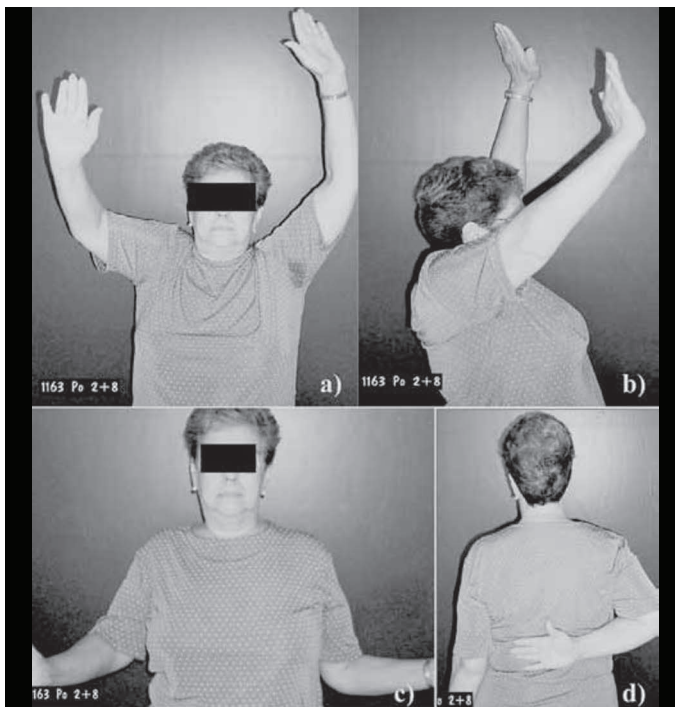


Figure 7 – Case 1 – photographs illustrating final clinical appearance two years and eight months into the postoperative period: a) front elevation view, b) elevation seen in profile, c) lateral rotation, d) medial rotation.

DISCUSSION

Pseudarthrosis of the surgical neck of the humerus is uncommon^(1,3-5,7-11), which is evidenced by the small sample size of most of the published literature, and in most cases, it is extremely disabling^(1,3,8,11,12). The fractures that most commonly progress to pseudarthrosis are two-part fractures of the surgical neck^(3,4,10,11,13-15), which was also verified by our statistics, in which 76% involved this region of the humerus. However, we should note that, in our study, we analyzed only the pseudarthroses of surgical neck and those resulting from three-part fractures with the consolidation of the tubercle with a deviation of less than five millimeters.

Similarly to Norris et al.⁽²⁰⁾, we considered three months after the fracture enough time to diagnose the pseudarthrosis, since we had four cases that, with this period of evolution, already showed signs of pseudarthrosis.

The treatment of the fracture in the acute phase was not statistically analyzed as a factor related to the etiology of pseudarthrosis due to the small sample size; however, we found that the operated patients were treated inappropriately in our opinion, predisposing cases 1, 3, 4 and 6, for example, to pseudarthrosis (Table 1).

Pseudarthrosis of the proximal humerus should be treated as early as possible to prevent worsening of local conditions, such as osteopenia, bone resorption, capsuloligamentous and myotendinous retraction, and cavitation in the proximal fragment^(1,3,5,8,11,16). However, Duralde et al.⁽⁵⁾ did not notice a worsening of results with increases in the interval between the fracture and surgery for the pseudarthrosis. In our study, pseudarthrosis was diagnosed on average 7.4 months after fracture, and although it is not possible to test statistically due to the small number of cases, we found no correlation of pseudarthrosis with longer periods of evolution with worse results. However, due to local difficulties and the high potential for complications, conservative treatment may also be indicated in the elderly, in oligosymptomatic patients, and in patients with severe medical problems^(1,3,5,9,13,17,18).

In cases where the proximal fracture fragment is very small, with significant cavitation, and porotic, in other words, in type I (high) cases, partial or total joint replacement may be indicated, especially if the articular surface of the glenoid cavity is

affected^(1,2,10,21). However, although such a procedure leads to pain relief, there is significant limitation of movement in the shoulder joint with functional impairment and unsatisfactory outcomes^(5,13,18,22). According to the classification used⁽¹⁾, we found 11 cases of low pseudarthrosis and only two high cases (cases 9 and 13), but even in these cases it was possible to perform proximal fixation, providing results that were excellent in the first (UCLA = 35) and good in the second (UCLA = 28) (Table 1). However, in our sample, there were no complex cases or cases where the IO was not possible with the technique proposed. In such cases, in our opinion, what should be considered when opting for IO and bone graft instead of the arthroplasty is the fact that, even though this is the high type of pseudarthrosis, there is the minimal bone quantity necessary for proper fixation. Other authors also consider the biological solution, with stable synthesis and bone graft, better than arthroplasty in situations with adequate bone stock in the humeral head^(1,4-6,13,18,20,21).

In the historical evolution of surgical treatment of pseudarthrosis of the surgical neck of the humerus, several techniques were developed to improve the quality of bone fixation of the proximal fragment. In 1996, Walch et al.⁽⁸⁾ described a technique using internal fixation with a T-plate associated with corticospongious intramedullary graft taken from the iliac crest and surrounded by cancellous bone graft, obtaining 96% consolidation and 81.2% according to a modified version of Constant's scale. Using such a graft increased fixation stability, both by acting as a domestic tutor, as well as the increased fixation strength of the screws in the proximal and distal fragments. Unlike Walch et al.⁽⁸⁾, we chose to fixate the pseudarthrosis with the PFS 80[®] angled-type plate⁽²³⁾ based on its results for fracture fixation in two parts of the surgical neck of the humerus, which achieved 91.3% good and excellent results according to the UCLA criteria⁽²⁵⁾ and 97.8% consolidation⁽²³⁾. Moreover, we associated tying with braided wire nonabsorbable polyester suture number 5 through holes in the proximal part of the plate, since the proximal fragment usually presents with bone resorption as well as osteopenia, and fixation is improved with this tie. It was Bosworth⁽²¹⁾ who initially described this type of treatment of pseudarthrosis with IO with the angled plate. This requires less soft tissue dissection,

even reducing the risk of necrosis of the humeral head⁽²²⁾. In 1994, Jupiter and Mullaji⁽¹¹⁾ reported 88% consolidation in nine cases; however, 44% had unsatisfactory results with the use of the angled plate and cancellous bone graft. However, they also highlighted the other advantages of the plate, such as the resistance imposed by the blade to traction at the fracture from gravity and the possibility of axial and interfragmentary compression exerted by the distal screws. In 2001, Ring et al.⁽¹⁶⁾ used the angled plate in combination with cancellous bone graft for the IO of pseudarthrosis cases and found 80% had good and excellent results, according to the modified Constant-Murley scale; however, consolidation did not occur in two cases (8%). The authors correlate this fact to the poor clinical condition of these patients. Galatz et al.⁽¹⁸⁾, in 2004, in 13 cases operated using an angled plate (10 cases) or a T-plate (three cases) for fixation, 12 achieved excellent and satisfactory results, according to the Neer criteria⁽¹⁹⁾.

In our sample, we obtained 61% excellent and good results, according to the UCLA functional scale, and 92% consolidation. We had no poor results in any of our cases and the fair results were due to occasional pain, a limited range of motion, and motor strength grade 4 in two cases (2, 7). Case 10 was a patient who suffered a fracture of the greater tubercle and the acromion, and progressed to pseudarthrosis of the two. The acromion was operated and the greater tubercle could not be repaired completely. After six months, he had a new trauma, and suffered a fracture of the surgical neck of the humerus, which also developed into pseudarthrosis that was treated with the proposed technique. Case 11 evolved with subacromial impingement caused by the plate, and had pain during specific activities and 120° elevation of the limb; however, the patient chose not to remove it. Finally, case 13, who was suspected of nonconsolidating pseudarthrosis, was reoperated and cancellous bone graft was placed in the medial defect that was found, had occasional pain and 120° of elevation. Despite these five fair cases, all patients were satisfied with the surgical procedure. In the literature, we found only two cases of avascular necrosis of the humeral head after treatment of pseudarthrosis of the humeral neck with IO. In our series, we did not find any cases of necrosis of the humeral head in the postoperative period. However,

since we evaluated only cases resulting from two-part fractures of the surgical neck and in three parts, with deviations of the greater tubercle of less than five millimeters, according to the Neer criteria⁽²⁴⁾, it was expected that there would be no development of necrosis in these cases (Table 1).

We also had, as a complication, a case of partial loosening of the distal plate fixation, diagnosed in the third month after surgery, but the pseudarthrosis had consolidated and the patient had no clinical complaints (UCLA = 29) (case 1). In our opinion, the loosening was due to osteopenia of the diaphysis and to avoid further complications like this, we used the PFO[®] nut*, required in five of our cases (Table 1).

CONCLUSIONS

Surgical treatment of pseudarthrosis of the surgical neck of the humerus by open reduction and IO with the PFS 80[®] angled plate⁽²³⁾, associated with intramedullary tricortical bone graft and autologous cancellous bone graft, led to consolidation in 92% of cases, excellent and good results in 61.5% of patients, and satisfaction in all patients at the end of treatment.

Pseudarthrosis of the surgical neck of the humerus resulting from two-part fractures had better outcomes, with 70% excellent and good results, than those resulting from three-part fractures involving the surgical neck and greater tubercle, which achieved only 33%.

* Checchia SL, Mercadante MT, Santos PD, Miyazaki NA, Roncetti R, Klausser RG, Waldrigues MG. Development and preliminary evaluation of a nut for bone fixation. Free topic presented in the 32nd Congress of the Brazilian Society of Orthopedics and Traumatology held from November 1 to 4, 2000, in Rio de Janeiro.

REFERENCES

- Checchia SL, Doneux PS, Miyazaki AN, Spir IA, Bringel R, Ramos CH. Classification of non-unions of the proximal humerus. *Int Orthop*. 2000;24(4):217-20.
- Volgas DA, Stannard JP, Alonso JE. Nonunions of the humerus. *Clin Orthop Relat Res*. 2004;(419):46-50.
- Lin J, Hou SM. Locked-nail treatment of humeral surgical neck nonunion. *J Trauma*. 2003;54(3):530-5.
- Nayak NK, Schickendantz MS, Regan WD, Hawkins RJ. Operative treatment of nonunion of surgical neck fractures of the humerus. *Clin Orthop Relat Res*. 1995;(313):200-5.
- Duralde XA, Flatow EL, Pollock RG, Nicholson GP, Self EB, Bigliani LU. Operative treatment of nonunions of the surgical neck of the humerus. *J Shoulder Elbow Surg*. 1996;5(3):169-80.
- Wang GJ, Reger SI, Stamp WG. Nonunion of fractures of the proximal humerus: a method of treatment using a modified Moe plate. *South Med J*. 1977;70(7):818-20.
- Sorensen KH. Pseudarthrosis of the surgical neck of the humerus: two cases, one bilateral. *Acta Orthop Scand*. 1964;34:132-8.
- Walch G, Badet R, Nové-Josserand L, Levigne C. Nonunions of the surgical neck of the humerus: surgical treatment with an intramedullary bone peg, internal fixation, and cancellous bone grafting. *J Shoulder Elbow Surg*. 1996;5(3):161-8.
- Scheck M. Surgical treatment of nonunions of the surgical neck of the humerus. *Clin Orthop Relat Res*. 1982;(167):255-9.
- Antuña AS, Sperling JW, Sánchez-Sotelo J, Cofield RH. Shoulder arthroplasty for proximal humeral nonunions. *J Shoulder Elbow Surg*. 2002;11(6):114-21.
- Jupiter JB, Mullaji AB. Blade plate fixation of proximal humeral non-unions. *Injury*. 1994;25(5):301-3.
- Baux S, Razemon JP. Les fractures et les fractures-luxations de l'extrémité supérieure de l'humerus. *Rev Chir Orthop Reparatrice Appar Mot*. 1969;55(5):387-496.
- Healy WL, Jupiter JB, Kristiansen TK, White RR. Nonunion of the proximal humerus. A review of 25 cases. *J Orthop Trauma*. 1990;4(4):424-31.
- Cofield RH. Comminuted fractures of the proximal humerus. *Clin Orthop Relat Res*. 1988;(230):49-57.
- Coventry MB, Laumen EL. Ununited fractures of the middle and upper humerus. Special problems in treatment. *Clin Orthop Relat Res*. 1970;(69):174-8.
- Ring D, McKee MD, Perey BH, Jupiter JB. The use of blade plate and autogenous cancellous bone graft in the treatment of ununited fractures of the proximal humerus. *J Shoulder Elbow Surg*. 2001;10(6):501-7.
- Rockwood CA, Pearce JC. Management of proximal humerus nonunion. *Orthop Trans*. 1989;13:644.
- Galatz LM, Williams GR Jr, Fenlin JM Jr, Ramsey ML, Iannotti JP. Outcome of open reduction and internal fixation of surgical neck nonunions of the humerus. *J Orthop Trauma*. 2004;18(2):63-7.
- Neer CS 2nd. Nonunion of the surgical neck of the humerus. *Orthop Trans*. 1983;7:389.
- Norris TR, Turner JA, Bovil D. Nonunion of the upper humerus: an analysis of the etiology and treatment in 28 cases. In Post M. Morrey BF & Hawkins RJ (ed): *Surgery of the shoulder*, Chicago, Mosby 1990 p. 63-7.
- Bosworth DM. Blade plate fixation: technique suitable for fractures of the surgical neck of humerus and similar lesions. *J Am Med Assoc*. 1949;141(16):1111-3.
- Galatz LM, Iannotti JP. Management of the surgical neck nonunions. *Orthop Clin of North Am*. 2000;31(1):51-61.
- Checchia SL, Doneux PS, Miyazaki AN, Fregoneze M, Silva LA, Lobo AC, et al. Avaliação do tratamento cirúrgico da fratura em duas partes do colo cirúrgico do úmero com placa PFS 80[®]. *Rev Bras Ortop*. 2004;39:555-67.
- Neer CS 2nd. Displaced proximal humeral fractures. Part I-Classification. *J Bone Joint Surg Am*. 1970;52(6):1077-89.
- Ellman H, Kay SP. Arthroscopic subacromial decompression for chronic impingement. Two-to five-years results. *J Bone Joint Surg Br*. 1991;73(3):395-8.
- Hawkins RJ, Bokor DJ. Clinical evaluation of shoulder problems. In: Rockwood CA Jr, Matsen FA 3rd. *The Shoulder*. Philadelphia: WB Saunders; 1998. p.175-180.