



# Development and validation of a postoperative nomogram for predicting overall survival after endoscopic surgical management of olfactory neuroblastoma

Jingyi Yang<sup>a</sup>, Xiaole Song<sup>a</sup>, Yuting Lai<sup>a</sup>, Weidong Zhao<sup>b</sup>, Jiaying Zhou<sup>a</sup>, Quan Liu<sup>a</sup>, Wanpeng Li<sup>a</sup>, Huankang Zhang<sup>a</sup>, Huan Wang<sup>a</sup>, Peng Shi<sup>c</sup>, Hongmeng Yu<sup>a,d,\*</sup>, Xicai Sun<sup>a,\*</sup>, Dehui Wang<sup>a,\*</sup>

<sup>a</sup> Department of Otolaryngology, Eye and ENT Hospital, Fudan University, Shanghai 200031, PR China

<sup>b</sup> Department of Nasal and Cranial Surgery, Eye and ENT Hospital, Fudan University, Shanghai 200031, PR China

<sup>c</sup> Department of Environmental Health, School of Public Health, China Medical University, Shenyang 110000, PR China

<sup>d</sup> Research Units of New Technologies of Endoscopic Surgery in Skull Base Tumor, Chinese Academy of Medical Sciences, Shanghai 200031, PR China

## ARTICLE INFO

### Article History:

Received 21 May 2020

Revised 16 September 2020

Accepted 17 September 2020

Available online xxx

### Keywords:

Olfactory neuroblastoma

Endoscopic surgery

Overall survival

Nomogram

## ABSTRACT

**Background:** Olfactory neuroblastoma (ONB) is a rare malignancy arising in the nasal vault. Endoscopic resection has been reported to improve overall survival (OS). At present, clinicopathological predictors of the prognosis of ONB remain undefined.

**Methods:** Data including demographics, clinical characteristics and follow-up information of ONB patients treated with endoscopic surgery were collected. Risk factors on OS rates were investigated by LASSO and Cox analyses. A nomogram was developed and evaluated with internal validation. Risk groups were established according to patients' points in the nomogram.

**Findings:** 154 ONB patients treated with surgery were included in this single center study. A nomogram based on multivariate Cox regression model including multiple tumor history, orbital invasion, carotid canal invasion, modified Kadish stage, delivery sequence of RT and surgery, sequence of chemotherapy and surgery was developed. The bias-corrected C-index (0.886 [95% CI: 0.843–0.943]) was significantly higher than of conventional staging classifications. The AUC of nomogram regarding 1-, 2- and 5-year OS probabilities reached 0.912, 0.929 and 0.957, respectively. The risk levels based on nomogram points were more discriminative than conventional classifications.

**Interpretation:** Validation analysis showed good predictive accuracy and discriminative ability of the nomogram. Therefore, the nomogram could be utilized to individually predict survival probability for ONB patients after endoscopic resection.

**Funding:** This study was funded by the Chinese Academy of Medical Sciences (No. 2019-I2M-5-003), the Shanghai Science and Technology Commission (No. 19411950600), the Shanghai Hospital Development Center (No. SHDC12018118) and the Eye, Ear, Nose and Throat Hospital of Fudan University (No. SYB202006).

© 2020 Published by Elsevier Ltd. This is an open access article under the CC BY-NC-ND license (<http://creativecommons.org/licenses/by-nc-nd/4.0/>)

## 1. Introduction

Olfactory neuroblastoma (ONB) is a rare malignancy arising in the nasal vault, accounting for approximately 6% of entire sinonasal malignant tumors [1,2]. The origin of ONB is uncertain with hypothesis holding that ONB possibly originates from primitive basal cells of the olfactory epithelium [3]. Orbital and anterior skull base involvement is frequently observed in ONB [4]. Since firstly reported as *esthésioneuroépithéliome olfactif* by Berger et al. [5] in 1924, various

prognostic indicators of ONB have been reported including pathological grades, cervical lymph node involvement, intracranial extension, and positive surgical margins [6,7]. However, the diagnosis and management of ONB have been challenging due to its rarity, atypical histopathological features which were easily confused with other neuroendocrine tumors and the lack of a standard staging system [8]. ONB has been treated with multidisciplinary protocols mainly based on surgery [9], and endoscopic surgery has been increasingly implemented in clinical practice. The benefit of radiotherapy (RT) and chemotherapy have been reported while no consensus on delivery sequence of surgery and adjuvant treatments has been reached [10].

At present, the most widely used staging system for ONB is modified Kadish stage, consisting of three stratifications of local extension

\* Corresponding authors.

E-mail addresses: [hongmengyush@fudan.edu.cn](mailto:hongmengyush@fudan.edu.cn) (H. Yu), [laryngeal@163.com](mailto:laryngeal@163.com) (X. Sun), [wangdehuent@sina.com](mailto:wangdehuent@sina.com) (D. Wang).

## Research in Context

### *Evidence before this study*

Olfactory neuroblastoma is an uncommon sinonasal malignant tumor. Several stratification systems including modified Kadish stage, Dulguerov stage and conventional AJCC 8th TNM staging systems have been proposed. However, here has yet to be an officially acknowledged stage system and treatment modality for olfactory neuroblastoma due to the rarity of its diagnosis.

### *Added value of this study*

The 2-, 5- and 10- year overall survival rates of the entire cohort were 86.2%, 78.2% and 72.5%, respectively. In this study we established a novel nomogram with excellent performance in predicting personalized overall survival probability in olfactory neuroblastoma patients with endoscopic surgery. The nomogram integrated 6 independent risk factors including, orbital invasion, carotid canal invasion, RT, chemotherapy the modified Kadish stage. Our purpose was to provide early stage outcomes of treating olfactory neuroblastoma patients with endoscopic surgical techniques in the form of a nomogram, since the endoscopic approach has been increasingly adopted in managing sinonasal malignancies while few studies have reported the outcome of its effectiveness in olfactory neuroblastoma.

### *Implications of all the available evidence*

Our study investigated the risk factors of survival after endoscopic surgery in a rare tumor, olfactory neuroblastoma. The nomogram established in our study could provide a reliable individualized model to predict survival for olfactory neuroblastoma patients, which could provide possible reference for otolaryngology surgeons in making treatment plans.

results were also assessed for reference. Cases with IHC results that did not support the diagnosis of ONB, or indicated further molecular pathology examination, or suggested to perform pathological biopsy again, were excluded from this study. (3) Incomplete data collection: Patients without sufficient data of interest including loss of clinical characteristics and lost to follow up.

### 2.2. Data collection and extraction

This study adhered to the Helsinki Declaration of 1975 and the requirement for written informed consent have been accordingly waived due to the retrospective study design. This study has been conducted according to the STROBE guidelines. The medical records, pathological reports, computed tomography (CT) and magnetic resonance (MR) imaging results were collected. Following data were extracted: demographic characteristics, pre- and postoperative pathological diagnosis, clinical characteristics, treatment modalities, follow-up periods and relevant survival and recurrent outcomes. Patients were stratified into different clinical stages according to the 8th edition of American Joint Committee on Cancer (AJCC) staging system for nasal cavity, modified Kadish stage and Dulguerov stage [11,12].

Surgical approaches comprised of pure endoscopic endonasal approach (EEA), endoscopic skull-base resection and endoscopic craniobasal approach. Endoscopic skull-base resection refers to operations in which anterior skull base resection and reconstruction was performed using endoscopic approach. The endoscopic craniobasal approach refers to open surgery in anterior skull base performed by neurosurgeons and assisted by otolaryngology surgeons using endoscopic approach to remove disease in the sinonasal area. According to preoperative imaging and intraoperative findings, for tumors invading only the bone of anterior skull base with no obvious evidence of dura involvement found, we tend to preserve the dura to reduce the incidence of cerebrospinal fluid (CSF) rhinorrhea. These patients were generally recommended with adjuvant treatment to improve local control. Severe perioperative complications were also collected. Tumor anatomic location and extent of invasion, the presence of distant and cervical lymph node metastases was retrieved from imaging findings. Retropharyngeal lymph nodes with diameter > 5 mm and cervical lymph nodes with shortest diameter of the largest axis > 10 mm or necrosis on the CT/MRI images were considered positive [13]. Patients suspected of cervical lymph node involvement at presentation were generally recommended with elective neck irradiation (ENI) with/without chemotherapy and elective neck dissection (END) was performed in 3 patients. Orbital invasion was classified into three grades according to classification proposed by Iannetti et al. [14]: (I) erosion or destruction of the medial orbital wall; (II) invasion of the periorbital fat tissue; and (III) invasion of the medial rectus of the ocular bulb, the ocular bulb itself, the optic nerve, or the palpebral skin. All patients had a strong desire to preserve their eyes in this study. Rigorous preoperative conversation was made with Grade III orbital invasion patients and their dependents, informing the need to perform orbital exenteration and the potential disadvantage of choosing globe preserving surgery. Adequate informed consents were made. Given the situation, in operation we tended to preserve the eyeball and tried to pursue GTR when there was limited involvement of intraorbital fat or when the tumor could be separated from the eyeball. Considering the survival benefit of surgical treatment, operations were still performed to remove disease for patients rejecting orbital exenteration after thorough conversation with patients on inform consent. Adjuvant treatment was recommended strongly postoperatively in these patients.

Some patients received RT pre- or postoperatively based on tumor invasion and patients' tolerance to whole course RT. The techniques utilized included two-dimensional conventional RT (2D-RT), three-dimensional conformal RT (3D-CRT), and intensity-modulated RT (IMRT). The radiation dose ranged from 50 to 72 Gy for the

and tumor metastasis [11]. However, detailed clinical characteristics such as orbital invasion, skull base invasion and choice of treatment strategies should be taken into account for prognostic assessment. Nomogram is a graphical prediction tool intergrading significant prognostic factors based on regression models. Our purpose was to provide early stage outcomes of treating ONB patients with endoscopic surgical techniques in the form of a nomogram, since the endoscopic approach has been increasingly adopted in managing sinonasal malignancies while few studies have reported the outcome of its effectiveness in ONB.

## 2. Material and Methods

### 2.1. Study population

Under the approval of ethics committee of the Eye, Ear, Nose and Throat Hospital of Fudan University, which is a teaching tertiary specialized hospital located in Shanghai, China, medical record database of the hospital was retrospectively searched to collect data of patients pathologically diagnosed with "olfactory neuroblastoma" or "esthesioneuroblastoma" between June 12, 2007 and October 30, 2019.

Exclusion of patients was conducted by the following criteria: (1) Without endoscopic surgical treatment: Patients who received only chemotherapy, radiotherapy or concomitant chemoradiotherapy in the Department of Radiotherapy of the Eye, Ear, Nose and Throat Hospital or treated with only open surgery. (2) Other pathological types: Pathological diagnosis was made by two pathologists independently in this study. Hematoxylin and Eosin (HE) stain was regarded as the gold standard for diagnosis, and immunohistochemistry (IHC)

preoperative group and 50–69 Gy for the postoperative group. Chemotherapy was given concurrently with RT or as neoadjuvant treatment to surgery with various regimens including platinum-based drugs with vincristine, epirubicin and pirarubicin. Radical surgical resection and postoperative RT remained the mainstay of standard treatment for ONB, while preoperative RT and adjuvant chemotherapy have been recommended by several studies in especially locally advanced disease with potential benefit in prognosis [10, 15]. Patients were generally informed of these modalities and made autonomous choice of their treatment during informed consent conversation.

A standard follow-up protocol was applied. Enhanced CT or MRI and endonasal endoscopy were routinely performed during return visits. Whole-body imaging was performed annually to detect distant metastases. Patients were reached by outpatient visits and telephone interviews. Follow-up period was defined as the duration between the date of a patient's admission and the date when event of interest occurred or the deadline of follow-up. Information about recurrence and survival were collected. The deadline of follow-up was February 20, 2020.

### 2.3. Statistical analysis

Mean and median value of continuous variables were calculated together with standard deviations (SDs) and interquartile ranges (IQRs). The least absolute shrinkage and selection operator (LASSO) method was adopted for variable selection. Features with nonzero coefficients in the LASSO Cox regression model were selected as potential survival predictors. The variables were then included in uni- and multivariable Cox regression analysis followed by a stepwise regression calculating hazard ratio (HR) with 95% confidence interval (CI) to identify independent risk predictors. Then a multivariate Cox regression model incorporating these factors recognized by stepwise regression analysis was established. A nomogram interpreting the Cox regression model were accordingly generated for predicting 1-, 2- and 5-year OS probabilities. Internal validation was performed to evaluate model performance. The discriminative ability was assessed by calculating C-indices and the area under curve (AUC) of the receiver operating characteristic (ROC) curves [16]. C-indices were internally validated by bootstrapping with 1000 resamples. Calibration plots were generated to evaluate the accuracy of prediction by bootstrapping with 1000 resamples. Patients were stratified into three risk groups namely low, moderate and high risk according to their individual points in nomogram, and the comparison between nomogram risk groups and conventional staging systems were presented by survival plots with Kaplan-Meier method. Decision curve analysis (DCA) was performed to compare clinical net benefit of the nomogram and conventional staging systems with R package *stdca*. Net reclassification improvement (NRI) and integrated discrimination improvement (IDI) were calculated to show the improvement in the predictive accuracy of the nomogram [17]. Univariate Cox regression was performed to investigate the risk factors concerning locoregional recurrence. Statistical analyses were all conducted with R software (version 3.5.3; <http://www.Rproject.org>). R packages including *survival*, *survminer*, *rms*, *glmnet*, *regplot*, *survivalROC*, *survcomp*, etc were used. Two-sided  $P < 0.05$  was considered statistically significant.

### 2.4. Role of funding

The funders had no role in study design, data collection and analysis, decision to publish, or preparation of the manuscript.

## 3. Results

### 3.1. Baseline characteristics and survival analysis

There were 167 patients diagnosed with ONB identified in the medical record database of the Eye, Ear, Nose and Throat Hospital of

Fudan University. After applying the inclusion and exclusion criteria, 7 patients were excluded due to undefined pathological diagnosis, 6 patients were excluded due to loss of follow-up and finally a total of 154 ONB patients were included for analysis. The median age at diagnosis of the ONB cohort was 51.0 years (mean:  $49.7 \pm 15.4$  years, range: 1–78 years, IQR: 33.75 years, Table 1). The majority of the patients were male (76.0%, 117/154). 11 (7.1%) patients were found with multiple tumor history. Among them, 3 were diagnosed with second primary malignancy (SPM) and there was one 53-year-old male afflicted by 3 cancers. Detailed information of these cases was

**Table 1**

Baseline demographics & clinical characteristics of study population.

Variables		Number of patients(%)
<b>Demographics &amp; clinical features</b>		
mean Age (SD; range)		49.7 (15.4; 1–78)
Sex	Female	37(24.0%)
Recurrent disease	Yes	13(8.4%)
Multiple malignant tumor history	Yes	11(7.1%)
<b>Surgical information</b>		
Surgical approach	EEA	119(77.3%)
	Endoscopic skull-base resection	26(16.9%)
	Endoscopic cranioasial approach	9(5.8%)
Draf III	Yes	35(22.7%)
Intraoperative CSF rhinorrhea	Yes	40(26.0%)
Skull base reconstruction	Yes	47(30.5%)
Perioperative complications	Yes	19(12.3%)
Extent of resection	GTR	135(87.7%)
	Subtotal	19(12.3%)
Margin status	Unknown	26(16.9%)
	Negative	89(57.8%)
	Positive	39(25.3%)
<b>Extent of local invasion</b>		
Orbital invasion	No	78(50.6%)
	Grade I	34(22.1%)
	Grade II	21(13.6%)
	Grade III	21(13.6%)
PPF invasion	Yes	18(11.7%)
Carotid canal invasion	Yes	9(5.8%)
Skull base invasion	Yes	80(51.9%)
Dura involvement	Yes	62(40.6%)
Intracranial invasion	Yes	49(31.8%)
<b>Conventional staging information</b>		
Modified Kadish stage	A	13(8.4%)
	B	38(24.7%)
	C	69(44.8%)
	D	34(22.1%)
Dulguerov stage	I	44(28.6%)
	II	29(18.8%)
	III	27(17.5%)
	IV	54(35.1%)
AJCC 8th T stage	T1	19(12.3%)
	T2	40(26.0%)
	T3	14(9.1%)
	T4a	21(13.6%)
	T4b	60(39.0%)
Cervical lymph node metastasis	Yes	32(20.8%)
Distant metastasis	Yes	5(3.2%)
<b>Adjuvant treatment</b>		
RT	No	32(20.8%)
	preoperative	40(26.0%)
	postoperative	82(53.2%)
Chemotherapy	No	67(43.5%)
	preoperative	28(18.2%)
	postoperative	59(38.3%)

SD, standard deviation; PPF, Pterygopalatine fossa; EEA, endoscopic endonasal approach; GTR, Gross total resection; RT, Radiotherapy; AJCC; American Joint Committee on Cancer.

summarized in Table S1. By the time of diagnosis, 32 (20.8%) patients were found with cervical lymph node metastasis, and 5 (3.2%) had distant metastases. 76 (43.5%) patients exhibited orbital invasion. According to Iannetti's grading classification on extent of orbital invasion [14], Grade I, Grade II and Grade III invasion comprised 22.1% (34/154), 13.6% (21/154) and 13.6% (21/154) of the cohort, respectively. Modified Kadish stage C (44.8%, 69/154), Dulguerov stage IV (35.1%, 54/154) and AJCC T stage T4b (39.0%, 60/154) were most commonly observed in relevant stage systems. In 40 (26.0%) and 82 (53.2%) cases, RT was respectively delivered pre- and postoperatively. 28 (18.2%) patients received neoadjuvant chemotherapy, and postoperative chemotherapy were performed in 59 (38.3%) cases.

In regard to surgical approaches, 119 (77.3%) patients received EEA and 27 (17.4%) received endoscopic skull-base resection (with skull-base reconstruction), and in 8 (5.3%) cases the operations were carried out in endoscopic cranionasal approach. Gross total resection (GTR) was achieved in 135 (87.7%, 135/154) patients while there were 19 (12.3%, 19/154) patients receiving subtotal resection. Margin status was unavailable in 26 (16.9%, 26/154) cases, and patients found with negative and positive margins accounted for 57.8% (89/154) and 25.3% (39/154), respectively. There were 19 (12.3%) people suffering from perioperative complications, such as intraoperative rupture of ICA (0.6%, 1/154), perioperative coma (1.3%, 2/154) and delirium (1.3%, 2/154), vision loss (0.6%, 1/154), transfusion reaction (0.6%, 1/154), CSF rhinorrhea (0.6%, 1/154) and epistaxis (0.6%, 1/154), postoperative fever (2.6%, 4/154), postoperative hypotension (2.6%, 4/154) and postoperative heart failure (1.3%, 2/154) (Table S2). The patient suffering from postoperative CSF rhinorrhea was dealt with conservative and antibiotic treatment to avoid meningitis. The patient with intraoperative ICA rupture passed away due to fatal hemorrhage even with emergency treatment. Postoperative coma and delirium owed mostly to brain edema caused by surgical trauma. Patients with postoperative coma regained consciousness after supportive therapy with antiepileptic drugs while in one case the patient's condition steadily deteriorated and died of brain death and cardiac arrest. Heart failure was often attributed to inappropriate fluid therapy and one patient passed away despite of positive cardiotoxic treatment. More details of baseline characteristics of these ONB patients were summarized in Table 1.

All patients were actively followed up till the date of death or the deadline with a median follow-up period of 35 months (mean: 45.4 ± 35.4 months, range: 1-152 months, IQR: 68 months). At the end of follow-up, 29 (18.8%) patients passed away and 4 of the death were attributed to causes other than ONB. The 2-, 5-, and 10- year overall survival (OS) rates of the entire cohort were respectively 86.2%, 78.2% and 72.5% (Figure S1A). 31 (20.1%) patients were observed with locoregional recurrence during follow-up, with a median recurrence free survival (RFS) period of 33.5 months (mean: 43.4 ± 34.9 months, range: 1-141 months, IQR: 53 months). The 2-, 5-year RFS rates were 84.3% and 79.3%, respectively (Figure S1B). Variables with  $p$  value < 0.1 were included in multivariate Cox analysis followed by backward stepwise regression. Recurrent disease at presentation (HR[95% CI]: 6.454[2.203-18.911],  $p=0.001$ ), orbital invasion (grade I or II, HR[95% CI]: 8.901[3.215-24.644],  $p<0.001$ ; grade III, HR[95% CI]: 5.689 [1.810-17.885],  $p=0.003$ ), RT (postoperative, HR[95% CI]: 0.179 [0.063-0.513],  $p=0.001$ ; preoperative, HR[95% CI]: 0.130[0.037-0.459],  $p=0.002$ ) and positive margins (negative margins, HR[95% CI]: 0.108[0.040-0.294],  $p<0.001$ ; unknown status, HR[95% CI]: 0.235 [0.077-0.718],  $p=0.011$ ) were identified as significant predictors of recurrence free survival (Table S3). Moreover, survival analysis revealed that preoperative chemotherapy improved RFS rate when compared with postoperative chemotherapy (Log-Rank  $p=0.037$ , Figure S2).

### 3.2. Nomogram development and validation

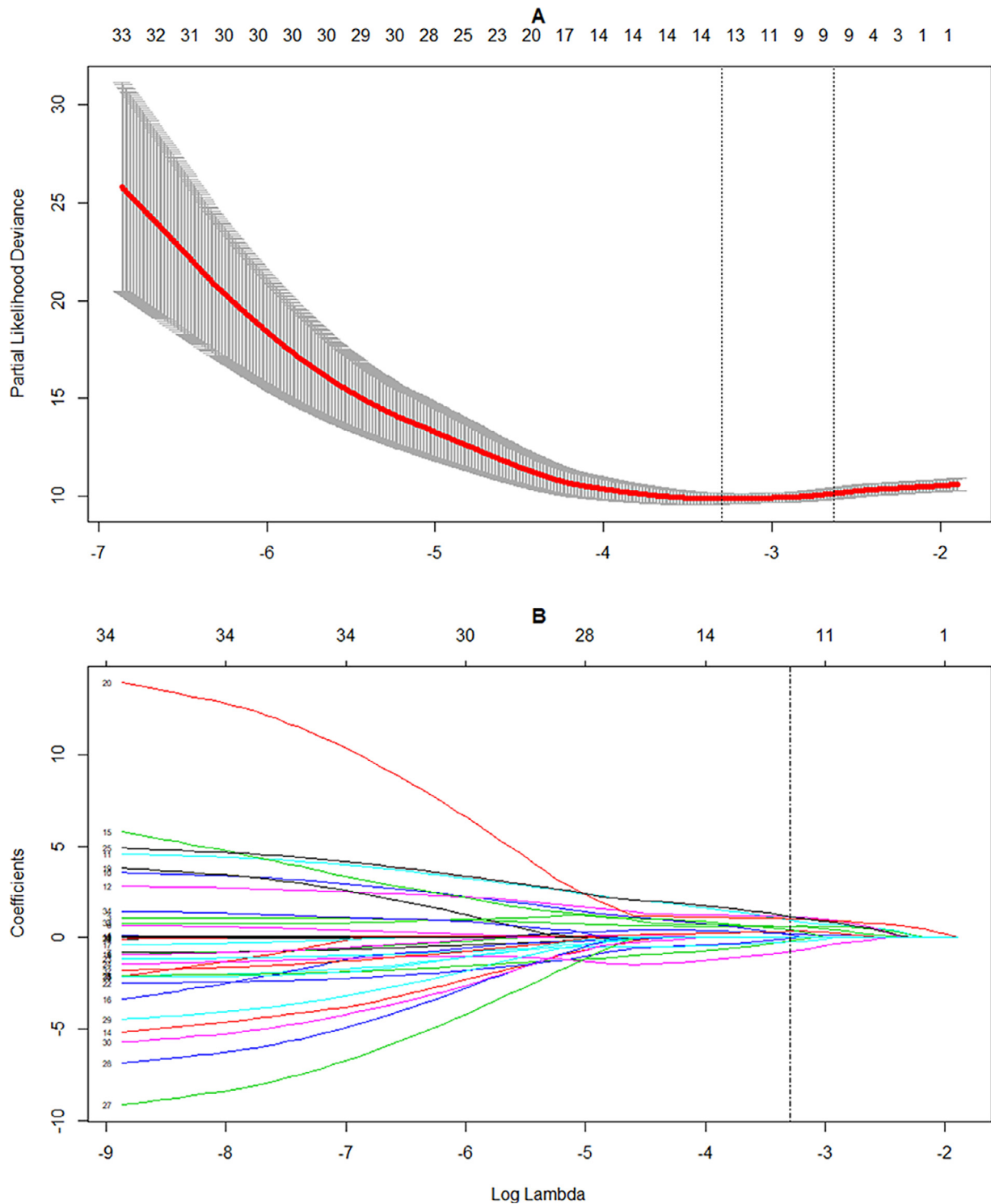
Based on 154 patients in the cohort, by selecting features with nonzero coefficients in the LASSO Cox regression model, 11 candidate variables associated with OS were identified (Fig. 1). These potential predictors consisted of recurrent disease, multiple tumor history, perioperative complications, orbital invasion, pterygopalatine fossa (PPF) invasion, carotid canal invasion, intracranial invasion, modified Kadish stage, RT and chemotherapy, and AJCC T stage. The candidate variables were then included in uni- and multivariable Cox regression analysis followed by a backward stepwise method for a model with smallest Akaike information criterion (AIC) value (Table 2). Finally, a multivariate Cox regression model was established to incorporate these significant risk factors including multiple tumor history (HR[95% CI]: 11.919 [3.601-39.452],  $p<0.001$ ), orbital invasion (Grade I+II, HR[95% CI]: 6.656[2.045-21.666],  $p=0.002$ ; Grade III, HR[95% CI]: 13.887 [3.303-58.385],  $p<0.001$ ), carotid canal invasion (HR[95% CI]: 5.004[1.273-19.677],  $p=0.021$ ), modified Kadish stage (Stage C, HR [95% CI]: 1.493[0.353-6.316],  $p=0.586$ ; Stage D, HR[95% CI]: 6.542 [1.565-27.355],  $p=0.010$ ), RT (postoperative, HR[95% CI]: 0.263 [0.093-0.740],  $p=0.011$ ; preoperative, HR[95% CI]: 0.351[0.066-1.858],  $p=0.218$ ) and chemotherapy (postoperative, HR[95% CI]: 0.307[0.114-0.829],  $p=0.020$ ; preoperative, HR[95% CI]: 0.102 [0.016-0.664],  $p=0.017$ ) (Table 2). A nomogram was accordingly developed integrating the best subsets of clinicopathological variables to predict 1-, 2- and 5-year OS probability in ONB patients treated with endoscopic resection (Fig. 2). Points of each variables in the nomogram were summarized in Table S4.

The performance of the nomogram was internally validated by estimating the discriminative ability and calibration of the new model. The bias-corrected C-index generated by bootstrap resampling was 0.886 (95% CI: 0.843-0.943) and was higher than C-indices of modified Kadish stage (0.787; 95% CI: 0.666-0.908;  $p<0.001$ ), Dulguerov stage (0.743; 95% CI: 0.639-0.846;  $p<0.001$ ) and integrated AJCC 8th TNM staging system (0.755, 95% CI: 0.660-0.850;  $P<.001$ ), indicating an excellent discriminative ability of the nomogram.

We also compared the predictive ability of the new model and conventional staging systems by comparing AUC of time-dependence ROC curves. ROC curves indicated that the nomogram had a better predictive accuracy regarding 1-, 2- and 5-year OS rates, with the AUC of nomogram reaching 0.912, 0.929 and 0.957, respectively (Fig. 3). The calibration plots internally validated by bootstrap resampling also proved an appreciable reliability of the nomogram predicting survival rates at 1-, 2- and 5-years (Fig. 4).

### 3.3. Comparison of the nomogram and traditional ONB staging systems

The primary cohort was divided into 3 stratifications, namely low-, moderate- and high-risk groups, by a trisection of the range of patients' individual points according to the nomogram (Fig. 2). Survival analysis were conducted by Kaplan-Meier method. The results proved that the OS was obvious distinguishable between 3 risk groups (Fig. 5A, Log-Rank  $p<0.001$ ), indicating that nomogram exhibited excellent discriminative ability when compared to modified Kadish, Dulguerov and 8th AJCC T stage systems (Fig. 5B-D). The results of DCA demonstrated that in a wide range of threshold probabilities, using the nomogram to predict 1-, 2-year and 5-year OS rates added more benefit than modified Kadish stage (Fig. 6). Moreover, the nomogram showed an improved prediction performance with significantly positive NRI and IDI when compared to Modified Kadish stage in predicting 1-year (IDI = 0.305[0.153-0.527],  $p<0.001$ ; NRI = 0.622 [0.309-0.824],  $p<0.001$ ), 2-year (IDI = 0.371[0.233-0.534],  $p<0.001$ ; NRI = 0.595[0.336-0.795],  $p<0.001$ ) and 5-year (IDI = 0.363[0.240-0.520],  $p<0.001$ ; NRI = 0.517[0.349-0.774],  $p=0.002$ ) OS rates.



**Fig. 1.** LASSO Cox regression model to select candidate variables associated with OS. (A) Plot of 10-fold cross-validation via minimum criteria for selection of the optimal value of tuning parameter ( $\lambda$ ). Dotted vertical lines were drawn at the value with the minimum criteria and 1 standard error of the minimum criteria. (B) LASSO coefficient profiles of 18 clinical features associated with OS. A dotted vertical line is drawn at the optimal  $\lambda$  value chosen by 10-fold cross-validation which resulted in 14 nonzero coefficients related to 11 variables. LASSO, least absolute shrinkage and selection operator; OS, overall survival.

#### 4. Discussion

Olfactory neuroblastoma (ONB) is an uncommon sinonasal malignant tumor with a reported incidence of 0.037/100,000 persons/year [18]. Several stratification systems including modified Kadish stage, Dulguerov stage and conventional AJCC 8th TNM staging systems have been proposed while there has yet to be an officially

acknowledged stage system for ONB due to the rarity of its diagnosis. In the current study, we developed a survival prediction model presented in terms of nomogram for ONB patients underwent endoscopic surgery.

Patients diagnosed with ONB in this study were enrolled retrospectively from a single center. The 2-, 5- and 10- year overall survival (OS) rates of the entire cohort were 86.2%, 78.2% and 72.5%,

**Table 2**  
Univariate and Multivariate Cox regression analysis of OS in ENB patients with endoscopic surgery.

Variables		Univariate Cox regression HR(95% CI)	p value	Multivariate Cox regression HR(95% CI)	p value
Recurrent disease	No	reference	-	-	-
	Yes	4.944(2.078-11.766)	<0.001	-	-
Multiple tumor history	No	reference	-	reference	-
	Yes	3.553(1.446-8.730)	0.007	11.919(3.601-39.452)	<0.001
Perioperative complications	No	reference	-	-	-
	Yes	3.689(1.565-8.696)	0.003	-	-
Orbital invasion	No orbital invasion	reference	-	reference	-
	Grade I or II	3.023(1.247-7.330)	0.014	6.656(2.045-21.666)	0.002
	Grade III	8.183(3.015-22.200)	<0.001	13.887(3.303-58.385)	<0.001
Carotid canal invasion	No	reference	-	reference	-
	Yes	7.079(2.364-21.200)	<0.001	5.004(1.273-19.677)	0.021
PPF invasion	No	reference	-	-	-
	Yes	4.605(1.881-11.27)	<0.001	-	-
Intracranial invasion	No	reference	-	-	-
	Yes	2.981(1.417-6.273)	0.004	-	-
Modified Kadish stage	A or B	reference	-	reference	-
	C	2.374(0.743 -7.590)	0.145	1.493(0.353-6.316)	0.586
	D	8.172(2.698-24.750)	<0.001	6.542(1.565-27.355)	0.010
RT	No	reference	-	reference	-
	postoperative	0.2373(0.106-0.532)	<0.001	0.263(0.093-0.740)	0.011
	preoperative	0.108(0.033-0.350)	<0.001	0.351(0.066-1.858)	0.218
Chemotherapy	No	reference	-	reference	-
	postoperative	0.379(0.160-0.897)	0.027	0.307(0.114-0.829)	0.020
	preoperative	0.174(0.040-0.745)	0.019	0.102(0.016-0.664)	0.017
AJCC T stage	T1	reference	-	-	-
	T2	0.653(0.146-2.924)	0.577	-	-
	T3	2.136(0.477-9.561)	0.321	-	-
	T4a	1.104(0.222-5.490)	0.903	-	-
	T4b	2.488(0.712-8.694)	0.153	-	-

ONB, Olfactory neuroblastoma; OS, Overall survival; PPF, Pterygopalatine fossa; RT, Radiotherapy; AJCC, American Joint Committee on Cancer; HR, Hazard ratio; CI, Confidence interval. Log rank  $p < 0.05$  stands for statistical significance.

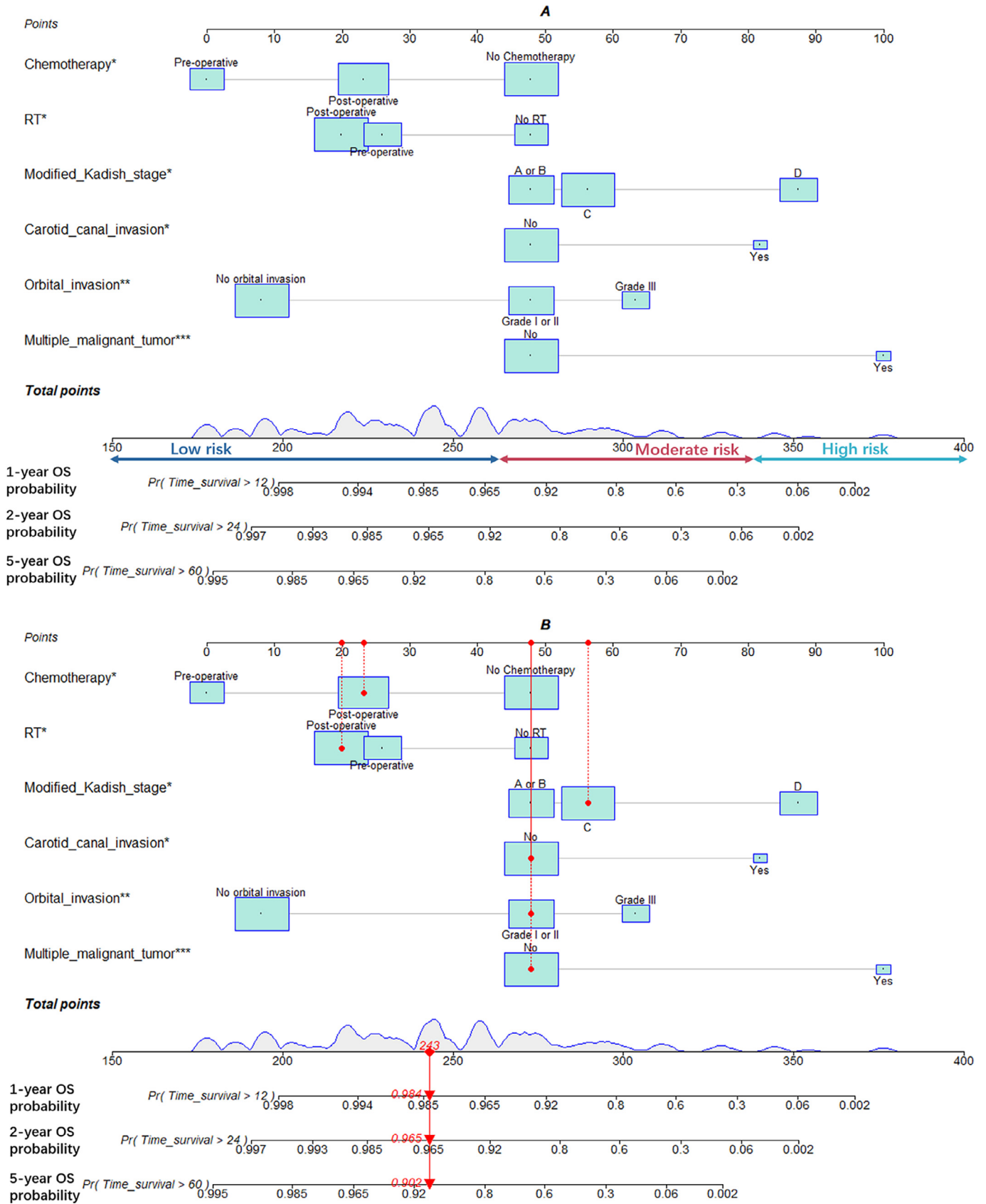
respectively. The 5-year OS rate was in line with prior single center reports and population-based studies ranging from 61% to 87% [19–23]. The 10-year OS rate was also consistent to previous reports of approximately 70% [20, 21].

The present nomogram integrated several clinical characteristics including the multiple tumor history, carotid canal invasion, extent of orbital invasion, delivery sequence between RT and surgery, and sequence between surgery and chemotherapy. Although the small number of positive events in this study might raise biased estimation, statistical differences were still observed in HRs. Although surgical approach was not recognized as an independent prognostic factor in this study, there was a trend towards worse OS in the group receiving endoscopic craniofacial approach, probably attributed to that open resection was often performed in cases with advanced disease. A meta-analysis by Fu et al. [24] revealed that endoscopic resection had better OS and DFS ( $p = 0.001$  and  $p = 0.004$ , respectively) compared to open approach, but no statistical improvement in locoregional control or metastasis-free survival (MFS) was found. Moreover, Kliromos et al. [25] mentioned in their case series of endoscopic management of ONB that endoscopic approach was reported with high rates of local control while its impact on prognosis remained unclear. In the current study, modified Kadish stage C, Dulguerov stage IV and AJCC T stage T4b were the most common classifications in relevant stage systems, indicating that ONB patients were frequently diagnosed with advanced disease, which was consistent with previous reports [15]. Widely invaded tumor posed challenge to endoscopic total resection and our result proved that among all anatomic sites affected, carotid canal involvement was a significant negative indicator for survival. Skull base reconstruction was performed in 47 (30.5%) cases with bone defect caused by surgery or intraoperative CSF rhinorrhea. Grafts utilized for reconstruction consisted of autogenous fat and fascia lata, artificial dura mater, nasoseptal pedicled flap, inferior turbinate or middle turbinate mucosa flap, in consideration

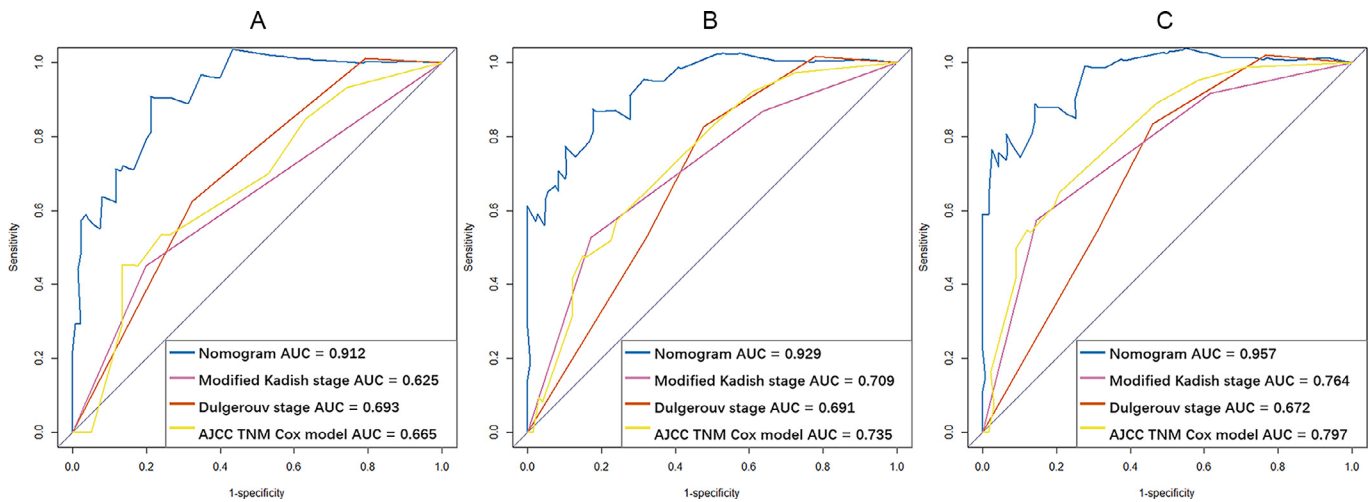
of tumor ranges, anatomic invaded structures and surgical process. Neither CSF rhinorrhea nor graft necrosis was found during postoperative endoscopic and radiological revision, since no bone or cartilage is used as graft material to avoid radionecrosis in the study [26].

Orbital invasion was divided into three grades as proposed by Iannetti et al. [14]. Our result revealed that grade III, which indicated tumor invasion of extraocular muscles, eye globe, orbital apex, or optic nerve, was a significantly negative factor on survival. The adverse impact of orbital invasion on survival was probably attributed to the difficulty in achieving negative margins by endoscopic approach for tumors involving orbital contents. The indications for orbital exenteration are continuously changing, from invasion beyond the orbital periosteum to extraconal fat and extraconal muscles [27–29]. In this study, considering that all patients had a strong desire to preserve their eyes, we tended to avoid orbital exenteration and spare the eyeball. RT and/or chemotherapy were performed postoperatively in these patients and most of them exhibited good response. Since the result of long-term follow up is deficient in these ONB patients, the effectiveness of globe preserving surgery is in need of further investigation. However, we believe that orbital exenteration should be cautiously performed to preserve function, avoid esthetic deformity and improve life quality [30]. Lisan et al. [29] reported that patients with orbital exenteration and eyeball preservation shared similar prognoses in terms of 5-year OS rate and local control rates. Li et al. [4] proposed that invasion of extraocular muscles or the eye globe should not be taken as indication for eye enucleation and preoperative RT could probably increase the possibility for eye-sparing operation.

Cervical lymph node involvement has long been reported as a risk factor on survival [13,31] and timely cervical management by RT or neck dissection were advocated for patients with N+ neck [6]. The Kadish stage system [32] and its modified version (Foote stage) [11] have been widely used for ONB staging although have received



**Fig. 2.** Postoperative nomogram predicting 1-, 2- and 5-year OS probability of ENB patients after endoscopic surgery. (A) Each clinical variable has a certain number of points (top row) ranging from 0 to 100. The sum of points of each variable was related to the probability of OS at specific timepoints (1 year, 2 years and 5 years). (B) An example illustrating the use of the nomogram. This patient was one of the ENB cohort in the current study. The patient received postoperative chemotherapy (points=23), postoperative RT (points=20), modified Kadish stage C(points=56), no carotid canal invasion (points=23), grade I orbital invasion (points=48), no multiple malignant tumor(points=48), thus the total points of this patient is 218, which is corresponded to a 98.4% probability of 1-year overall survival, a 96.5% probability of 2-year OS and a 90.2% probability of 5-year OS. ENB, Esthesioneuroblastoma; RT, radiotherapy; OS, overall survival.



**Fig. 3.** Time-dependent ROC curves of the nomogram, modified Kadish stage, Dulgerouv stage and AJCC TNM staging system predicting 1-year (A), 2-year (B) and 5-year (C) OS with corresponding AUC values. ROC, receiver operating characteristic; AUC, Area under curve; AJCC, American Joint Committee on Cancer; OS, overall survival.

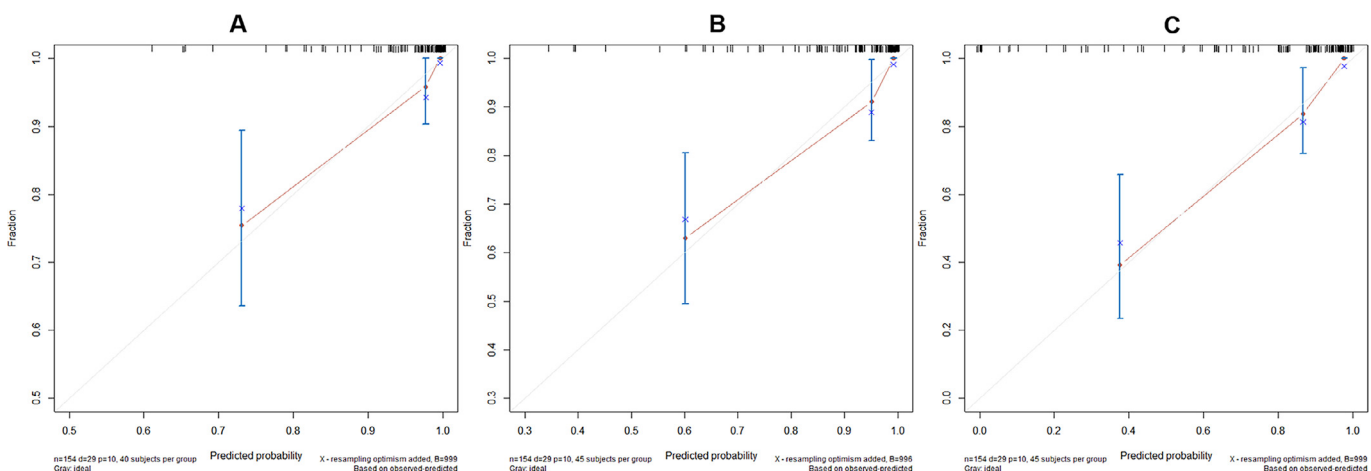
criticisms for the rough assessment of local extension [6]. The present nomogram incorporated modified Kadish stage with some detailed descriptions for local invasion including orbital and carotid canal involvement to develop an individualized model with improved discriminative ability.

Moreover, multiple tumor history was identified as a risk factor for survival in ONB patients, which could definitely contribute to increased mortality risk. There were 11 (7.1%) patients diagnosed with other malignancies, suggesting that patient diagnosed with ONB might be more susceptible to malignant tumors. Genetic predisposition could be a possible explanation. The result suggested that ONB patients were in need of long-term surveillance for secondary primary malignant tumors.

RT and chemotherapy have been combined with surgical resection in a multidisciplinary perspective to deal with ONB [6,9,33]. Surgical resection followed by adjuvant RT has been advocated as standard protocol [10]. Preoperative RT was reported to improve prognosis but there has yet to be a consensus on the delivery sequence of RT and surgery [34]. In accordance with previous studies [10, 33, 34], the benefit in survival and local control of both pre- and postoperative RT were proved by our results, although there was no significant difference between these two RT-surgery sequence groups. Similar results were observed in our investigation of the effectiveness of chemotherapy. Generally, neoadjuvant chemotherapy was applied for ONB patients with recurrent, metastatic, or

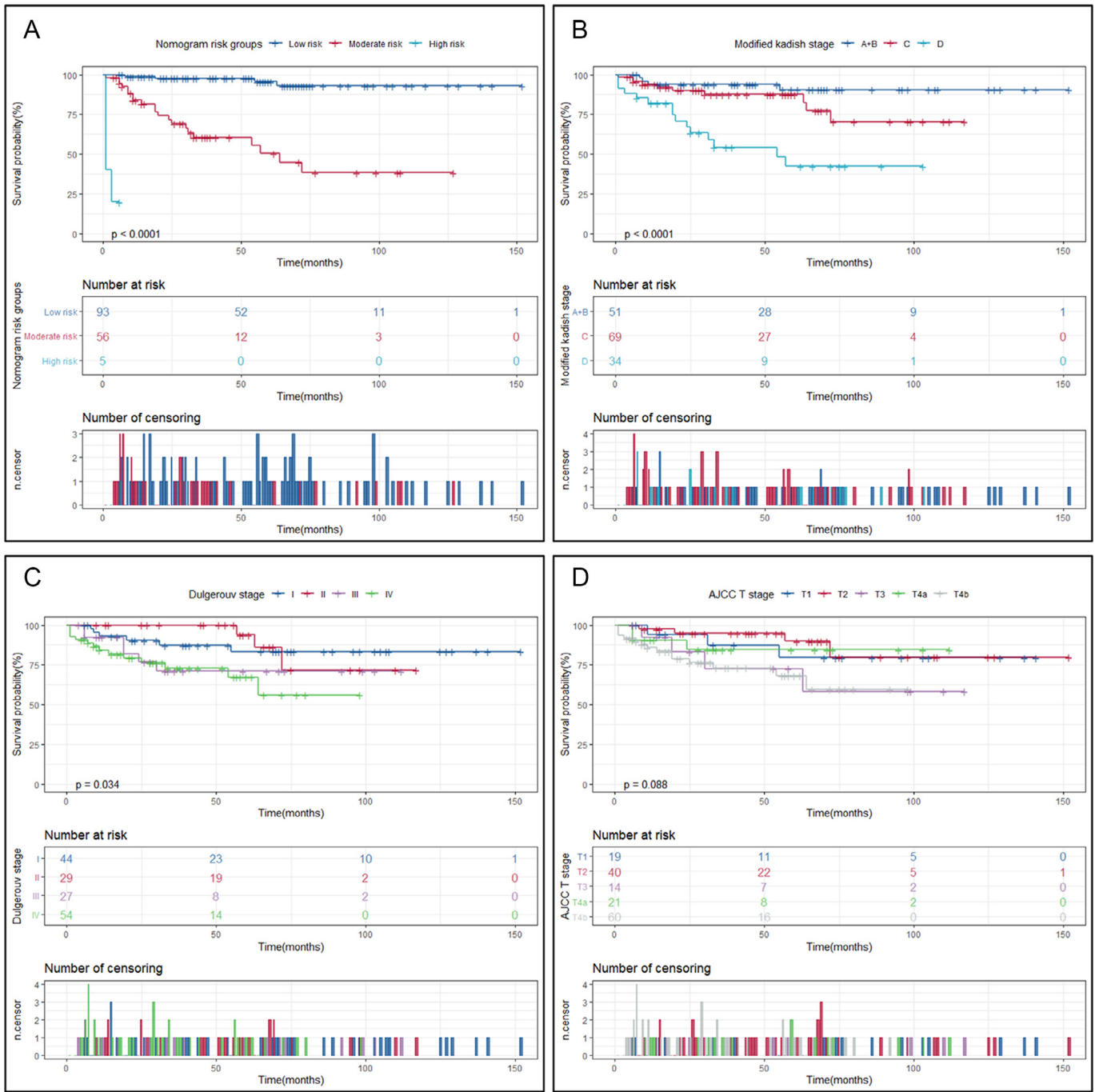
locally advanced disease to improve survival [6]. Cases with poorly differentiated disease were reported to benefited from postoperative chemotherapy after total resection [10, 35]. Of note, our results revealed that neoadjuvant chemotherapy significantly improved RFS, while postoperative chemotherapy group shared similar RFS rates with patients without chemotherapy.

To our knowledge, this is the first study to develop a nomogram based on clinical characteristics to predict OS in ONB patients treated with endoscopic resection. However, several limitations of this study should be acknowledged. First, this single-center study has inevitable bias due to its retrospective nature. This retrospective study might have selection bias in the inclusion of patients and the collection of clinical characteristics of interest. We basically collected ONB patients in a chronological order according to their time of admission. And since that our center is a hospital specialized in eye, ear, nose and throat disease, some patients with advanced tumor (such as intracranial lesion) might preferred to seek medical advice in other general tertiary hospitals instead of our institution, which might have caused selection bias. Second, despite an internal validation with bootstrap method, the nomogram is in lack of external validation due to the limited sample size considering the rarity of ONB, which could result in the difficulty to uncover and avoid potential over-fitting of the regression model and hence reduce the validity of the nomogram, leaving the generality of the nomogram in other population remained uncertain. To eliminate the shortcoming of this study, multi-center



**Fig. 4.** Internal and calibration plots of the nomogram by bootstrapping with 1000 resamples predicting 1-year (A), 2-year (B) and 5-year (C) OS.



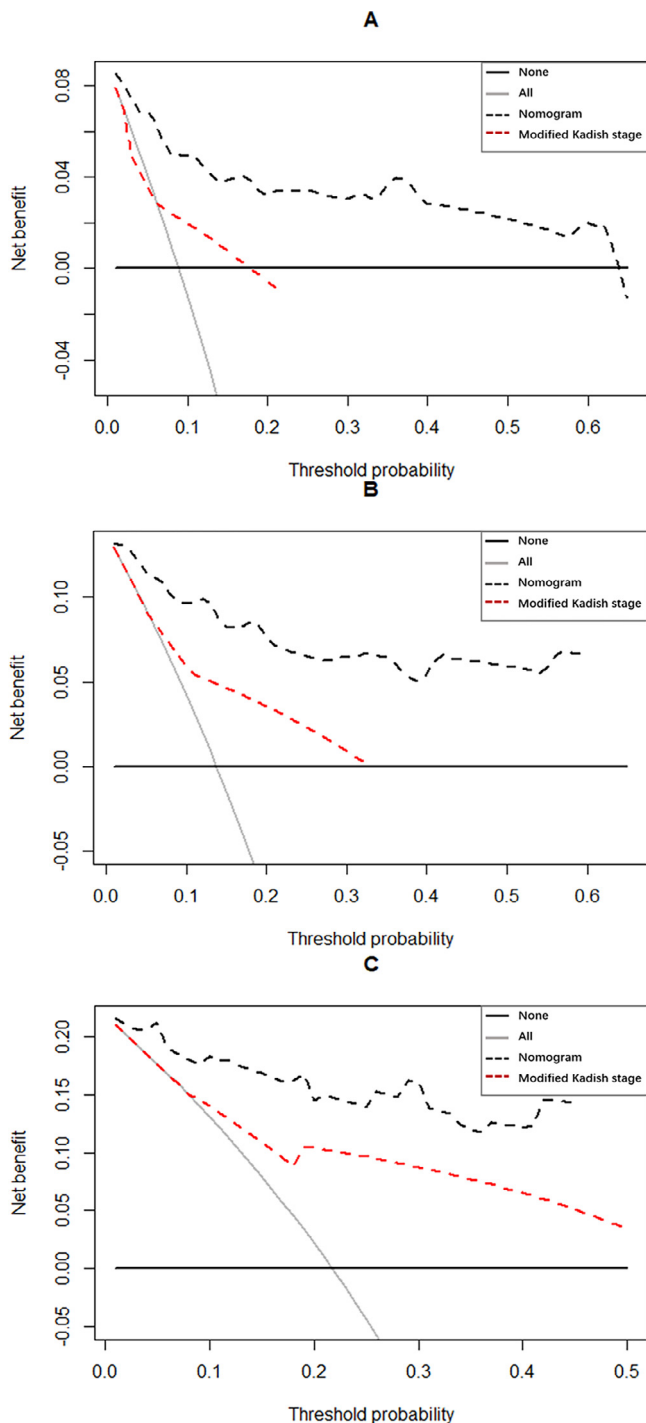


**Fig. 5.** Kaplan-Meier survival curves comparing risk groups generated by nomogram (A) and conventional staging systems including modified Kadish (B), Dulguerov (C) and AJCC 8th T stage (D). AJCC, American Joint Committee on Cancer.

research with larger sample size and randomized double blind prospective clinical trials are in need for further investigation. Third, Hyams grades were not included in this study because the system has not been generally used to assess pathological grades for every ONB patients until recent years in our institution. The impact of Hyams grades on outcomes has been demonstrated in previous studies including reports from Mayo Clinic and MD Anderson Cancer Center [36, 37]. Excluding those patients without Hyams grading records would definitely increase the quality of evidence, but would also lead to insufficient samples to generate reliable statistical results. Thus, the relevant features had to be omitted in this study. Moreover, our study was restricted by the relatively short period of time studied with very few patients have been followed up for over 10 years since the surgeons with endoscopic surgical technique of EEA was not

fully-fledged in our center until the 2000s. Long-term follow up is necessary to further validate the assumptions and conclusions regarding prognosis.

In conclusion, a nomogram for predicting the probability of OS in ONB patients with endoscopic surgery was developed and validated in this study. The present nomogram based on clinical features showed excellent discriminative ability and accuracy for prediction, in comparison with conventional stage classifications including modified Kadish, Dulguerov and AJCC 8th TNM staging system. Therefore, the nomogram could be utilized to individually predict survival probability at different time points for ONB patients after endoscopic resection. We believe that our results could assist clinicians to assess the early prognosis of certain ONB patients, so as to effectively communicate with patients on informed consent as well as to develop



**Fig. 6.** Plots of DCA for the nomogram and the modified Kadish stage system predicting 1-year (A), 2-year (B) and 5-year (C) OS probabilities. DCA, Decision curve analysis; OS, overall survival.

appropriate treatment and follow-up strategies, adding to the literature about outcomes of ONB patients treated with endoscopic surgery since there were relatively few studies providing results of this technique.

#### Data sharing statement

According to the data agreement we signed with the Eye & ENT Hospital, Fudan University, Shanghai, China, we are not allowed to share our data.

#### Declaration of Competing Interest

We declare that all authors have no other funding, financial relationships, or conflicts of interest to disclose.

#### Acknowledgment

Our deepest gratitude goes to all the olfactory neuroblastoma patients enrolled in this study. Jingyi Yang would like to appreciate Ruoyan Wei and Shenchao Wang for their encouragement and care.

#### Funding

This study was funded by the Research Units of New Technologies of Endoscopic Surgery in Skull Base Tumor (2018RU003) supported by Chinese Academy of Medical Sciences (No. 2019-I2M-5-003) to H.Y., the clinical medicine project “Science and Technology Innovation Action Plan” (No. 19411950600) of Science and Technology Commission of Shanghai Municipality to H.Y., the clinical medicine project “Optimization and promotion of the treatment of recurrent nasopharyngeal carcinoma” (No. SHDC12018118) supported by Shanghai Shen Kang Hospital Development Center to D.W., and the “Outstanding Doctor & Outstanding Clinical Researcher” project titled “Effectiveness of radiotherapy versus endoscopic surgery in the treatment of olfactory neuroblastoma sensitive to chemotherapy: A randomized controlled clinical trial” (No. SYB202006) supported by the Eye, Ear, Nose and Throat Hospital of Fudan University to X.S.. The funders had no role in the study design, data collection and analysis, decision to publish, or preparation of the manuscript. The authors have not been paid to write this article by a pharmaceutical company or other agency.

#### Supplementary materials

Supplementary material associated with this article can be found, in the online version, at doi:10.1016/j.eclim.2020.100577.

#### References

- [1] Song CM, Won TB, Lee CH, et al. Treatment modalities and outcomes of olfactory neuroblastoma. *Laryngoscope* 2012;122(11):2389–95.
- [2] Bradley PJ, Jones NS, Robertson I. Diagnosis and management of esthesioneuroblastoma. *Curr Opin Otolaryngol* 2003;11(2):112–8.
- [3] Classe M, Yao H, Mouawad R, et al. Integrated multi-omic analysis of esthesioneuroblastomas identifies two subgroups linked to cell ontogeny. *Cell Rep* 2018;25(3):811–21.
- [4] Li R, Tian S, Zhu Y, et al. Management of orbital invasion in esthesioneuroblastoma: 14 years' experience. *Radiat Oncol* 2019;14(1).
- [5] Berger L, Luc R, Richard D. L'esthesioneuroepitheliome olfactive. *Bull Assoc Fr Etud Cancer* 1924;13:410–21.
- [6] Abdelmeguid AS. Olfactory neuroblastoma. *Curr Oncol Rep*, 2018;20(1):7.
- [7] Saade RE, Hanna EY, Bell D. Prognosis and biology in esthesioneuroblastoma: the emerging role of Hyams grading system. *Curr Oncol Rep* 2015;17(1):423.
- [8] Dulguerov P, Allal AS, Calcaterra TC. Esthesioneuroblastoma: a meta-analysis and review. *Lancet Oncol* 2001;2:683–90.
- [9] Miller KC, Marinelli JP, Van Gompel JJ, et al. Utility of adjuvant chemotherapy in patients receiving surgery and adjuvant radiotherapy for primary treatment of esthesioneuroblastoma. *Head Neck* 2019;41(5):1335–41.
- [10] Fiani B, Quadri SA, Cathel A, et al. Esthesioneuroblastoma: a comprehensive review of diagnosis, management, and current treatment options. *World Neurosurg* 2019;126:194–211.
- [11] Morita A, Ebersold MJ, Olsen KD, et al. Esthesioneuroblastoma: prognosis and management. *Neurosurgery* 1993;32(5):706–15.
- [12] Dulguerov P, Calcaterra T. Esthesioneuroblastoma: the UCLA experience 1970–1990. *Laryngoscope* 1992;102:843–9.
- [13] Song X, Wang J, Wang S, Yan L, Li Y. Prognostic factors and outcomes of multimodality treatment in olfactory neuroblastoma. *Oral Oncol* 2020;103:104618.
- [14] Iannetti G, Valentini V, Rinna C, Ventucci E, Marianetti TM. Ethmoido-orbital tumors: our experience. *J Craniofac Surg* 2005;16:1085–91.
- [15] Alotaibi HA, Priola SM, Bernat A, et al. Esthesioneuroblastoma: summary of single center experiences with focus on adjuvant therapy and overall survival. *Cureus* 1(6): e4897.

- [16] Harrell FE, Lee KL, Mark DB. Multivariate prognostic models: issues in developing models, evaluation assumptions and adequacy, and measuring and reducing errors. *Stat Med* 1996;15:361–87.
- [17] Pencina MJ, D'Agostino RB, Vasan RS, et al. Evaluating the added predictive ability of a new marker: from area under the ROC curve to reclassification and beyond. *Stat Med* 2008;27(2):157–72.
- [18] König MS, Osnes T, Meling TR. Treatment of esthesioneuroblastomas. *Neurochirurgie* 2014;60(4):151–7.
- [19] Joshi RR, Husain Q, Roman BR, et al. Comparing Kadish, TNM, and the modified dulguerov staging systems for esthesioneuroblastoma. *J Surg Oncol* 2019;119(1):130–42.
- [20] Lui A, Parvathaneni U, Laramore GE, et al. Management and long-term outcomes of esthesioneuroblastoma at a single institution. *Int J Radiat Oncol Biol Phys* 2017;99:355–6.
- [21] Sharrett JM, Jiang W, Mohamed AS, et al. Multimodality management of patients with esthesioneuroblastoma. *Int J Radiat Oncol Biol Phys* 2015;93:E349.
- [22] Carey RM, Godovchik J, Workman AD, et al. Patient, disease, and treatment factors associated with overall survival in esthesioneuroblastoma. *Int Forum Allergy Rhinol* 2017;7:1186–94.
- [23] Tajudeen BA, Arshi A, Suh JD, et al. Importance of tumor grade in esthesioneuroblastoma survival a population-based analysis. *Jama Otolaryngol* 2014;140(12):1124.
- [24] Fu TS, Monteiro E, Muhanna N, Goldstein DP, de Almeida JR. Comparison of outcomes for open versus endoscopic approaches for olfactory neuroblastoma: a systematic review and individual participant data meta-analysis. *Head Neck* 2016;38(Suppl 1):E2306–16.
- [25] Klironomos G, Gonen L, Au K, et al. Endoscopic management of esthesioneuroblastoma: our experience and review of the literature. *J Clin Neurosci* 2018.
- [26] Bozkurt G, Leone F, Arosio AD, et al. Septal flip flap for anterior skull base reconstruction after endoscopic transnasal craniectomy: long-term outcomes. *World Neurosurg* 2019;166:E1–8.
- [27] Suarez C, Ferlito A, Lund VJ, et al. Management of the orbit in malignant sinonasal tumors. *Head Neck* 2008;30(2):242–50.
- [28] Imola MJ, Schramm VJ. Orbital preservation in surgical management of sinonasal malignancy. *Laryngoscope* 2002;112(8):1357–65.
- [29] Lisan Q, Kolb F, Temam S, et al. Management of orbital invasion in sinonasal malignancies. *Head Neck* 2016;38:1650–6.
- [30] Safi AF, Behn L, Rothamel D, et al. Therapy of sinonasal malignancies invading the orbit-orbital exenteration versus preservation of the orbit plus radiotherapy. *J Cranio Maxill Surg* 2017;45(2):258–61.
- [31] Zanation AM, Ferlito A, Rinaldo A, Gore MR, Lund VJ, McKinney KA, et al. When, how and why to treat the neck in patients with esthesioneuroblastoma: a review. *Eur Arch Otorhinolaryngol* 2010;267:1667–71.
- [32] Kadish S, Goodman M, Wang C. Olfactory neuroblastoma—a clinical analysis of 17 cases. *Cancer* 1976;37(3):1571–6.
- [33] Turri-Zanoni M, Maragliano R, Battaglia P, et al. The clinicopathological spectrum of olfactory neuroblastoma and sinonasal neuroendocrine neoplasms: refinements in diagnostic criteria and impact of multimodal treatments on survival. *Oral Oncol* 2017;74:21–9.
- [34] Yin ZZ, Gao L, Luo JW, et al. Long-term outcomes of patients with esthesioneuroblastomas: a cohort from a single institution. *Oral Oncol* 2016;53:48–53.
- [35] Porter AB, Bernold DM, Giannini C, et al. Retrospective review of adjuvant chemotherapy for esthesioneuroblastoma. *J Neurooncol* 2008;90:201–4.
- [36] Agarwal V, Hughes J, Foote R, et al. Delaying post-operative radiation in low grade esthesioneuroblastoma: Is it worth the wait? *J Neurol Surg B* 2017;78(S 01):S1–S156.
- [37] Saade RE, Hanna EY, Bell D. Prognosis and biology in esthesioneuroblastoma: the emerging role of Hyams grading system. *Curr Oncol Rep* 2015;17(1):423.