

## C A S E R E P O R T

# The use of Carbon-Peek volar plate after distal radius osteotomy for Kienbock's Disease in a volleyball athlete: a case report

*Matteo Guzzini, Giorgio Princi, Lorenzo Proietti, Andrea Ferretti*

Orthopaedic Unit and "Kirk Kilgour" Sports Injury Centre, S. Andrea Hospital, University of Rome "La Sapienza", Rome, Italy

**Summary.** Kienbock's Disease, or lunatomalacia, has uncertain etiopathogenesis, it is more common in male from 20 to 45-year-old. The Lichtman's classification is the most used by authors and it divides Kienbock's Disease in 4 stages according to radiographic parameters. In early stages could be performed a conservative treatment, but failure rate is high; various surgical techniques are available in case of failure or higher stages. We report a case of a 26-year-old female volleyball player affected by stage I Kienbock's Disease who underwent distal radius osteotomy core decompression synthesized with Carbon-Peek plate fixation. Follow-up was performed with clinical evaluation (ROM analysis, VAS score, Quick Dash Score), wrist radiographs and wrist MRI. ([www.actabiomedica.it](http://www.actabiomedica.it))

**Key words:** Kienbock, Carbon-Peek plate, volleyball, radius osteotomy, core decompression

## Introduction

Kienbock's Disease has uncertain etiopathogenesis, it is probably caused by repeated wrist traumatism or a single acute episode (1, 2); it is more common in dominant hand of male from 20 to 45-year of age.

Lichtman classification divides Kienbock's Disease in 4 stages (3, 4):

- stage I: normal radiographs, changes on MRI;
- stage II: definite density changes in the lunate bone on x-ray images;
- stage IIIA: collapsed lunate without scaphoid rotation;
- stage IIIB: collapsed lunate with fixed scaphoid rotation;
- stage IV: pan carpal arthrosis.

A variety of surgical treatments are available (temporary scapho-trapezio-trapezoidal pinning, joint leveling procedure, arthroscopic core decompression (5), radial wedge osteotomy, vascularized bone graft,

wrist fusion, etc.) after failure of conservative treatments (rest, NSAID, Corticosteroid injection, shock waves, etc). In case of young patients, a radius-carpal joint decompression performed with a shortening osteotomy of the distal radius can represent a valid choice of treatment. Carbon-Peek fixation devices are currently used in traumatology with good clinical and radiological results for the treatment of wrist and ankle fractures (6, 7); in particular for wrist fractures are available two kind of plates (standard plates or anatomic low-profile Carbon-Peek plates) (8).

We report a case of a 26-year-old female volleyball player affected by stage I Kienbock's Disease who underwent distal radius osteotomy core decompression with Carbon-Peek plate fixation. Follow-up was performed with clinical evaluation (ROM analysis, VAS score, Quick Dash Score), radiographs and MRI scan. To our knowledge, there are no studies in the literature regarding Kienbock's disease treated with Carbon-Peek fixation devices.

## Case History

A 26-year-old female volleyball player presented with an increasing left wrist pain, swelling, tenderness and functional limitation without any efficient trauma. Conventional wrist radiographs displayed normal carpal bones and a negative ulnar variance. Wrist Magnetic Resonance Imaging (MRI) showed high signal intensity of the lunate on T2-weighted images and normal signal intensity on T1-weighted images (Fig. 1). These results are compatible with a diagnosis of stage I Kienbock's Disease according to Lichtman's classification (3, 4).

After 1 month of conservative treatment (rest and NSAID) with no results, surgical options were the following: distal radius core decompression, joint levelling procedure, revascularization procedures. Due to negative ulnar variance a surgical core decompression with distal radius shortening osteotomy associated with Carbon-Peek plate fixation was performed. The choice of Carbon-Peek plate was due to its radiolucency on radiographs and low intensity signal on MRI. The postoperative protocol included wrist immobilization with cast for 2 weeks and follow-up was performed with clinical and radiographical evaluation at 1 month

follow-up and clinical, radiographical and MRI evaluation at 3 months follow-up. Pain relief was obtained at 3 weeks and complete consolidation of osteotomy was shown after 1 month on radiographs. Normal signal intensity on MRI T2-weighted images for lunate bone was shown at 3 months follow-up (Fig. 2).

Return to volleyball training was conceded after 3 months.

Clinical evaluation was performed with analysis of wrist range of motion (ROM), Visual Analogue Score (VAS) and Quick Dash Score at final follow-up. Results showed wrist flexion of 90 degrees, wrist extension of 85 degrees, ulnar deviation of 35 degrees, radial deviation of 20 degrees (Fig. 3). VAS score at follow-up was 0. Quick Dash Score result was 6.8%.

## Discussion

Kienbock's Disease is difficult to diagnose in early stage and in these cases MRI T2-weighted images represent the gold standard for diagnosis. In early stages (I-II according to Lichtman's classification) associated with a negative ulnar variance, distal radius shortening osteotomy with plate fixation offers good clinical

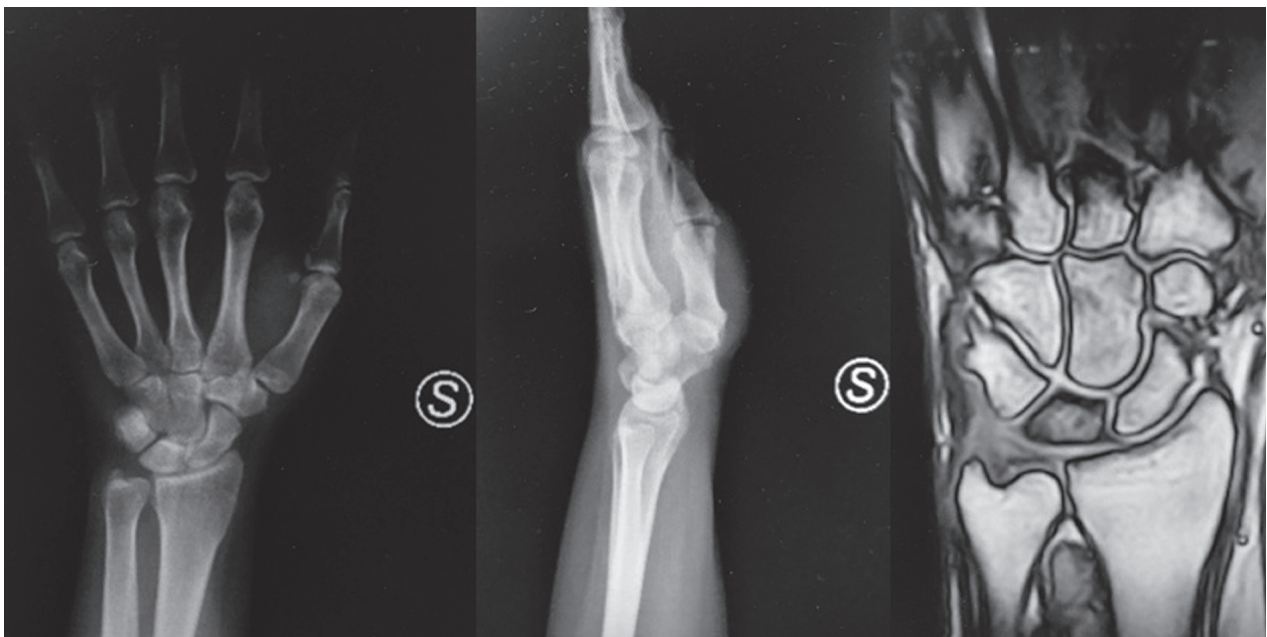
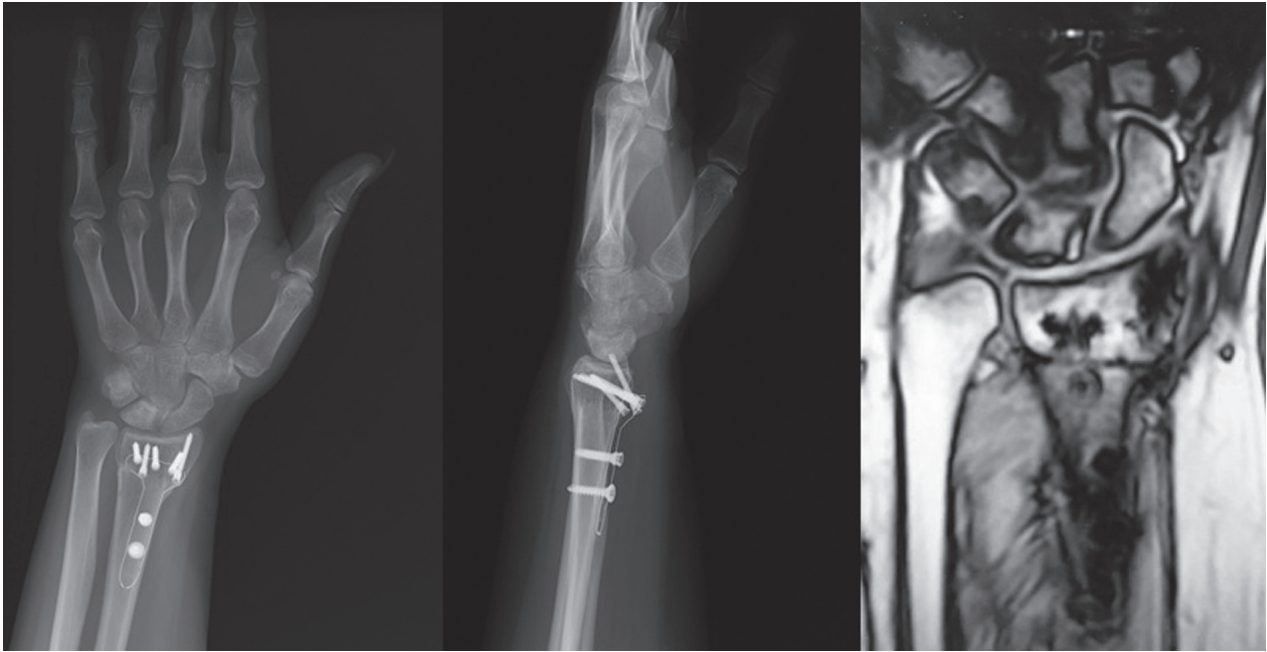
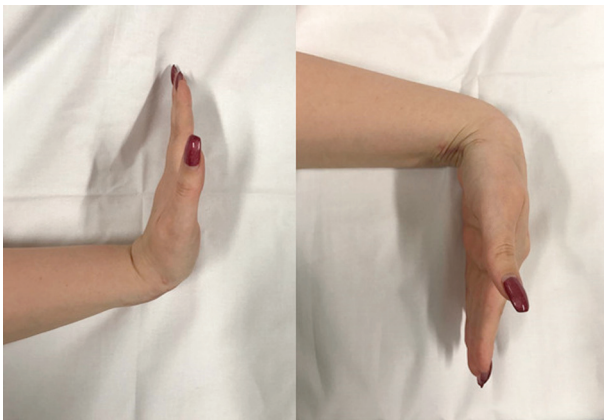

Figure 1. X-Ray and MRI images preoperative



**Figure 2.** X-Ray and MRI images at 3 months follow-up



**Figure 3.** Wrist range of motion at 3 months follow-up

results in few weeks but using conventional stainless-steel radial plate will not permit good images at MRI follow-up. The great advantage of Carbon-Peek plate fixation devices is that guarantees low impact on MRI images quality allowing MRI follow-up until T2-weighted signal intensity normalization was obtained.

Carbon-Peek devices yield several advantages over traditional orthopaedic materials including radiolucency and low interference on MRI scans (9). Moreover, Carbon-Peek implants can be designed with

tailored mechanical properties in order to give to the device appropriate strength, stiffness and toughness (10). Steinberg et al. reported similar biomechanical characteristics between Carbon-Peek and conventional devices (11).

In the literature there are many studies documenting good clinical performance of Carbon-Peek devices in spinal, orthopaedic and trauma surgery (6, 7, 12-15).

This case report suggests that Carbon-Peek plate fixation is a safe and advisable procedure after radius osteotomy for treatment of early stage Kienbock's disease due to its hypodensity on MRI scan.

**Patient Declaration Statement:** The authors certify that they have obtained all appropriate patient consent forms. In the form the patient has given her consent for her images and other clinical information to be reported in the journal. The patient understand that their names and initials will not be published and due efforts will be made to conceal their identity, but anonymity cannot be guaranteed.

**Conflict of interest:** Each author declares that he or she has no commercial associations (e.g. consultancies, stock ownership, equity interest, patent/licensing arrangement etc.) that might pose a conflict of interest in connection with the submitted article

## References

1. Beckenbaugh RD, Shives TC, Dobyns JH, et al. Kienbock's disease. The natural history of Kienbock's disease and consideration of lunate fractures. *Clin Orthop*, pp. 149. 98-106, 1980.
2. Nakamura R1, Imaeda T, Suzuki K, Miura T. Sports-related Kienböck's disease. *Am J Sports Med*, pp. 19(1):88-91, 1991 Jan-Feb.
3. Lichtman DM, Mack GR, MacDonald RI, Gunther SF, Wilson JN. Kienbock 's disease: The role of silicone replacement arthroplasty. *J Bone Joint Surg*, pp. 59:899-908, 1977.
4. Lichtman DM, Alexander AH, Mack GR, Gunther SF. Kienböck's disease--update on silicone replacement arthroplasty. *J Hand Surg Am*, pp. 7(4):343-7, 1982 Jul.
5. Bain GI, Smith ML, Watts AC. Arthroscopic Core Decompression of the Lunate in Early Stage Kienbock Disease of the Lunate. *Tech Hand Up Extrem Surg.*, pp. 15(1):66-9, 2011 Mar.
6. Perugia D, Guzzini M, Mazza D, Iorio C, Civitenga C, Ferretti A. Comparison between Carbon-PEEK volar locking plates and titanium volar locking plates in the treatment of distal radius fractures. *Injury*, pp. 48 Suppl 3:S24-S29, 2017 Oct.
7. Guzzini M, Lanzetti RM, Lupariello D, Morelli F, Princi G, Perugia D, Ferretti A. Comparison between carbon-peek plate and conventional stainless steal plate in ankle fractures. A prospective study of two years follow up. *Injury*, pp. 48(6):1249-1252, 2017 Jun.
8. Guzzini M, Lupariello D, Lanzetti RM, Mazza D, Ferretti A. Preliminary experience with triangular CarboFix "Piccolo" Distal Radius Plate in wrist fractures. Clinical and radiological results. *Acta Biomed*, vol. 90, pp. Supplement 1: 00-00, 2019.
9. Baidya KP, Ramakrishna S, Rahman M, Ritchie A. Quantitative radiographic analysis of fiber reinforced polymer composites. *J Biomater Appl*, p. 15:279-289, 2001.
10. Akay M, Aslan N. An Estimation of Fatigue Life for a Carbon Fibre/Poly Ether Ether Ketone Hip Joint Prosthesis. *Proc Inst Mech Eng*, p. 209:93-103, 1995.
11. Steinberg EL, Rath E, Shlaifer A, Chechik O, Maman E, Salai M. Carbon fiber reinforced PEEK Optima—a composite material biomechanical properties and wear/debris characteristics of CF-PEEK composites for orthopedic trauma implants. *J Mech Behav Biomed Mater*, p. 17:221-228, 2013.
12. Rhee PC, Shin AY. The rate of successful four-corner arthrodesis with a locking, dorsal circular polyether-etherketone (PEEK-Optima) plate. *J Hand Surg Eur*, p. 38:767-773, 2013.
13. Nakahara I, Takao M, Bandoh S, Bertollo N, Walsh WR, Sugano N. In vivo implant fixation of carbon fiber-reinforced PEEK hip prostheses in an ovine model. *J Orthop Res*, p. 31:485-492, 2013.
14. Kasliwal MK, O'Toole JE. Clinical experience using polyetheretherketone (PEEK) intervertebral structural cage for anterior cervical corpectomy and fusion. *J Clin Neurosci*, p. 21:217-220, 2014.
15. Tarallo L, Mugnai R, Adani R, Zambianchi F, Catani F. A new volar plate made of carbon-fiber-reinforced polyetheretherketon for distal radius fracture: analysis of 40 cases. *J Orthop Traumatol*, p. 15(4): 277-283, 2014.

Received: 1 October 2019

Accepted: 3 November 2019

Correspondence:

Dr. Giorgio Princi

Via di Grottarossa 1035 - 00196, Rome, Italy

Tel: +39 3929489166

E-mail: giorgioprinci@outlook.com