

## SHORT REPORT

# Arterial Embolisation of Paediatric Mesenteric Pseudoaneurysm Secondary to Blunt Abdominal Trauma

Chris Bent \*

Department of Radiology, Riverside University Health System, Moreno Valley, CA, USA

**Introduction:** Ruptured post-traumatic pseudoaneurysms of the superior mesenteric artery (SMA) are potentially life threatening and rarely reported in the paediatric population. The purpose of this report is to highlight the potential of endovascular treatment in this age group.

**Report:** A 16 year old male presented to the emergency department (ED) with seizure like activity. He was hypotensive and tachycardic with worsening abdominal distension. Past medical history was significant for a motor vehicle accident 16 days previously for which he was hospitalised and underwent emergency surgery. During the previous hospitalisation the patient was found to have liver and renal lacerations, haemoperitoneum, and small and large bowel serosal injuries. At surgery, haemostasis of liver lacerations was achieved, a traumatic anterior abdominal wall hernia was repaired, and short segment small and large bowel resections with primary anastomoses were performed. The patient was discharged uneventfully from the outside hospital eight days prior to presentation. Computed tomography in the ED at presentation identified haemorrhage from a ruptured 2 cm SMA pseudoaneurysm. This was successfully treated by transcatheter microcoil embolisation. The patient was discharged uneventfully and was without abdominal complaints at the 29 month clinic follow up.

**Discussion:** Post-traumatic SMA pseudoaneurysms in the paediatric population are rare; endovascular management may be a successful alternative or adjunct to surgical repair.

© 2022 The Author(s). Published by Elsevier Ltd on behalf of European Society for Vascular Surgery. This is an open access article under the CC BY-NC-ND license (<http://creativecommons.org/licenses/by-nc-nd/4.0/>).

Article history: Received 3 August 2021, Revised 26 October 2021, Accepted 17 January 2022,

**Keywords:** Embolisation, Mesenteric haemorrhage, Paediatric, Pseudoaneurysm, Superior mesenteric artery, Visceral artery

## INTRODUCTION

Superior mesenteric artery (SMA) pseudoaneurysms are rare in adults but even more so in the paediatric population. They are caused not only by traumatic injury to the artery wall, but can also occur secondary to connective tissue disorders, pancreatitis, infection, or prior surgery.<sup>1</sup> The condition is important as SMA pseudoaneurysms have a high risk of rupture and carry a significant mortality rate.<sup>1</sup> Open surgery has been the standard treatment of choice in the traumatic setting; however, advances in endovascular techniques, including stenting or embolisation, have made them alternative options in the adult population. To date, fewer than 10 cases of SMA aneurysms in children have been published, of which four cases were treated endovascularly.<sup>2</sup> None of those previously published occurred secondary to trauma. In this case report, a 16 year old male diagnosed with a post-

traumatic ruptured SMA pseudoaneurysm treated via percutaneous embolisation is presented.

## CASE REPORT

A 16 year old male presented with seizure like activity seen at home was brought to the emergency department (ED) by ambulance. In the ED, the patient was hypotensive and tachycardic with worsening abdominal distension. His past medical history was significant for a motor vehicle accident 16 days previously for which he was hospitalised at a different facility. Records from the prior hospitalisation indicated the patient had liver and left renal lacerations, haemoperitoneum, as well as serosal duodenal, jejunal, and sigmoid colon injuries. Computed tomography (CT) with intravenous (IV) contrast in the portal venous phase was reviewed and the findings were concordant with the listed injuries; no SMA pseudoaneurysm was seen. At surgery, haemostasis of the liver lacerations was achieved, a traumatic anterior abdominal wall hernia was repaired, and small bowel and short segment sigmoid resections with primary anastomoses were performed. The patient was discharged uneventfully from the outside hospital eight days prior to presentation.

\* Corresponding author. Department of Radiology, Riverside University Health System, Moreno Valley, CA 92555, USA.

E-mail address: [c.bent@ruhealth.org](mailto:c.bent@ruhealth.org) (Chris Bent).

2666-688X/© 2022 The Author(s). Published by Elsevier Ltd on behalf of European Society for Vascular Surgery. This is an open access article under the CC BY-NC-ND license (<http://creativecommons.org/licenses/by-nc-nd/4.0/>).

<https://doi.org/10.1016/j.ejvsf.2022.01.012>

ED presentation laboratory studies were significant for anaemia (haemoglobin 7.8 g/dL, decreased from 10.5 g/dL on discharge from prior hospitalisation). Head CT was negative. Abdominal and pelvic CT with IV contrast in the portal venous phase demonstrated moderate volume haemoperitoneum, a large mesenteric haematoma, and a ruptured 2 cm pseudoaneurysm arising from the proximal SMA (Figs. 1 and 2). After crystalloid and blood product resuscitation the patient's blood pressure stabilised, but he remained tachycardic. Owing to the recent extensive operations, with small and large bowel resections, and the origin of the pseudoaneurysm from the proximal SMA, the general surgery service consulted for potential endovascular options. Emergency angiography with embolisation was performed (Fig. 3). This entailed SMA selection with a 5 F C2 diagnostic catheter (Cook Medical, Bloomington, IN, USA) and selective catheterisation of the pseudoaneurysm with a Renegade STC microcatheter and Fathom 16 wire (Boston Scientific, Marlborough, MA, USA). The pseudoaneurysm was embolised with Concerto detachable microcoils (Medtronic, Fridley, MN, USA).

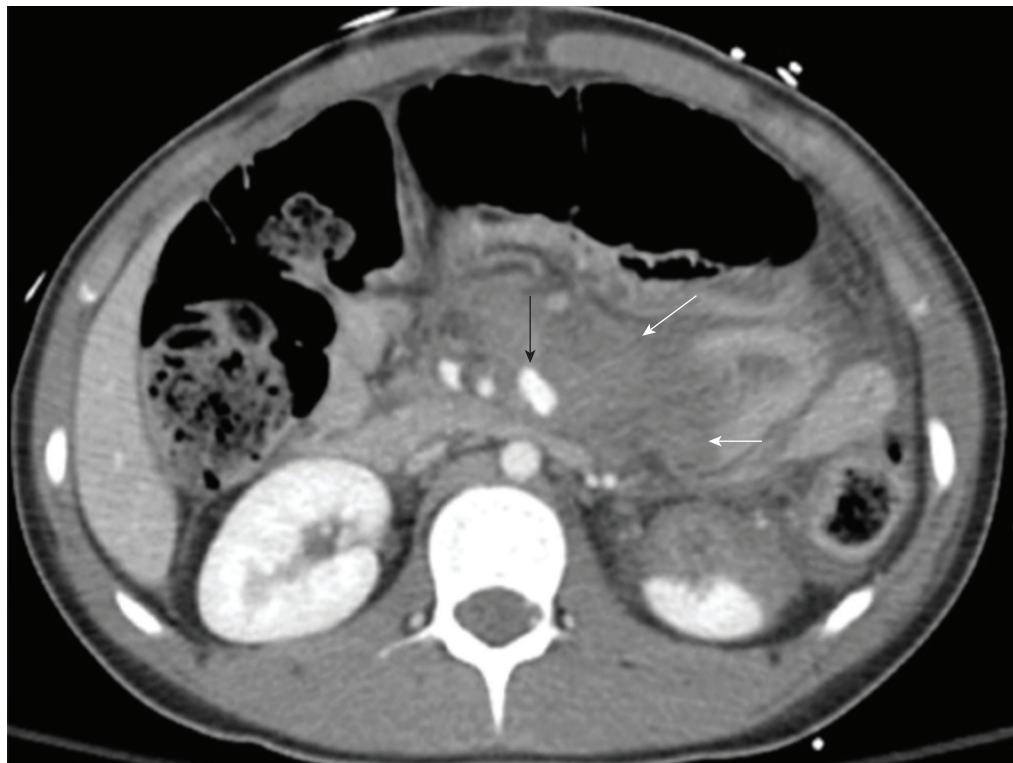
The patient was admitted to the intensive care unit but did not require repeat laparotomy. He improved over several days and subsequently underwent percutaneous drain placement to relieve pressure from large volume haemoperitoneum. He remained haemodynamically stable, with a stable haemoglobin level on analysis. The drains were

removed prior to discharge. Outpatient abdominal and pelvic CT with IV contrast in the portal venous phase performed four weeks later demonstrated the embolised pseudoaneurysm with stable coil pack, a widely patent SMA, and near complete resolution of the haemoperitoneum (Fig. 4). The patient had no abdominal complaints at the 29 month clinic follow up. In the absence of symptoms, no further CT imaging with its associated radiation in this paediatric patient has been performed.

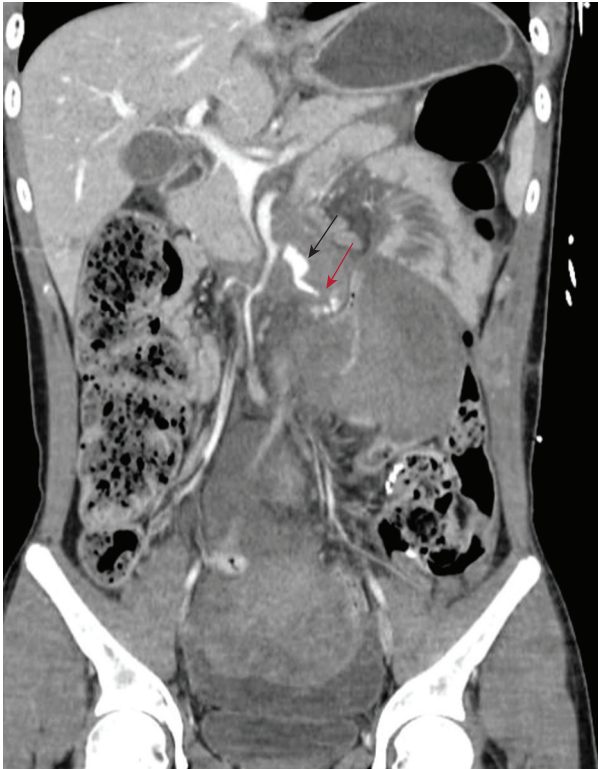## DISCUSSION

Mesenteric haemorrhage is a rare but potentially life threatening complication of blunt abdominal trauma. Blunt bowel and mesenteric injuries are identified in 1%–5% of adult blunt abdominal trauma patients undergoing laparotomy.<sup>3</sup> Haemodynamically stable and stabilised blunt trauma patients generally undergo CT scans on presentation. Although CT findings of mesenteric injuries may prove to be a diagnostic challenge, IV contrast extravasation in the mesentery with associated haematoma or haemoperitoneum is diagnostic of mesenteric vascular injury when present. Extravasation may occur with or without underlying pseudoaneurysm.<sup>4</sup>

The gold standard in the management of active mesenteric haemorrhage is open surgery, with options including surgical excision, ligation with or without concomitant bowel resection, grafting, or primary vascular repair.<sup>5–7</sup>



**Figure 1.** Axial intravenous contrast enhanced computed tomography at the level of the kidneys demonstrates a 2 cm focus of contrast consistent with superior mesenteric artery pseudoaneurysm (black arrow) surrounded by mesenteric haematoma (white arrows). Note left renal partial devascularisation is also seen.

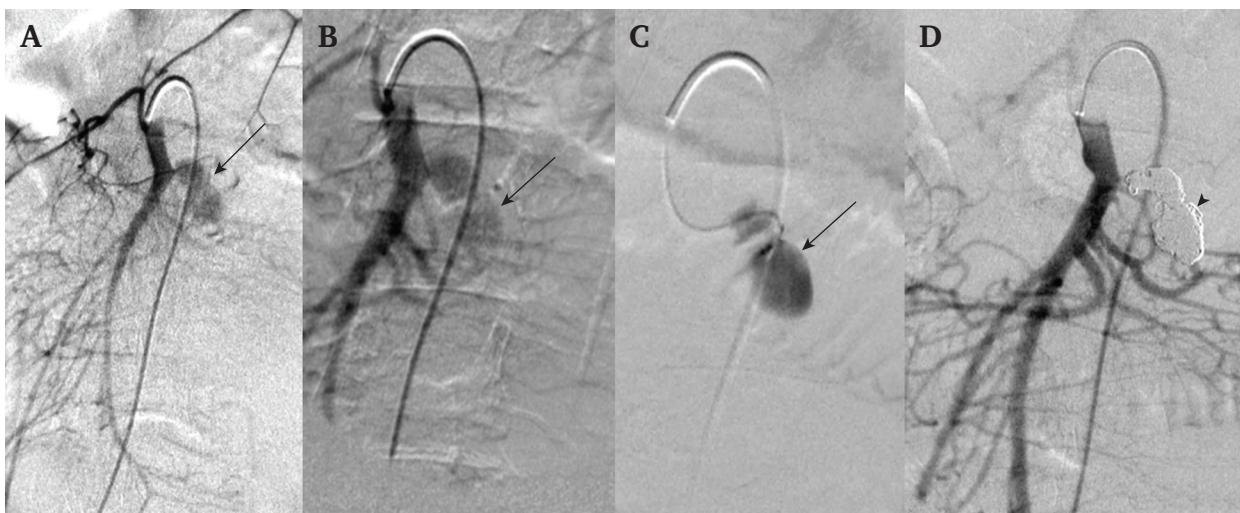


**Figure 2.** Coronal intravenous contrast enhanced computed tomography through the superior mesenteric artery (SMA) demonstrates pseudoaneurysm (black arrow) arising from the SMA at the origin of a jejunal branch artery. The red arrow highlights a focus of active extravasation from inferior margin pseudoaneurysm. Note the large surrounding mesenteric haematoma and pelvic haemoperitoneum.

Several reports exist in the adult literature regarding successful endovascular management by transcatheter embolisation or stent graft placement in the management of selected cases with low complication rates.<sup>8–10</sup> The goal of endovascular therapy is to stop the active haemorrhage, limit the formation of haematoma, and possibly avoid surgery.<sup>8–10</sup> The known complications of endovascular therapy include rebleeding, non-target embolisation or migration of embolic material, acute bowel ischaemia, chronic bowel stricture, and contrast related renal failure.

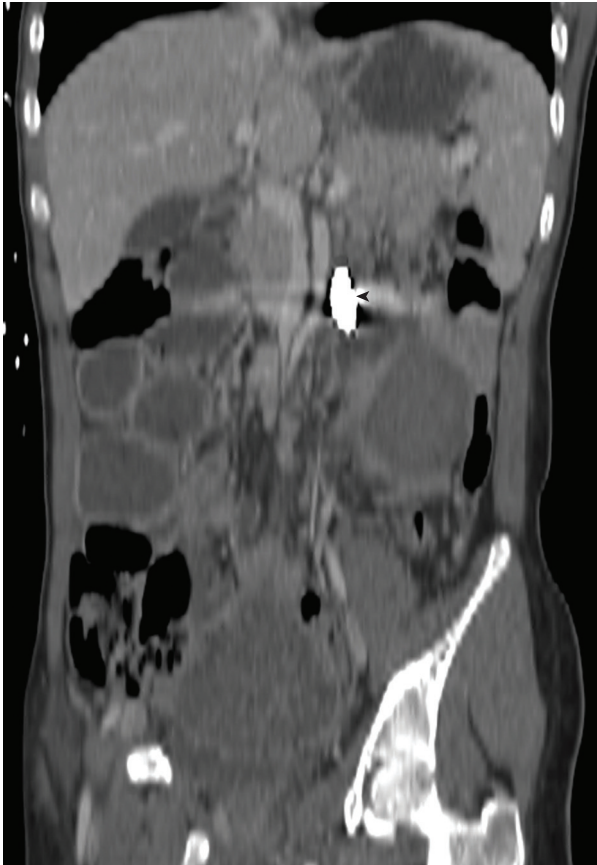The increasing number of endovascular reports in the adult literature suggests its growing use despite the absence of randomised trial data. However, there is even less published evidence in the paediatric trauma population. The closest analogous data in the paediatric literature is in the management of mesenteric aneurysms. Only nine SMA territory aneurysms have been published previously in the paediatric population (<18 years old).<sup>2</sup> None of these was secondary to trauma. Aetiologies included previous surgery, local or embolic infection, underlying connective tissue disorder, or idiopathic. Four of the nine presented with intra-abdominal haemorrhage and one with gastrointestinal bleeding. Five were managed surgically, two were treated by percutaneous embolisation, one by thrombin injection, and one died after unsuccessful embolisation.<sup>2</sup> The index case presented is believed to be the first reported delayed presentation of a ruptured paediatric SMA pseudoaneurysm secondary to blunt trauma treated successfully by embolisation.

In this case, stent graft placement and coil embolisation were both entertained, with the latter being chosen given the narrow pseudoaneurysm neck on angiography, secure



**Figure 3.** Four digital subtraction angiogram images from the endovascular embolisation procedure. (A) Initial and (B) magnification superior mesenteric artery (SMA) angiograms demonstrating 2 cm ovoid pseudoaneurysm (black arrow). (C) Pseudoaneurysm (black arrow) angiogram confirming microcatheter position within the pseudoaneurysm and absence of active extravasation. (D) Post-embolisation SMA angiogram demonstrating successful microcoil embolisation of pseudoaneurysm (black arrowhead) with patent SMA.





**Figure 4.** Coronal intravenous contrast enhanced computed tomography through the superior mesenteric artery (SMA) performed four weeks post-embolisation demonstrates embolised pseudoaneurysm coil pack (black arrowhead) and patent adjacent SMA.

sac microcatheterisation, and reduced risk of covering or excluding the origin of adjacent jejunal artery branches compromising bowel perfusion. Owing to the previous small and large bowel resections, there was concern that stent grafting could compromise perfusion to other segments of bowel as normal collateral pathways may have ligated. Stent grafts were available at time of the procedure should embolisation have been technically suboptimal.

### Conclusion

Although there is a lack of data regarding the management of post-traumatic SMA pseudoaneurysms in the paediatric

population due to their rarity, this case suggests that, in select patients, endovascular management can be a successful alternative or adjunct to open surgery.

### CONFLICT OF INTEREST

None.

### FUNDING

None.

### REFERENCES

- 1 Tulsyan N, Kashyap VS, Greenberg RK, Sarac TP, Clair DG, Pierce G. The endovascular management of visceral artery aneurysms and pseudoaneurysms. *J Vasc Surg* 2007;**45**:276–83.
- 2 Gander R, Pérez M, Bueno J, Lara A, Segarra A, Martínez MA, et al. Rupture of a superior mesenteric artery aneurysm in pediatric age: case report and literature review. *Cir Pediatr* 2015;**28**:40–4 (in Spanish).
- 3 Nolan BW, Gabram SG, Schwartz RJ, Jacobs LM. Mesenteric injury from blunt abdominal trauma. *Am Surg* 1995;**61**:501–6.
- 4 LeBedis CA, Anderson SW, Soto JA. CT imaging of blunt traumatic bowel and mesenteric injuries. *Radiol Clin North Am* 2012;**50**:123–36.
- 5 Fakhry SM, Brownstein M, Watts DD, Baker CC, Oller D. Relatively short diagnostic delays (<8 hours) produce morbidity and mortality in blunt small bowel injury: an analysis of time to operative intervention in 198 patients from a multicenter experience. *J Trauma* 2000;**48**:408–14.
- 6 Phillips B, Reiter S, Murray EP, McDonald D, Turco L, Cornell DL, et al. Trauma to the superior mesenteric artery and superior mesenteric vein: a narrative review of rare but lethal injuries. *World J Surg* 2018;**42**:713–26.
- 7 Pulli R, Dorigo W, Troisi N, Pratesi G, Innocenti AA, Pratesi C. Surgical treatment of visceral artery aneurysms: a 25-year experience. *J Vasc Surg* 2008;**48**:334–42.
- 8 Bertelli R, Fugazzola P, Zaghi C, Taioli A, Giampalma E, Agnoletti V, et al. Transcatheter arterial embolization in abdominal blunt trauma with active mesenteric bleeding: case series and review of literature. *Emerg Radiol* 2021;**28**:55–63.
- 9 Kim SK, Lee J, Duncan JR, Picus DD, Darcy MD, Sauk S. Endovascular treatment of superior mesenteric artery pseudoaneurysms using covered stents in six patients. *AJR Am J Roentgenol* 2014;**203**:432–8.
- 10 Barrionuevo P, Malas MB, Nejm B, Haddad A, Morrow A, Ponce O, et al. A systematic review and meta-analysis of the management of visceral artery aneurysms. *J Vasc Surg* 2019;**70**:1694–9.