

# Arthroscopic Patellar Osteochondral Transplantation



Jim C. Hsu, M.D., and James C. Linhoff, P.A.-C.

**Abstract:** The undersurface location of the patellar articular cartilage presents unique challenges to osteochondral defect treatment. Current osteochondral grafting techniques and instrumentation require arthrotomy and patellar eversion to access the defect with the necessary perpendicular trajectory. We describe an all-arthroscopic patellar osteochondral grafting technique, with transpatellar retrograde reaming for recipient socket creation and graft fixation, to treat focal patellar cartilage defects.

## Introduction

Given the significant forces imparted daily across the patellofemoral joint,<sup>1</sup> a full-thickness patellar cartilage defect can lead to knee pain, defect propagation, and arthritis. Spontaneous healing of full-thickness cartilage defect is rare and typically results in fibrocartilage, with inferior durability and function.<sup>2</sup>

Treatment methods for articular cartilage defects include microfracture, osteochondral grafting, and autologous chondrocyte transplantation.<sup>2</sup> Osteochondral grafting has the advantage of being a one-stage treatment that instantly resurfaces the defect with mature hyaline cartilage already attached to the bone.

Arthroscopic techniques for osteochondral graft harvest and implantation are well established as treatment of cartilage defects in most areas of the knee.<sup>3</sup> However, osteochondral grafting to the patella is still performed with an open approach, with arthrotomy and patellar eversion, to provide the necessary perpendicular access.<sup>4,5</sup>

All-inside reaming of femoral and tibial tunnels with adjustable-diameter retrograde reamers is an increasingly common component of arthroscopic ligament reconstructions and other procedures.<sup>6</sup> By incorporating the retrograde reaming technique, it is possible to bypass the access limitation to the patellar undersurface

by using the osteochondral grafting technique we describe below.

## Surgical Technique

### Indications

Arthroscopic patellar osteochondral grafting is indicated in patients with symptomatic, small- to moderate-size, focal high-grade or full-thickness articular cartilage defects of the patella, for whom conservative treatment has failed.

### Patient Evaluation

Patients typically report anterior knee pain exacerbated by patellofemoral compartment-loading activities. Patellar instability is an important element in evaluation, treatment discussion and planning, to consider concurrent procedures addressing concerns beyond the articular cartilage defect.

### Imaging

Preoperative X-rays and MRI are evaluated (Fig 1). Location, orientation, and size of the cartilage defect and other intra-articular abnormalities are noted. Templating and measurement of the perpendicular distance from defect to anterior patellar cortex on sagittal and axial series can help visualize a perpendicular trajectory to the defect and determine available distance for recipient socket and anchor fixation. A defect significantly greater than 12-mm diameter may require open osteochondral allograft, due to limits in both the currently available osteochondral autograft harvester and retrograde reamer dimensions.

### Patient Positioning and Initial Arthroscopic Assessment

The patient is placed in a supine, standard arthroscopic setup. Anterolateral and anteromedial portals are

*The Polyclinic, Seattle, Washington, U.S.A. (J.C.H., J.C.L.).  
Full ICMJE author disclosure forms are available for this article online, as supplementary material.*

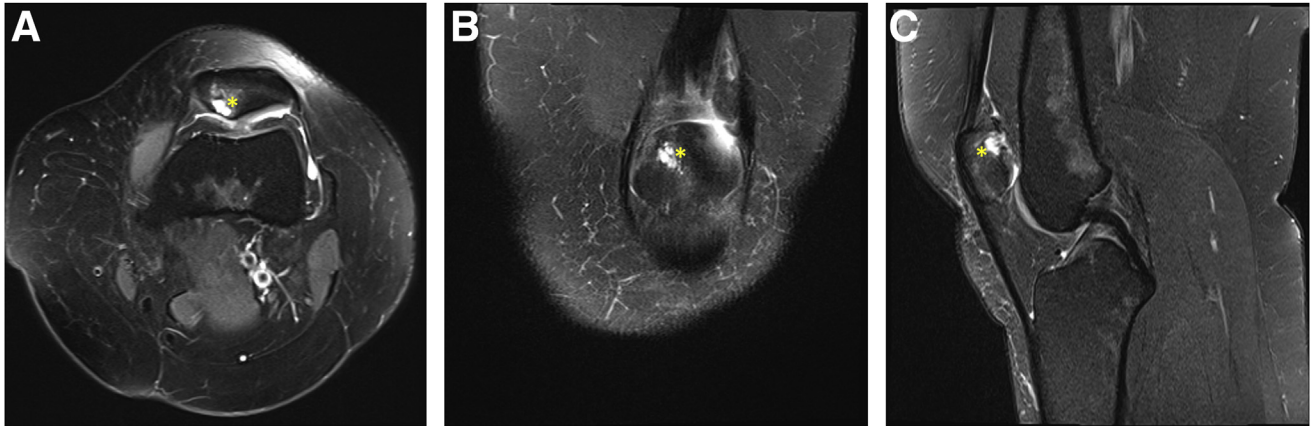
*Received October 25, 2021; accepted November 16, 2021.*

*Address correspondence to Jim C. Hsu, M.D., The Polyclinic, 904 7th Ave., 4th Floor, Seattle, WA, 98104, U.S.A. E-mail: [hsujim@gmail.com](mailto:hsujim@gmail.com)*

*© 2021 THE AUTHORS. Published by Elsevier Inc. on behalf of the Arthroscopy Association of North America. This is an open access article under the CC BY-NC-ND license (<http://creativecommons.org/licenses/by-nc-nd/4.0/>).*

*2212-6287/211520*

*<https://doi.org/10.1016/j.eats.2021.11.017>*



**Fig 1.** Preoperative magnetic resonance imaging, left knee. Chondral defect and subchondral bony changes (asterisk) in the superomedial patellar undersurface are shown on axial (A), coronal (B), and sagittal (C) views.

established. Standard arthroscopy is performed, and any other pathology is addressed.

The patellar cartilage defect is assessed (Fig 2A). A measurement probe is used to determine the defect diameter and its center point (Fig 2C). A 70° lens may help visualization.

Our preferred osteochondral autograft harvesters are available in 6-, 8-, 10-, and 12-mm diameters (Arthrex, Naples, FL). The defect diameter is rounded up to one of the diameters: this is the graft diameter.

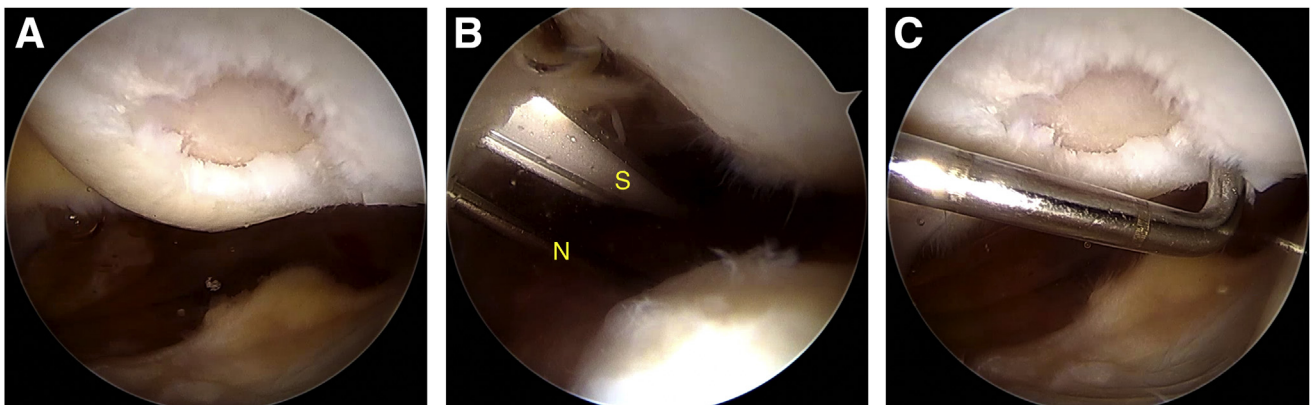
#### **Osteochondral Autograft Harvest and Preparation, or Allograft Preparation**

If the autograft option is chosen, an osteochondral graft harvester matching the graft diameter is used to harvest an osteochondral autograft in standard fashion, from a location based on surgeon preference and

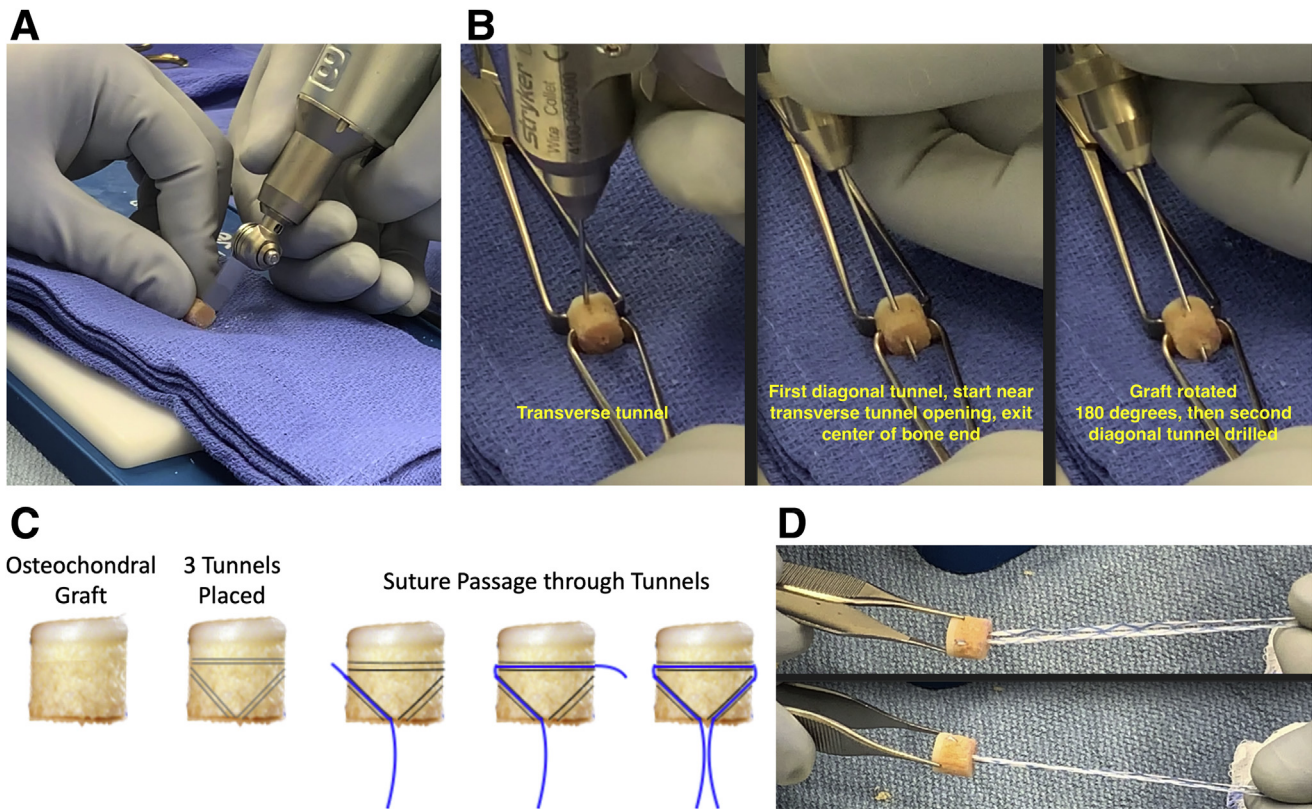
patient-specific factors. The graft is partially extruded from the harvester until 10-mm length remains within the cylinder. A sagittal saw is used to cut the extruded bone flush with cylinder opening, resulting in a 10-mm graft height.

If the allograft option is chosen, grafts up to 12-mm diameter can be used. The allograft is trimmed with a sagittal saw to achieve a total height of 10 mm (Fig 3A), copiously pressure-lavaged for 10-20 minutes, and then prepared following the same steps below.

A .045" K-wire is drilled across the bone about 2 mm below the subchondral surface (Fig 3B). Two more oblique passages are made, starting just below the openings of the transverse tunnel and exiting near the center of the bone end, with the three tunnels approximating a triangle. A 1.4-mm reinforced tape suture (SutureTape, Arthrex) is passed through the



**Fig 2.** Arthroscopic evaluation of articular cartilage defect. The patient is in the supine position. Arthroscopic views of the fully extended left knee, from the anteromedial portal. (A) Full-thickness focal articular cartilage defect in the superomedial patellar undersurface. (B) A superomedial portal is established using a spinal needle (N) and scalpel (S), aiming to make a portal that will allow for the tip of the drill guide to sit flush with the articular surface of the affected area. (C) The defect is measured using a probe with calibration marks (distance = 5 mm), and the center of the defect area is determined.



**Fig 3.** Osteochondral graft preparation. (A) Whether allograft sourced from a tissue bank or autograft is harvested at this time, the osteochondral graft, of suitable diameter based on defect measurement, is trimmed to a length of 10 mm. (B) Using a small, .045" K-wire, three passages in a triangular pattern are made: one transverse tunnel close to articular surface, then two diagonal tunnels starting just distal to the openings of the first and heading distally and exiting the bone at the center of the bone end. (C) Diagram showing the osteochondral graft, three tunnels, and the stepwise passage of a reinforced suture (SutureTape, Arthrex, Naples, FL) through the three tunnels, with the free suture ends exiting at the center of the bone end. (D) Appearance of the final graft/suture construct.

tunnels, with the two free ends exiting at the center of the bone end (Fig 3, C and D). The tunnel configuration permits secure capture and collinear pull on the graft, and it avoids suture bowstringing that can impede graft seating.

### Transpatellar Retrograde Reaming, and Recipient Socket Preparation

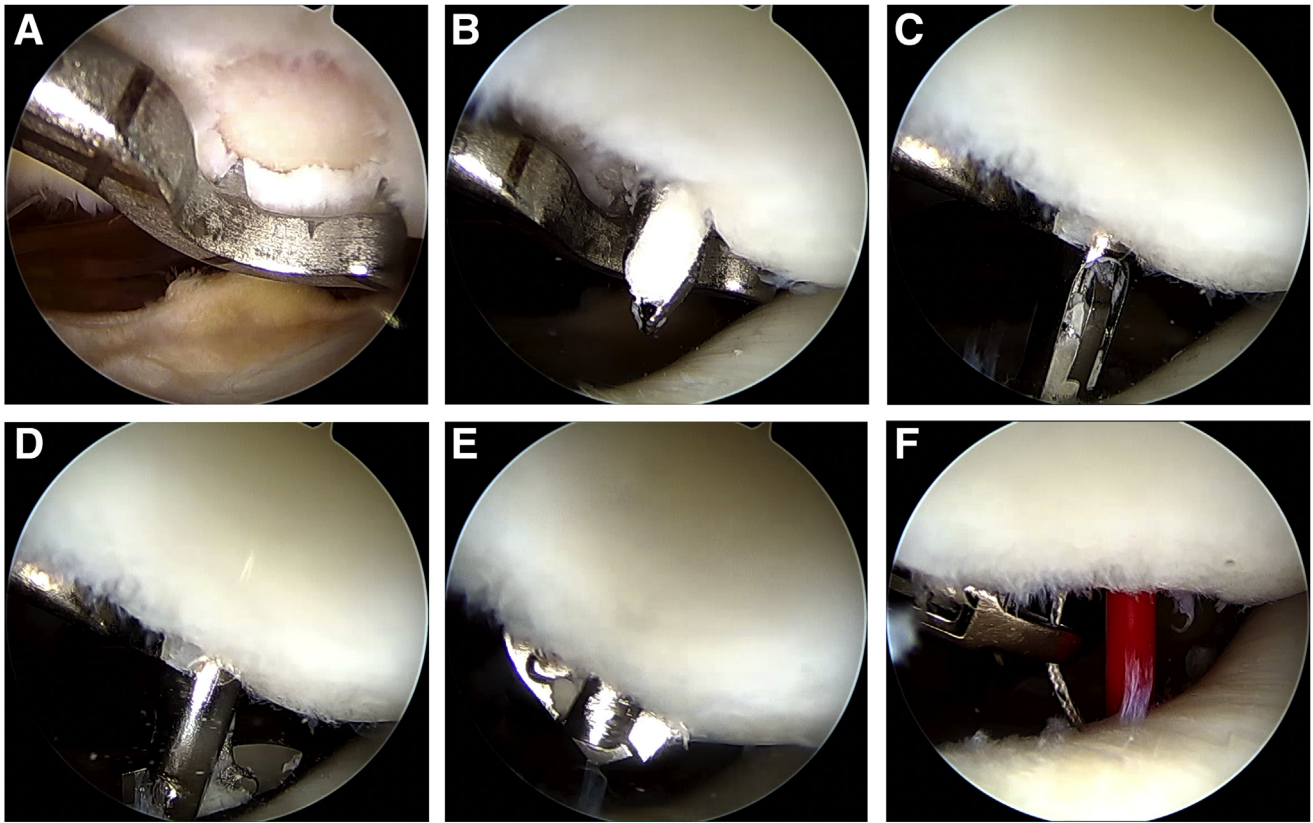
The tip of an ACL drill guide set at 90° is placed through the portal affording the best access, then flush on the patellar undersurface and centered on the defect (Fig 4A). Through a small prepatellar incision, the drill sleeve is advanced onto the anterior patellar cortex. A smaller diameter guide wire is passed first to ensure placement (Fig 4B), then an adjustable-diameter retrograde reamer (FlipCutter III, Arthrex) is advanced through the patella at a perpendicular trajectory to the center of the defect (Fig 4C). Once in the joint, the reamer tip is expanded to the graft diameter (Fig 4D). Next, retrograde reaming is performed to

achieve a recipient socket with 10-mm total depth from articular cartilage surface to the base, with incremental reaming and frequent checks to ensure the socket depth precisely matches the 10-mm graft height (Fig 4E). The tip is closed, and the reamer is removed. The socket is debrided and then visualized to ensure debris is fully cleared.

A passing loop suture (FiberStick, Arthrex) is placed outside-in through the reamer passageway, into the joint space, and then retrieved through the portal that affords the easiest graft passage (Fig 4F), and then used to shuttle the graft traction suture into the portal, recipient socket, and out the anterior patella (Fig 5A).

### Osteochondral Graft Placement and Fixation

The osteochondral graft is introduced into the joint with a clamp, bone side first (Fig 5B). The graft is provisionally seated into the recipient socket, then



**Fig 4.** Retrograde reaming of patellar recipient socket. The patient is in the supine position. Arthroscopic views of the fully extended left knee, from the anteromedial portal. (A) With drill guide set to 90°, the guide tip is placed flat on the defect, while the drill sheath is placed on the anterior cortex of the patella through a small prepatellar incision, adjusted for a perpendicular trajectory to the center of the defect. (B) The pathway is predrilled with a 2.4-mm guide wire. (C) Once the guide wire trajectory is confirmed satisfactory, the wire is removed, and the retrograde adjustable diameter reamer (FlipCutter III, Arthrex) is passed into the joint. (D) The reamer is dialed to the desired recipient socket diameter, matching the graft diameter. (E) Retrograde reaming is done carefully and incrementally, to ensure accurate reaming of a recipient socket with 10-mm depth. (F) Once the reamer is retracted fully and removed, a loop passing suture (FiberStick, Arthrex) is passed into the joint through the same transpatellar passageway and then retrieved from the joint through a portal.

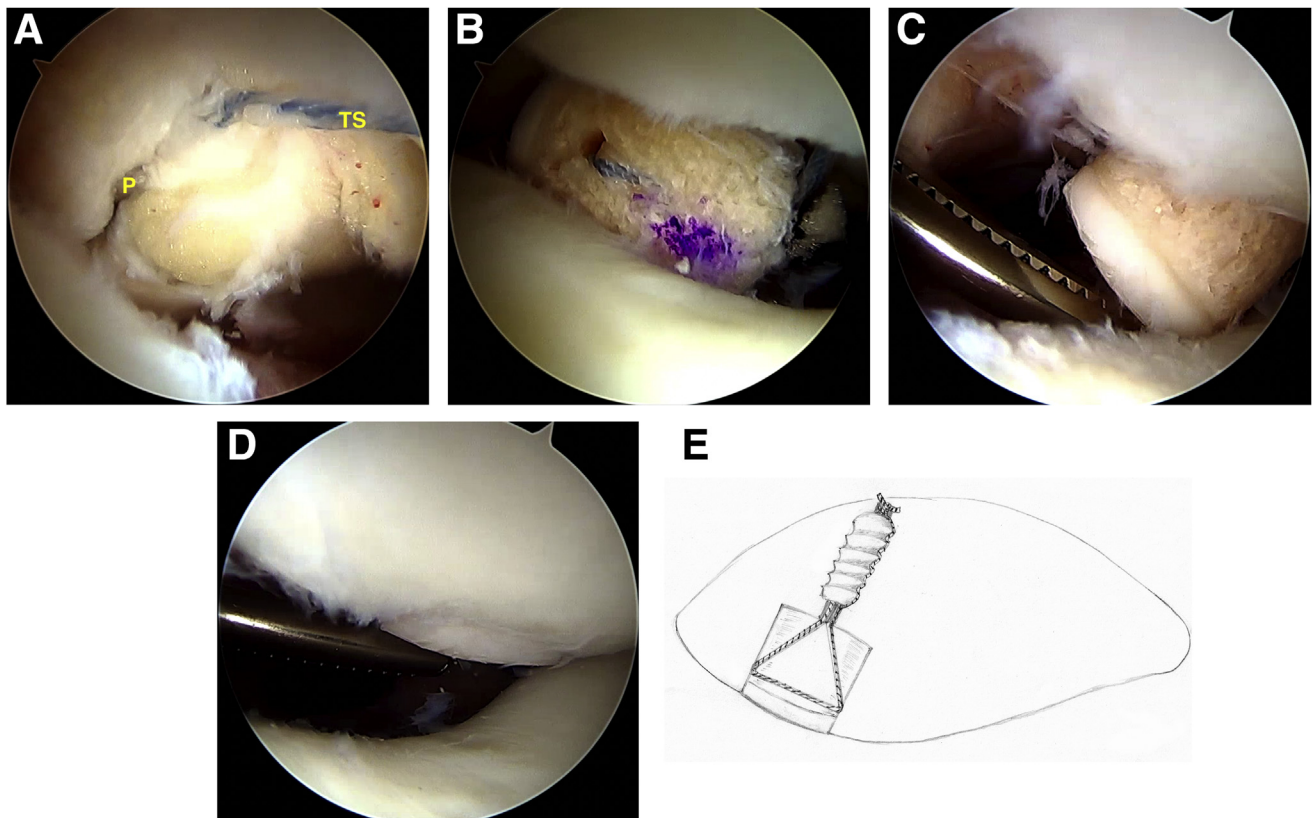
further inserted until flush with the surface, with continued upward tension on the traction suture plus pushing up with a smooth and flat instrument such as a Freer or Key elevator (Fig 5, C and D).

Once the graft placement is satisfactory, one limb of the traction suture is threaded through a short 4 mm × 10 mm tenodesis screw (Arthrex) and cannulated screwdriver. Both suture limbs are held in tension to hold the graft securely in the socket as the screw is inserted into the reamer passageway, until slightly countersunk. The suture limbs are tied over the screw and trimmed to minimize prominence on anterior patellar surface once final checks confirm graft stability (Fig 5E).

The surgical procedure is demonstrated in [Video 1](#). Surgical pearls/pitfalls are summarized in [Table 1](#). Advantages and disadvantage are listed in [Table 2](#).

### Rehabilitation

Weight bearing as tolerated is allowed with the knee in full extension, with an immobilizer or hinged brace. Passive motion can start immediately, with use of a constant passive motion (CPM) device, starting at 0-40°, advancing gradually according to tolerance to about 90°. After 3 weeks, the patient further advances range of motion and isometric strengthening as tolerated, but squatting or crouching is avoided. At 6 weeks, the patient can work to improve strength and



**Fig 5.** Placement and fixation of the osteochondral graft. The patient is in the supine position. Arthroscopic views of the fully extended left knee, from the anteromedial portal. (A) The loop passing suture through the recipient socket is used to shuttle the traction suture (TS) of the graft into the knee joint through the superomedial portal (P), into the recipient socket, and then out through the patella anteriorly. (B) The graft is introduced into the joint, bone end first. (C and D) Using both the traction suture to pull and the clamp to push and direct the graft, the osteochondral graft is seated into the recipient socket. (E) Diagram demonstrating the final fixation construct: the traction suture is tensioned to secure the graft into the socket, then one limb of the suture is passed through a tenodesis screw (4 mm × 10 mm Tenodesis Screw; Arthrex) and the other limb outside. The screw is advanced fully into the bone, while the suture limbs are held under tension, and then the limbs are tied over the screw.

neuromuscular training, including gradual introduction of squatting and crouching via leg presses starting with partial body weight. At 3 months postoperatively, dynamic activities are gradually introduced, with the goal of returning to running by 4 to 6 months postoperatively.

### Discussion

Osteochondral grafting is routinely performed arthroscopically to treat cartilage defects throughout most areas of the knee. However, for the patella, grafting is still performed via an open approach, since arthrotomy and patellar eversion are necessary for a perpendicular approach to the articular surface with current osteochondral grafting instrumentation.<sup>7,8,9</sup>

With retrograde transpatellar reaming and fixation via suture and screw, we demonstrate it is possible to arthroscopically achieve perpendicular access to the patellar undersurface, ream the recipient socket, and insert and secure the graft.

The main advantage of our technique is the decreased morbidity of the arthroscopic approach. The open approach to the patellar undersurface is not without drawbacks. With a more extensile incision, dissection, and arthrotomy, patellar eversion can induce transient patellar ischemia.<sup>10,11</sup> Medial parapatellar arthrotomy further disrupts medial blood supply and can lead to altered patellar kinematics, vastus medialis weakness, patellar instability, knee stiffness, and pain.<sup>12</sup> Medial arthrotomy also may conflict with common concurrent procedures, such as medial patellofemoral ligament (MPFL) reconstruction, since it transects and potentially weakens the very anatomic structures the MPFL reconstruction is aiming to reinforce.

The main limitation of our technique, and all other cartilage-restorative techniques, is injury selection. While cartilage lesions in the patella are common, many are diffuse and degenerative in nature. For such conditions, focal osteochondral grafting is unlikely to be clinically beneficial.

**Table 1.** Surgical Pearls and Pitfalls**Operating table setup**

- Consider performing the procedure on a flat operating table with a side post, rather than lowering the foot of the table: this provides the best security and obviates positioning assistance for key steps of the procedure, including patellar reaming, graft passage, and osteochondral autograft harvest from most locations, which are all performed with the knee fully extended.

**Graft/recipient socket diameter considerations**

- In our technique, the graft and recipient socket have matching diameters, to permit a snug yet smooth arthroscopic graft insertion without impaction. The graft is secured with reinforced sutures and a tenodesis screw, and it does not rely solely on a pressed-fit through side wall contact for stability, as in standard osteochondral grafting.
- A graft sizing block can help confirm graft diameter and ensure ease of graft insertion.

**Osteochondral autograft harvesting instrumentation considerations**

- Osteochondral graft harvesting instrumentation systems typically harvest a graft with a diameter .5 mm greater than the recipient site for a press-fit fixation. It is important to know the actual diameter of the harvester of the surgeon's preferred system, so that the recipient socket is not unintentionally small, creating challenges for arthroscopic graft insertion.
- Note that many retrograde variable-diameter reamers can be adjusted in .5-mm increments and can accommodate harvesters that are .5 mm oversized.

**Drill guide instrumentation**

- Not all standard drill guides allow for a 90° drilling angle setting; thus, it is important to confirm one is available preoperatively. Also, a drill guide with a flat rather than a pointed tip is preferred, so it can sit flat on the target surface and help determine the perpendicular drill trajectory to the center of the defect area.
- We use a marking hook drill guide attachment designed for pediatric knee ligament reconstruction that allows for a 90° setting and has a flat, semicircular tip (Arthrex, Naples, FL, part no. AR-1510FRS or AR-1510FLS).

**Graft insertion and handling**

- Care is taken primarily to push the graft into the joint with a clamp and into the socket with a flat instrument, and to secondarily pull on the suture, to avoid graft bone damage. A flexible cannula (PassPort, Arthrex) may facilitate graft introduction.
- If the graft needs to be removed from the socket before final fixation for any reason, such as retrimming of the bone portion to enhance fit, it can be carefully pushed back into the joint using a blunt tip wire up to 3.5-mm diameter or an arthroscopic knot pusher from outside in through the reamer tunnel. Once retrieved out of the joint, with traction suture still through the patella, the graft can be processed, and graft placement is repeated.

A more technical limitation stems from the currently available instrumentation: the maximum diameter for both osteochondral harvesters and retrograde reamers is 12 mm. Future retrograde reamers larger than 12 mm in diameter may allow treatment of larger osteochondral defects.

Finally, as with any surgical technique, larger, longitudinal studies will be needed to determine the long-term outcome.

In summary, we report an all-arthroscopic osteochondral grafting technique to treat symptomatic, focal patellar undersurface cartilage defects. Our arthroscopic osteochondral grafting technique is safe, uses standard instrumentation, and offers a minimally invasive alternative to current open techniques. We hope our report will generate interest and spur further refinement.

**Table 2.** Advantages and Disadvantages**Advantages**

- Decreased general morbidity through arthroscopic approach
- Avoidance of medial arthrotomy and parapatellar soft tissue disruption
- Avoidance of patellar eversion and perfusion interruption
- Utilizes common instrumentation and implants

**Disadvantages**

- Primarily related to patient/injury selection:
  - Technique suitable for treatment of focal articular cartilage defects, not diffuse, often degenerative cartilage lesions
  - Maximum treatable defect size is 12 mm in diameter, limited by maximum reaming diameter of currently available retrograde reamers

**References**

1. Huberti HH, Hayes WC. Patellofemoral contact pressures: The influence of q-angle and tendofemoral contact. *J Bone Joint Surg Am* 1984;66:715-724.
2. Karuppall R. Current concepts in the articular cartilage repair and regeneration. *J Orthop* 2017;14:A1-A3.
3. Patil S, Tapasvi SR. Osteochondral autografts. *Curr Rev Musculoskelet Med* 2015;8:423-428.
4. Lin KM, Wang D, Burge AJ, Warner T, Jones KJ, Williams RJ 3rd. Osteochondral allograft transplant of the patella using femoral condylar allografts: magnetic resonance imaging and clinical outcomes at minimum 2-year follow-up. *Orthop J Sports Med* 2020;8:2325967120960088.
5. Figueroa D, Calvo Rodriguez R, Donoso R, Espinoza J, Vaisman A, Yañez C. High-grade patellar chondral defects: promising results from management with osteochondral autografts. *Orthop J Sports Med* 2020;8:2325967120933138.
6. Robin BN, Jani SS, Marvil SC, Reid JB, Schillhammer CK, Lubowitz JH. Advantages and disadvantages of transtibial, anteromedial portal, and outside-in femoral tunnel drilling in single-bundle anterior cruciate ligament reconstruction: A systematic review. *Arthroscopy* 2015;31:1412-1417.
7. Donoso R, Figueroa D, Espinoza J, Yañez C, Saavedra J. Osteochondral autologous transplantation for treating patellar high-grade chondral defects: A systematic review. *Orthop J Sports Med* 2019;7:2325967119876618.
8. Brophy RH, Wojahn RD, Lamplot JD. Cartilage restoration techniques for the patellofemoral joint. *J Am Acad Orthop Surg* 2017;25:321-329.
9. Cohen M, Amaro JT, Fernandes dSCF, et al. Osteochondral autologous transplantation for treating chondral lesions in the patella. *Rev Bras Ortop* 2015;47:348-353.

10. Hasegawa M, Kawamura G, Wakabayashi H, Sudo A, Uchida A. Changes to patellar blood flow after minimally invasive total knee arthroplasty. *Knee Surg Sports Traumatol Arthrosc* 2009;17:1195-1198.
11. Zan P, Wu Z, Yu X, Fan L, Xu T, Li G. The effect of patella eversion on clinical outcome measures in simultaneous bilateral total knee arthroplasty: A prospective randomized controlled trial. *J Arthroplasty* 2016;31:637-640.
12. Nam D, Abdel MP, Cross MB, et al. The management of extensor mechanism complications in total knee arthroplasty. *J Bone Joint Surg Am* 2014;96:e47.