

# Dedifferentiated Endometrioid Carcinomas with Neuroendocrine Differentiation: A Clinicopathological and Immunohistochemical Study of Three Cases

This article was published in the following Dove Press journal:  
*Cancer Management and Research*

Feng Zhou<sup>1,2</sup>  
Xiaofei Zhang<sup>1</sup>  
Hao Chen<sup>2</sup>  
Wenxin Zheng<sup>2-4</sup>

<sup>1</sup>Department of Pathology, Women's Hospital, School of Medicine, Zhejiang University, Hangzhou, Zhejiang Province, People's Republic of China; <sup>2</sup>Department of Pathology, University of Texas Southwestern Medical Center, Dallas, TX, USA; <sup>3</sup>Department of Obstetrics and Gynecology, University of Texas Southwestern Medical Center, Dallas, TX, USA; <sup>4</sup>Harold C Simmons Comprehensive Cancer Center at University of Texas Southwestern Medical Center, Dallas, TX, USA

**Purpose:** To investigate the relationship between dedifferentiated endometrioid carcinomas with neuroendocrine differentiation and mismatch repair deficiency.

**Patients and Methods:** The clinicopathological records and samples of three patients were retrieved from the Pathology Department of Zhejiang University's School of Medicine Women's Hospital.

**Results:** The tumors comprised one dominant poorly differentiated component (60–90% of the neoplasm volume) and one well-differentiated glandular component. The poorly differentiated component showed solid sheets with organoid growth patterns and insular, trabecular and rosette/pseudorosette patterns. Large polygonal cells, vesicular nuclei, prominent nucleoli, and abundant eosinophilic cytoplasm were observed in the poorly differentiated area. All three cases were diffusely positive for p16 and for at least two of three neuroendocrine markers (chromogranin, synaptophysin, neural cell adhesion molecule (CD56)) in >10% of cancer cells. Loss of MMR protein expression was found in two patients: MLH1 and PSM2 in patient 2 and MSH2 and MSH 6 in patient 3. Abnormal P53 and SMARCB1 (INI1) expression was noted in patient 3. All three patients underwent total abdominal hysterectomy and bilateral salpingo-oophorectomy, and two received postoperative chemotherapy and/or radiation therapy. The patients survived disease-free for 60, 26 and 15 months, respectively.

**Conclusion:** Dedifferentiated endometrioid carcinomas with neuroendocrine differentiation may be associated with mismatch repair deficiency and have an improved prognosis.

**Keywords:** dedifferentiated endometrioid carcinoma, large cell neuroendocrine carcinoma, MMR deficiency

## Introduction

As recommended by the World Health Organization, the terminology for gastroentero-pancreatic neuroendocrine tumors (NETs) is applicable to neuroendocrine carcinoma (NEC) arising from the female genital tract.<sup>1</sup> NETs are classified as poorly differentiated or well-differentiated NETs based on the tumor nuclear grade. Cases of low-grade NET and high-grade NEC are rare.<sup>2,3</sup> Small cell NEC or large cell NEC (LCNEC) exhibits aggressive behavior and is associated with a poor prognosis.<sup>4</sup> Approximately 100 cases of NEC of endometrial origin have been reported,<sup>4</sup> and recently a relationship between endometrial NEC and abnormal

Correspondence: Feng Zhou  
Departments of Pathology, Women's Hospital, School of Medicine, Zhejiang University, Hangzhou, Zhejiang Province, People's Republic of China  
Tel +86-571-89991702  
Email fungchew@zju.edu.cn

expression of mismatch repair (MMR) proteins was described.<sup>5-7</sup> Here, we identified three cases of dedifferentiated endometrioid carcinomas with neuroendocrine differentiation and found that two cases were associated with MMR deficiency.

## Patients and Methods

### Tissue Samples

Clinicopathological samples and records for our three study subjects were retrieved from the Pathology Department at the Zhejiang University School of Medicine Women's Hospital. Inclusion was limited to cases from the past 5 years. The World Health Organization diagnostic criteria for LCNEC were used as follows: 1) large cells with prominent nucleoli and abundant cytoplasm, 2) a neuroendocrine growth pattern (organoid, insular, trabecular, rosette/pseudo-rosette), and 3) >10% tumor cells reactive to at least one NET marker including chromogranin, synaptophysin and CD56.<sup>1</sup> Hematoxylin and eosin and immunohistochemistry (IHC) slides were reviewed by three gynecological pathologists (FZ, XZ and WZ) until a consensus was reached. All patients provided informed consent to participate in this study and for publication of the data. This study was approved by the hospital ethics committee.

### IHC Analysis

Paraffin sections (4  $\mu$ m) were stained with a panel of antibodies using the 2-step Envision method according to the manufacturer's instructions and visualized using 3-diaminobenzidine tetrachloride (Sigma, St Louis, MO) as described previously.<sup>8</sup> The sources and dilutions of the antibodies used in this study are detailed in Table 1. All primary antibodies and the detection kit were obtained from Dako Corporation (Glostrup, Denmark). The negative control entailed the use of the same non-specific IgG but omitting the primary antibody. The IHC staining was scored as follows: negative (no cells stained), focally positive ( $\leq$ 10% cells stained), patchy positive (11–49% cells stained) and diffusely positive ( $\geq$ 50% cells stained).

## Results

### Clinical Findings

The main clinical findings are summarized in Table 2. Briefly, the median age was 56 years (range, 54–59 years), and all patients presented with postmenopausal or perimenopausal vaginal bleeding/discharge. All patients

**Table 1** Antibody Clones, Sources, and Dilutions

Antibody	Clones	Dilutions	Sources
p16	16P04/JC2	1:100	Zeta
p53	DO-7	1:600	Thermo
ER	1D5	1:300	Thermo
PR	1A6	1:500	Thermo
Chromogranin	SP12	1:500	Thermo
Synaptophysin	SP11	1:200	Thermo
CD56	123C3	1:400	Thermo
MLH1	ES05	1:50	Leica
PSM2	A16-4	1:100	Epitomics
MSH2	25D12	1:100	Leica
MSH6	EP49	1:400	Epitomics
SMARCB1 (INI1)	25/BAF47	1:100	BD Biosciences
SMARCA4 (BRG1)	EPR3912	1:50	Abcam
ARID1A	HPA005456	1:400	Sigma
Ki67	MIB-1	1:400	Dako

**Abbreviations:** ER, estrogen receptor; PR, progesterone receptor; CD56, neural cell adhesion molecule.

denied a family history of endometrial or colon cancer. No other history of malignancy was identified. The diagnosis was determined by endometrial biopsy, followed by total abdominal hysterectomy with bilateral salpingo-oophorectomy and staging procedures. The FIGO stage at diagnosis was IIB in case 1, IB in case 2, and IIIC2 in case 3. Case 1 and case 3 were treated with both chemotherapy and radiation therapy postoperatively, while case 2 received adjuvant radiation therapy only.

### Pathological Findings

The pathological findings are presented in Table 2. Macroscopically, all tumors formed large, polypoid, intracavitary masses ranging from 3 to 4.5 cm in size. The tumor in case 1 was located in the lower uterine segment. The tumors of case 2 and 3 were largely located in the uterine fundus. The cut surface was soft, fleshy and necrotic. Microscopically, the tumors showed a dominant poorly differentiated component constituting 60–90% of the total tumor volume. A small component of well-differentiated endometrioid carcinoma with focal areas of squamous differentiation was identified in case 3. Increased numbers of tumor-infiltrating lymphocytes at the tumor invasion front or periphery were found in all three cases (Figure 1A). Extensive geographic necrosis was present. The poorly differentiated components mostly showed solid sheets, organoid growth patterns, and insular, trabecular and rosette/pseudorosette patterns in approximately 30% of cancerous areas (Figure 1B–D). The poorly

**Table 2** Clinical Findings and Pathological Results of the Tumours

	Case 1	Case 2	Case 3
Age (yr)	54	59	55
History of pregnancy	Gravidity 2, Parity 2	Gravidity 2, Parity 2	Gravidity 2, Parity 1
History of cancer	NO	NO	NO
Familial history of cancer	NO	NO	NO
Clinical presentation	Irregular menstruation	Postmenopausal vaginal bleeding	Postmenopausal vaginal bleeding and discharge
Serum tumor biomarkers	Normal CEA, CA125 and CA153	Normal CEA, CA125 and CA153	CA125:50.1 U/mL, Normal CEA and CA153
Imaging findings	A mass in the LUS and cervical canal	A mass in the uterine fundus	A mass in the uterine fundus
FIGO stage	IIB	IB	IIIC2
Tumor size	4 × 3 × 1.5 cm <sup>3</sup>	4.5×4.4×1.8cm <sup>3</sup>	3 × 2.5 × 1 cm <sup>3</sup>
Pathological findings	Poorly differentiated component (90%) + EC Grade I (10%)	Poorly differentiated component (60%) + EC Grade I (40%)	Poorly differentiated component (70%) + EC Grade I (30%)
Mitotic count	>20/10HPF	>20/10HPF	>20/10HPF
MI	<50%	>50%	>50%
Cervical interstitial infiltration	YES	NO	NO
LVSI	YES	NO	YES
Treatment	TAH-BSO+RT+CTX	TAH-BSO	TAH-BSO+CTX
Follow-up	Ned at 60 mo	Ned at 26 mo	Ned at 15 mo

**Abbreviations:** CEA, carcinoembryonic antigen; CA, cancer antigen; LUS, lower uterine segment; EC, endometrioid carcinoma; HPF, high power field; MI, myometrial invasion; LVSI, lymphovascular space invasion; ned, no evidence of disease; TAH-BSO, total abdominal hysterectomy and bilateral salpingo-oophorectomy; RT, radiation therapy; CTX, chemotherapy; mo, month.

differentiated components contained cells with large, polygonal, vesicular nuclei, prominent nucleoli and abundant eosinophilic cytoplasm. The mitotic count was >20 per 10 high-power fields in each case. Lymphovascular space invasion was evident in cases 1 and 3, but not case 2. Three para-aortic lymph nodes showed poorly differentiated components and metastasis by morphological analysis in case 3. No nodal metastasis was seen in case 1 or 2.

The immunostaining results are presented in Table 3. All poorly differentiated components were positive for p16 and at least two of three neuroendocrine markers (chromogranin, synaptophysin and CD56) in >10% of the tumor cells. Synaptophysin was the most commonly expressed biomarker (20% of cells in case 1, 15% in case 2, 80% in case 3), followed by chromogranin (15% of cells in case 2, 70% in case 3) and CD56 (20% of cells in case 1, 80% in case 3). In case 3, there was strong and diffuse expression of all three neuroendocrine markers. The well-differentiated adenocarcinoma components were all positive for the estrogen receptor and focally positive for chromogranin. IHC expression of p53 was normal in all the cases. Notably, p53 was diffusely positive in the poorly

differentiated component in case 3. Loss of SMARCB1 (INI1) expression was found in case 3, but no loss of SMARCA4 (BRG1) or ARID1A expression was noted in any of the cases. Regarding MMR biomarkers, MLH1 and PSM2 staining was negative in case 2, and MSH2 and MSH6 staining was negative in case 3. Representative images of the IHC staining results are shown in Figure 1E–I.

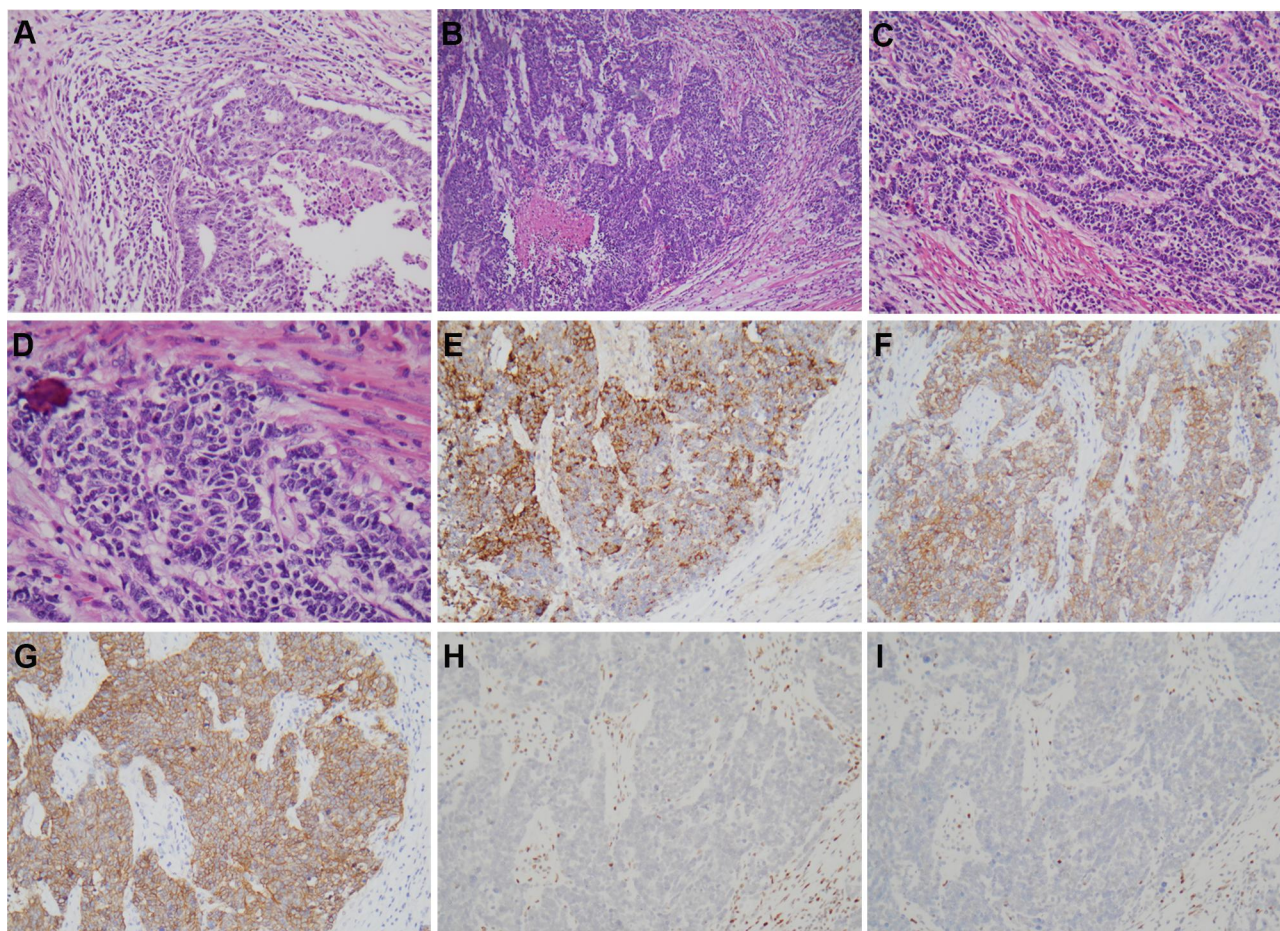
Based on the above findings, a diagnosis of dedifferentiated endometrioid carcinoma with neuroendocrine differentiation (large cell type) was made for all three cases.

## Follow-Up

Follow-up data were available for all patients. All three patients were alive without disease for 60, 26 and 15 months, respectively.

## Discussion

LCNECs arising from the endometrium are rarer than those arising from the cervix and ovaries.<sup>4</sup> These neoplasms are either “pure” LCNEC or mixed with other histologic components.<sup>5–7,9–19</sup> Among other histologic components of endometrial LCNEC, endometrioid



**Figure 1 (A–I)** Case 3: Well-differentiated endometrioid carcinoma with local squamous differentiation and increased tumor-infiltrating lymphocytes (A, 20×). Large cell neuroendocrine carcinoma (LCNEC) arranged in solid sheets and organoid with necrosis (B, 10×), trabecular (C, 20×) and rosette/pseudorosette (D, 40×). The immunochemical photograph of LCNEC: chromogranin (E, 20×), synaptophysin (F, 20×), neural cell adhesion molecule (CD56) (G, 20×), MSH2 (H, 20×), MSH6 (I, 20×).

carcinoma is the most common histologic type, followed by serous carcinoma. Based on prior reports and our case studies, the most common clinical symptoms are postmenopausal or perimenopausal vaginal bleeding and/or abnormal vaginal discharge.<sup>5–16</sup>

Endometrial NECs often occur in association with a more typical form of endometrioid carcinoma.<sup>4</sup> In our cases, the adenocarcinoma component was also low-grade endometrioid carcinoma. Pocrnich et al described 10 mixed low-grade (FIGO stage 1–2) endometrioid and NECs.<sup>5</sup> The neuroendocrine component was large and small cell type in eight and two tumors, respectively, and all tumors were positive for at least one neuroendocrine marker (chromogranin, synaptophysin or CD56) in >10% of neoplastic cells. Similarly, Espinosa et al<sup>6</sup> reported three tumors with a LCNEC component and one tumor with a small cell carcinoma component. All tumors demonstrated neuroendocrine expression in  $\geq 70\%$  of the

cells in the undifferentiated component. In our study, at least two of three neuroendocrine markers were positive in  $\geq 10\%$  of tumor cells. Synaptophysin was most commonly expressed, followed by chromogranin and CD56. However, expression of neuroendocrine markers, especially CD56, is a common feature of endometrial cancers, even without classic neuroendocrine histology.<sup>17</sup>

There is evidence that NEC originates from neuroendocrine cells in the endometrium as a result of “divergent differentiation”.<sup>9</sup> Yasuoka et al<sup>20</sup> found identical clonality between cervical adenocarcinoma and NEC in an X-chromosome clonality assay. Ariura et al<sup>19</sup> also reported identical alterations in PTEN, PIK3CA and FGFR3 in the endocrine and LCNEC components of NEC. Howitt et al<sup>18</sup> reported that 50% of endometrial NECs were ultramutated or hypermutated, which is more representative of other histologic types of endometrial carcinoma than canonical small cell carcinoma of the lung. Such observations suggest

**Table 3** Immunostaining Results of the Tumours

	Case 1		Case 2		Case 3	
	Poorly Differentiated Component	EC	Poorly Differentiated Component	EC	Poorly Differentiated Component	EC
PI6	+ (D)	+ (P)	+ (P)	+ (F)	+ (D)	+ (P)
P53	+ (P)	+ (F)	+ (F)	+ (F)	+ (D)	+ (F)
ER	–	+ (D)	+ (D)	+ (D)	–	+ (P)
PR	–	+ (D)	+ (D)	+ (P)	–	+ (F)
Chromogranin	–	+ (F)	+ (P)	+ (F)	+ (D)	+ (F)
Synaptophysin	+ (D)	–	+ (P)	–	+ (D)	–
CD56	+ (P)	–	–	–	+ (D)	+ (F)
MLH1	+ (R)	+ (R)	Lost	Lost	+ (R)	+ (R)
PSM2	+ (R)	+ (R)	Lost	Lost	+ (R)	+ (R)
MSH2	+ (R)	+ (R)	+ (R)	+ (R)	Lost	Lost
MSH6	+ (R)	+ (R)	+ (R)	+ (R)	Lost	Lost
SMARCB1 (INI1)	+ (intact)	+ (intact)	+ (intact)	+ (intact)	Lost	Lost
SMARCA4 (BRG1)	+ (intact)	+ (intact)	+ (intact)	+ (intact)	+ (intact)	+ (intact)
ARID1A	+ (intact)	+ (intact)	+ (intact)	+ (intact)	+ (intact)	+ (intact)
Ki67	+ (D)	+ (P)	+ (D)	+ (P)	+ (D)	+ (D)

**Abbreviations:** EC, endometrioid carcinoma; ER, estrogen receptor; PR, progesterone receptor; CD56, neural cell adhesion molecule; D, diffuse (≥50% labeling); F, focal (≤10% labeling); –, negative; P, patch (11–49% labeling); +, positive; R, retained nuclear staining.

that NEC may arise from adenocarcinoma via a “dedifferentiation process”. The overt continuity between the two components and focally positive expression of neuroendocrine markers in the adenocarcinoma component in one of our cases support this hypothesis. In addition, the loss of INI1 (a dedifferentiation marker) expression was found in both components (case 3), which suggests “dedifferentiation” from endometrioid carcinoma to NEC as a mechanism for the development of these cancers.

Among the three commonly used dedifferentiation markers (INI1, BRG1 and ARID1A), INI1 expression was negative in one of our three cases. INI1, BRG1 and ARID1A are part of the switch/sucrose non-fermenting protein complex. Loss of expression of proteins in this complex is a widely used diagnostic marker of dedifferentiated carcinomas.<sup>6,21,22</sup> Rosa-Rosa et al<sup>21</sup> evaluated 10 dedifferentiated carcinomas, of which 9 showed loss of ARID1A expression. Another study found that 15 of 30 (50%) dedifferentiated carcinomas showed loss of BRG1 or INI1, or both.<sup>22</sup> In our study, only case 3 showed loss of INI1 expression.

The tumors of all three patients showed an increased number of tumor-infiltrating lymphocytes at the tumor invasion front or periphery. The tumor in case 1 was located in the lower uterine segment. Such morphological findings might indicate Lynch syndrome.<sup>23</sup> Thus, IHC staining of a MMR protein panel (MLH1, PMS2, MSH2 and MSH6) was used to screen for Lynch syndrome and guide the

germline mutation testing. Interestingly, abnormal MMR protein expression was noted in two of the three cases. There was negative staining of MLH1 and PMS2 in case 2 and of MSH2 and MSH6 in case 3. Previous reports have described abnormal expression of MMR proteins in endometrial NEC.<sup>5–7</sup> Combined loss of MLH1 and PMS2 is seen most commonly. Pocrnich et al<sup>5</sup> reported that 6 of 18 endometrial NEC cases showed loss of MLH1/PMS2 expression. In contrast, isolated MSH6 loss or combined MSH2/MSH6 loss is relatively rare in endometrial NEC. A recent report showed MLH1/PMS2 loss in two of four endometrial NECs.<sup>6</sup> Collectively, these reports indicate a relationship between loss of MMR protein expression and endometrial LCNEC.

Although LCNEC usually exhibits aggressive behavior, our patients survived with no disease for 60, 26 and 15 months, respectively. Interestingly, patient 2 (stage IB) and patient 3 (stage IIIC2), who had para-aortic lymph node metastasis, did not receive adjuvant chemotherapy or radiation therapy. The reason for the relatively good prognosis remains unclear. We speculate that loss of MMR protein expression in tumor cells elicits a greater immune response due to impaired DNA repair in the tumor cells. This enhanced immune response may improve prognosis compared with NEC without loss of MMR protein expression. Pocrnich et al<sup>5</sup> reported that only three of eight patients with endometrial NEC with MMR deficiency (stage IIIC2 in one, stage IVB in two) died from

their disease during follow-up; however, tumor-infiltrating lymphocytes were observed in only two cases.

## Conclusion

Dedifferentiated endometrioid carcinomas with neuroendocrine differentiation are associated with MMR deficiency, which may improve the prognosis of affected patients. Our observations were based on a relatively small number of follow-up samples. Thus, additional systematic studies are needed to address this topic comprehensively.

## Author Contributions

All authors made a significant contribution to the work reported, whether that is in the conception, study design, execution, acquisition of data, analysis and interpretation, or in all these areas; took part in drafting, revising or critically reviewing the article; gave final approval of the version to be published; have agreed on the journal to which the article has been submitted; and agree to be accountable for all aspects of the work; H.C. and X.Z. took part in drafting, H.C. and W.Z. revising or critically reviewing the article; F.Z. gave final approval of the version to be published.

## Disclosure

All authors report no conflicts of interest in this work.

## References

- Kurman RJ; International Agency for Research on Cancer. *World Health Organization: WHO Classification of Tumours of Female Reproductive Organs*. 4th ed. International Agency for Research on Cancer: Lyon; 2014.
- Gonzalez-Bosquet E, Gonzalez-Bosquet J, Garcia Jimenez A, Gil A, Xercavins J. Carcinoid tumor of the uterine corpus. A case report. *J Reprod Med*. 1998;43(9):844–846.
- Chetty R, Clark SP, Bhathal PS. Carcinoid tumour of the uterine corpus. *Virchows Arch a Pathol Anat Histopathol*. 1993;422(1):93–95. doi:10.1007/BF01605139
- Howitt BE, Kelly P, McCluggage WG. Pathology of neuroendocrine tumours of the female genital tract. *Curr Oncol Rep*. 2017;19(9):59. doi:10.1007/s11912-017-0617-2
- Pocrnich CE, Ramalingam P, Euscher ED, Malpica A. Neuroendocrine carcinoma of the endometrium: a clinicopathologic study of 25 cases. *Am J Surg Pathol*. 2016;40(5):577–586. doi:10.1097/PAS.0000000000000633
- Espinosa I, De Leo A, D'Angelo E, et al. Dedifferentiated endometrial carcinomas with neuroendocrine features: a clinicopathologic, immunohistochemical, and molecular genetic study. *Hum Pathol*. 2018;72:100–106. doi:10.1016/j.humpath.2017.11.006
- Chougule A, Garg R, Jain V. Paranuclear dot-like pancytokeratin positivity and MLH1/PMS2 loss in large cell neuroendocrine carcinoma of the endometrium. *Pathology*. 2016;48(7):736–739. doi:10.1016/j.pathol.2016.08.012
- Liu L, Zhou F, Qin J, Qian Z, Huang L. Roles of mifepristone on the regulation of cytotoxic lymphocytes and regulatory T cells. *Gynecol Obstet Invest*. 2017;82(6):533–537. doi:10.1159/000455848
- Matsumoto H, Nasu K, Kai K, Nishida M, Narahara H, Nishida H. Combined large-cell neuroendocrine carcinoma and endometrioid adenocarcinoma of the endometrium: a case report and survey of related literature. *J Obstet Gynaecol Res*. 2016;42(2):206–210. doi:10.1111/jog.12881
- Tu YA, Chen YL, Lin MC, Chen CA, Cheng WF. Large cell neuroendocrine carcinoma of the endometrium: a case report and literature review. *Taiwan J Obstet Gynecol*. 2018;57(1):144–149. doi:10.1016/j.tjog.2017.12.025
- Albores-Saavedra J, Martinez-Benitez B, Luevano E. Small cell carcinomas and large cell neuroendocrine carcinomas of the endometrium and cervix: polypoid tumors and those arising in polyps may have a favorable prognosis. *Int J Gynecol Pathol*. 2008;27(3):333–339. doi:10.1097/PGP.0b013e31815de006
- Mulvany NJ, Allen DG. Combined large cell neuroendocrine and endometrioid carcinoma of the endometrium. *Int J Gynecol Pathol*. 2008;27(1):49–57. doi:10.1097/pgp.0b013e31806219c5
- Deodhar KK, Kerkar RA, Suryawanshi P, Menon H, Menon S. Large cell neuroendocrine carcinoma of the endometrium: an extremely uncommon diagnosis, but worth the efforts. *J Cancer Res Ther*. 2011;7(2):211–213. doi:10.4103/0973-1482.82942
- Ono K, Yokota NR, Yoshioka E, et al. Metastatic large cell neuroendocrine carcinoma of the lung arising from the uterus: a pitfall in lung cancer diagnosis. *Pathol Res Pract*. 2016;212(7):654–657. doi:10.1016/j.prp.2016.03.009
- Kobayashi A, Yahata T, Nanjo S, et al. Rapidly progressing large-cell neuroendocrine carcinoma arising from the uterine corpus: a case report and review of the literature. *Mol Clin Oncol*. 2017;6(6):881–885. doi:10.3892/mco.2017.1229
- Nguyen ML, Han L, Minors AM, et al. Rare large cell neuroendocrine tumor of the endometrium: a case report and review of the literature. *Int J Surg Case Rep*. 2013;4(8):651–655. doi:10.1016/j.ijscr.2013.04.027
- Moritz AW, Schlumbrecht MP, Nadji M, Pinto A. Expression of neuroendocrine markers in non-neuroendocrine endometrial carcinomas. *Pathology*. 2019;51(4):369–374. doi:10.1016/j.pathol.2019.02.003
- Howitt BE, Dong F, Vivero M, et al. Molecular characterization of neuroendocrine carcinomas of the endometrium: representation in all 4 TCGA groups. *Am J Surg Pathol*. 2020; Publish Ahead of Print. doi:10.1097/PAS.0000000000001560
- Ariura M, Kasajima R, Miyagi Y, et al. Combined large cell neuroendocrine carcinoma and endometrioid carcinoma of the endometrium: a shared gene mutation signature between the two histological components. *Int Cancer Conf J*. 2017;6(1):11–15. doi:10.1007/s13691-016-0263-9
- Yasuoka H, Tsujimoto M, Ueda M, et al. Monoclonality of composite large-cell neuroendocrine carcinoma and invasive intestinal-type mucinous adenocarcinoma of the cervix: a case study. *Int J Gynecol Pathol*. 2013;32(4):416–420. doi:10.1097/PGP.0b013e318261c35b
- Rosa-Rosa JM, Leskela S, Cristobal-Lana E, et al. Molecular genetic heterogeneity in undifferentiated endometrial carcinomas. *Mod Pathol*. 2016;29(11):1390–1398. doi:10.1038/modpathol.2016.132
- Karnezis AN, Hoang LN, Coatham M, et al. Loss of switch/sucrose non-fermenting complex protein expression is associated with dedifferentiation in endometrial carcinomas. *Mod Pathol*. 2016;29(3):302–314. doi:10.1038/modpathol.2015.155
- Resnick KE, Hampel H, Fishel R, Cohn DE. Current and emerging trends in Lynch syndrome identification in women with endometrial cancer. *Gynecol Oncol*. 2009;114(1):128–134. doi:10.1016/j.ygyno.2009.03.003

## Cancer Management and Research

Dovepress

### Publish your work in this journal

Cancer Management and Research is an international, peer-reviewed open access journal focusing on cancer research and the optimal use of preventative and integrated treatment interventions to achieve improved outcomes, enhanced survival and quality of life for the cancer patient.

The manuscript management system is completely online and includes a very quick and fair peer-review system, which is all easy to use. Visit <http://www.dovepress.com/testimonials.php> to read real quotes from published authors.

Submit your manuscript here: <https://www.dovepress.com/cancer-management-and-research-journal>