

Immunohistochemical detection of MnSOD in colon adenocarcinoma patients – clinical application

Jerzy Z. Piecuch¹, Marek Kucharzewski², Grzegorz Wyrobiec³, Marlena Brzozowa-Zasada³

¹Department of General and Bariatric Surgery and Emergency Medicine in Zabrze, Faculty of Medical Sciences in Zabrze, Medical University of Silesia, Katowice, Poland

²Faculty of Health Sciences, Jan Dlugosz University of Czestochowa, Czestochowa, Poland

³Department of Histology and Cell Pathology in Zabrze, Faculty of Medical Sciences in Zabrze, Medical University of Silesia in Katowice, Poland

Gastroenterology Rev 2024; 19 (2): 186–193
DOI: <https://doi.org/10.5114/pg.2024.139238>

Key words: antioxidant enzyme, MnSOD, colon adenocarcinoma, oxidative stress.

Address for correspondence: Dr Marlena Brzozowa-Zasada, Department of Histology and Cell Pathology, Faculty of Medical Sciences in Zabrze, Medical University of Silesia in Katowice, Poland, phone: +48 32 2722842, e-mail: marlena.brzozowa@op.pl

Abstract

Introduction: Colon adenocarcinoma (COAD) is one of the most frequently identified cancers of the digestive system. It is worth noting that the 5-year survival rates for patients diagnosed early are approximately 90%, whereas for patients with advanced diagnosis it is only 10%. It may indicate that metastasis is a critical cause of death for cancer patients.

Aim: The current study investigated the immunohistochemical expression of MnSOD in individuals living in Poland, who were diagnosed as colon adenocarcinoma patients, to assess its prognostic significance by correlating its expression with the clinicopathological factors and overall survival (OS).

Material and methods: Paraffin-embedded adenocarcinoma samples were assessed immunohistochemically for MnSOD protein. The relationship between MnSOD immunorexpression and clinicopathological factors including the 5-year overall survival (OS) were evaluated.

Results: Immunohistochemical expression of MnSOD protein was detected in colon adenocarcinoma samples and non-pathological samples of colon tissues. As demonstrated, the level of the MnSOD immunohistochemical reactivity was not correlated with clinicopathological factors. A multivariate analysis demonstrated that the grade of tumour differentiation and MnSOD immunorexpression in healthy tissues were independent risk factors for worse survival of patients.

Conclusions: The high level of MnSOD immunorexpression in cancerous tissue was not associated with malignancy-related clinicopathological factors and 5-year overall survival of patients.

Introduction

Colon adenocarcinoma (COAD) is one of the most commonly diagnosed cancers of the gastrointestinal system. It is thought that more than 2.2 million new cases will be diagnosed and 1.1 million deaths will occur because of COAD by 2030. Unfortunately, despite adequate surgical therapies and chemotherapies, the 5-year survival rate of COAD patients is still poor. It is worth noting that the 5-year survival rate for patients diagnosed early is approximately 90%, whereas for patients with advanced diagnosis it is only 10%. This may indicate that metastasis is a critical cause of death for cancer patients [1–3]. Hence, there is an urgent need to identify novel prognostic biomarkers associated with metastasis, which can identify the high-risk patients

and facilitate the timely application of appropriate individual treatments for COAD patients.

It has been widely reported that mitochondria are a known source of intracellular reactive oxygen species (ROS). Under physiological conditions they are constantly generated as by-products of aerobic metabolism in the mitochondria. During mitochondrial respiration, the tricarboxylic acid (TCA) cycle produces components with reducing properties, acting as a source for electrons. Electron transfer between mitochondrial electron transport complexes sets up a proton gradient for synthesis of ATP. It has been revealed that electrons can flee from the electron transport chain and react with oxygen molecules to form superoxide anions, which play a major role in a wide array of ROS [4]. It is worth

mentioning that roughly 1–5% of the total oxygen consumed during the respiration process is transformed to superoxide radicals. Superoxide is highly reactive and toxic. For example, it may react with nitric oxide to form highly reactive peroxynitrite. These ROS are major factors associated with damage to mitochondrial lipids, proteins, and nucleic acids [5].

To counter the harmful effect of ROS, cells are possessed with an antioxidant defence system to detoxify ROS and avert them from their accumulation at high concentrations. The mitochondria-located manganese superoxide dismutase (MnSOD, SOD2) is known to convert superoxide to the less reactive hydrogen peroxide (H_2O_2), which may break down further into water and dioxygen by other enzymatic and non-enzymatic antioxidants. Because superoxide primarily emerges from mitochondria, mitochondrial MnSOD is thought to play a major role in detoxification of ROS [6,7].

Nevertheless, there is a little information about the expression of this protein in cancers of the digestive tract, especially in colon adenocarcinoma. It has been revealed that immunohistochemical expression of MnSOD was detected in colon adenoma and adenocarcinoma. However, there is no information about the influence of this protein on patients' prognosis, especially those who did not receive any chemotherapies before surgical resection.

Aim

Therefore, the current study investigated the immunohistochemical expression of MnSOD in individuals living in Poland, who were diagnosed as colon adenocarcinoma patients, to assess its prognostic significance by correlating its expression with the clinicopathological factors and overall survival (OS).

Material and methods

Tissue samples

All colon adenocarcinoma samples were collected from patients who underwent radical surgery at the Municipal Hospital in Jaworzno. All patients were definitively diagnosed with colon adenocarcinoma and did not receive adjuvant chemotherapy or immunotherapy prior to surgery. The exclusion criteria were as follows: (1) history of previous malignant disease, (2) familial adenomatous polyposis, (3) inflammatory bowel disease, (4) preoperative anti-cancer treatment, and (5) evidence of distant metastasis. The clinicopathological characteristics obtained from the medical records were as follows: age, gender, location of tumour, grade of tumour differentiation, depth of invasion, regional lymph node involvement, operation record, treat-

ment record, reoccurrence, and vital status at the last follow-up date. The follow-up period was 60 months (5 years).

The colon adenocarcinoma specimens belonged to 48 men and 49 women (mean age: 68; range: 33–89 years). Tumours were located in the proximal part of the colon in 50 (51.5%) cases and in the distal part of the colon in 47 (48.45%) cases. Two levels of differentiation were used to classify the grading as follows: well differentiated, 66 (68.04%) cases; and poorly differentiated, 31 (31.96%) cases (Table I).

Immunohistochemical staining

For the immunohistochemical studies the paraffin-embedded specimens were cut into 4- μ m-thick sections, fixed on Polysine slides, deparaffinised in xylene, and rehydrated through a graded series of alcohol. To retrieve the antigenicity, the tissue sections were treated twice with microwaves in a 10 mM citrate buffer (pH 6.0) for 8 min each. Subsequently, sections were

Table I. Demographic, clinical, and tumour-related characteristics of patients included in the study ($n = 98$)

Parameter	N	%
Gender:		
Male	49	51
Female	48	49
Age [years]:		
≤ 60	26	27
> 61–75	37	38
75	34	35
Me [Q1–Q3]	68 [59–79]	
Min.–max.	33–89	
Grade of histological differentiation:		
Well	66	68
Poor	31	32
Depth of invasion:		
T1/T2	13	13
T3	67	69
T4	17	18
Regional LN involvement:		
N0	48	49
N1	37	38
N2	12	12
Location of tumour:		
Proximal part of colon	50	51
Distal part of colon	47	48

incubated with rabbit monoclonal antibody to MnSOD (final dilution 1 : 400) (Abcam cat. number ab68155). For visualisation of protein expression, the sections were treated with the BrightVision detection system and Permanent AP Red Kit (Zytomed). Mayer's haematoxylin was used to counterstain the nuclei.

The scores were assigned separately for the stained area and for the intensity of the immunohistochemi-

cal reaction. Quantification connected to the stained area of the tissue section was performed as follows: (1) < 33% of cells showed immunoreaction, (2) 33–66% of the cells had positive reaction to MnSOD, and (3) > 66% of the cells were positive. The intensity of the immunohistochemical reaction was quantified as follows: (1) absent or weak, (2) moderate, and (3) strong. Each tissue section was characterised by a final grade

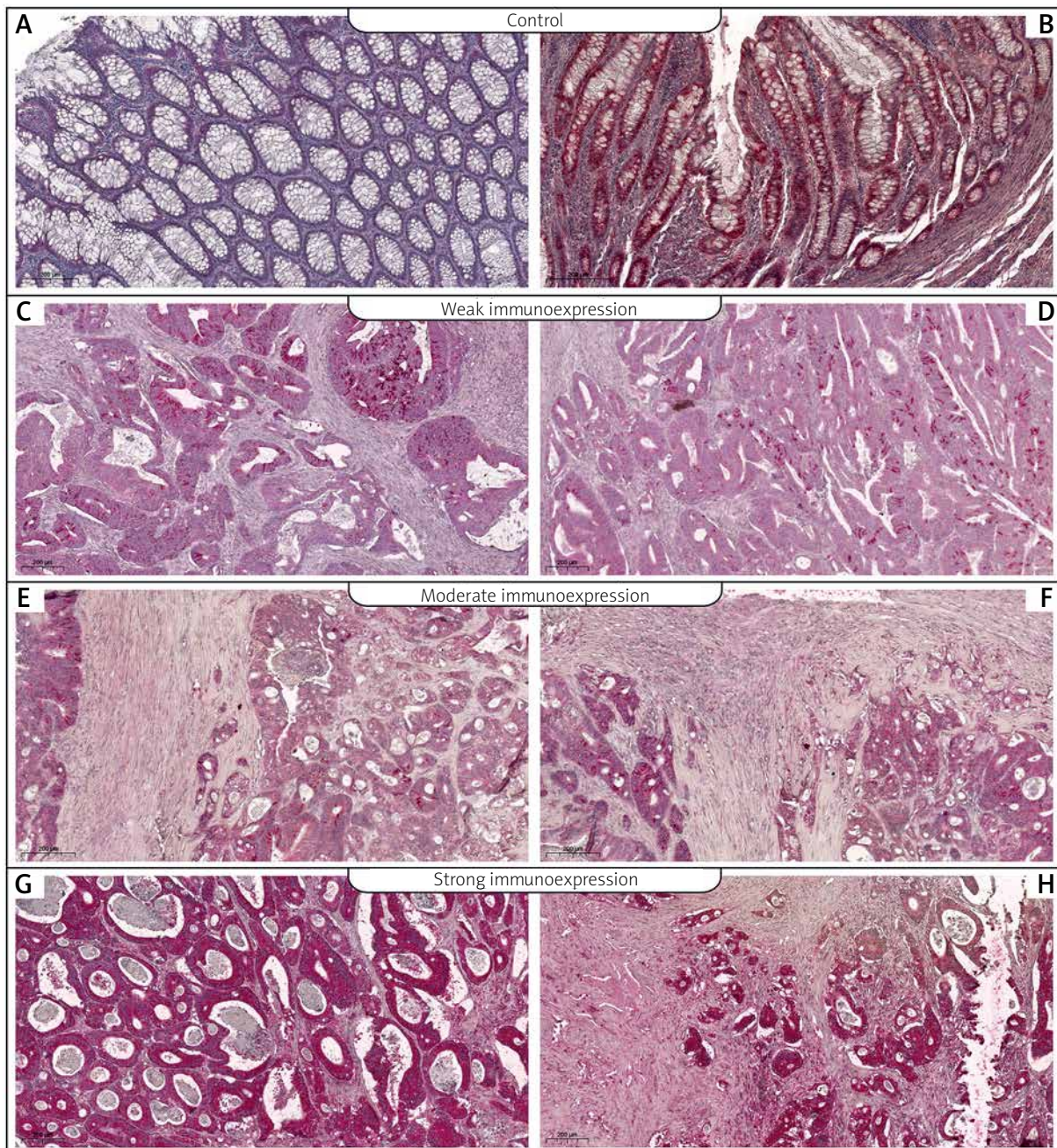


Figure 1. Immunohistochemical expression of MnSOD protein in non-pathological colon samples (A, B) and in tumour tissue: C, D – weak expression of MnSOD protein in colon adenocarcinoma samples, E, F – moderate expression of MnSOD, G, H – strong expression of MnSOD

derived from the multiplication of the stained area and the intensity of the staining. The MnSOD expression was considered to be absent/low for grade 1; moderate for grades 2, 3, and 4; and strong for grades 6 and 9.

Statistical analysis

Statistical analyses were conducted using Statistica 9.1 (StatSoft, Poland). The clinical characteristics of the patients in relation to MnSOD immunoreactivity were assessed by performing the Kruskal-Wallis test and *U* Mann-Whitney test. The Kaplan-Meier method was used to study overall survival rate curves, and the log-rank test was used to compute differences between the curves.

Results

To investigate the prognostic utility of MnSOD expression, the immunohistochemical analysis was performed in colon adenocarcinoma tissues and adjacent non-pathological samples in patients diagnosed with colon adenocarcinoma. It should be pointed out that expression of MnSOD protein in non-pathological samples was described as weak or moderate. In samples of colon adenocarcinoma, the high, moderate, and weak levels of MnSOD protein were demonstrated as well (Figure 1). Among the colon adenocarcinoma samples, 24 (25%) showed weak immunohistochemical reaction, 27 (28%) demonstrated moderate immu-

Table II. Correlations between MnSOD immunoexpression and clinicopathological characteristics in colon cancer patients

Parameter		The immunoexpression level of MnSOD			Statistical analysis
		1	2	3	
Age	≤ 60	6	7	13	H (2.97) = 0.113 NS
		24%	27%	50%	
	61–75	10	9	18	
		27%	24%	49%	
	> 75	8	11	15	
		24%	32%	44%	
Gender	Female	15	15	19	Z = -1.773 NS
		31%	31%	39%	
	Male	9	12	27	
		19%	25%	56%	
Grade of histological differentiation	Well	18	16	32	Z = -0.138 NS
		27%	24%	48%	
	Poor	6	11	14	
		19%	35%	45%	
Depth of invasion	T1/T2	3	4	6	H (2.97) = 0.169 NS
		23%	30%	46%	
	T3	17	19	31	
		25%	28%	46%	
	T4	4	4	9	
		24%	24%	53%	
Regional LN involvement	N0	13	14	21	Z = -0.721 NS
		27%	29%	44%	
	N1/N2	11	13	25	
		22%	27%	51%	
Location of tumour	Left	13	10	27	Z = -0.807 NS
		26%	20%	54%	
	Right	11	17	19	
		23%	36%	40%	

H – Kruskal-Wallis test, Z – U Mann-Whitney test.

noreactivity, and 46 (47%) showed strong expression. The relationships between the expression level and each clinicopathological parameter are summarised in Table II. As demonstrated, the level of the MnSOD immunohistochemical reactivity was not correlated with demographic factors including gender and age. The correlations were not also observed between MnSOD immunohistochemical reaction and clinicopathological factors (all $p > 0.05$; Table II).

The Kaplan-Meier survival analysis showed that the overall survival rate in the group of patients with a low expression of MnSOD was not significantly lon-

ger than that for patients with a moderate or strong level of MnSOD immunoreactivity ($p < 0.001$). The low-MnSOD patients had an average survival time of 39.3 months (95% CI: 31.300–47.283), whereas the MnSOD moderate expression groups had an average survival time of 37 months (95% CI: 30.077–43.775). The strong-MnSOD patients had an average survival time of 35.5 months (95% CI: 33.134–40.536). The average survival time for all the patients was 36.8 months (95% CI: 33.134–40.536). Univariate log-rank test for overall survival in 97 patients with colon adenocarcinoma demonstrated that grade of tumour differentiation

Table III. Univariate log-rank test for overall survival in patients with colon adenocarcinoma

Variable		N	Overall survival Me	χ^2	P-value
The immunoexpression level of MnSOD	Low	24	45	0.942	NS
	Moderate	27	45		
	Strong	46	34		
Gender	Female	49	36	< 0.001	NS
	Male	48	40		
Age	≤ 60	26	34	2.518	NS
	61–75	37	40		
	> 75	34	45		
Grade of histological differentiation	Well	66	45	22.651	< 0.001
	Poor	31	23		
Depth of invasion	T1/T2	13	46	2.535	NS
	T3	67	45		
	T4	17	32		
Regional LN involvement	N0	48	43	0.372	NS
	N1/N2	49	34		
Location of tumour	Proximal colon	50	43	0.129	NS
	Distal colon	47	35		
The expression of MnSOD in healthy colon mucosa	Low	39	46	7.900	0.005
	Moderate	58	27		

Table IV. Multivariate Cox regression analysis of overall survival in patients with colon adenocarcinoma

Prognostic parameter	Multivariate analysis		
	HR	95% CI	P-value
Gender	–	–	–
Age	–	–	–
The grade of histological differentiation	2.740	1.864–4.027	< 0.001
Depth of invasion	–	–	–
Regional LN involvement	–	–	–
The tumour location	–	–	–
The immunoexpression level of MnSOD in cancer tissue	–	–	–
The immunoexpression level of MnSOD in healthy colon mucosa	1.700	1.073–2.694	0.024

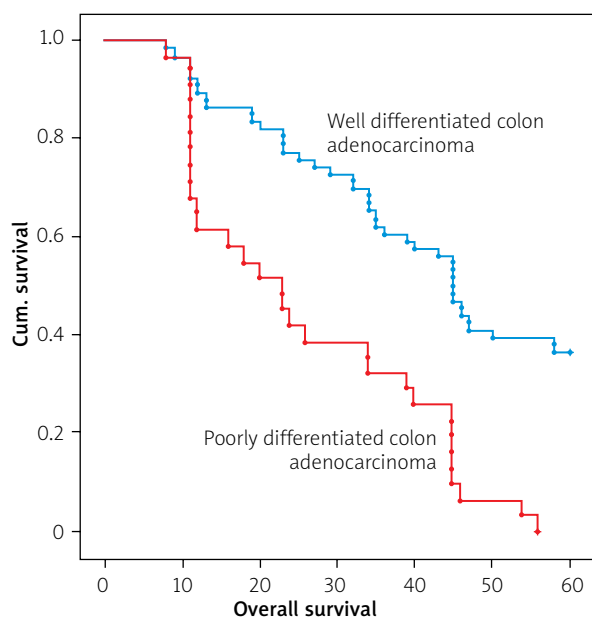


Figure 2. Kaplan-Meier survival curves of colon adenocarcinoma patients with moderate and poor cancer histological differentiation; follow-up period = 60 months

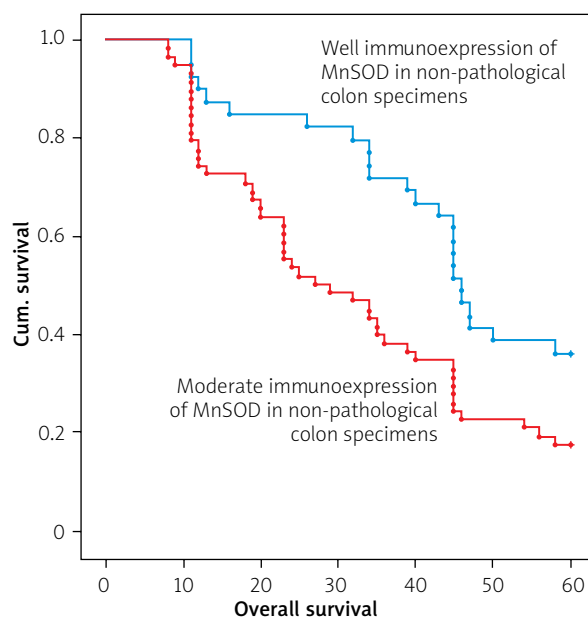


Figure 3. Kaplan-Meier survival curves of colon adenocarcinoma patients with low and strong MnSOD immunohistochemical expression in colon adenocarcinoma patients; follow-up period = 60 months

and MnSOD immunoeexpression in non-pathological samples were significantly correlated with reduced OS (Table III). Moreover, a multivariate analysis demonstrated that grade of tumour differentiation (HR = 2.740; 95% CI: 1.864–4.027, $p < 0.001$) and MnSOD immunoeexpression in non-pathological adjacent colon tissue (HR = 1.700; 95% CI: 1.073–2.694) were independent risk factors for worse survival (Table IV; Figures 2, 3).

Discussion

MnSOD has been characterized as an antioxidant factor associated with the process of cancer development. Through the changing cellular processes, its up- and downregulation is clearly related to cancer development. A great number of studies have demonstrated that MnSOD expression was upregulated in many cancers. However, inhibition of MnSOD expression has been detected as well [8, 9]. The increased expression of MnSOD has been observed in cancer patients including lymphoma [10, 11], oral carcinoma [12–14], oesophageal squamous cell carcinoma [15], glioblastoma [16], ovarian carcinoma [17, 18], kidney cancer [19, 20], and colon cancer [21]. The results of our study demonstrated that expression of MnSOD was up-regulated in colon adenocarcinoma tissue in comparison to healthy ones. Interestingly, the level of MnSOD immunohistochemical expression was not correlated with clinicopathological

factors and cancer progression. Also, the expression of MnSOD in colon adenocarcinoma patients with lymph node metastasis was not significantly higher than that observed in patients without metastasis. Moreover, the level of MnSOD expression in cancer samples was not correlated with the overall survival of patients. It should be pointed out that the level MnSOD expression in adjacent non-pathological tissue was correlated with reduced level of survival. Apart from the level of histological differentiation, the level of MnSOD in adjacent non-pathological mucosa was the second factor connected with poor prognosis. Our study is the first to demonstrate that expression of MnSOD is a factor that may be correlated with reduced survival of patients. But in this context our study has some limitations. Firstly, the patients are only from a European population living in Poland. Secondly, the small sample size has attenuated statistical power. Therefore, further studies are warranted to confirm our findings.

Connor *et al.* showed that the increased activity of Mn-SOD in bladder cancer causes a 3-fold increase in the invasiveness of this tumour. This indicates the enormous importance of this enzyme as a potential diagnostic marker and to monitor the patient's condition and assess whether the tumour is entering an invasive phase. It seems therefore that elevated levels of MnSOD can be correlated with acquisition of invasive abilities

during epithelial mesenchymal transition (EMT) [22]. Some studies revealed that MnSOD-dependent production of H₂O₂ increased the expression of matrix-degrading metalloproteinases (MMPs), forming permissive conditions for metastatic disease. Hempel *et al.* demonstrated that acquisition of metastatic phenotype was connected with increased expression of MnSOD in the 253J B-V cells [23]. It was also demonstrated in fibrosarcoma through MMP1 [24] in lung adenocarcinoma throughout the FoxM1–MMP2 axis [25]. A recent work has proposed a novel action of SOD2 as a sustaining factor in the Warburg effect. According to this study, SOD2 causes a metabolic shift to glycolysis in cancer cells by upregulating the AMP-activated kinase (AMPK) pathway, thus pointing out that H₂O₂ is also involved in cancer metabolic bioenergetics [26, 27].

Conclusions

The results of our study demonstrated that expression of MnSOD was up-regulated in colon adenocarcinoma tissue in comparison to samples without any pathological changes. The level of MnSOD immunohistochemical expression was not related to clinicopathological factors. It should be pointed out here that the level MnSOD expression in healthy tissues and the grade of histological differentiation was correlated with reduced OS.

Funding

This study was supported by grant PCN-1-153/N/O/O and KNW-2-B28/D/6/N.

Ethics approval

Not applicable.

Conflict of interest

The authors declare no conflict of interest.

References

- Rawla P, Sunkara T, Barsouk A. Epidemiology of colorectal cancer: incidence, mortality, survival, and risk factors. *Gastroenterology Rev* 2019; 14: 89-103.
- Sawicki T, Ruszkowska M, Danielewicz A, et al. A review of colorectal cancer in terms of epidemiology, risk factors, development, symptoms and diagnosis. *Cancers* 2021; 13: 2025.
- Brzozowa-Zasada M. Immunohistochemical expression of Snail1 protein in colorectal adenocarcinoma samples and its prognostic activity in Caucasian patients. *Gastroenterology Rev* 2021; 16: 339-45.
- Sabharwal SS, Schumacker PT. Mitochondrial ROS in cancer: initiators, amplifiers or an Achilles' heel? *Nat Rev Cancer* 2014; 14: 709-21.
- Lee YG, Park DH, Chae YC. Role of mitochondrial stress response in cancer progression. *Cells* 2022; 11: 771.
- Prasad S, Gupta SC, Tyagi AK. Reactive oxygen species (ROS) and cancer: role of antioxidative nutraceuticals. *Cancer Lett* 2017; 387: 95-105.
- Moloney JN, Cotter TG. ROS signalling in the biology of cancer. *Semin Cell Dev Biol* 2018; 80: 50-64.
- Kim YS, Gupta Vallur P, Phaëton R, et al. Insights into the dichotomous regulation of SOD2 in cancer. *Antioxidants (Basel)* 2017; 6: 86.
- Ashtekar A, Huk D, Magner A, et al. Alterations in SOD2-induced oxidative stress affect endocrine cancer progression. *J Clin Endocrinol Metab* 2018; 103: 4135-45.
- Karihtala P, Porvari K, Soini Y, et al. Redox regulating enzymes and connected microRNA regulators have prognostic value in classical Hodgkin lymphomas. *Oxid Med Cell Longev* 2017; 2017: 2696071.
- Bur H, Haapasaari KM, Turpeenniemi-Hujanen T, et al. Oxidative stress markers and mitochondrial antioxidant enzyme expression are increased in aggressive Hodgkin lymphomas. *Histopathology* 2014; 65: 319-27.
- Ye H, Wang A, Lee BS, et al. Proteomic based identification of manganese superoxide dismutase 2 (SOD2) as a metastasis marker for oral squamous cell carcinoma. *Cancer Genomics Proteomics* 2008; 5: 85-94.
- Wang W, He Q, Sun J, et al. Pyruvate kinase M2 deregulation enhances the metastatic potential of tongue squamous cell carcinoma. *Oncotarget* 2017; 8: 68252-62.
- Chang B, Yang H, Jiao Y, et al. SOD2 deregulation enhances migration, invasion and has poor prognosis in salivary adenoid cystic carcinoma. *Sci Rep* 2016; 6: 25918.
- Ma RL, Shen LY, Chen KN. Coexpression of ANXA2, SOD2 and HOXA13 predicts poor prognosis of esophageal squamous cell carcinoma. *Oncol Rep* 2014; 31: 2157-64.
- Shwetha SD, Shastry AH, Arivazhagan A, et al. Manganese superoxide dismutase (MnSOD) is a malignant astrocytoma specific biomarker and associated with adverse prognosis in p53 expressing glioblastoma. *Pathol Res Pract* 2016; 212: 17-23.
- Hemachandra LP, Shin DH, Dier U, et al. Mitochondrial superoxide dismutase has a protumorigenic role in ovarian clear cell carcinoma. *Cancer Res* 2015; 75: 4973-84.
- Amano T, Chano T, Isono T, et al. Abundance of mitochondrial superoxide dismutase is a negative predictive biomarker for endometriosis-associated ovarian cancers. *World J Surg Oncol* 2019; 17: 24.
- Isono T, Chano T, Yonese J, et al. Therapeutic inhibition of mitochondrial function induces cell death in starvation-resistant renal cell carcinomas. *Sci Rep* 2016; 6: 25669.
- Yoshida T, Kageyama S, Isono T, et al. Superoxide dismutase 2 expression can predict prognosis of renal cell carcinoma patients. *Cancer Biomark* 2018; 22: 755-61.
- Meng X, Wu J, Pan C, et al. Genetic and epigenetic down-regulation of microRNA-212 promotes colorectal tumor metastasis via dysregulation of MnSOD. *Gastroenterology* 2013; 145: 426-36.e1-6.
- Connor KM, Hempel N, Nelson KK, et al. Manganese superoxide dismutase enhances the invasive and migratory activity of tumor cells. *Cancer Res* 2007; 67: 10260-7.

23. Hempel N, Ye H, Abessi B, et al. Altered redox status accompanies progression to metastatic human bladder cancer. *Free Radic Biol Med* 2009; 46: 42-50.
24. Nelson KK, Subbaram S, Connor KM, et al. Redox-dependent matrix metalloproteinase-1 expression is regulated by JNK through Ets and AP-1 promoter motifs. *J Biol Chem* 2006; 281: 14100-10.
25. Satomi A, Murakami S, Hashimoto T, et al. Significance of superoxide dismutase (SOD) in human colorectal cancer tissue: correlation with malignant intensity. *J Gastroenterol* 1995; 30: 177-82.
26. Tsanou E, Ioachim E, Briasoulis E, et al. Immunohistochemical expression of superoxide dismutase (MnSOD) anti-oxidant enzyme in invasive breast carcinoma. *Histol Histopathol* 2004; 19: 807-13.
27. Hart PC, Mao M, de Abreu AL, et al. MnSOD upregulation sustains the Warburg effect via mitochondrial ROS and AMPK-dependent signalling in cancer. *Nat Commun* 2015; 6: 6053.

Received: 12.04.2022

Accepted: 27.10.2022

Online publication: 26.04.2024