



REVIEW ARTICLE

Impacted maxillary canine in unilateral cleft lip and palate: A literature review



Ali Alqerban*

Department of Preventive Dental Sciences, College of Dentistry, Prince Sattam Bin Abdulaziz University, Alkharj, Saudi Arabia

Received 17 September 2018; revised 31 October 2018; accepted 1 November 2018
Available online 9 November 2018

KEYWORDS

Maxillary canine;
Cleft lip;
Cleft palate;
Impaction

Abstract *Background:* The incidence of canine impaction in unilateral cleft lip and palate (UCLP) is increasing and in most cases is a part of a syndrome. The provision of different treatment modalities in these patients is a challenging and daunting task.

Objective: The objective of the present review was to scrutinize the available evidence on canine impaction in UCLP patients.

Materials and methods: Using PRISMA guidelines, a review was conducted via the PubMed (MEDLINE), ISI Web of Knowledge, Google Scholar, and Embase databases using different keywords. Studies were shortlisted and inspected according to the following inclusion criteria: (1) papers published in English over the past 40 years, (2) study participants with maxillary canine impaction in unilateral cleft lip and palate, (3) studies reporting on canine impaction and cleft lip and palate, and (4) no age limit was applied so studies published on both children and adults with unilateral cleft lip and palate and canine impaction were included. Studies which justified inclusion criteria were included whereas the rest of the studies were removed.

Results: A total of 279 studies were retrieved using the search strategy. After removing duplicate reports and scrutinizing those based on title and abstract, 54 studies were shortlisted for full text review. Following the review, 22 studies were included in the final list. The presentation of data was based on the year of study, type of cleft, gender, age of bone graft, spontaneous eruption, and surgical exposure.

Conclusion: Every UCLP patient is different and treatment modalities should vary according to the characteristics, subjective response, and variability of the malformation.

© 2018 The Author. Production and hosting by Elsevier B.V. on behalf of King Saud University. This is an open access article under the CC BY-NC-ND license (<http://creativecommons.org/licenses/by-nc-nd/4.0/>).

* Address: Alkharj Public library, Saad Ibn Muadh AlKharj, Saudi Arabia.

E-mail address: a.alqerban@psau.edu.sa.

Peer review under responsibility of King Saud University.



Production and hosting by Elsevier

Contents

1. Introduction	85
1.1. What is canine impaction?	85
1.2. Theories and etiology related to canine impaction	85
1.3. Clinical findings to predict canine impaction	85
1.4. Adverse effects of canine impaction and interceptive treatment modalities	86
1.5. Canine eruption and UCLP patients	86
1.6. The nomenclature of bone transplantation and canine impaction in UCLP patients	86
2. Materials and methods	87
3. Results	87
4. Discussion	88
4.1. Canine impaction as a complication after bone graft	90
4.2. Role of agenesis and malformation of the lateral incisor in canine impaction	90
5. Future recommendations	90
6. Conclusion	90
Conflict of interest	90
Ethical statement	90
Acknowledgement	90
References	90

1. Introduction

Worldwide, unilateral cleft lip and palate (UCLP) has a prevalence of 0.5–3 per 1000 births (Akcem et al., 2010). In approximately 10% to 20% of these children, the cleft is part of a syndrome (Derijcke et al., 1996). Strong variations exist according to gender, population, geographic region, and maternal characteristics. UCLP is more common in the left side than the right with a ratio of 2:1, more often in boys than girls with a ratio of 2:1, and more common in the Caucasian population (Derijcke et al., 1996; Dewinter et al., 2003; Akcem et al., 2010). The etiology of clefts involves both genetic and local factors (Akcem et al., 2010).

1.1. What is canine impaction?

Canine impaction can be defined as an infra-osseous position of the canine after the expected eruption time (Litsas and Acar, 2011). Normally, a palatal displaced maxillary canine will result in an impaction (Power and Short, 1993). Canine impaction in the general population varies from 0.8% to 5.2% (Litsas and Acar, 2011).

1.2. Theories and etiology related to canine impaction

The etiology of canine impaction is summarized into two theories that attempt to explain the occurrence of palatal displaced canines. The first is guidance theory, which states that the canine tooth is insufficiently guided by eruption. The second is genetic theory, in which a developmental disorder in the dental lamina is considered the cause of the abnormal angular eruption (Litsas and Acar, 2011). Other reasons for retention of the canine include lack of space, persistence of the primary canine, and displacement of the canine germ by the developing maxillary sinus (Van Der Wal and Van Der Meulen, 2001). Most often, in a labially impacted canine,

crowding is the primary culprit. For instance, in 83% of labial impacted canines, there is lack of space. However, in palatal impactions, only 15–18% of cases show crowding (Bishara, 1992; Litsas and Acar, 2011). Furthermore, a labially impacted canine tooth will usually erupt naturally high in the labial sulcus, while for palatally impacted canines, intervention is required. This is probably due to the thick cortical bone of the palate along with the dense, thick, and resistant overlying palatal mucosa (Bishara, 1992).

1.3. Clinical findings to predict canine impaction

Clinically, it can be anticipated that canines can be impacted when: (1) the left and right sides of canine are asymmetrical with respect to each other; (2) the primary canine remains intact until the age of 15 years; (3) the canines are not palpable at their normal place (such as a labial bulge) despite advanced occlusal development and somatic maturity; (4) the eruption of the lateral incisor is late, with distal or labial inclination or migration; and (5) a palatal bulge is present (Ericson and Kuroi, 1988; Bishara, 1992). Some authors believe that the risk of canine tooth impaction can also be partly predicted on the basis of dentofacial characteristics and by evaluating the transversal maxillary width (Litsas and Acar, 2011). Furthermore, impaction can also be detected via radiographic evaluation (Alqerban et al., 2016). On a panoramic image, four radiographic factors are correlated to predict the prognosis of an impacted canine. These include the angulation between the tooth axis and the midline, the vertical distance of the crown tip to the occlusal plane, the anteroposterior position of the root point relative to the center line, and the degree of overlap between the angular tooth crown tip and the lateral incisor (Fleming et al., 2009; Litsas and Acar, 2011). Warford et al. (2003) investigated the mesiodistal location of the canine crown with respect to the neighboring teeth (sector) and the angulation with respect to a horizontal reference line as predictors of angular tooth impaction. The study concluded

that if the sector is more mesially localized, the risk of impaction is greater. The angulation, however, does not significantly contribute to predicting angular tooth impaction. Similarly, [Katsnelson et al. \(2010\)](#) attempted to determine the palatal or buccal position of an impacted canine tooth by measuring the angle between the tooth axis and the occlusal plane. The results showed that if the angle is greater than 65° , there are greater chances of the canine being situated buccally. Similarly, [Sajani and King \(2012\)](#) noted that from the age of five, there is a significant difference in the distance from the canine cuspid to the occlusal plane between the canine that will be impacted to the non-impacted contralateral canine. Moreover, from the age of nine, the impacted canine is more located in the mesial sector with an increased canine angle to the midline, in contrast to the non-impacted contralateral canine, which is respectively located directly above the primary canine and vertically angulated.

1.4. Adverse effects of canine impaction and interceptive treatment modalities

Adverse effects of an impacted canine include migration of the adjacent teeth and the loss of arch length, internal resorption, dentogenic cyst formation, external root resorption, and infection (mainly in cases of partial impaction) ([Bishara, 1992](#); [Litsas and Acar, 2011](#)). Furthermore, patients with an impacted canine require a longer treatment period. Orthodontic treatment should be started early to avoid ankylosis of the canine or resorption of the roots of the incisors ([Ericson and Kuroi, 1987](#)). The interceptive treatment for a displaced or impacted maxillary canine is extraction of the primary canine with maxillary expansion. Combining primary canine extraction with cervical pull headgear can significantly increase the success of treatment according to [Leonardi et al. \(2004\)](#) and [Baccetti et al. \(2008\)](#). The possible treatment options when the maxillary canine is effectively impacted are (1) no treatment and follow-up; (2) surgical release, which is the most desirable solution; (3) auto-transplantation of the canine; (4) prosthetic replacement; and (5) extracting the canine with posterior segmental osteotomy to move the buccal segment to mesial and thus close the space. The extraction of the canine must always be avoided because of its aesthetic and functional importance ([Alqerban et al., 2009](#)). Extraction is exceptionally only indicated in cases of ankylosis, internal or external root resorption, root dilatation, and pathological changes such as infection or cyst formation ([Bishara, 1992](#)).

1.5. Canine eruption and UCLP patients

All maxillary canines move incisally, buccally, and mesially on both the cleft and non-cleft sides ([Alqerban et al., 2009](#)). If the lateral incisor is present, it is usually located on the side of the bone defect. The canine tooth, on the other hand, is usually located at the distal edge of the gap or is superior to the bony defect ([Oberoi et al., 2010](#)). However, [Russell and McLeod \(2008\)](#) reported that canine teeth obtain more vertical angulation during eruption. [Lindauer et al. \(1992\)](#) established that in UCLP patients aged 9–10 years, the risk of impaction is higher when the canine tooth overlaps more than half of the root of the lateral incisor.

The maxillary canines at the cleft side erupt slower with delayed root development compared to those at the contralateral side ([Russell and McLeod, 2008](#)). This increases the risk of impaction. In addition, the amount of root development does not affect the outcome in terms of canine eruption ([Enemark et al., 2001](#)). A split-mouth study by [El et al. \(1982\)](#) found that the canine on the contralateral side (mean age of eruption 12.3 ± 1.2 SD) erupts faster than the canine on the cleft side (mean age of eruption 13.4 ± 1.9 SD). [Enemark et al. \(2001\)](#) found that contra-lateral canines erupt spontaneously. However, the risk of angular tooth impaction on the contralateral side is greater than the risk in the general population.

In UCLP patients who had not undergone bone grafting, there was a significant difference in the canine angle before and after eruption. After eruption, this angle was much more vertical, most likely because of conduction through the cortical bone ([Alqerban et al., 2009](#)). However, in children receiving a bone graft, there were no changes in the angle of eruption of the canines ([Oberoi et al., 2010](#)). This indicates that these canines erupt in the same inappropriate angle as before secondary bone grafting transplantation (SABT). From the aforementioned findings, it can be inferred that surgical exposure is necessary to correct inappropriate angles of eruption ([Russell and McLeod, 2008](#); [Oberoi et al., 2010](#)).

1.6. The nomenclature of bone transplantation and canine impaction in UCLP patients

There are three types of bone transplantation: primary, secondary, and tertiary. Primary bone transplantation is performed in primary dentition and completed before the age of 2 years. However, it may compromise midfacial growth ([Fudalej et al., 2011](#)).

Secondary bone graft transplantation (SABT) is further divided into two types: early and late secondary bone transplantation. In early SABT, the bone graft is placed at 5–7 years of age when the root formation of the lateral incisor reaches one-third to one-half of its final length ([Sindet-Pedersen and Enemark, 1985](#); [Kleinpoort et al., 2017](#)). However, late SABT occurs at 9–11 years of age when the root formation of the canine is one-quarter to two-thirds of its final length ([Boyne and Sands, 1972](#); [Lilja et al., 2000](#)). Orthodontic expansion of the maxillary arch will often be required before to improve access to the alveolar cleft and the closure of the nasal floor ([Hogan et al., 2003](#)). The choice between early and late SABT is made by evaluating and comparing the advantages and disadvantages. In patients with healthy lateral incisors, the procedure can be done earlier so that the lateral incisors can be maintained. In patients with agenesis of the lateral incisor or in whom maxillary growth problems would be detrimental, the surgery can be scheduled later ([Shashua and Omnell, 2000](#); [Kuijpers-Jagtman, 2006](#)).

A tertiary bone graft is performed when all of the permanent teeth have erupted. In UCLP, an alveolar bone graft can also be performed after the eruption of the permanent canines ([Lorenzoni et al., 2017](#)). At this stage, the bone graft only serves to restore the continuity of the alveolar crest, to close a persistent bucconasal fistula, to retract the canine orthodontically, or to place an implant at a later stage ([Da Silva Filho et al., 2000](#)). A bone graft at an older age is less

Table 1 Factors that may contribute Alveolar Bone Transplantation (ABT).

Variables	Reference
Age	Bergland et al. (1986a, 1986b), Ozawa et al. (2007)
Absence or presence of lateral incisor	Lilja et al. (2000)
Eruption of crown	Boyne and Sands (1972); Long et al. (1996)
Height of intermediary septa	Bergland et al. (1986a, 1986b)
Width of cleft	Jabbari et al. (2016)
Classification of malocclusion	Gereltzul et al. (2005), Jabbari et al. (2016)
Canine inclination	Enemark et al. (2001)
Timing of procedure	Enemark et al. (2001), Jia et al. (2006)
Type of cleft	Enemark et al. (2001)
Presurgical status of alveolar gap	Enemark et al. (2001)
Experience of surgeon	Long et al. (1996)

successful and can lead to more frequent problems (Long et al., 1996). According to Enemark et al. (1985), the risk of root resorption of the canine is greater once bone grafting is performed after the eruption of the canine tooth. This can be avoided by covering the canine with lyophilized (freeze-dried) bone during the operation. In a tertiary bone graft, wound dehiscence and bone sequestration are more common compared to primary and secondary bone graft (Amanat and Langdon, 1991). This is because, with aging, the healing potential decreases and the integration of the bone graft are no longer ideal, partly because the bone marrow is older and therefore has less regenerative capacity.

The optimal time for alveolar bone transplantation (ABT) has been long discussed in the literature. There is growing consensus that secondary bone grafting at 9–11 years of age, when the root development of the canine is one-half to one-third, provides the best results (Boyne and Sands, 1972; Turvey et al., 1984). Other factors may also be of interest as displayed in Table 1.

2. Materials and methods

The present review followed four stages of search strategy: (1) literature search, (2) study selection, (3) data removal, and (4) summarizing and writing the results. The pilot search led to the final research question and dictated the inclusion and exclusion criteria.

An electronic search was carried out via the PubMed (MEDLINE), ISI Web of Knowledge, Google Scholar, and Embase databases using five major keywords “cleft lip,” “cleft palate,” “canine impaction,” “unilateral cleft lip,” and “maxillary canine” in combination.

Studies that met the following inclusion criteria were subsequently included: (1) papers published in English language over the past 40 years, (2) study participants with maxillary canine impaction in the unilateral cleft lip and palate, (3) studies reporting on canine impaction and cleft lip and palate, and (4) no age limit was applied, so studies of children and adults with unilateral cleft lip and palates and canine impaction were included.

Duplicate studies were removed. The exclusion criteria to filter the studies were (1) articles in languages other than English, (2) any gray literature, (3) non-peer reviewed articles, and

(4) articles that did not focus on maxillary canine impaction in cleft lip and palate patients.

Screening and study selection were done by the author (AA). First, the abstract and titles of the studies were screened superficially. Studies meeting the research questions were selected for full review. Then full text review studies meeting the predefined inclusion and exclusion criteria were shortlisted. Data extraction for each included study was done on data extraction forms recording the main finding and characteristics of the study. To minimize examiner, bias a dental colleague (orthodontist) was also asked to do final screening independently. Any disagreement was resolved by discussion between the two and a consensus was achieved. The online search was supplemented by hand searching and examining the bibliography of studies shortlisted according to the inclusion criteria.

Endnote Citation Manager X9 was used to file the studies according to database, duplicates, initial screening, and final inclusion. The complete process according to the PRISMA guidelines is presented in Fig. 1.

3. Results

The search strategy retrieved 278 studies, and only 1 study was eligible through other sources. After removing duplicates ($n = 58$), 221 studies were scrutinized for title and abstract and 54 were shortlisted for full text review. Following the discussion and review, 22 studies were included in the final list (Fig. 1).

The studies significant to this review are critically analyzed and summarized in Table 2. A total of 22 articles were included. These articles were published from 1981 to 2010. Most of the studies on maxillary canine impaction in the unilateral cleft lip and palate patients were older. The articles included had a quantitative study design and the samples of study participants ranged from 340 to 18. One-third of the articles used retrospective study design to validate the age of alveolar grafting in cleft patients (Troxell et al., 1982; Turvey et al., 1984; Dempf et al., 2002; Eldeeb et al., 1986; Amanat and Langdon, 1991). The general characteristics discussed in the final studies included the relevant age of bone graft in cleft patients, the advantages of alveolar bone grafting and canine exposure, and planning orthodontic treatment in accordance with midfacial growth in cleft palate patients.

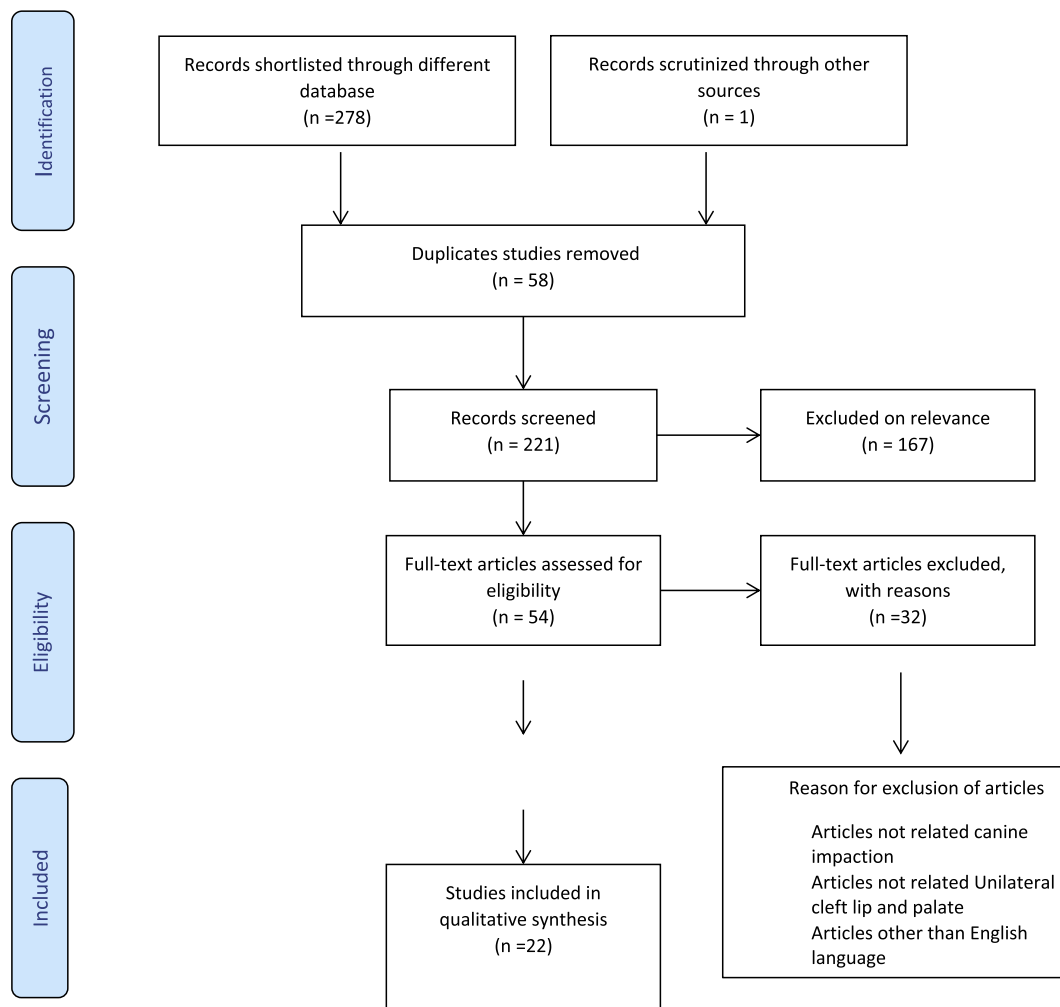


Fig. 1 Prisma flow chart.

4. Discussion

Surgical exposure is required when radiographically clear deviations from the direction and location of the permanent canine can be demonstrated after SABB or when there is resorption of the adjacent teeth or cystic radiolucency around the canine tooth (Matsui et al., 2005).

Maxillary canine impaction in UCLP patients is still under investigation and to date there have been few split-mouth studies. The occurrence of surgical exposure has already been reported by several authors (Table 2). There is a substantial disparity among the reported studies related to surgical procedures and canine impaction in UCLP patients.

A strong variation in these results persists and can be explained by various reasons. Foremost, the procedural and surgical techniques vary between different centers. A study by Enemark et al. (2001) attributed the effect of primary surgical procedures to a high percentage in impacted canines, that is, 35% of the cases required surgery. Similarly, Eldeeb et al. (1986) reported a high percentage of surgically exposed canines. Both authors admitted that this percentage is an underestimation of the number of spontaneous eruptions, as they chose surgical exposure over waiting for a spontaneous

delayed eruption as the former is more convenient and time saving.

A study by Tortora et al. (2008) investigated the success of early secondary gingival alveoplasty (ESGAP) at 2–3 years of age, with simultaneous closure of the hard palate. In this study, 15.5% of the canine teeth showed impaction, of which 4.4% were exposed surgically. This number was higher than studies by McCanny and Roberts-Harry (1998), Dempf et al. (2002), and Hogan et al. (2003) after SABB. The results of research by Tortora et al. (2008) illustrated that early closing of the alveolar ridge may be responsible for less space for the canine to erupt spontaneously. Other authors Vichi and Franchi (1995), Russell and McLeod (2008), Celikoglu et al. (2015) reported a higher impaction percentage, because of which Tortora et al. (2008) stated that ESGAP does not have an adverse effect on angle eruption (Table 2).

Hinrichs and Novak (2012) and Bergland et al. (1986a, 1986b) reported that the anatomy of the alveolar ridge was the reason for canine impaction. Muco-buccal and muco-labial patches do not satisfy, in contrast to a mucogingival patch. Muco-buccal and muco-labial patches persist as soft and red tissues that form resilient obstacles to the erupting tooth.

Table 2 Description of studies that have reported the frequency of maxillary canine exposure on cleft lip and palate patients.

Authors	Year of study	Type clefts		N	Gender		Age of bone graft	Spontaneous eruption	Surgical exposure
		BC	UC		Male	Female			
Kwon et al.	1981	35	64	99	62	37	7–11 yrs	73%	27%
El Deeb et al.	1982	18	28	46	32	14	7–14 yrs	17.9%	82% (14% exposed, 67.9% exposed + orthodontic traction)
Troxell et al.	1982	4	26	30	14	16	7–26 yrs	95%	0%
Turvey et al.	1984	9	15	24	13	11	7.3–25.4 yrs	95%	5%
Hinrichs et al. (1984)	1984	–	18	18	10	8	7.3–13.9 yrs	44%	56%(11.1% exposed, 44.4% exposed + orthodontic traction)
Enemark et al.	1985	–	62	62		/	8.6–15.11 yrs	50%	8.1%
El Deeb et al.	1986	18	8	26	17	9	7–13 yrs	41%	59%
Bergland et al.	1986	49	291	340	218	122	8–17 yrs	85%	15%
Bergland et al.	1986	41	–	41	25	16	8.9–17.4 yrs	95%	5%
Enemark et al. (1987)	1987	44	151	224	153	71	Canine not erupted at 10 yrs Canine erupted through: graft 13 yrs.10 mths	–	30%
Paulin et al.	1988	13	54	67	–	–	37 patients, Canine not erupted at ABT: 8–14 yrs 30 patients, Canine erupted through at ABT: 10–20 yrs	93%	7%
Amanat & Langdon	1991	13	21	34	23	11	7–24 yrs	–	2.1%
McCanny & Roberts-Harry	1998	12	17	29	7 group A 8 group B	9 group A 5 group B	Group A: 9–39 yrs Group B: 7–25 yrs	Group A: 43.5% Group B: 44.5%	Group A: 8.7% Group B: 5.5%
Da Silva Filho et al.	2000	–	UCL:12	50	32	18	–	72%	6%
Enemark et al.	2001	–	UCLP:101	101	72	29	Mandibular bone: 8.10–11.8 yrs Hip bone 8.8–12.4 yrs	68% 65%	32% 35%
van der Wal & van der Meulen	2001	11	51	62	–	–	8.6–12.8	77%	20%
Dempf et al.	2002	49	UC:42	91	–	–	SABT: 10.6 Tertiary graft: 21.3	100%	0%
Hogan et al.	2003	11	UC:23	34	19	15	8.5–18.4	92%	8%
Matsui et al.	2005		UC:340	340	98	142	Canine not erupted at SABT: 9.1 yrs	78.9%	Canine not erupted at SABT: 18.9%
Russel & McLeod	2008	48	UC:53	101	–	–	78 early SABT: 5–8.9 23 late SABT: 9.3–16.9		20-time higher risk compared to general population
Tortora et al.	2008	29	UC:87	116	–	–	UCLP: 18–55 months BCLP: 20–63 months	80%	4.4%
Oberoi et al.	2010	4	UC:12	21	12	9	10. 6	88%	12%

BC = bi-lateral cleft, UC = unilateral clefts, CLA = cleft lip and alveolar ridge, CLAP = cleft alveolar ridge and palate.

Damage to the periodontal ligaments during the surgical procedure leads to necrosis, resulting in the resorption and ankylosis of the tooth (Andreasen and Ravn, 1972). Moreover, each sample is unique with individual characteristics, just as each cleft lip palate is unique. For example, surgical exposure was more frequent in patients with both a cleft alveolar ridge and palate compared to patients with only a cleft alveolar ridge, more often with a bilateral cleft than unilateral. The width of the defect also plays a vital role (Matsui et al., 2005). Interestingly, it was also observed that alveolar cleft width increased significantly in patients who underwent surgical exposure compared to those who had spontaneous eruption (Nishihara et al., 2014).

4.1. Canine impaction as a complication after bone graft

The role of secondary and late secondary bone grafts has been evaluated by many studies and has a negative impact on canine eruption (Sindet-Pedersen and Enemark, 1985). Russell and McLeod (2008) documented that SABG before canine eruption may lead to canine impaction. Similarly, alveolar bone grafts and maxillary expansion (before or after bone grafts) increased the chance of spontaneous eruption of the permanent maxillary canine (El et al., 1982; Russell and McLeod, 2008). However, Matsui et al. (2005) found that increasing the width of the alveolar cleft increases the risk of permanent canine impaction. Moreover, Gereltzul et al. (2005) reported that the gap in the eruption path of the canine enhances the chances of canine impaction. A recent study by Kleinpoort et al. (2017) found that early secondary alveolar bone grafting after maxillary expansion before the eruption of the permanent incisor did not increase the risk of permanent maxillary canine impaction (Kleinpoort et al., 2017).

4.2. Role of agenesis and malformation of the lateral incisor in canine impaction

Bone and soft tissue defects in UCLP patients have increased the incidence of dental abnormalities, that is, supernumerary, agenesis, and malformed lateral incisors (Dewinter et al., 2003). Several authors believed that the absence or malformation of the lateral incisor or the presence of a supernumerary element influences the eruption of the adjacent canine tooth (Vichi and Franchi, 1995; Russell and McLeod, 2008; Celikoglu et al., 2015; Amanat and Langdon, 1991; Bergland et al., 1986a, 1986b).

However, according to Russell and McLeod (2008), the chances of canine impaction are higher when the lateral incisor is missing, supernumerary, or malformed. Vichi and Franchi (1995), Enemark et al. (2001), and Enemark et al. (2001) documented a greater risk of canine retention if the lateral incisor was congenitally absent. In contrast, other authors deny that the lateral incisor is significant for guiding the canine (Tortora et al., 2008; Paulin et al., 1988; Troxell et al., 1982; Oberoi et al., 2010). Moreover, Gereltzul et al. (2005) and Kleinpoort et al. (2017) reported that there was no effect of the lateral incisors on the impaction of the maxillary canines. Other studies (Meazzini et al., 2008; Oberoi et al., 2010; Kleinpoort et al., 2017; Turvey et al., 1984; Kwon et al., 1981; Bergland et al., 1986a, 1986b) found that agenesis of the lateral incisor does not increase the risk of canine impac-

tion in UCLP and has no role in the process of canine eruption while the supernumerary teeth play a significant role.

From the aforementioned discussion, it is quite evident that disparities exist among different studies. At present, there is no clear consensus on the ideal age of bone grafting in UCLP patients. However, most of the available evidence supports secondary bone grafts at 9–11 years of age, when the root development of the canine is one-half to one-third. Furthermore, whether bone grafting is necessary, or one should wait for the spontaneous eruption of the canine remains vague and unclear. Therefore, in the authors' opinion, in today's rapidly advancing medical field, one optimal treatment plan to adhere to when treating canine impaction in patients with cleft lip and palate is not possible.

5. Future recommendations

Clinically speaking, based on the results of this literature review, interventional study designs are suggested with larger sample sizes. Also, studies assessing unilateral cleft patients' effect on oral health related quality of life (OHRQOL) should be explored. Finally, the use of dental lasers to treat cleft lip and palate patients should be assessed.

Treating UCLP patients is a multidisciplinary approach and clear guidelines at the international level should be established considering the guidance and expertise of oral surgeons, orthodontists, prosthodontists, and public health professionals.

6. Conclusion

Within the limitations of the present study, secondary bone grafts at 9–11 years of age, when the root development of the canine is one-half to one-third, provides better results. In accordance with the available evidence in the present study, every patient is different and treatment options vary according to the characteristics, subjective response, and variability of the malformation.

Conflict of interest

There was no conflict of interest to declare.

Ethical statement

There is no ethical statement to declare

Acknowledgement

This project was supported by the Deanship of Scientific Research at Prince Sattam Bin Abdulaziz University under the research project 2016/03/5678.

References

- Akcam, M.O., Evrigen, S., Uslu, O., Memikoğlu, U.T., 2010. Dental anomalies in individuals with cleft lip and/or palate. *Eur. J. Orthod.* 32, 207–213.
- Alqerban, A., Jacobs, R., Lambrechts, P., Loozen, G., Willems, G., 2009. Root resorption of the maxillary lateral incisor caused by

- impacted canine: a literature review. *Clin. Oral. investigations*. 13:247–255.
- Algerban, A., Storms, A.S., Voet, M., Fieuws, S., Willems, G., 2016. Early prediction of maxillary canine impaction. *Dentomaxillofac Radiol. Invest.* 45, 20150232.
- Amanat, N., Langdon, J.D., 1991. Secondary alveolar bone grafting in clefts of the lip and palate. *J. Craniomaxillofac Surg.* 19, 7–14.
- Andreasen, J., Ravn, J., 1972. Epidemiology of traumatic dental injuries to primary and permanent teeth in a Danish population sample. *Inter. J. Oral Surg.* 1, 235–239.
- Baccetti, T., Leonardi, M., Armi, P., 2008. A randomized clinical study of two interceptive approaches to palatally displaced canines. *Eur. J. Orthod.* 30, 381–385.
- Bergland, O., Semb, G., Abyholm, F., Borchgrevink, H., Eskeland, G., 1986a. Secondary bone grafting and orthodontic treatment in patients with bilateral complete clefts of the lip and palate. *Ann. Plast. Surg.* 17, 460–474.
- Bergland, O., Semb, G., Abyholm, F.E., 1986b. Elimination of the residual alveolar cleft by secondary bone grafting and subsequent orthodontic treatment. *Cleft. Palate J.* 23, 175–205.
- Bishara, S.E., 1992. Impacted maxillary canines: a review. *Am. J. Orthod. Dentofacial Orthop.* 101, 159–171.
- Boyne, P.J., Sands, N.R., 1972. Secondary bone grafting of residual alveolar and palatal clefts. *J. Oral Surg.* 30, 87–92.
- Celikoglu, M., Buyuk, S., Sekerci, A., Cantekin, K., Candirli, C., 2015. Maxillary dental anomalies in patients with cleft lip and palate: a cone beam computed tomography study. *J. Clin. Pediat. Dent.* 39, 183–186.
- da Silva Filho, O.G., Teles, S.G., Ozawa, T.O., Filho, L.C., 2000. Secondary bone graft and eruption of the permanent canine in patients with alveolar clefts: literature review and case report. *Angle Orthod.* 70, 174–178.
- Dempf, R., Teltzrow, T., Kramer, F.-J., Hausamen, J.-E., 2002. Alveolar bone grafting in patients with complete clefts: a comparative study between secondary and tertiary bone grafting. *Cleft Palate-craniofacial J.* 39, 18–25.
- Derijcke, A., Eerens, A., Carels, C., 1996. The incidence of oral clefts: a review. *Br. J. Oral. Maxillofac Surg.* 34, 488–494.
- Dewinter, G., Quiryne, M., Heidebuchel, K., Verdonck, A., Willems, G., Carels, C., 2003. Dental abnormalities, bone graft quality, and periodontal conditions in patients with unilateral cleft lip and palate at different phases of orthodontic treatment. *Cleft Palate Craniofac J.* 40, 343–350.
- El, M.D., Messer, L., Lehnert, M., Hebda, T.W., Waite, D., 1982. Canine eruption into grafted bone in maxillary alveolar cleft defects. *Cleft Palate J.* 19, 9–16.
- Eldeeb, M.E., Hinrichs, J.E., Waite, D.E., Bandt, C.L., Bevis, R., 1986. Repair of alveolar cleft defects with autogenous bone grafting: periodontal evaluation. *Cleft Palate J.* 23, 126–136.
- Enemark, H., Jensen, J., Bosch, C., 2001. Mandibular bone graft material for reconstruction of alveolar cleft defects: long-term results. *Cleft Palate Craniofac J.* 38, 155–163.
- Enemark, H., Krantz-Simonsen, E., Schramm, J.E., 1985. Secondary bonegrafting in unilateral cleft lip palate patients: indications and treatment procedure. *Int. J. Oral Surg.* 14, 2–10.
- Enemark, H., Sindet-Pedersen, S., Bundgaard, M., 1987. Long-term results after secondary bone grafting of alveolar clefts. *J. Oral Maxillofac Surg.* 45, 913–919.
- Ericson, S., Kurol, J., 1987. Radiographic examination of ectopically erupting maxillary canines. *Am. J. Orthod. Dentofacial Orthop.* 91, 483–492.
- Ericson, S., Kurol, J., 1988. Resorption of maxillary lateral incisors caused by ectopic eruption of the canines. A clinical and radiographic analysis of predisposing factors. *Am. J. Orthod. Dentofacial Orthop.* 94, 503–513.
- Fleming, P.S., Scott, P., Heidari, N., Dibiase, A.T., 2009. Influence of radiographic position of ectopic canines on the duration of orthodontic treatment. *Angle Orthod.* 79, 442–446.
- Fudalej, P., Janiszewska-Olszowska, J., Wedrychowska-Szulc, B., Katsaros, C., 2011. Early alveolar bone grafting has a negative effect on maxillary dental arch dimensions of pre-school children with complete unilateral cleft lip and palate. *Orthod. Craniofacial Res.* 14, 51–57.
- Gereltzul, E., Baba, Y., Ohyama, K., 2005. Attitude of the canine in secondary bone-grafted and nongrafted patients with cleft lip and palate. *Cleft Palate Craniofac J.* 42, 679–686.
- Hinrichs, J., Novak, M., 2012. Classification of diseases and conditions affecting the periodontium. Carranza's Clinical Periodontology. Reed Elsevier India Private Limited, New Delhi.
- Hinrichs, J.E., el-Deeb, M.E., Waite, D.E., Bevis, R.R., Bandt, C.L., 1984. Periodontal evaluation of canines erupted through grafted alveolar cleft defects. *J. Oral Maxillofac Surg.* 42, 717–721.
- Hogan, L., Shand, J., Heggie, A., Kilpatrick, N., 2003. Canine eruption into grafted alveolar clefts: a retrospective study. *Aust. Dent. J.* 48, 119–124.
- Jabbari, F., Reiser, E., Thor, A., Hakelius, M., Nowinski, D., 2016. Correlations between initial cleft size and dental anomalies in unilateral cleft lip and palate patients after alveolar bone grafting. *Uppsala J. Med. Sci.* 121, 33–37.
- Jia, Y., Fu, M., Ma, L., 2006. Long-term outcome of secondary alveolar bone grafting in patients with various types of cleft. *Br. J. Oral Maxillofac Surg.* 44, 308–312.
- Katsnelson, A., Flick, W.G., Susarla, S., Tartakovsky, J.V., Miloro, M., 2010. Use of panoramic x-ray to determine position of impacted maxillary canines. *J. Craniomaxillofac Surg.* 68, 996–1000.
- Kleinpoort, F., Ferchichi, H., Belkhou, A., Tramini, P., Bigorre, M., Capter, G., 2017. Early secondary bone grafting in children with alveolar cleft does not modify the risk of maxillary permanent canine impaction at the age of 10 years. *J. Craniomaxillofac Surg.* 45, 515–519.
- Kuijpers-Jagtman, A., 2006. The orthodontist, an essential partner in CLP treatment. *B ENT*, 57.
- Kwon, H.J., Waite, D.E., Stickel, F.R., Chisholm, T., McParland, F., 1981. The management of alveolar cleft defects. *J. Am. Dent. Assoc.* 102, 848–853.
- Leonardi, M., Armi, P., Franchi, L., Baccetti, T., 2004. Two interceptive approaches to palatally displaced canines: a prospective longitudinal study. *Angle Orthod.* 74, 581–586.
- Lilja, J., Kalaaji, A., Friede, H., Elander, A., 2000. Combined bone grafting and delayed closure of the hard palate in patients with unilateral cleft lip and palate: facilitation of lateral incisor eruption and evaluation of indicators for timing of the procedure. *Cleft Palate Craniofac J.* 37, 98–105.
- Lindauer, S.J., Rubenstein, L.K., Hang, W.M., Andersen, W.C., Isaacson, R.J., 1992. Canine impaction identified early with panoramic radiographs. *J. Am. Dent. Assoc.* 123, 95–97.
- Litsas, G., Acar, A., 2011. A review of early displaced maxillary canines: etiology, diagnosis and interceptive treatment. *Open Dent. J.* 5, 39–47.
- Long Jr., R.E., Paterno, M., Vinson, B., 1996. Effect of cuspid positioning in the cleft at the time of secondary alveolar bone grafting on eventual graft success. *Cleft Palate-Craniofacial J.* 33, 225–230.
- Lorenzoni, D.C., Janson, G., Bastos, J.C., Carvalho, R.M., Bastos, J. C., Lauris, R.C.M.C., Henriques, J.F.C., Ozawa, T.O., 2017. Evaluation of secondary alveolar bone grafting outcomes performed after canine eruption in complete unilateral cleft lip and palate. *Clin. Oral Invest.* 21, 267–273.
- Matsui, K., Echigo, S., Kimizuka, S., Takahashi, M., Chiba, M., 2005. Clinical study on eruption of permanent canines after secondary alveolar bone grafting. *Cleft Palate Craniofac J.* 42, 309–313.
- McCanny, C.M., Roberts-Harry, D.P., 1998. A comparison of two different bone-harvesting techniques for secondary alveolar bone grafting in patients with cleft lip and palate. *Cleft Palate Craniofac J.* 35, 442–446.

- Meazzini, M.C. et al, 2008. Comparison of growth results in patients with unilateral cleft lip and palate after early secondary gingivoalveoloplasty and secondary bone grafting: 20 years follow up. *Scand. J. Plast. Reconstr. Surg. Hand Surg.* 42 (6), 290–295.
- Nishihara, K., Nozoe, E., Maeda, A., Hirahara, N., Okawachi, T., Miyawaki, S., Nakamura, N., 2014. Outcome following secondary autogenous bone grafting before and after canine eruption in patients with unilateral cleft lip and palate. *Cleft Palate-Craniofacial J.* 51, 165–171.
- Oberoi, S., Gill, P., Chigurupati, R., Hoffman, W.Y., Hatcher, D.C., Vargervik, K., 2010. Three-dimensional assessment of the eruption path of the canine in individuals with bone-grafted alveolar clefts using cone beam computed tomography. *Cleft Palate-craniofac J.* 47, 507–512.
- Ozawa, T., Omura, S., Fukuyama, E., Matsui, Y., Torikai, K., Fujita, K., 2007. Factors influencing secondary alveolar bone grafting in cleft lip and palate patients: prospective analysis using CT image analyzer. *Cleft Palate Craniofac J.* 44, 286–291.
- Paulin, G., Astrand, P., Rosenquist, J.B., Bartholdson, L., 1988. Intermediate bone grafting of alveolar clefts. *J. Craniomaxillofac Surg.* 16, 2–7.
- Power, S.M., Short, M.B., 1993. An investigation into the response of palatally displaced canines to the removal of deciduous canines and an assessment of factors contributing to favourable eruption. *Br. J. Orthod.* 20, 215–223.
- Russell, K.A., McLeod, C.E., 2008. Canine eruption in patients with complete cleft lip and palate. *Cleft Palate Craniofac J.* 45, 73–80.
- Sajani, A.K., King, N.M., 2012. Early prediction of maxillary canine impaction from panoramic radiographs. *Am. J. Orthod. Dentofacial Orthop.* 142, 45–51.
- Shashua, D., Omnell, M.L., 2000. Radiographic determination of the position of the maxillary lateral incisor in the cleft alveolus and parameters for assessing its habilitation prospects. *Cleft Palate Craniofac J.* 37, 21–25.
- Sindet-Pedersen, S., Enemark, H., 1985. Comparative study of secondary and late secondary bone-grafting in patients with residual cleft defects. Short-term evaluation. *Int. J. Oral Surg.* 14, 389–398.
- Tortora, C., Meazzini, M.C., Garattini, G., Brusati, R., 2008. Prevalence of abnormalities in dental structure, position, and eruption pattern in a population of unilateral and bilateral cleft lip and palate patients. *Cleft Palate Craniofac J.* 45, 154–162.
- Troxell, J.B., Fonseca, R.J., Osbon, D.B., 1982. A retrospective study of alveolar cleft grafting. *J. Oral Maxillofac Surg.* 40, 721–725.
- Turvey, T.A., Vig, K., Moriarty, J., Hoke, J., 1984. Delayed bone grafting in the cleft maxilla and palate: a retrospective multidisciplinary analysis. *Am. J. Orthod.* 86, 244–256.
- Van der Wal, K., van der Meulen, B., 2001. Eruption of canines through alveolar bone grafts in cleft lip and palate. *Nederlands tijdschrift voor tandheelkunde.* 108, 401–405.
- Vichi, M., Franchi, L., 1995. Abnormalities of the maxillary incisors in children with cleft lip and palate. *ASDC J. Dent. Child* 62, 412–417.
- Warford Jr., J.H., Grandhi, R.K., Tira, D.E., 2003. Prediction of maxillary canine impaction using sectors and angular measurement. *Am. J. Orthod. Dentofac. Orthop.* 124, 651–655.