

Malignant Degeneration of Scars

This article was published in the following Dove Press journal:
Cancer Management and Research

Anca E Chiriac¹
Mircea Betiu²
Piotr Brzezinski^{3,4}
Beatriz Di Martino Ortiz⁵
Anca Chiriac⁶⁻⁸
Liliana Foia⁹
Doina Azoicai¹

¹Department of Epidemiology, Faculty of Medicine, "Grigore T. Popa" University of Medicine and Pharmacy, Iași, Romania;

²Department of Dermatovenereology, Faculty of Medicine, "Nicolae Testemitanu" State University of Medicine and Pharmacy, Kishinev, Republic of Moldova; ³Department of Physiology and Cosmetology, Institute of Biology and Environmental Protection, Pomeranian Academy, Slupsk, Poland, ⁴Department of Dermatology, Provincial Specialist Hospital in Slupsk, Ustka, Poland, Military Support Unit, Ustka, Poland; ⁵Dermatology Department, Clinicas Hospital, Faculty of Medical Sciences, National University of Ausunción-Paraguay, ⁶Department of Dermatology, Nicolina Medical Center, Iasi, Romania; ⁷Department of Dermatophysiology, "Apollonia" University, Iasi, Romania; ⁸"P. Poni" Institute of Macromolecular Chemistry, Romanian Academy, Iasi, Romania; ⁹Department of Surgery, Faculty of Dentistry, "Grigore T. Popa" University of Medicine and Pharmacy, Iași, Romania

Abstract: "Marjolin's ulcer" is known as malignant degeneration of ancient burn scars, but both words can induce misdiagnosis. Malignant degeneration of scarring tissue can occur and can vary in its clinical, histological manifestations and its pre-existing skin lesions. We present several cases to substantiate our observations. "Marjolin's ulcer" is not synonym to an ulceration appeared on an old burn scar, transformed into squamous cell carcinoma.

Keywords: ulcer, Marjolin, malignant degeneration, scar

Introduction

In 1828 a French surgeon Jean Nicholas Marjolin described atypical changes in burn scars; since then, in daily practice, it has been frequently used the diagnosis of "Marjolin's ulcer".

Marjolin's ulcer occurs in 1–2% of burn scars and, classically, is a form of squamous cell carcinoma (SCC).^{1,2} The latency between initial scar and malignant degeneration can vary between 2 and 25 years, with an average of approximately 8 years.² Although malignancy can occur on previous other type of skin injury, most cases described in the literature highlights the presence of skin ulceration on the inferior limbs in male patients, as initial step in malignancy.³ Flame burns were reported with highest incidence, followed by local trauma.⁴

Its definition involves the notion of chronicity and latency, but recently, it has emerged the notion of acute Marjolin's ulcer, representing only 7% of all cases.⁵ More data are needed to clarify the idea of malignancy occurring during wound healing.

Marjolin's ulcer is characterised as a unique lesion, however the concept of "multiple synchronous Marjolin ulcers" have been reported in recent years.⁶

Marjolin's ulcer is rare in daily practice and represents only 2% of all SCCs.⁷

We present case series of patients diagnosed with Marjolin's ulcers, that do not fulfil the standard criteria: old scar+ ulceration+ malignant degeneration into SCC.

Case 1

A 77-year-old fair skin male patient was referred to Plastic Surgery for excision of two "Marjolin's ulcers". The diagnosis has been issued by a dermatologist, who described clinically, two small ulcerations, with delicate rims and indurated bases, emerged within the margins of a large scar on the right nasal wing. The scar was, in fact, an old cutaneous flap, round shaped and well delineated, achieved decades ago subsequent to a caustic burn (Figure 1).

Large excision was made and pieces sent to Pathology. Histologic examination described: islands and nests of basaloid cells, with palisading of the cells at the periphery and a haphazard arrangement of those cells in the centers of the islands;

Correspondence: Anca E Chiriac
Department of Epidemiology, Faculty of Medicine, "Grigore T. Popa" University of Medicine and Pharmacy, Iași, Romania
Email chiriacut@yahoo.com

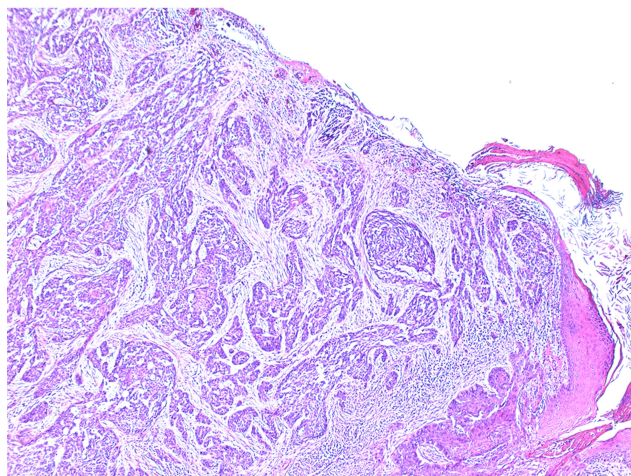
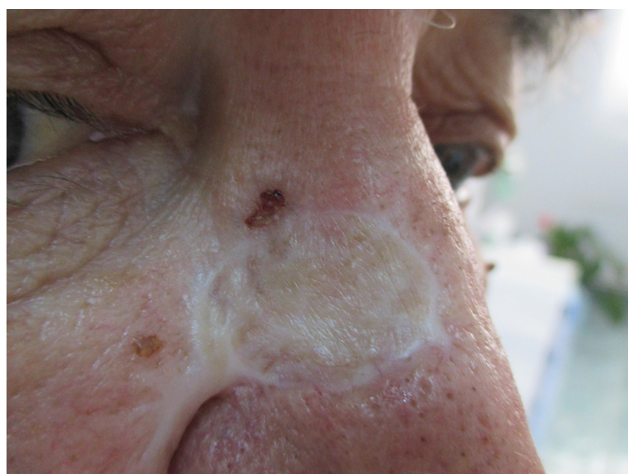

Figure 1 Photo image: two small ulcerations, with delicate rims and indurated bases, emerged within the margins of a large scar on the right nasal wing. Histologic image: Islands and nests of basaloid cells, with palisading of the cells at the periphery and a haphazard arrangement of those cells in the centers of the islands. The tumor cells have a hyperchromatic nucleus with relatively little, poorly defined cytoplasm. An inflammatory cell infiltrate is present. The epidermis is ulcerated (HE 10X).

the tumor cells with hyperchromatic nucleus and relatively little, poorly defined cytoplasm and inflammatory cell infiltrate (Figure 1).

Based on clinical and histologic grounds final diagnosis was basal cell carcinomas (BCCs) on sun exposed areas, within the limits of an old scar, in an elderly patient.

Case 1: old scar+ ulceration+ basal cell carcinoma (BCC).

Case 1 describes an ulceration occurred on an old scar, that proved to be, after histologic examination, basal cell carcinoma (BCC).

Case 2

A 64-year-old female retired nurse, with allergic background, has been treated for months for an eczematous-

like lesion, located on the right third digital pulp, on an area of severe scarring and contracture, induced by a critical burn, occurred three decades previously (Figure 2). She has been treated for chronic allergic contact dermatitis for the last two years, with systemic antihistamines and local potent steroids in combination with emollients, but with no improvement. Ultrasound

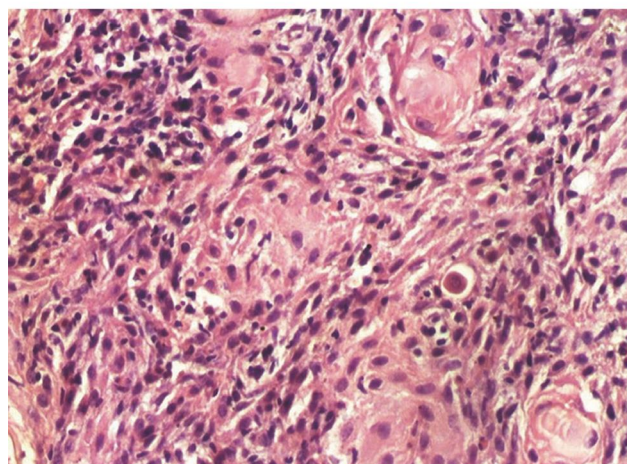
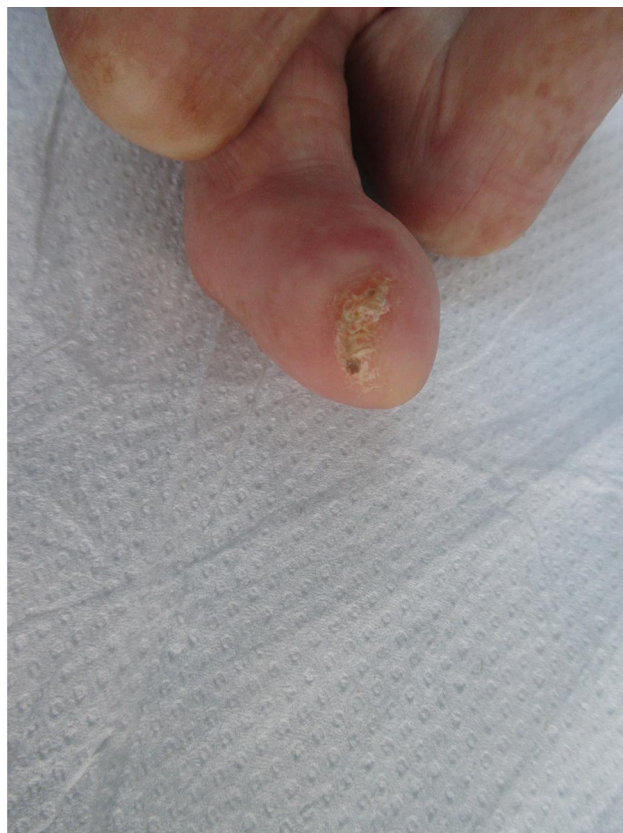

Figure 2 Photo image: Eczematous-like lesion, located on the right third digital pulp, on an area of severe scarring and contracture. Histologic image: Nests of squamous epithelial cells in the dermis. The cells have abundant eosinophilic cytoplasm and a large, vesicular nucleus. There is variable central keratinization and horn pearl formation. Individual cell keratinization is also present (HE 40X).

examination and radiology imaging were within normal limits, proving that only the skin was affected. A 4 mm punch biopsy was performed and sent for pathology report.

Histologic examination described: nests of squamous epithelial cells in the dermis, characterized by abundant eosinophilic cytoplasm and a large, vesicular, nucleus (Figure 2). Due to the diagnosis of squamous cell carcinoma (SCC) the amputation of the phalange was recommended and the patient was transferred to Oncology Department for follow-up.

Case 2: old scar+ typical malignant degeneration (into squamous cell carcinoma (SCC)+ no ulceration).

Case 2 describes a squamous cell carcinoma (SCC) appeared on an old scar, within the area of an eczema-like lesion, in the absence of ulceration.

Case 3

A 57-year-old male patient, treated for years for venous insufficiency and stasis dermatitis seek for medical advice for a small papule, surrounding by ulceration, within the limits of affected area, completely asymptomatic (Figure 3). He has been treated for months with emollients, potent steroids and antibiotics, but the lesion has continued to grow. A 4 mm punch biopsy was decided and done just from the ulcerative lesion. Histologic report was in favour of squamous cell carcinoma (SCC)-Figure 3 and the patient was transferred to Oncology for further evaluation and treatment.

Case 3: ulceration+ malignant degeneration into squamous cell carcinoma (SCC)-+ no scarring tissue

Case 3 describes malignant degeneration into squamous cell carcinoma (SCC) on a previous ulceration, but in the absence of any scar.

Case 4

A 65-year-old male patient addressed to the Plastic Surgery Department for a large ulceration, covered with pus and necrotic tissue, localized within the area of a large ancient burn scar (Figure 4). Surgical treatment allowed sampling for histologic examination which concluded malignant melanoma (Figure 4). Patient was transferred to Oncology for oncologic re-evaluation due to the diagnosis of melanoma.

Case 4: previous scar+ ulceration+ malignant degeneration into melanoma

Case 4 describes malignant degeneration into melanoma of a previous old scar, but no ulceration.

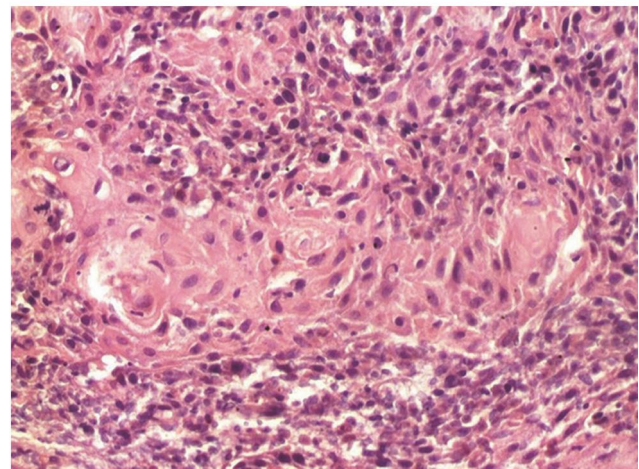
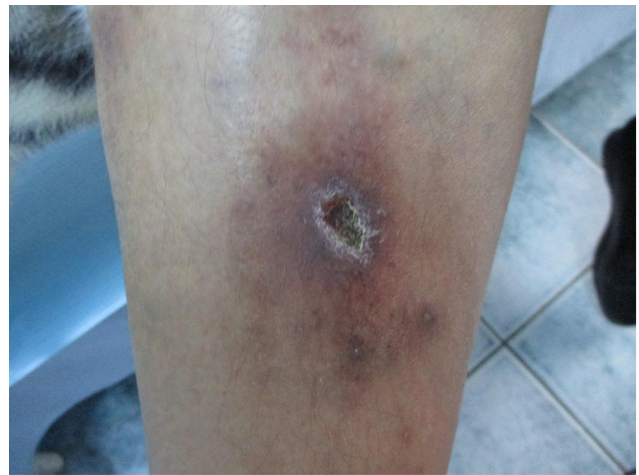

Figure 3 Photo image: Small papule, surrounding by ulceration within the area of stasis dermatitis. Histologic image: Nests of squamous epithelial cells in the dermis. The cells have abundant eosinophilic cytoplasm and a large, vesicular, nucleus. There is variable central keratinization and horn pearl formation. Individual cell keratinization is also present (HE 40X).

Case 5

A 52-year-old female patient seeks for advice and treatment for a persistent pruritus and eczema-like lesion, covered by crust, localized in the interscapular area, close to a small scar of unknown origin (Figure 5). Several diagnoses such as neurotic excoriations, chronic eczema, notalgia paresthetica, Marjolin's ulcer, were listed. Patient was in good health condition; usual lab investigations were within normal ranges. One-day hospitalization for a detailed examination could not find pathological changes. It was decided and performed a 4 mm punch biopsy from the erythematous squamous plaque. Histologic report described nodular histologic (solid) basal cell carcinoma (Figure 5).

Case 5: previous small scar+ no ulceration+ malignant degeneration into basal cell carcinoma (BCC).

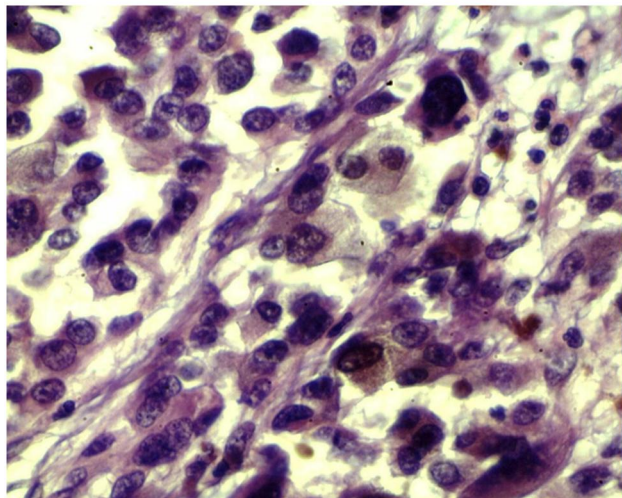
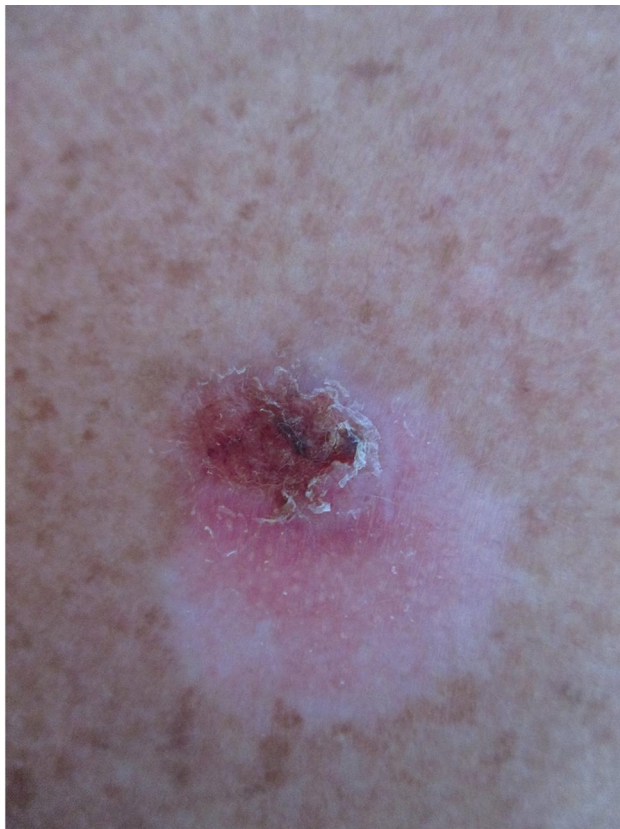

Figure 4 Photo image: Large ulceration, covered with pus and necrotic tissue, localized within the area of a large ancient burn scar on the thorax. Histologic image: The tumor cells in the dermis have large, hyperchromatic nuclei and hyperchromatic nucleoli often present. There is melanin present in the cells (HE 100X).

Case 5 describes malignant degeneration into basal cell carcinoma (BCC) on a previous small scar, but in the absence of ulceration.

Discussions

Marjolin's ulcer is a rare, aggressive skin cancer of previously injured skin, mostly scars and chronic wounds.

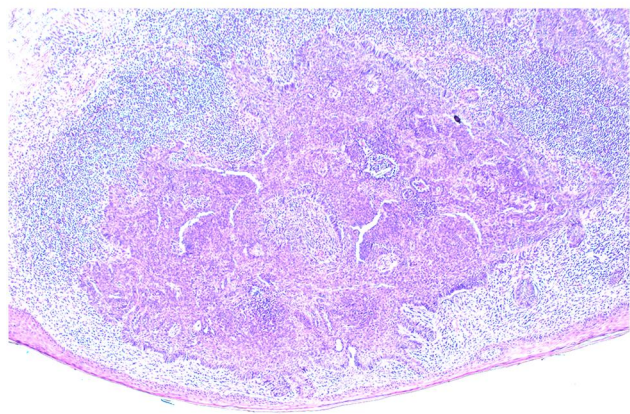
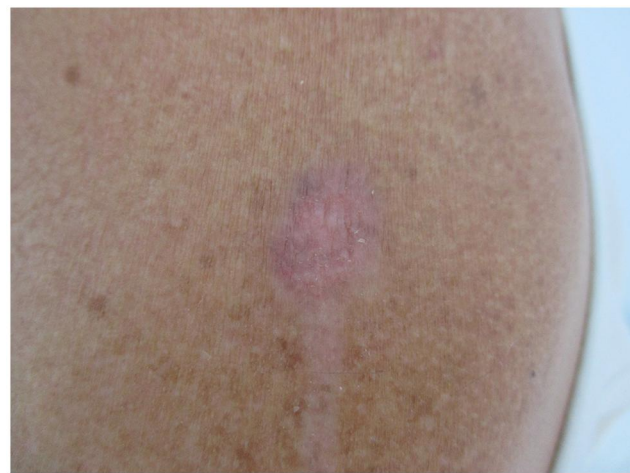

Figure 5 Photo image: Interscapular small scar and eczema-like lesion covered by crust. Histologic image: Nodular histologic (solid) basal cell carcinoma. Histological characteristics area similar to those described in photography number 1B. The epidermis is not ulcerated in this field. An inflammatory cell infiltrate is present (HE 40X).

Although Aurelius Cornelius Celsus was first author who noticed malignancy within a burn scar, later in 1833, Jean Nicolas Marjolin wrote: [...] The tumour ... makes its appearance in some old scar, many years after the injury which has produced it has been healed ... from a flogging or a scald In this stage it gives no pain nor inconvenience ... the growth of the tumour becomes more rapid, the warty appearance being in some measure lost, a more solid substance projecting from the diseased skin, which bears much resemblance to the fungus of fungus h ematodes. [...] the tumour ulcerates and sloughs alternately ... a foul excavated ulcer, except in its circumference, where the skin is raised, thickened, and everted ...^{8,9}

For the last decades, many published reports have described cases of neoplasms extended within the limits

of scars, chronic ulcerations and chronic inflammatory skin areas, complicating the simple initial definition of Marjolin's ulcer.

The rate of malignant transformation is estimated to be 1–2%.¹⁰

Malignant shift requires, in average, more than three decades of time after the initial injury, although sparse reports of cancer transformation of an acute ulcer within the first 12 months from skin wound have been declared. Searching all documented cases of Marjolin's ulcer, one can conclude that the interval between the initial skin wound, of any type, and malignant transformation have found to vary between 4 weeks to 75 years.¹¹

The terminology of “ulcer/ulceration” implies the notion of wound, but variable cases of so-called Marjolin's ulcer have been described clinically, as non-ulcerative lesions, such as chronic eczema-like plaques, keloids or simple papules spread on scarring tissue.

Moreover, malignant degenerations do not occur only on pre-existing burns, but also on other types of scars or chronic inflammatory skin lesions, such as venous stasis ulcers, amputations, frostbite, sting bites, osteomyelitis, post-traumatic wounds, chronic fistulas, decubitus ulcers, Fournier gangrene, hidradenitis suppurativa, vaccination sites, cutaneous lupus, all kind of scars, radiodermatitis and, recently, skin graft donor sites.^{12–15}

Histologic examinations of biopsies, collected from the lesions or excised samples, have proved that malignant degeneration was not only squamous cell carcinoma type (SCC), but also basal cell carcinoma (BCC) or even melanoma, and, rarely, variable types of sarcoma or mucoepidermoid carcinoma.⁷ It is admitted that SCC developed within scarring tissue is more aggressive than SCC of other aetiology, more profuse and with metastases to regional lymph nodes.¹⁶

Men are more often diagnosed with Marjolin's ulcer, and the location of this type of skin cancer could be, according to statistics, in descending order: lower extremities, upper limbs, gluteal region, face.¹⁷

An essential dispute focusses on the risk of malignant shift based on the type of pre-existing skin wound; it has been admitted that the highest risk belongs to burns, followed by non-healing post-traumatic skin lesions, venous leg ulcerations, fistulas and pressure sores.^{4,18}

Conclusions

The diagnosis of “Marjolin's ulcer”, in our opinion, should be avoided because it can create confusion. Malignant degeneration of scarring tissue should be the main concern

for patients and for their healthcare monitors. Any type of suspicious wound changes should be monitored and the lesion should be immediately biopsied. If malignancy is confirmed by histologic examination, staging and treatment are of outmost importance. In addition, long term post-treatment follow-up surveillance should be performed at regular intervals for recurrence.

Ethics

The study was approved by the Apollonia University Iasi Ethical Committee.

Consent

Written informed consent was obtained from the patient for publication of this case report and any accompanying images.

Disclosure

This article was prepared or completed by the authors within their personal capacities. The opinions expressed in this article are the authors' own and do not reflect the view of the National Institutes of Health. The authors declare no conflicts of interest in this work.

References

- Bazaliński D, Przybek-Mita J, Barańska B, Więch P. Marjolin's ulcer in chronic wounds – review of available literature. *Contemp Oncol.* 2017;21(3):197–202.
- Dávila Osorio VL, Méndez Gaviria L, Amador Patarroyo JR, González Coral MI. Marjolin ulcer: a report of 2 cases of squamous cell carcinoma arising from posttraumatic soft-tissue scarring. *Actas Dermosifiliogr.* 2020;111(1):81–83. doi:10.1016/j.ad.2018.06.025
- Xia C, Chu ZG. Clinical research on the expression of three vascular regulatory factors in different morphological regions of Marjolin ulcer and their relationship with angiogenesis. *Zhonghua Shao Shang Za Zhi.* 2019;35(9):676–682.
- Chaturvedi G, Gupta AK, Das S, Gohil AJ, Lamba S. Marjolin ulcer: an observational epidemiological study from a tertiary care centre in India. *Ann Plast Surg.* 2019;83(5):518–522. doi:10.1097/SAP.00000000001995
- Lebaschi AH, Hajirostam M, Keramati MR. Marjolin's ulcer: clinical and pathologic features of 83 cases and review of literature. *Med J Islam Repub Iran.* 2013;27(4):215–224.
- Hobbs M, Campbell E, Braun KA, Wong L. Multiple synchronous acute Marjolin ulcer: a report of 2 cases and literature review. *JAAD Case Rep.* 2019;5(6):511–513. doi:10.1016/j.jder.2019.04.002
- Copcu E. Marjolin's ulcer: a preventable complication of burns? *Plast Reconstr Surg.* 2009;124(1):156e–64e. doi:10.1097/PRS.0b013e3181a8082e
- Sharma A, Schwartz RA, Swan KG. Marjolin's warty ulcer. *J Surg Oncol.* 2011;103(2):193–195. doi:10.1002/jso.21783
- Hawkins C. On warty tumours in cicatrices. *Lond Med Gaz.* 1833;13:481–482.
- Chalya PL, Mabula JB, Rambau P, et al. Marjolin's ulcers at a university teaching hospital in Northwestern Tanzania: a retrospective review of 56 cases. *World J Surg Oncol.* 2012;10:38. doi:10.1186/1477-7819-10-38

11. Novick M, Gard DA, Hardy SB, Spira M. Burn scar carcinoma: a review and analysis of 46 cases. *J Trauma*. 1977;17(10):809–817. doi:10.1097/00005373-197710000-00010
12. Elkins-Williams ST, Marston WA, Hultman CS. Management of the chronic burn wound. *Clin Plast Surg*. 2017;44(3):679–687. doi:10.1016/j.cps.2017.02.024
13. Giesey R, Delost GR, Honaker J, Korman NJ. Metastatic squamous cell carcinoma in a patient treated with adalimumab for hidradenitis suppurativa. *JAAD Case Rep*. 2017;3(6):489–491. doi:10.1016/j.jdc.2017.08.017
14. Saaiq M, Ashraf B. Marjolin's ulcers in the post-burned lesions and scars. *World J Clin Cases*. 2014;2(10):507–514. doi:10.12998/wjcc.v2.i10.507
15. Sadegh Fazeli M, Lebaschi AH, Hajirostam M, Keramati MR. Marjolin's ulcer: clinical and pathologic features of 83 cases and review of literature. *Med J Islam Repub Iran*. 2013;27(4):215–224.
16. Kerr-Valentic MA, Samimi K, Rohlen BH, Agarwal JP, Rockwell WB. Marjolin's ulcer: modern analysis of an ancient problem. *Plast Reconstr Surg*. 2009;123(1):184–191. doi:10.1097/PRS.0b013e3181904d86
17. Zieliński T, Lewandowska M. Owrzodzenie Marjolina – nowotwór złośliwy rozwijający się na podłożu przewlekłych owrzodzeń i blizn. Analiza 8 przypadków [Marjolin's ulcer – malignancy developing in chronic ulcers and scars. Analysis of 8 cases]. *Przegl Dermatol*. 2010;97:38–42.
18. Trent JT, Kirsner RS. Wounds and malignancy. *Adv Skin Wound Care*. 2003;16(1):31–34. doi:10.1097/00129334-200301000-00014

Cancer Management and Research

Dovepress

Publish your work in this journal

Cancer Management and Research is an international, peer-reviewed open access journal focusing on cancer research and the optimal use of preventative and integrated treatment interventions to achieve improved outcomes, enhanced survival and quality of life for the cancer patient.

The manuscript management system is completely online and includes a very quick and fair peer-review system, which is all easy to use. Visit <http://www.dovepress.com/testimonials.php> to read real quotes from published authors.

Submit your manuscript here: <https://www.dovepress.com/cancer-management-and-research-journal>