

Ictal ^{99m}Tc -Ethyl Cysteinate Dimer SPECT Findings of a Girl With Refractory Localization-Related Epilepsy Who Developed Transient Ictal Bradycardia

Tomokazu Kimizu, MD¹, Hiromitsu Toshikawa, MD¹, Sadami Kimura, MD¹,
Tae Ikeda, MD¹, Yukiko Mogami, MD¹, Keiko Yanagihara, PhD¹,
Haruhiko Kishima, PhD², and Yasuhiro Suzuki, MD¹

Abstract

Ictal bradycardia, which is considered to be one of the causes of sudden unexplained death in epilepsy, is rare. A 10-year-old girl with focal cortical dysplasia in her right centroparietal region developed transient ictal bradycardia during cluster seizures. Brain magnetic resonance imaging demonstrated a high signal intensity lesion adjacent to the focal cortical dysplasia lesion. Ictal ^{99m}Tc -ethyl cysteinate dimer single-photon emission computed tomography (SPECT) detected hyperperfusion in an area containing the high signal intensity lesion, which was located close to the insular cortex. Since the hyperperfusion zone observed on SPECT was considered to reflect seizure propagation, it is possible that the ictal bradycardia experienced in the present case was caused by the following mechanism: The repetitive seizure activity caused the high-intensity lesion seen on MRI to expand into the right insular cortex, which controls cardiac rhythm, resulting in ictal bradycardia.

Keywords

ictal bradycardia, sudden unexplained death in epilepsy, cluster seizures, ictal SPECT, insular cortex

Received March 08, 2015. Received revised June 08, 2015. Accepted for publication June 16, 2015.

Sudden unexplained death in epilepsy is defined as a nontraumatic, non-drowning-related sudden unexplained death in a patient with epilepsy. Sudden unexplained death in epilepsy exhibits an incidence of about 1/1000 patient-years in adults, while it is much less common in children.¹ The risk factors for sudden unexplained death in epilepsy include a high seizure frequency, the presence of generalized tonic-clonic seizures, early-onset epilepsy, having suffered with epilepsy for a long period, antiepileptic drug therapy (polytherapy or abrupt changes in the antiepileptic drug used), a prolonged postictal state, and mental retardation.² The pathogenetic mechanisms of sudden unexplained death in epilepsy remain unclear. Most research into sudden unexplained death in epilepsy has focused on seizure-related respiratory depression, cerebral depression, autonomic dysfunction, and cardiac arrhythmia.

Changes in cardiac rhythm occur during most epileptic seizures. The most common form of cardiac arrhythmia experienced during epileptic seizures is sinus tachycardia, which occurs in over 90% of cases.³ Ictal tachycardia is usually

benign and of no consequence. On the contrary, ictal bradycardia is a rare event that affects <5% of patients with epilepsy.⁴ Although convincing evidence is lacking, it has been suggested that ictal bradycardia is one of the causes of sudden unexplained death in epilepsy. Here, the authors report the case of a girl with focal cortical dysplasia who developed transient ictal bradycardia during cluster seizures. Ictal bradycardia was defined as a heart rate of <60 beats/min during epileptic seizures.

¹ Department of Pediatric Neurology, Osaka Medical Center and Research Institute for Maternal and Child Health, Osaka, Japan

² Department of Neurosurgery, Osaka University Graduate School of Medicine, Osaka, Japan

Corresponding Author:

Tomokazu Kimizu, MD, Department of Pediatric Neurology, Osaka Medical Center and Research Institute for Maternal and Child Health, 840 Murodo-cho, Izumi, Osaka 594-1101, Japan.

Email: tk_in_the_sea@yahoo.co.jp



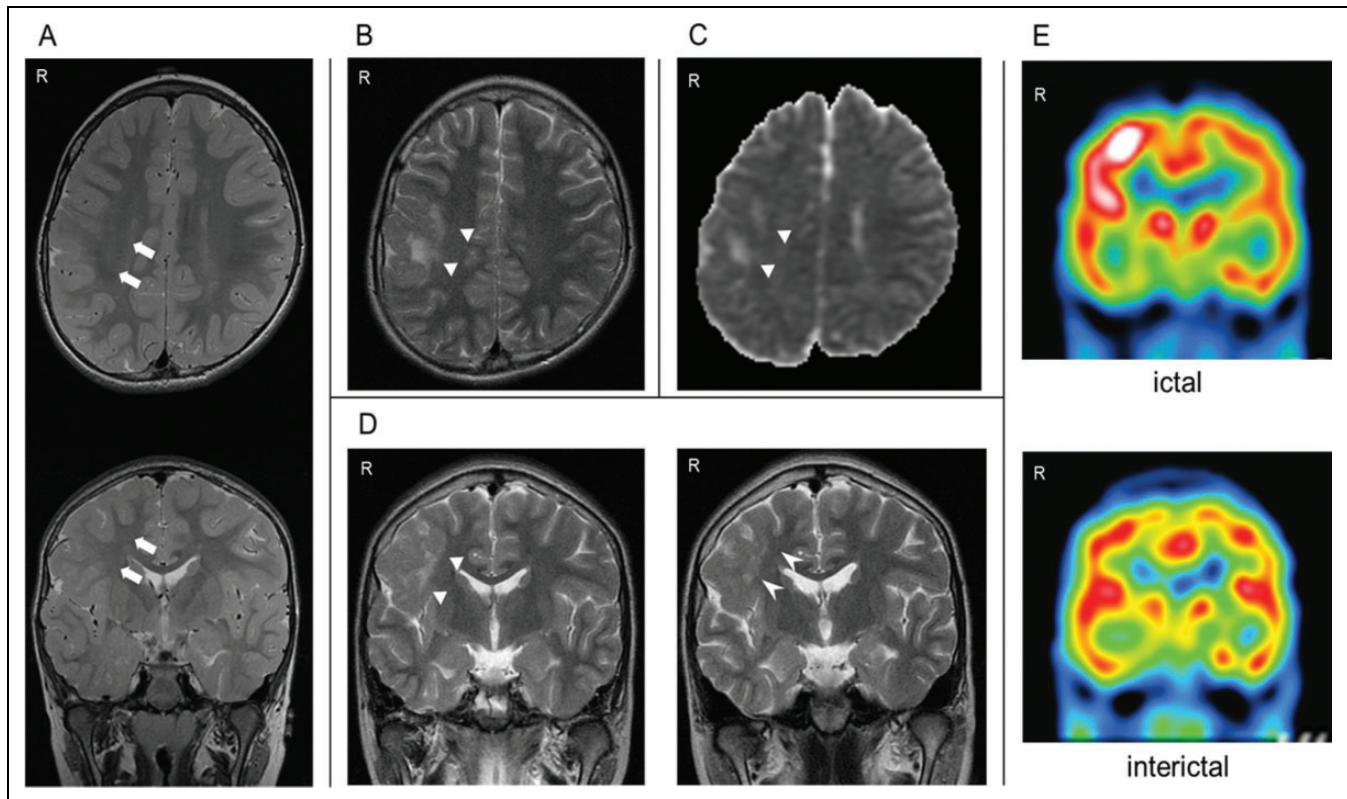


Figure 1. A, At the age of 3 years, a T2-weighted MRI scan showed focal cortical dysplasia in the right centroparietal region (↔). There were no high signal intensity lesions at this time. B, On day 2 after admission, a T2-weighted MRI image showed a high signal intensity lesion (▲) adjacent to the focal cortical dysplasia lesion. C, Apparent diffusion coefficient mapping also showed a high signal intensity lesion in the same region. D, The high signal intensity lesion (▲) was located close to the right insular cortex (left). On day 69, the high signal intensity lesion had diminished in size, and the patient's cluster seizures had improved (right). E, On day 27, ictal ^{99m}Tc -ethyl cysteinate dimer SPECT detected hyperperfusion in a region containing the high signal intensity lesion seen on MRI, which was located close to the right insular cortex. Interictal ^{99m}Tc -ethyl cysteinate dimer SPECT performed on day 68 did not detect any abnormalities. MRI indicates magnetic resonance imaging; SPECT, single-photon emission computed tomography.

Case Report

A 2-year-old girl presented with partial seizures that manifested as twitching of the left angle of the mouth and jerking of the left upper limb but usually did not result in a loss of consciousness. The child's birth and the pregnancy preceding it were unremarkable. There was no family history of epilepsy or cardiac arrhythmia. During infancy, the child's motor and cognitive development were within the normal ranges. At the age of 3 years, she was referred to our center with the aim of achieving control of her seizures. An electroencephalogram (EEG) showed repetitive focal spikes in the right central region. Brain magnetic resonance imaging (MRI) showed focal cortical dysplasia in the right centroparietal region (Figure 1A), while interictal ^{99m}Tc -ethyl cysteinate dimer single-photon emission computed tomography (SPECT) did not detect any abnormalities (data not shown). The patient's seizures were refractory to various antiepileptic drugs.

At the age of 10 years and 5 months, the patient was admitted because of a sudden worsening of her seizures. On admission, she was taking phenytoin (250 mg/d) in combination with valproate (400 mg/d). The frequency of her seizures ranged

from 3 to 5 an hour. An ictal EEG showed rhythmic fast waves arising from the right central region, which sometimes evolved into diffuse slow waves corresponding to asymmetric bilateral tonic seizures (left > right). The patient's seizures did not respond to the intravenous administration of midazolam, lidocaine, and phenobarbital. On the second day after admission, T2-weighted MRI and apparent diffusion coefficient mapping revealed a high signal intensity lesion adjacent to the focal cortical dysplasia lesion (Figure 1B-D, left). Diffusion-weighted imaging also revealed a high signal intensity lesion in the same region (data not shown). The MRI perfusion imaging was not performed.

On the third day after admission, bradycardia was observed during a seizure. An EEG performed at the onset of the seizure showed rhythmic fast waves arising from the right central region. Ten seconds after the onset of the seizure, when the epileptic activity evolved into diffuse slow waves, the patient's baseline sinus heart rate of about 100 beats/min suddenly dropped to 40 to 50 beats/min, and she started to exhibit an idioventricular rhythm. Immediately after the seizure activity disappeared, the patient's cardiac rhythm returned to a normal sinus rhythm

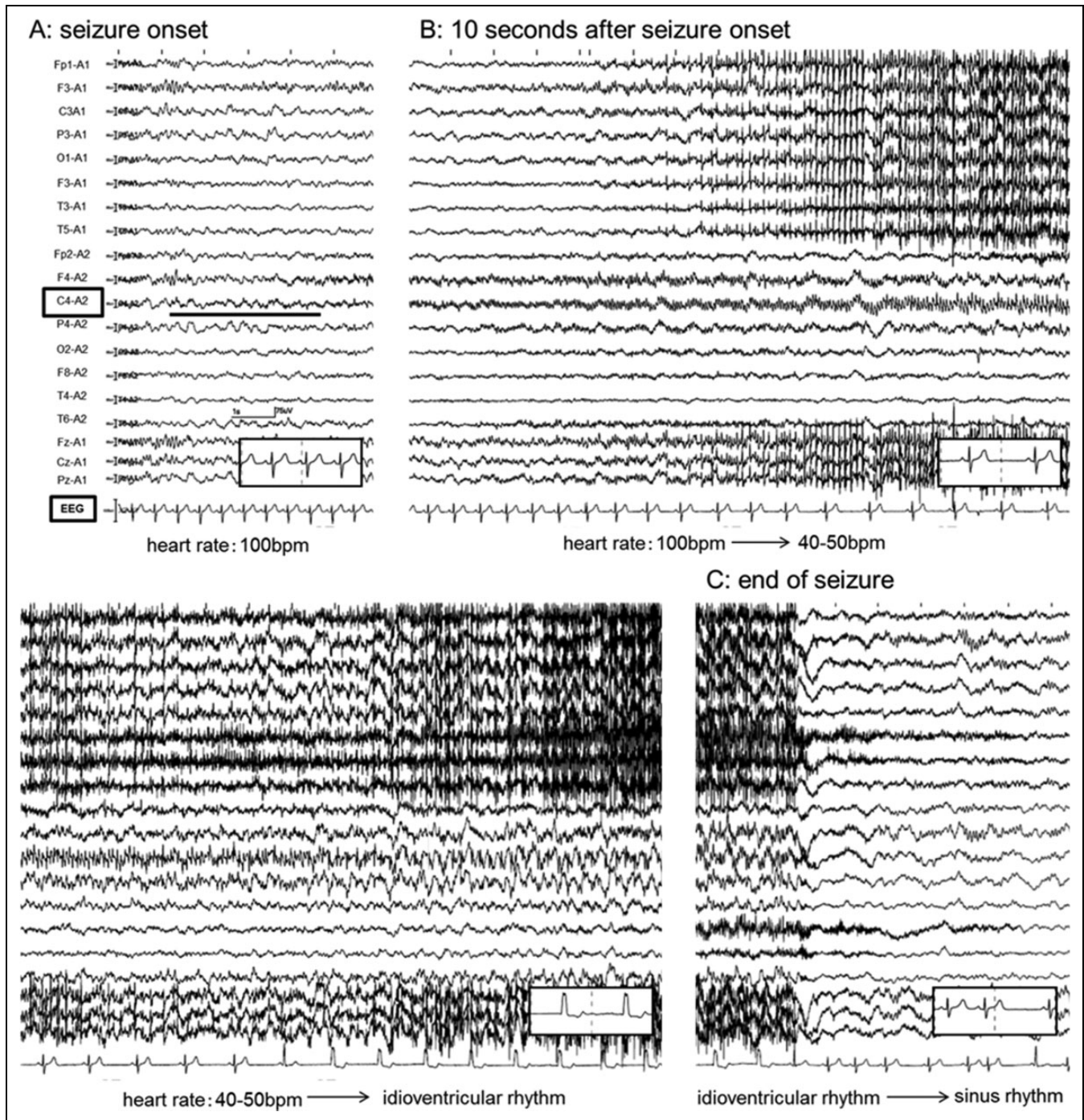


Figure 2. A, An EEG performed at seizure onset showed rhythmic fast waves arising from the right central region. B, About 10 seconds after seizure onset, when the patient's epileptic activity evolved into diffuse slow waves, her baseline sinus heart rate of about 100 beats/min suddenly dropped to 40 to 50 beats/min and then exhibited an idioventricular rhythm. C, After the seizure activity disappeared (68 seconds after onset), the patient's cardiac rhythm returned to a normal sinus rhythm. EEG indicates electroencephalogram.

(Figure 2). Oxygen desaturation (an oxygen saturation value of <92%) due to apnea (defined as breath arrest lasting >10 seconds) also occurred after the appearance of ictal bradycardia. Cardiac assessments, including continuous 24-hour ambulatory electrocardiography (ECG) monitoring and echocardiography, did not detect any abnormalities between the seizures.

Between 3 and 5 days after the patient's admission, the frequency of her seizures increased to 5 to 10 an hour. The patient's ictal bradycardia and apnea were usually accompanied by seizures, despite the prompt discontinuation of phenytoin and lidocaine. The idioventricular rhythm was observed in about half of the seizures. On the sixth day after admission,

when a brief period of ictal asystole occurred, barbiturate (sodium thiopental) therapy was started while the patient was under mechanical ventilation. The frequency of the patient's seizures decreased to once or twice an hour after the initiation of the barbiturate therapy (5 mg/kg/h), and her ictal bradycardia subsided. After the continuous intravenous infusion of sodium thiopental for 48 hours, the dose was gradually reduced. The patient's seizures subsequently worsened again. These seizures produced similar symptoms and paroxysmal EEG discharges to the previous seizures. However, the patient's bradycardia was less severe than it had been previously, her heart rate only fell to around 60 to 70 beats/min, and she did not develop cardiac arrhythmia. On the 25th day after admission, she was extubated. Ictal SPECT performed on day 27 showed hyperperfusion in the area containing both the focal cortical dysplasia lesion and the high signal intensity lesion seen on MRI (Figure 1E). The frequency of the patient's seizures was reduced via the continuous infusion of midazolam and high-dose phenobarbital, and hence, her ictal bradycardia subsided again. Interictal SPECT performed on day 68 did not reveal any abnormalities (Figure 1E). On day 69, the high-intensity lesion adjacent to the focal cortical dysplasia lesion was found to have diminished in size on follow-up MRI (Figure 1D, right). The patient was discharged on day 74. Interictal ^{18}F -fluorodeoxyglucose positron emission tomography/computed tomography was performed 2 months after discharge and detected hypometabolism in the right centroparietal region but not in the right insular cortex (data not shown). She underwent surgery at the age of 13 years and 1 month, and the lesion was partially resected. A histopathological examination resulted in a diagnosis of focal cortical dysplasia type IIB. There were no findings that were suggestive of Rasmussen syndrome. After surgery, the patient had infrequent partial seizures that were similar to those observed before surgery but no longer developed cluster seizures.

Discussion

Ictal bradycardia is considered to be rare in children because there have only been a few reported pediatric cases. However, a recent study found that ictal bradycardia occurred in 8.2% of the pediatric patients with epilepsy admitted to a pediatric epilepsy monitoring unit.⁵ Another comparative study reported that ictal bradycardia occurred more often in children (23.8% of pediatric seizures) than in adults (7.3% of adult seizures).⁶ In adults, ictal bradycardia was found to be more strongly associated with seizures originating from the temporal lobe, while in children it was more prevalent in patients having seizures of extratemporal origin.⁶ The risk factors for ictal bradycardia include seizure clustering,⁷ having suffered with epilepsy for a long period, taking multiple antiepileptic drugs, a younger age at seizure onset, and refractory epilepsy.⁸

The propagation of seizure activity into the autonomic centers that regulate the cardiovascular system is assumed to be the leading mechanism of ictal bradycardia. In 1990, Oppenheimer and Cechetto demonstrated that stimulation of the left insular

cortex evoked bradycardia in rats.⁹ The same authors later showed that perioperative stimulation of the insular cortex tended to result in heart rate changes (left insular cortex: bradycardia and right insular cortex: tachycardia) in patients with epilepsy.¹⁰ Although conflicting results have been obtained regarding the left- or right-sided predominance of ictal bradycardia,¹¹ several other studies have suggested that the insular cortex plays an important role in cardiac regulation in humans.^{12,13} However, to the best of our knowledge, there has only been 1 case report of ictal bradycardia due to an insular cortex lesion, which involved a 3-year-old girl with focal cortical dysplasia in her right insular cortex.¹³

Some antiepileptic drugs, such as carbamazepine, lamotrigine, phenytoin, and lidocaine, are known to act as sodium channel blockers and can have side effects that affect the cardiac conduction system.¹⁴ Our patient was receiving phenytoin and lidocaine for her cluster seizures when the first episode of ictal bradycardia occurred. However, phenytoin and lidocaine are unlikely to have caused the bradycardia experienced in the present case due to (1) the prolonged (>2 weeks) persistence of the bradycardia, despite the prompt discontinuation of the above-mentioned drugs and (2) the absence of cardiac arrhythmia between seizures according to continuous 24-hour ambulatory ECG monitoring.

Focal cortical dysplasia constitutes the most important cause of intractable localization-related epilepsy in childhood. A recent study reported that ictal SPECT is useful for defining the epileptic zone in a high proportion of children with focal cortical dysplasia who undergo surgical evaluation.¹⁵ In our patient, the high signal intensity lesion seen on T2-weighted MRI image appeared when the patient had cluster seizures and diminished in size as her seizures improved, suggesting that these MRI changes were related to seizure clustering. Ictal SPECT detected hyperperfusion in the area containing the high signal intensity lesion depicted on MRI, which was located very close to the right insular cortex. This hyperperfusion zone was considered to reflect seizure propagation. The ictal bradycardia experienced by our patient might have been caused by the following mechanism: Repetitive seizure activity might have expanded from the hyperperfusion zone into the right insular cortex, which controls cardiac rhythm, resulting in ictal bradycardia.

The autonomic alterations and heart rate changes seen during epilepsy are complex and are not fully understood.³ Although the presence of hyperperfusion on ictal SPECT might represent zones of seizure propagation, there have not been any reports about the ictal SPECT findings of patients with ictal bradycardia. In our patient, ictal SPECT demonstrated hyperperfusion in an area that was close to the insular cortex but did not involve the insular cortex itself. Subtraction ictal SPECT coregistered to MRI analysis also failed to detect ictal hyperperfusion in the right insular cortex (data not shown). One possible reason for this is that the patient's bradycardia was less severe at the time of the ictal SPECT study than it had been previously. Although the seizures experienced by the patient after the injection of the radiotracer used for the SPECT produced similar symptoms and paroxysmal EEG discharges to the previous seizures, the

bradycardia induced was mild (the patient's heart rate only fell to 60-70 beats/min) and did not lead to cardiac arrhythmia. Thus, seizures involving more severe ictal bradycardia might have been found to involve the insular cortex on SPECT.

In this study, ictal and interictal SPECT were performed during the patient's cluster seizures (day 27), when ictal bradycardia was observed, and on day 68, when the ictal bradycardia had gone into remission. However, no ictal SPECT scans were performed after the patient's ictal bradycardia went into remission because she did not experience seizures often during the follow-up period. Comparing the 2 ictal SPECT scans might have helped us to clarify the origin of the patient's ictal bradycardia and why her ictal bradycardia was transient. Further studies with ictal SPECT are necessary to elucidate the pathophysiology of ictal bradycardia in patients with epilepsy, providing that clinical conditions allow it.

Acknowledgments

This study was performed at Osaka Medical Center and Research Institute for Maternal and Child Health. This case has not been presented elsewhere.

Author Contributions

TK wrote the article; HT, SK, TI, YM, and KY are physicians and contributed to the patient's treatment during her hospital stay; and HK and YS reviewed the article.

Declaration of Conflicting Interests

The authors declared no potential conflicts of interest with respect to the research, authorship, and/or publication of this article.

Funding

The authors received no financial support for the research, authorship, and/or publication of this article.

Ethical Approval

Ethical approval is not necessary for case reports from Osaka Medical Center and Research Institute for Maternal and Child Health.

References

1. Milroy CM. Sudden unexpected death in epilepsy in childhood. *Forensic Sci Med Pathol*. 2011;7(4):336-340.
2. Devinsky O. Sudden, unexpected death in epilepsy. *N Engl J Med*. 2011;365(19):1801-1811.
3. Sevcencu C, Struijk JJ. Autonomic alterations and cardiac changes in epilepsy. *Epilepsia*. 2010;51(5):725-737.
4. Devinsky O. Effects of seizures on autonomic and cardiovascular function. *Epilepsy Curr*. 2004;4(2):43-46.
5. Moseley BD, Nickels K, Britton J, Wirrell E. How common is ictal hypoxemia and bradycardia in children with partial complex and generalized convulsive seizures? *Epilepsia*. 2010;51(7):1219-1224.
6. Pavlova M, Singh K, Abdennadher M, et al. Comparison of cardiorespiratory and EEG abnormalities with seizures in adults and children. *Epilepsy Behav*. 2013;29(3):537-541.
7. Moseley BD, Wirrell EC, Nickels K, Johnson JN, Ackerman MJ, Britton J. Electrocardiographic and oximetric changes during partial complex and generalized seizures. *Epilepsy Res*. 2011;95(3):237-245.
8. Singh K, Katz ES, Zarowski M, et al. Cardiopulmonary complications during pediatric seizures: a prelude to understanding SUDEP. *Epilepsia*. 2013;54(6):1083-1091.
9. Oppenheimer SM, Cechetti DF. Cardiac chronotropic organization of the rat insular cortex. *Brain Res*. 1990;533(1):66-72.
10. Oppenheimer SM, Gelb A, Girvin JP, Hachinski VC. Cardiovascular effects of human insular cortex stimulation. *Neurology*. 1992;42(9):1727-1732.
11. Britton JW, Ghearing GR, Benarroch EE, Cascino GD. The ictal bradycardia syndrome: localization and lateralization. *Epilepsia*. 2006;47(4):737-44.
12. Tokgozoglu SL, Batur MK, Top uoglu MA, Saribas O, Kes S, Oto A. Effects of stroke localization on cardiac autonomic balance and sudden death. *Stroke*. 1999;30(7):1307-1311.
13. Seeck M, Zaim S, Chaves-Vischer V, et al. Ictal bradycardia in a young child with focal cortical dysplasia in the right insular cortex. *Eur J Paediatr Neurol*. 2003;7(4):177-181.
14. Hesdorffer DC, Tomson T. Sudden unexpected death in epilepsy. Potential role of antiepileptic drugs. *CNS Drugs*. 2013;27(2):113-119.
15. Krsek P, Kudr M, Jahodova A, et al. Localizing value of ictal SPECT is comparable to MRI and EEG in children with focal cortical dysplasia. *Epilepsia*. 2013;54(2):351-358.