

Received: 2021.08.16

Accepted: 2021.12.16

Available online: 2022.01.07

Published: 2022.02.10

Case Report of Cardiorenal Syndrome with Ascites and *Listeria monocytogenes* Peritonitis: The Role of Large-Volume Paracentesis and Albumin Replacement

Authors' Contribution:

Study Design A
Data Collection B
Statistical Analysis C
Data Interpretation D
Manuscript Preparation E
Literature Search F
Funds Collection G

BEF **Minas Karagiannis**
BF **Panagiotis Giannakopoulos**
D **Aggeliki Sardeli**
D **Ourania Tsotsorou**
D **Dimitra Bacharaki**
DEF **Demetrios V. Vlahakos**

Division of Nephrology, Second Department of Internal Medicine, Attikon University Hospital, National and Kapodistrian University of Greece, Haidari, Greece

Corresponding Author: Minas Karagiannis, e-mail: minaskar64@gmail.com
Financial support: None declared
Conflict of interest: None declared

Patient: Female, 77-year-old
Final Diagnosis: Cardiorenal syndrome • *Listeria monocytogenes* infection • spontaneous bacterial peritonitis
Symptoms: Abdominal distension • fever
Medication: —
Clinical Procedure: —
Specialty: Infectious Diseases • Nephrology

Objective: Rare disease


Background: Spontaneous bacterial peritonitis is a common infection in hospitalized patients with ascites, particularly in patients with cirrhosis. Spontaneous bacterial peritonitis is often associated with acute kidney injury. The causative agents of spontaneous bacterial peritonitis are usually gram-negative bacteria, but lately, the prevalence of spontaneous bacterial peritonitis caused by gram-positive bacteria is rising.

Case Report: In this report, we present the case of a 77-year-old woman with a history of cardiorenal syndrome with ascites and chronic kidney disease who was admitted with diarrhea, fever, and abdominal pain. Ascitic fluid paracentesis revealed spontaneous bacterial peritonitis due to *Listeria monocytogenes*. During hospitalization, her ascites gradually enlarged and her kidney function deteriorated. The deterioration of kidney function was at least partially attributed to sepsis caused by spontaneous bacterial peritonitis. In addition to proper antibiotic therapy with ampicillin and daily hemodialysis sessions, large-volume paracentesis and albumin infusions were instituted. After 5 days, she showed a fast improvement, the ascites subsided, and her renal function returned to baseline.

Conclusions: Spontaneous bacterial peritonitis caused by *Listeria monocytogenes* is associated with a poor outcome. Acute kidney injury in patients with spontaneous bacterial peritonitis is common and related with a poor outcome. Data about the role of large-volume paracentesis and albumin replacement in patients with spontaneous bacterial peritonitis are still ambiguous. In the literature, all patients with spontaneous bacterial peritonitis due to *Listeria monocytogenes* who underwent large-volume paracentesis survived.

Keywords: Acute Kidney Injury • *Listeria monocytogenes* • Paracentesis • Peritonitis • Renal Dialysis

Full-text PDF: <https://www.amjcaserep.com/abstract/index/idArt/934423>

 1533

 1

 1

 22



Background

Spontaneous bacterial peritonitis (SBP) is an infection of the ascitic fluid without a detectable intraabdominal surgically treatable source of infection. SBP develops in up to 30% of patients with ascites who are admitted to hospitals, particularly patients with cirrhosis [1]. The major mechanism is considered to be the bacterial translocation of gram-negative enteric bacteria, which have been found to be the main causative agents. Of particular interest is, however, that an increasing prevalence of SBP (48-62%) due to gram-positive bacteria has been observed over the last decade, particularly in Europe [2]. *Listeria monocytogenes*, a gram-positive rod, remains a rare cause of SBP. A 2011 systematic review [3] revealed 128 published cases of listeria-associated peritonitis. Among them, 86 patients had cirrhosis, 17 had end-stage renal disease and were on peritoneal dialysis, and 25 had no known underlying disease. Since then, 30 additional cases of SBP due to *L. monocytogenes* have been published, including a single case of congestive hepatopathy under immunosuppressive therapy [4].

In this report, we present the first case of a patient with cardiorenal syndrome and ascites who was diagnosed with peritonitis due to *L. monocytogenes* and survived. A literature review and the role of acute hemodialysis, large-volume paracentesis (LVP), and albumin infusion as life-saving therapeutic modalities in such cases will be discussed.

Case Report

The case of a 77-year-old woman who presented with fever, abdominal pain, and diarrhea for the past 5 days is presented in this report. The patient's medical history was significant for hypertension, insulin-treated diabetes mellitus, coronary artery disease, right-sided congestive heart failure with severe tricuspid regurgitation, chronic atrial fibrillation with acenocumarol treatment, and chronic kidney disease, with a baseline creatinine value of 2.5 mg/dL and an estimated glomerular filtration rate by MDRD formula of 20 mL/min/1.73 m². There was no history of liver disease or alcohol or drug use. She underwent a percutaneous transluminal coronary angioplasty 4 years earlier, a partial colectomy for repeated diverticular bleeding 2 years earlier, and a pacemaker implantation 8 months earlier.

On physical examination, she was awake and oriented to self and place. Her blood pressure was 100/70 mmHg, heart rate was 90 beats per min, temperature was 38°C, and oxygen saturation was 97% on room air. Notable findings were a large firm liver, large ascites with tenderness in the lateral abdominal wall, and 1+ pitting edema in the lower extremities.

Initial laboratory tests revealed a white blood cell count of 8510 K/ μ L, C-reactive protein of 200 mg/L (reference range, below 5 mg/L), and procalcitonin of 22 ng/mL (reference range, below 0.5 ng/mL). Additional results of the analysis of the blood chemistry were as follows: serum creatinine of 3.5 mg/dL, international normalized ratio (INR) of 5, brain natriuretic peptide of 9487 pg/mL, serum bicarbonate 17 mEq/L, blood urea nitrogen of 111 mg/dL, total bilirubin of 1.21 mg/dL, direct bilirubin of 0.86 mg/dL, aspartate aminotransferase of 22 U/L, alanine aminotransferase of 7 U/L, alkaline phosphatase of 73 U/L, and γ GT of 23 U/L. Her urinalysis was negative for infection.

A transthoracic echocardiogram was performed and was notable for an ejection fraction of 55%, with global hypokinesis, a dilated inferior vena cava, and an elevated pulmonary artery pressure of 52 mmHg. An abdominal computed tomography (CT) scan showed a small right pleural effusion and a large amount of free intraperitoneal fluid.

Because of concern for sepsis, she was empirically started on metronidazole and ceftolozane-tazobactam. After normalization of the INR, a diagnostic paracentesis of the ascites was performed. The aspirated fluid was dark yellow and turbid with total fluid protein of 5.21 g/dL and white blood cell count of 5120/mm³ (98% polymorphonuclear cells). The culture of the ascitic fluid revealed *L. monocytogenes*, which was sensitive to ampicillin, penicillin, meropenem, and co-trimoxazole. Then, antibiotic therapy was switched to ampicillin, which was given for 3 weeks.

During hospitalization, before *L. monocytogenes* was revealed from the culture of ascitic fluid, our patient's abdominal dilatation and discomfort worsened, she became lethargic, with no signs of asterixis, her kidney function deteriorated, and she became oliguric, with a peak creatinine value of 4.9 mg/dL. To detect the cause of the deterioration of renal function, urine microscopy evaluation was performed and the urinary sediment was bland without cells, casts or other specific findings. These findings contributed to the notion that the deterioration of kidney function could be attributed, at least partially, to sepsis caused by SBP. Since the ammonia levels were not elevated, the patient's worsening mental status was attributed to uremia, and she underwent daily dialysis sessions for 5 days, accompanied by LVP with removal of a total volume of 10 L of ascitic fluid and concurrent administration of 100 g of intravenous albumin. These maneuvers allowed the correction of uremic symptoms, improvement of the electrolyte and water balance, and correction of the effective volume and cardiovascular stability. After 5 days, she showed a fast improvement of her clinical condition, her mental status returned to normal, the abdominal tenderness disappeared, the volume of ascites remained small and stable, and renal function returned to baseline, with a serum creatinine of 2 mg/dL at discharge, when examination of ascitic fluid revealed transudate

Table 1. Nine case reports of spontaneous bacterial peritonitis with *Listeria monocytogenes* reporting volume of paracentesis published over the past decade.

Author/Year	Sex (M, F)	Age, years	Primary Disease	Paracentesis	PMNs in ascites cells/mm ³	AKI	HD	Outcome
Galan20/2011	F	76	Hemochromatosis	LVP >5 L	3100	No	No	Alive
Carsoso19/2012	M	51	Alcoholic cirrhosis	Diagnostic	16450	Yes	No	Dead
Yecies18/2013	M	62	Alcoholic cirrhosis	LVP >3 L	5160	No	No	Alive
Shaikh17/2015	F	65	Primary biliary cirrhosis	Diagnostic	8070	No	No	Alive
How16/2015	M	68	Alcoholic cirrhosis	LVP >5 L	2710	Yes	Yes	Alive
Gaspar14/2017	M	51	Congestive hepatopathy	LVP >5 L	9225	No	No	Alive

M – male; F – female; LVP – large-volume paracentesis; AKI – acute kidney injury; HD – hemodialysis; PMN – polymorphonuclear.

with a white blood count of 250 cells/mm³. At a follow-up visit 6 months later, the patient was alive and well at her usual state of health.

Discussion

In this case, SBP was caused by an uncommon bacterial agent, *L. monocytogenes*, in a female patient with severe cardiorenal syndrome and right-sided heart failure associated with cardiac cirrhosis and ascites. The patient had reported diarrhea for 5 days prior to admission, was not bacteremic, and therefore, it seemed reasonable to assume that gut colonization and subsequent transluminal migration of *L. monocytogenes* through the intestinal wall had occurred.

Patients with cirrhosis with listeria-infected ascites have been estimated to have mortality in the range of 30%. Patients usually die within 6 days of contracting the infection [5]. *L. monocytogenes*-related SBP, whose incidence has risen in recent years, requires early recognition and specific treatment. Our patient's condition worsened initially on conventional antibiotic treatment but improved after antibiotic therapy was switched to an ampicillin-based antibiotic regimen.

Acute kidney injury has been long known to be associated with SBP in up to 43% of such patients, and this relation is associated with a 6-fold mortality increase [6,7]. The acute kidney injury in SBP can be related to inflammatory molecules and endotoxemia [8]. The concentration of lipopolysaccharide is higher among cirrhotic patients with SBP and is associated with lower renal blood flow, glomerular filtration rate,

and stagnation of the microvascular flow. Accompanying antibiotics with albumin therapy has been demonstrated to reduce the incidence of renal impairment and in-hospital mortality from 29% to 10% [9], compared with antibiotics alone. Similarly, a recent Cochrane review supported the use of albumin for SBP and demonstrated protective effects on renal function and mortality [10]. These findings emphasize the significance of the correction of effective volume and the reduction of ascitic volume anticipated by the improvement of the intravascular colloid osmotic pressure induced by albumin infusion.

Since our patient developed acute-on-chronic kidney injury, daily hemodialysis sessions were initiated to control uremia, balance volume and electrolytes, and allow the administration of intravenous albumin infusion and the performance of LVP to decrease intraabdominal pressure and possibly reduce toxic burden. It is important to mention that there is an extreme paucity of evidence regarding the role and safety of LVP in SBP, and there are no clinical guidelines to provide recommendations on whether LVP can be considered in SBP. One small, randomized controlled study showed no worse outcomes with LVP and maybe a faster symptom relief course [11]. However, postulation of removing toxic burden through paracentesis was not confirmed in another nonrandomized trial [12].

There are 9 reported cases with *L. monocytogenes*-related SBP over the past decade that included information regarding paracentesis of ascites [13-21] (Table 1). After excluding 2 patients with malignancy [13,21] and 1 patient on chronic ambulatory peritoneal dialysis [15], we focused on 6 cases with ascites due to cirrhosis (3 associated with alcohol abuse, 1 with hemochromatosis, 1 with autoimmunity, and 1 with chronic

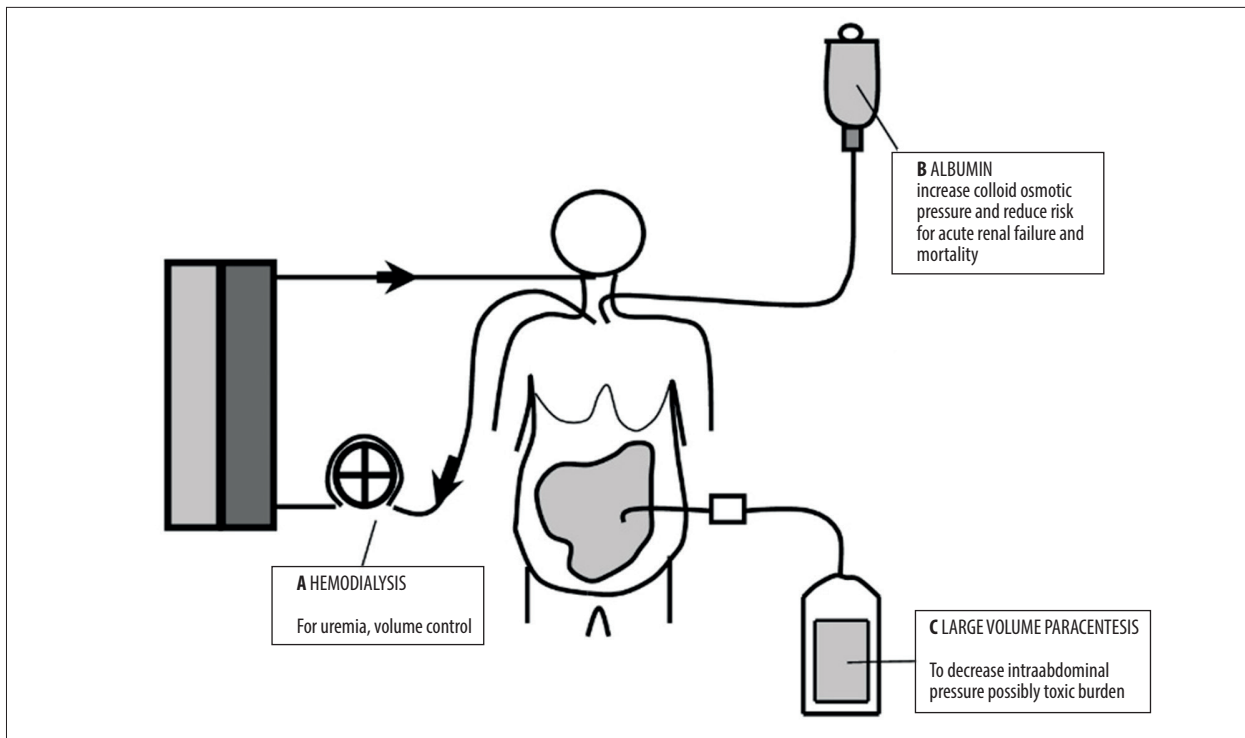


Figure 1. Interventions associated with favorable outcome in a woman with cardiorenal syndrome, ascites, and spontaneous bacterial peritonitis due to *Listeria monocytogenes*. A) Hemodialysis to control uremia, normalize volume, and maintain normal electrolyte balance. B) Albumin infusion along with proper antibiotic therapy to reduce the severity of renal impairment and mortality and improve intravascular colloid osmotic pressure. C) Large-volume paracentesis to diagnose the causative agent and to decrease the intraabdominal pressure and possibly the toxic burden.

congestion). Among them, all 4 patients undergoing LVP survived (**Table 1**). Experimental work in pigs has demonstrated that the inflammatory milieu of the ascites was eliminated by removing the inflamed peritoneal ascites using a wound vacuum system. It was also shown that the positive feedback loops that lead to multi-organ dysfunction were attenuated when ascites was removed, as evidenced by the reduced development of acute lung injury [22].

Conclusions

In conclusion, diagnostic paracentesis should immediately be performed in any patient with ascites and signs suggestive of

SBP, such as fever, gastrointestinal discomfort, altered mental status, and hypotension. Broad-spectrum antibiotic therapy is recommended initially and can be narrowed when susceptibility results become available. Acute kidney failure should be recognized and treated with hemodialysis, if needed. Intravenous albumin infusion and LVP seem to improve patient outcome (**Figure 1**). However, further investigations are warranted to delineate the clinical risks and benefits of LVP in SBP.

Declaration of Figures' Authenticity

All figures submitted have been created by the authors who confirm that the images are original with no duplication and have not been previously published in whole or in part.

References:

1. Marciano S, Díaz JM, Dirchwolf M, Gadano A. Spontaneous bacterial peritonitis in patients with cirrhosis: Incidence, outcomes, and treatment strategies. *Hepat Med*. 2019;11:13-22
2. Fiore M, Maraolo AE, Gentile I, et al. Current concepts and future strategies in the antimicrobial therapy of emerging Gram-positive spontaneous bacterial peritonitis. *World J Hepatol*. 2017;9(30):1166-75
3. Liatsos GD, Thanellas S, Pirounaki M, et al. *Listeria monocytogenes* peritonitis: Presentation, clinical features, treatment, and outcome. *Scand J Gastroenterol*. 2012;47(10):1129-40
4. Gaspar R, Rodrigues S, Macedo G. Spontaneous bacterial peritonitis due to *Listeria monocytogenes*: Always to be remembered. *Clin Res Hepatol Gastroenterol*. 2017;41(5):e68-70
5. Tablang MV. Spontaneous bacterial peritonitis caused by infection with *Listeria monocytogenes*. *Case Rep Gastroenterol*. 2008;2(3):321-25
6. Follo A, Llovet JM, Navasa M, et al. Renal impairment after spontaneous bacterial peritonitis in cirrhosis: Incidence, clinical course, predictive factors and prognosis. *Hepatology*. 1994;20(6):1495-501

7. Devani K, Charilaou P, Jaiswal P, et al. Trends in hospitalization, acute kidney injury, and mortality in patients with spontaneous bacterial peritonitis. *J Clin Gastroenterol.* 2019;53(2):e68-74
8. Peng JL, Techasatian W, Hato T, Liangpunsakul S. Role of endotoxemia in causing renal dysfunction in cirrhosis. *J Investig Med.* 2020;68(1):26-29
9. Sort P, Navasa M, Arroyo V, et al. Effect of intravenous albumin on renal impairment and mortality in patients with cirrhosis and spontaneous bacterial peritonitis. *N Engl J Med.* 1999;341(6):403-9
10. Zaccherini G, Tufoni M, Bernardi M. Albumin administration is efficacious in the management of patients with cirrhosis: A systematic review of the literature. *Hepat Med.* 2020;12:153-72
11. Choi CH, Ahn SH, Kim DY, et al. Long-term clinical outcome of large volume paracentesis with intravenous albumin in patients with spontaneous bacterial peritonitis: A randomized prospective study. *J Gastroenterol Hepatol.* 2005;20(8):1215-22
12. Abd Elaal MM, Zaghoul SG, Bakr HG, et al. Evaluation of different therapeutic approaches for spontaneous bacterial peritonitis. *Arab J Gastroenterol.* 2012;13(2):65-70
13. Eisa M, Tefera K, Alvanpour A. *Listeria peritonitis* and bacteremia in a patient with cholangiocarcinoma. *IDCases.* 2018;14:e00430
14. Gaspar R, Rodrigues S, Macedo G. Spontaneous bacterial peritonitis due to *Listeria monocytogenes*: Always to be remembered. *Clin Res Hepatol Gastroenterol.* 2017;41(5):e68-70
15. Beckerleg W, Keskar V, Karpinski J. Peritonitis as the first presentation of disseminated listeriosis in a patient on peritoneal dialysis – a case report. *Perit Dial Int.* 2017;37(2):239-40
16. How J, Azar MM, Meyer JP. Are nectarines to blame? A case report and literature review of spontaneous bacterial peritonitis due to *Listeria monocytogenes*. *Conn Med.* 2015;79(1):31-36
17. Shaikh B, Pathak R, Mainali NR, Gupta S. *Listeria monocytogenes* as a cause of spontaneous bacterial peritonitis: A rare entity. *J Community Hosp Intern Med Perspect.* 2015;5(1):26153
18. Yecies T, Inagami S. Spontaneous bacterial peritonitis caused by *Listeria monocytogenes* associated with ascitic fluid lymphocytosis: A case report and review of current empiric therapy. *Case Reports Hepatol.* 2013;2013:832457
19. Cardoso C, Cremers I, Oliveira AP. Spontaneous bacterial peritonitis caused by *Listeria monocytogenes*: A case report and literature review. *Ann Hepatol.* 2012;11(6):955-57
20. Galan SR, Kann PH, Gress TM, Michl P. *Listeria monocytogenes*-induced bacterial peritonitis caused by contaminated cheese in a patient with haemochromatosis. *Z Gastroenterol.* 2011 Jul;49(7):832-35
21. Haneche F, Brocard A, Garioud A, Cadranet JF. [Spontaneous bacterial peritonitis with *Listeria monocytogenes* leading to a cirrhosis discovery]. *Presse Med.* 2017;46(3):332-34 [in French]
22. Kubiak BD, Albert SP, Gatto LA, et al. Peritoneal negative pressure therapy prevents multiple organ injury in a chronic porcine sepsis and ischemia/reperfusion model. *Shock.* 2010;34(5):525-34