

## Obstetrical forceps-induced Descemet membrane tears

Rinky Agarwal, Nidhi Kalra Singh, Rajesh Sinha, Namrata Sharma

Obstetrical forceps-induced Descemet membrane tears (FIDMT) are usually encountered during complicated forceps-assisted deliveries. The condition may lead to significant visual debilitation in young children and is frequently ignored due to its low incidence. Undue stretch on the Descemet's membrane during the process of forceps-assisted delivery results in their vertical/oblique tear (s), which usually leads to corneal edema in early neonatal life. On its resolution, these residual tears result in visually disabling astigmatism that can lead to dense and recalcitrant amblyopia. Slit-lamp examination, anterior segment optical coherence tomography, specular microscopy, confocal microscopy, and corneal topography and tomography can be employed for its accurate diagnosis. While these can be prevented by improved perinatal care, once diagnosed, they mandate prompt refractive correction and amblyopia therapy to prevent disabling visual deterioration in affected children. In adulthood, medical and surgical management may be planned for symptomatic patients based on coexistent amblyopia as this is the major factor guiding visual prognosis. There is limited comprehensive literature in this regard, and the present review discusses the pathogenesis, clinical features, and recent developments in investigations, management, and outcomes of FIDMT during the last three decades.

**Key words:** Astigmatism, corneal edema, Descemet membrane tears, forceps

Obstetrical forceps-induced Descemet's membrane tears (FIDMT) were first documented by Truc in 1898.<sup>[1]</sup> In modern medicine, forceps-induced birth trauma to the eye is a rare clinical event as obstetrical forceps are infrequently employed for delivering neonates owing to the advancements in cesarean section.<sup>[2]</sup> However, this complication can still be encountered in developing countries like India where the surgical facilities for cesarean operation are not readily available at every clinic.<sup>[3]</sup> The condition can lead to significant visual debilitation in young children and is frequently overlooked due to its low incidence.<sup>[4]</sup> The present review discusses the pathogenesis, clinical features, and recent developments in investigations, management, and outcomes of FIDMTs during the last three decades.

### Literature Search

An electronic search of the PubMed database was performed for the years 1990–2021 with the keywords forceps-induced Descemet membrane tears/ruptures/breaks, obstetrical forceps-induced Descemet membrane tears/ruptures/breaks, birth trauma-induced Descemet membrane tears/ruptures/breaks, penetrating keratoplasty for forceps-induced Descemet membrane tears/corneal edema and endothelial keratoplasty for forceps-induced Descemet membrane tears/corneal edema. Some articles that were not found by our PubMed search were taken from the references from other articles and books.

Department of Ophthalmology, Dr Rajendra Prasad Centre for Ophthalmic Sciences, All India Institute of Medical Sciences, New Delhi, India

**Correspondence to:** Dr. Rinky Agarwal, Cataract, Cornea and Refractive Services, Dr Rajendra Prasad Centre for Ophthalmic Sciences, All India Institute of Medical Sciences, New Delhi - 110 029, India. E-mail: rinky.1990@gmail.com

Received: 14-Apr-2021

Revision: 07-Jul-2021

Accepted: 07-Jul-2021

Published: 26-Nov-2021

#### Access this article online

Website:

www.ijo.in

DOI:

10.4103/ijo.IJO\_863\_21

#### Quick Response Code:



### Epidemiology

According to Jain *et al.*,<sup>[2]</sup> around 17.3% of neonates born with forceps-assisted deliveries sustain ocular injuries (to eye or adnexa or both). According to McAnena *et al.*,<sup>[5]</sup> around one-third of these injuries are associated with corneal edema at birth, out of which one-fourth can finally culminate in corneal scarring and amblyopia. As reported by McDonald and Burgess, the majority of the cases reported are males.<sup>[6]</sup> The affected individuals commonly present in the third decade of life; however, the age of presentation can range from 3 to 66 years. These tears are generally unilateral and affect the left eye as the left occipito-anterior is the most common fetal position at birth. However, the right eye, as well as both eyes can also be involved rarely, depending on the presentation of the fetus in the uterus.<sup>[6]</sup> As they can go unnoticed in the early neonatal period, underreporting is common for these tears.

### Anatomy

The human cornea consists of five layers: epithelium, Bowman's membrane, stroma, Descemet's membrane (DM), and endothelium.<sup>[4]</sup>

DM, a basement membrane structure produced by the cornea endothelium, is composed of compacted collagenous and noncollagenous glycoproteins. At birth, the DM is much

This is an open access journal, and articles are distributed under the terms of the Creative Commons Attribution-NonCommercial-ShareAlike 4.0 License, which allows others to remix, tweak, and build upon the work non-commercially, as long as appropriate credit is given and the new creations are licensed under the identical terms.

**For reprints contact:** WKHLRPMedknow\_reprints@wolterskluwer.com

**Cite this article as:** Agarwal R, Singh NK, Sinha R, Sharma N. Obstetrical forceps-induced Descemet membrane tears. Indian J Ophthalmol 2021;69:3432-41.

thinner (3–4  $\mu\text{m}$ ) than in an adult (10–12  $\mu\text{m}$ ) and is more prone to injury despite its elastic properties.<sup>[7]</sup> Endothelial cells (ECs) are monolayered hexagonal cells lining the inner part of the cornea. They are around 3000 cells/ $\text{mm}^2$  at birth and heal mostly by migration and spreading, with cell proliferation playing a role secondary to healing by migration.<sup>[4]</sup>

## Pathogenesis

FIDMTs are usually encountered during complicated forceps-assisted delivery. During such deliveries, the eyeball undergoes accidental vertical compression between the bony orbital roof (either inferior or superior) and the blade of the maladjusted obstetric forceps. This leads to a transient or acute high rise of intraocular pressure (IOP) and horizontal stretching of the globe. When this pressure exceeds the elasticity of the DM, vertical or oblique ruptures ensue, along with a diffuse epithelial and stromal edema in the immediate postpartum period. Pecorella *et al.*<sup>[8]</sup> suggested that the edges of the torn DM curl toward the stroma, possibly because of the differential elasticity between its anterior banded and posterior nonbanded layers. The young endothelium then proliferates across the posterior cornea, synthesizing a new thick basement membrane that fills in the dehiscence and leads to gradual resolution of edema. Hyper production of DM at the edges of the tear leads

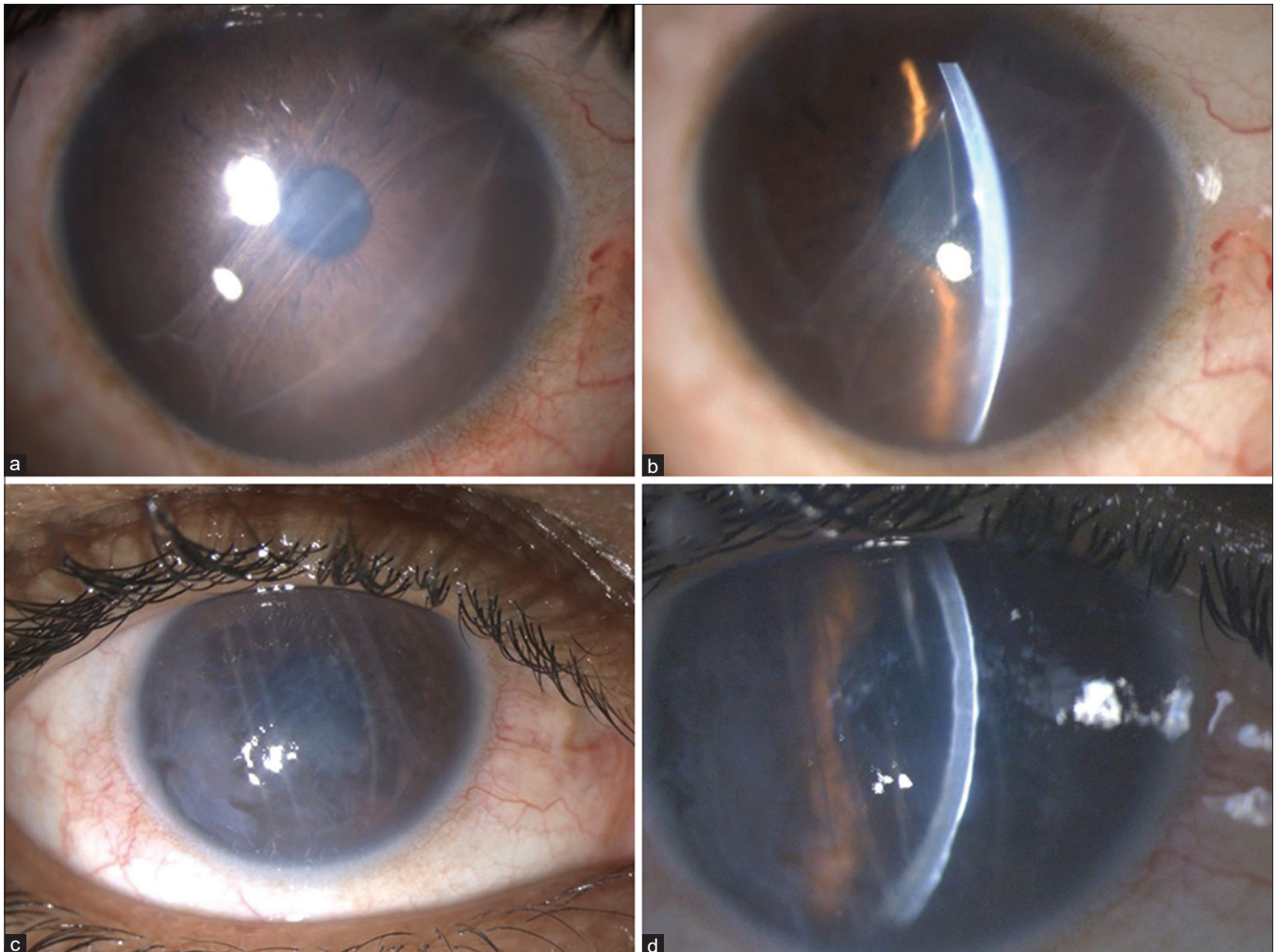
to endothelial protrusions at that site, a characteristic of FIDMT. Rarely, direct contact of the forceps with the cornea is also implicated as their mechanism of occurrence.

## Clinical Features

### Corneal edema

Corneal edema in FIDMT develops in two distinct phases. The first phase occurs immediately after birth and the child can present with a cloudy cornea at as early as 2–10 days of life.<sup>[9,10]</sup> The affected children can also present with lacrimation, photophobia, and blepharospasm. During this phase, the underlying DM tears may not be easily appreciated by the clinician owing to the overlying edematous and traumatized cornea. The edema usually spontaneously clears within 1–6 weeks, following which the permanent tears or scrolls can be appreciated [Fig. 1]. It is therefore recommended that the eye-care providers should look for probable DM detachment in any neonate presenting with prolonged corneal edema.

The second phase usually occurs decades later when the previously stressed corneal endothelium decompensates again [Fig. 1]. The time taken for decompensation may range from 25 to 44 years after the original insult. Infrequently, the cornea can remain clear despite the presence of a large break and absent DM



**Figure 1:** Clinical appearance of FIDMT and corneal edema on diffuse illumination (a and c) and slit-formation (b and d)

at the site of FIDMT and surrounding marked EC disturbances.<sup>[11]</sup> The decompensated eyes commonly present with acute edema and/or chronic bullous keratopathy, and the FIDMTs appear as thin, straight, or slightly arched lines during this stage.

### DM tears

These single or multiple linear tears are characteristically oriented in vertical or oblique directions [Fig. 1].<sup>[6]</sup> Nevertheless, rare cases of horizontal ruptures have also been documented.<sup>[12]</sup> These tears can be located centrally or peripherally and have characteristic scrolled-DM margins at their edges virtually diagnostic of birth trauma.<sup>[13]</sup> The longitudinal tears separate DM into several flat strips, each of which retains its terminal attachments near the periphery of the cornea.<sup>[6]</sup> The tissue between these ruptured lines experiences a relative lack of highly pleomorphic ECs and often has a ground glass/beaten metal appearance due to irregular basement membrane. This may explain the tendency of injured corneas at birth to develop edema requiring corneal transplantation later in life.<sup>[14]</sup> FIDMTs are mostly asymptomatic and may be incidentally diagnosed in adolescents or adults presenting with poor visual acuity, glare, or photophobia.<sup>[15]</sup>

### Refractive error

The response of kids to birth-related DM tears is variable.<sup>[16]</sup> Most of the children have high corneal astigmatism due to the scarring of the DM. The astigmatism is primarily with-the-rule type and can range from +2D to +9D. The steep axis usually corroborates with the direction of the tear and can range from 75° to 100°.<sup>[6,11]</sup> Unless managed in a timely fashion, it can lead to dense and irreversible amblyopia. Other refractive errors include progressively increasing myopia (due to form deprivation and resultant amblyopia), hypermetropia, and emmetropia in descending order.<sup>[6,17]</sup> Lambert reported a case of progressive hypermetropia with decreasing astigmatism and speculated that it was secondary to the development of compensatory lenticular or posterior corneal astigmatism.<sup>[16]</sup> However, the axis remained unchanged with time. Lambert also suggested that myopic astigmatism in these children is likely due to deformation of the cornea rather than form deprivation.<sup>[16]</sup>

### Poor visual acuity

Both children and adults can present with poor visual acuity due to FIDMTs.<sup>[6,13,14,16]</sup> The corneal trauma is usually unilateral, and therefore, the affected individuals are not categorized as completely blind but visually disabled.<sup>[6]</sup> Brightness acuity may also be decreased due to the presence of these tears. However, affected individuals can also remain asymptomatic with a normal visual acuity for entire life.<sup>[12]</sup>

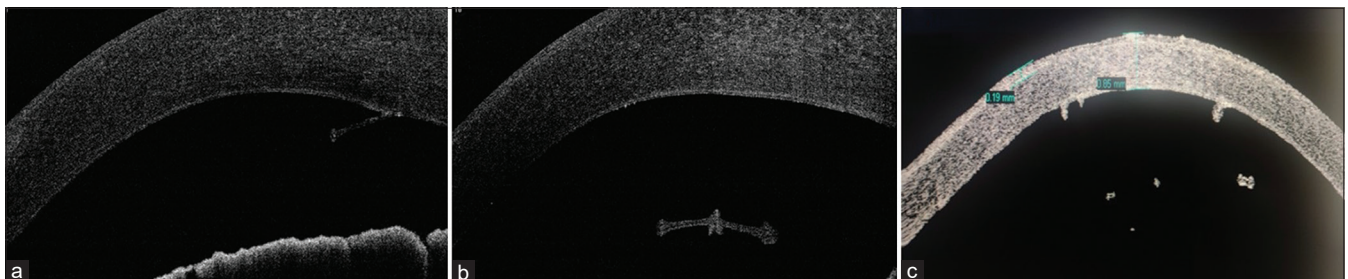
The cause of poor visual acuity in children is mainly due to form deprivation amblyopia resulting from

- Astigmatism: Breaks in the DM might allow expansion (and therefore flattening) of the cornea in a direction perpendicular to the long axis of the break. Induced astigmatism results from this flattening and compensatory steepening at 90°.

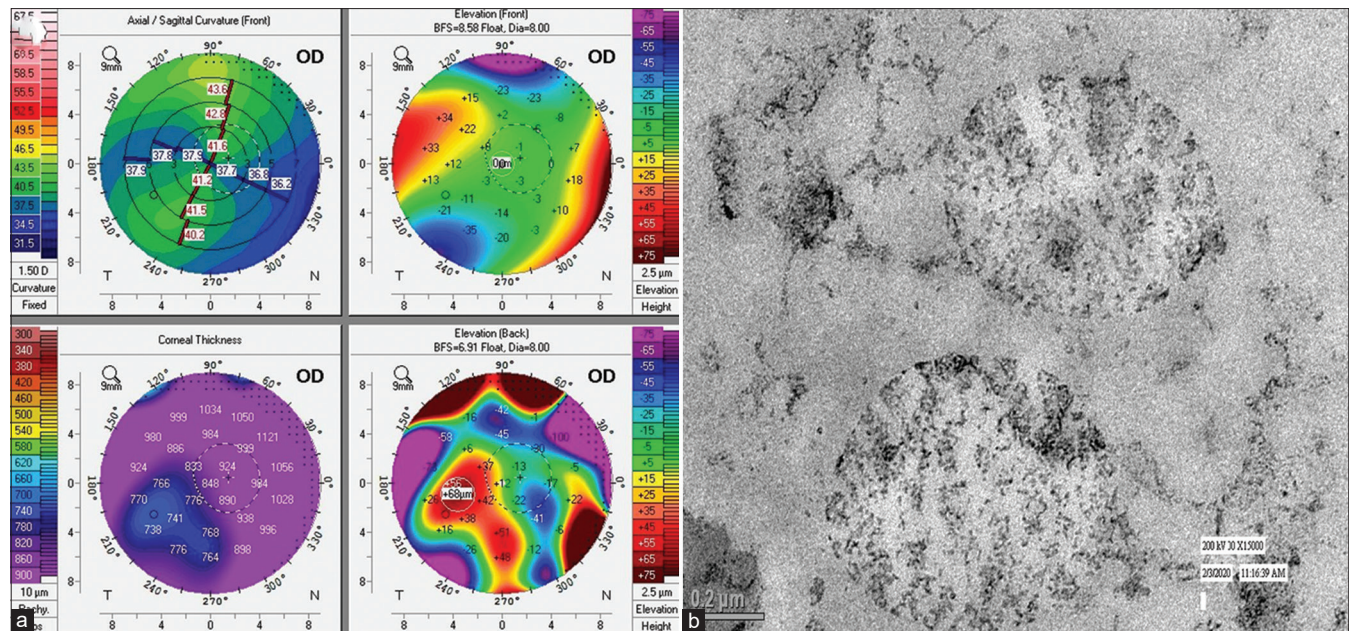
**Table 1: Findings of various investigations in FIDMT**

Slit-lamp examination <sup>[5,8,23,26]</sup>	Corneal stromal and epithelial edema DM tears
Anterior segment optical coherence tomography <sup>[5,8,23,26]</sup>	Hyperreflective linear structures or areas of focal hyperplasia projecting into the anterior chamber at the level of the posterior cornea to a depth of 100 and 430 μm. The other end of this membrane can be curled. Increased corneal thickness (438-837 μm) compared to the unaffected eye.
Specular microscopy <sup>[5,8,23,26]</sup>	Decreased endothelial cell counts (from undetectable to as high as 1992 cells/mm <sup>2</sup> ) Increased pleomorphism and polymegathism
<i>In vivo</i> confocal microscopy <sup>[5,8,23,26]</sup>	Normal to edematous superficial and basal epithelial cells, subepithelial nerve plexus, and stroma Within lesions Cicatricial highly reflective prominent scroll-structures above, at and behind the endothelium Bandlike structures presumably representing large fragments of thickened, hypertrophic, and protuberant DM and scar tissue Hyperreflective irregular inclusions corresponding to the lamellar, fibrous DM Severe reduction of EC density (450-650 cells/mm <sup>2</sup> ) with bright, nucleus-like spots within the cells Distortions of the cell layer profile in apical/mid-cornea Mildly decreased cell density (973 cells/mm <sup>2</sup> ), mild degree of pleomorphism, and polymegathism in the peripheral cornea
High-frequency ultrasound <sup>[5,8,23,26]</sup>	Increased corneal thickness Linear tear in DM Hypochoic Membrane on the posterior corneal surface
Corneal topography <sup>[5,8,23,26]</sup>	Regular astigmatism (+2D to +9D) correlating with the location of the striae (75°-110°) Increased corneal curvature (upto 56.60D) with steep keratometric axes parallel to the FIDMT Irregular astigmatism

\*FIDMT - Forceps-induced Descemet membrane tears; DM - Descemet membrane; EC - Endothelial cells



**Figure 2:** Appearance of FIDMT on ASOCT (a–c); note the rolled margins of torn DM and its thickening and protrusion in the anterior chamber



**Figure 3:** Astigmatism and high posterior elevation on corneal tomography (a), and proliferating endothelial cells in FIDMT (b)

- Anisometropia
- Corneal stromal edema/opacification in early life
- Opacities of the striae themselves
- Steep keratometry
- Associated ocular damage

While in adults, diminution of visual acuity can be attributed to

- Amblyopia
- Acute onset edema
- Chronic corneal decompensation of previously compromised endothelium.

### Exotropia

Sensory exotropia can also rarely be a primary presentation of this condition. This may result from disturbances in the fusion mechanism caused by FIDMTs and their complications that may induce severe obstacles to sensory perception.<sup>[9,18,19]</sup>

### Glaucoma

Most of the authors have reported a normal IOP in children with FIDMTs. Various authors such as Ponchel,<sup>[14]</sup> Kobayashi,<sup>[20]</sup> Kancherla,<sup>[21]</sup> and Hayashi<sup>[22]</sup> reported raised IOP after surgical interventions such as Descemet's puncture with air injection, Descemet stripping automated endothelial keratoplasty (DSAEK), and penetrating keratoplasty (PKP). The presumed mechanism could be localized iridocorneal adhesions, pupillary block glaucoma, inflammation, or steroid use. The effect of these tears on congenital glaucoma is yet to be evaluated. Childhood glaucoma, which has also been linked to traumatic hyphema, can also be rarely associated with FIDMTs.<sup>[22]</sup>

### Associated injuries

Along with FIDMT, obstetrical forceps can also cause damage to surrounding ocular structures. These associated injuries can indirectly aid clinicians in diagnosing missed FIDMTs. Few of the injuries, as reported by McDonald<sup>[6]</sup>, Kobayashi,<sup>[20]</sup> and Simpson,<sup>[23]</sup> include

- Ecchymosis
- Periorbital and eyelid edema

- Conjunctival injection
- Chemosis
- Hyphema
- Intraretinal hemorrhage
- Occipital depression
- Iris heterochromia
- Isolated DM detachment without FIDMT has also been associated with forceps-assisted delivery in a neonate<sup>[24]</sup>

## Investigations

Slit-lamp examination remains the first modality of visualizing FIDMTs [Fig. 1]. These ruptures are easily observable in retro or direct illumination. Sometimes, however, the overlying corneal edema may obscure finer details and accurate diagnosis may require imaging with sophisticated modalities such as anterior segment optical coherence tomography [ASOCT, Fig. 2] and high-frequency ultrasound.<sup>[25-27]</sup> Specular microscopy serves as a useful method of assessing the health of ECs, both qualitatively and quantitatively.<sup>[26]</sup> When this modality is not sufficient in obtaining cellular details, *in vivo* confocal microscopy may be helpful.<sup>[8,27,28]</sup> To determine the refractive changes induced by these tears, streak retinoscopy and corneal topography and tomography with the help of autokeratometry, Orbscan, and Pentacam [Fig. 3a] may be necessary. These investigations can guide appropriate refraction and help in ruling out keratoconus in affected individuals. Various findings of different imaging modalities are mentioned in Table 1.

## Histopathological Examination

### Light microscopy

Honig's classification based on the histological and ultrastructural findings includes four major types of obstetrical FIDMT:<sup>[29]</sup>

- Type I: Scroll formation at one margin of the break and DM extending into the anterior chamber at the other margin. It is suggested that these scrolls and protrusions of thickened

DM at the site of rupture indicate long-standing DM trauma and subsequent endothelial healing response that lays down many layers of new basement membrane to cover the defect<sup>[19]</sup>

- Type II: Scrolls of DM at both margins of the original break
- Type III: Fibrous proliferation around the area of break, creating a retrocorneal membrane
- Type IV: Small discontinuity in DM with minimal fibrosis
- Pecorella *et al.*<sup>[8]</sup> and Haddock *et al.*<sup>[13]</sup> described numerous histopathological findings such as
- Sparse or absent ECs at the site of rupture with remaining cells attenuated over the surface of the fold

#### Table 2: Differential diagnoses of FIDMT associated corneal problems

##### Differential diagnosis of Descemet's membrane tears<sup>[8,12,13,29]</sup>

Haab's striae  
Blunt trauma  
Surgical trauma  
Child abuse  
High myopia  
Reduplicated DM  
Idiopathic

##### Differential diagnosis of FIDMT-induced corneal edema<sup>[8,12,13,29]</sup>

Congenital glaucoma  
Posterior polymorphous corneal dystrophy  
Congenital hereditary endothelial dystrophy  
Mucopolysaccharidoses  
Posterior keratoconus  
Acute hydrops associated with keratoconus  
Fuch's endothelial corneal dystrophy  
Syphilitic interstitial keratitis

##### Differential diagnosis of astigmatism and steep cornea<sup>[8,12,13,29]</sup>

Keratoconus

\*FIDMT-Forceps-induced Descemet's membrane tears

- Invasion of EC cells into the DM from one site of rupture, forming a new basement membrane
- A thickened periodic acid-Schiff (PAS)-positive membrane with areas of nodular thickening at the edge of the initial break composed of concentric deposits of PAS-positive material on the stripped DM
- Full-thickness stromal scarring overlying the damaged endothelial area and scrolls, with occasional vacuolized large reactive keratocytes detected on CD34 immunohistochemistry
- A thick subepithelial fibrous layer and epithelial bullous edema

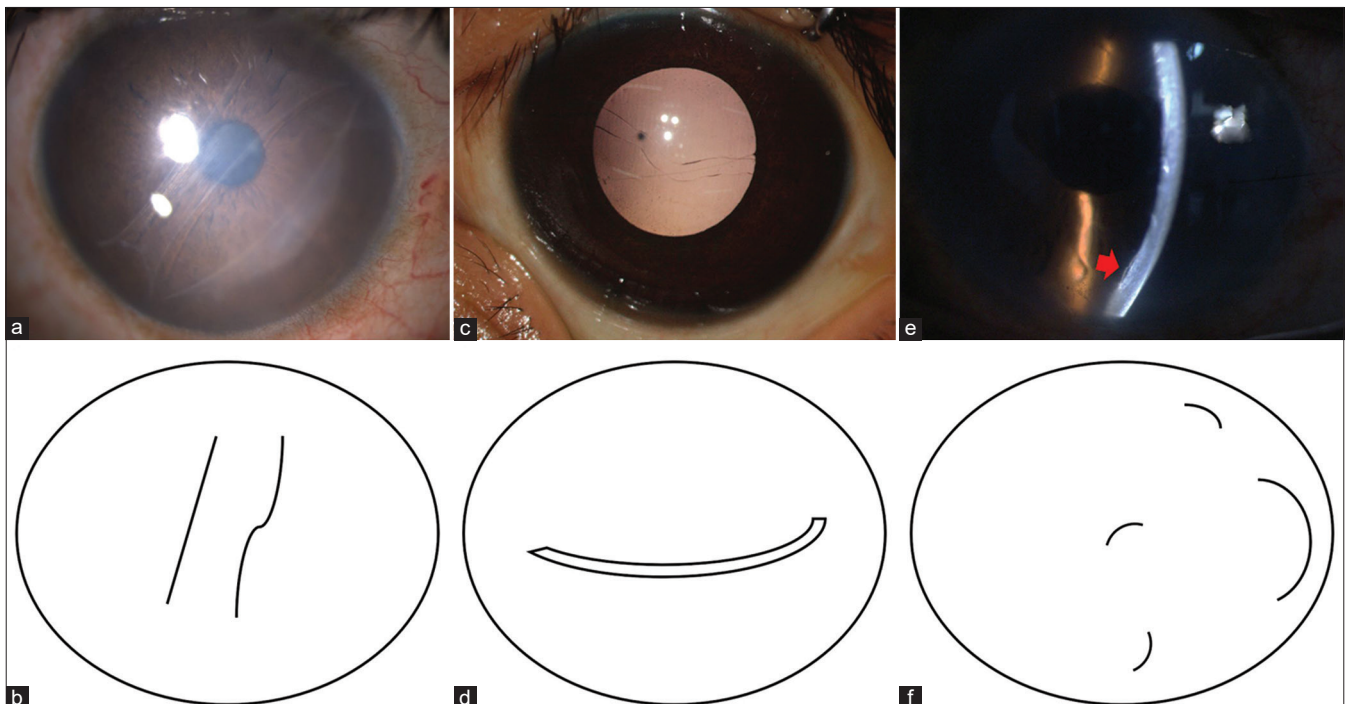
#### Transmission electron microscopy

Tetsumoto<sup>[19]</sup> observed the following findings on transmission electron microscopy

- Abnormal posterior collagenous layer at the site of DM fold composed of fine filaments, fusiform bundles of 110-nm banded material with subbands, amorphous basement-membrane-like material, and geographic appearance of banded material cutin
- Unusual epithelial transformation and proliferation of ECs [Fig. 3b] at both rupture sites of the DM, at the inner aspect of the DM, and at the level of the EC layer. These epithelial-like cells are characterized by desmosomal junctions, basal lamina, numerous microvilli, and 8-nm cytoplasmic filaments
- Fine filaments between the proliferating ECs in the DM and the endothelium. Anterior banded and posterior nonbanded portions of DM were not identified in both areas where EC cells were present or absent.

#### Scanning electron microscopy

- Folds in DM, spindle- and stellate-shaped cells and pigment granules, and attenuation or absence of endothelium in the area of the tear.



**Figure 4:** Vertical (a and b), horizontal (c and d), and random (e and f) orientation of FIDMT, Haab's striae, and surgically induced DM tears, respectively

## Diagnosis and Differential Diagnosis

Diagnosis of FIDMT is confirmed through a characteristic history of forceps use during birth and the presence of characteristic scrolled-DM tears. Yet, the diagnosis may sometimes become difficult when it is particularly tough to observe characteristic vertical DM scrolls and patients lack proper information concerning their birth or when their birth records are missing. In these cases, palpation of forceps-induced depressions around the ipsilateral orbital rim and the contralateral occipital region can be a quick, easy, and valuable method to support the diagnosis of forceps delivery or trauma, or both, and may assist in the diagnosis of forceps-induced corneal decompensation.<sup>[6,12]</sup> To establish an appropriate diagnosis in children, examination under anesthesia using ultrasound and handheld ASOCT is advised if prolonged corneal edema is noted after birth.<sup>[25]</sup>

Differential diagnoses of FIDMT and resultant corneal edema at different ages are mentioned in Table 2.<sup>[30,31]</sup> All these can be differentiated by careful history taking and clinical examination. Common differential diagnoses of FIDMTs recognized at birth include Haab's striae and congenital glaucoma. While FIDMTs are vertically oriented, unilateral, associated with with-the-rule

astigmatism, and have a characteristic history of birth trauma, Haab's striae are bilateral, horizontally oriented, associated with against-the-rule astigmatism, and lack any such history. It is because, unlike forceps injury, the force exerted in congenital glaucoma does not act in one direction. The corneal edema secondary to congenital glaucoma, unlike that secondary to FIDMT, is usually bilateral and associated with raised IOP and optic-nerve-head cupping. The DM tears associated with nonsurgical or surgical trauma and acute hydrops have varied orientations in contrast to FIDMT, which are usually oblique or vertical [Fig. 4].

## Management and Outcome

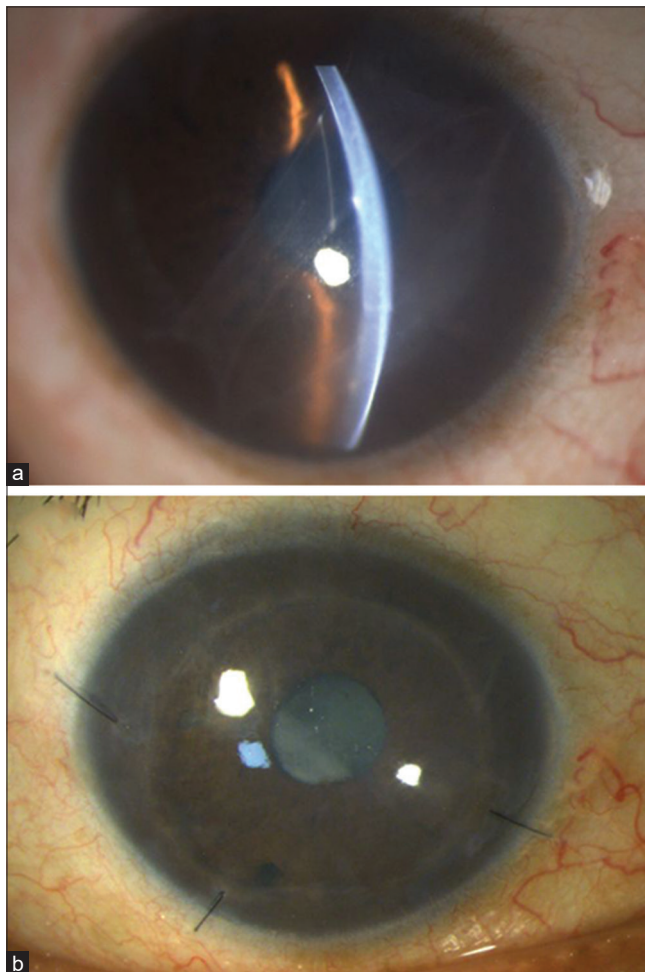
The management of FIDMT is dependent on its presentation and must be considered on a case-by-case basis.

### Conservative management

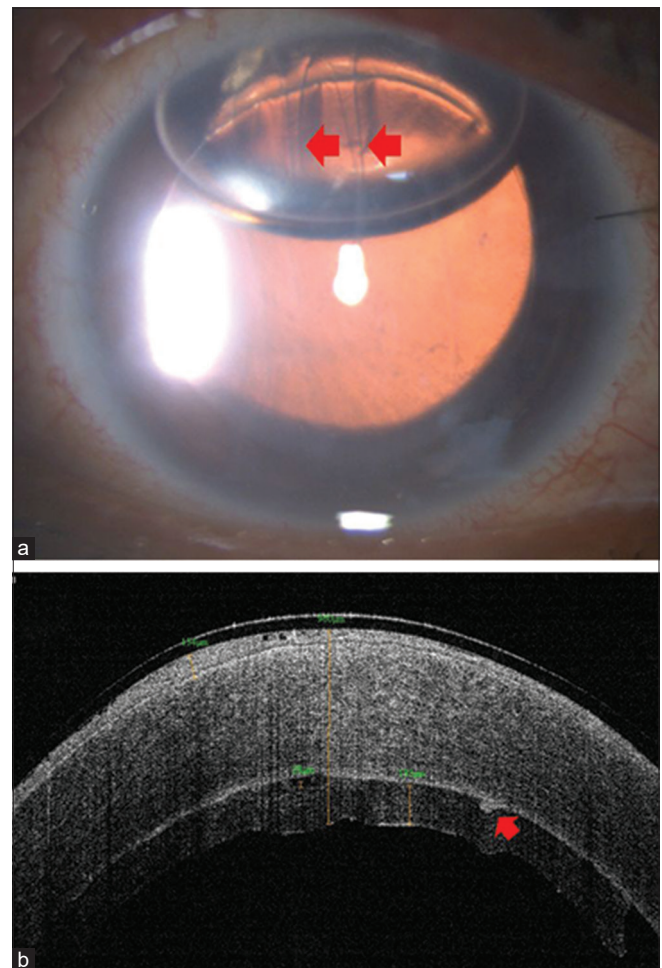
The corneal edema at birth usually resolves spontaneously in a few weeks and is commonly managed by observation alone.<sup>[30]</sup>

### Medical management

Clinicians, namely, Szaflik *et al.*,<sup>[27]</sup> and Ganesh *et al.*,<sup>[10]</sup> have tried hyperosmotic agents and topical steroids, respectively, for successful resolution of corneal edema associated with FIDMTs identified immediately after birth. In adults, these can be tried



**Figure 5:** Preoperative (a) and postoperative (b) appearance after DSAEK in FIDMT-induced corneal edema; note the clearing of cornea at 6 months after surgery



**Figure 6:** Attached DSAEK graft appreciated clinically (a) and on ASOCT (b) despite residual strands of rolled DM (red arrows)

**Table 3: Indications, surgical steps, and predictive factors for DSAEK in FIDMT**

Indications For DSAEK <sup>[13,14,20,21,31]</sup>
Symptomatic patient due to corneal edema
Clear cornea- when there is a difference in pachymetry, endothelial cell count, and visual acuity between both eyes
Striae-related visual disturbances
Preoperative assessment <sup>[13,14,20,21,31]</sup>
Degree of amblyopia
Careful history including consideration of previous visual function
Potential acuity measurement
Stromal opacity
Slit-lamp examination
Anterior segment optical coherence tomography
Astigmatism
Surgical steps <sup>[13,14,20,21,31]</sup>
To improve anterior chamber visualization
Epithelial debridement
Concomitant phacoemulsification-Trypan blue staining, endoilluminator, surgical slit-lamp
Graft insertion
Busin glide
Intraocular lens Sheet's glide
60:40 taco fold
Graft attachment
Corneal massage
Venting incision
Inferior peripheral iridectomy
Supine position for at least 1 hour
Wound apposition with sutures
Good predictors of visual outcome <sup>[13,14,20,21,31]</sup>
Mild - moderate amblyopia.
Absence of coexistent superficial stromal scarring,
Low-degree of preoperative astigmatism and anisometropia,
Absence of other ocular injuries such as retinal hemorrhage

for symptomatic improvement, and sometimes, these can be the only treatment measure required. For example, Szaflik *et al.*<sup>[27]</sup> reported improvement with hyperosmotic drops in a patient presenting with halos without much changes in visual acuity. However, these patients need periodic monitoring for signs of corneal decompensation due to a possible further reduction in EC density. After the resolution of corneal edema, the residual refractive error needs urgent attention due to the risk of anisometropia and dense amblyopia.<sup>[9]</sup> Prompt optical correction with spectacles/rigid gas permeable lenses along with aggressive patching therapy is important to prevent this permanent visual deficit.<sup>[16]</sup> However, in some cases, this treatment option is likely to be long-term and the visual results can be discouraging.<sup>[16]</sup>

### Surgical management

While some surgeons may refrain from surgical intervention because of severe amblyopia, others have described the benefits of corneal transplant in cases symptomatic due to corneal edema.<sup>[26]</sup> Sometimes, even clear corneas may require surgery. Ponchel *et al.*<sup>[14]</sup> suggested that the differences in pachymetry, EC count, and visual acuity between the two eyes were the first signs of endothelial decompensation of the affected cornea and preferred surgery in such cases. Early in life, intracameral air injection with puncture wounds over the detached DM has been tried by Kancherla *et al.*<sup>[21]</sup> for settling of DM detachment.

Kanellopoulos *et al.*<sup>[32]</sup> performed a combined topography-guided partial photorefractive keratectomy and Collagen cross-linking followed by phakic intraocular lens (IOL) implantation for secondary ectasia associated with FIDMTs. This was later succeeded by posterior chamber IOL implantation with good visual outcomes. Although these modalities may serve as useful alternative options to corneal transplant, accelerated EC loss due to multiple intraocular surgeries may still mandate a keratoplasty in the future.

Previously, PKP was the only surgical option to treat corneal edema and striae-related visual disturbances. Pecorella demonstrated a marked decrease in symptoms despite no improvement in visual acuity after PKP with IOL implantation in these eyes.<sup>[8]</sup> However, frequent complications of PKP in children limit its success rate. Recent studies have described the feasibility of DSAEK for this condition [Fig. 5].<sup>[13]</sup> It was first performed by Ponchel<sup>[14]</sup>, and the youngest reported case of DSAEK in this setting is that of an eight-year-old child.<sup>[20]</sup> It was previously presumed that DSAEK requires a completely smooth host corneal rear surface for donor attachment and irregular endothelial surface induced by FIDMTs could prevent its successful attachment.<sup>[27]</sup> However, with various authors recently reporting successful outcomes of DSAEK in similar eyes without notable complications, the trend appears to be changing [Fig. 6]. The indications, preoperative assessment, and surgical steps of DSAEK are compiled in Table 3.<sup>[14,20]</sup> Although the efficacy of DSAEK in clearing the affected cornea remains undisputed, sometimes, graft dislocation—either resolving with rebubbling or leading to primary donor failures—can also be encountered.<sup>[13,14,20,25,33]</sup> Presently, the effect of DSAEK grafts on astigmatism in FIDMTs remains unclear. While some believe that these do not affect preoperative astigmatism, others believe that centering the main incision on the steepest meridian could help in further decreasing it. However, the small incision used for DSAEK would probably be of limited effect in either decreasing or increasing the astigmatism, and if these eyes end up with high postoperative astigmatism, it is mostly a result of the patients' primary condition. Meticulous postoperative care is required for the early diagnosis and management of various complications, such as a rise in IOP and endothelial rejection, particularly in eyes subjected to concomitant cataract surgery.

The choice of DSAEK vs. PKP depends on the expertise of the surgeon and the availability of resources. As evident from various studies undertaken in the past three decades [Table 4], we can see that both PKP and DSAEK can be associated with poor visual outcomes in FIDMTs due to amblyopia, which is usually more severe if accurate refractive correction associated with occlusion therapy is not promptly started in the first few years after birth.<sup>[19]</sup> However, in eyes where the corneal edema occurs at a late stage in adulthood or in some cases where forceps lesions primarily involve the paracentral or peripheral cornea and spare the central optical zone, the outcome may be better.<sup>[33]</sup> Although the short-term outcomes (efficacy) are comparable between DSAEK and PKP, the incidence of late postoperative complications, such as rejection, suture-related complications, and wound dehiscence, remains higher in the latter group. Moreover, the postoperative outcomes of DSAEK in such eyes have been proven to be equivalent to those of DSAEK performed for other indications, except for slightly greater EC loss (43.9% and 33.18% according to Hayashi

**Table 4: A tabulated review of studies undertaken on FIDMT in the past three decades**

Author, year	No. of cases/eye	Age/sex	Symptoms	Visual acuity	Intervention	Outcome
Mc Donald, 1992 <sup>[6]</sup>	6/4R, 2L	41 (3-66) yr/M	DOV, CE	20/400-20/25	PKP in two eyes	-
Tetsumoto, 1993 <sup>[19]</sup>	4/3R	33-54 yr/2M, 2F	CE	2/100-25/20	PKP	2/100-60/100
Nelson, 1995 <sup>[12]</sup>	1/R	66 yr/F	Nil	20/20	No intervention	20/20
Gnanaraj, 2000 <sup>[18]</sup>	1/L	67 yr/M	Divergent squint	CF at 1m	Squint correction	CF at 1 m
Lambert, 2004 <sup>[16]</sup>	2/L	2-4 mon/M	CE		Rigid CL wear, amblyopia therapy	20/50-20/20
Szaflik, 2008 <sup>[27]</sup>	1/L	54 yr/M	DOV, Halos	20/24	Hyperosmotic agents	20/22
Ponchel, 2009 <sup>[14]</sup>	1/R	8 yr/M	Amblyopia	20/80	DSAEK	Graft dislocation, 20/32
Kanellopoulos, 2011 <sup>[32]</sup>	1/L	23 yr/M	Secondary ectasia	20/150	CXL, phakic IOL, posterior chamber IOL	20/25
Haddock, 2012 <sup>[13]</sup>	1/L	39 yr/M	DOV, halos, pain, photophobia	20/60	DSAEK	20/80
Ganesh, 2013 <sup>[10]</sup>	1/L	10 day/M	Lacrimation, photophobia, blepharospasm	20/30	Topical steroids	20/30
Hayashi, 2013 <sup>[22]</sup>	5/3L, 2R	41-54 yr/2M, 3F	Foreign-body sensation, blurred vision	20/1000-20/40	DSAEK±IOL	20/100-20/25
Alobaidy, 2014 <sup>[25]</sup>	1/L	72 yr/M	Referred for cataract surgery	6/60	No intervention	Dense amblyopia
Mandal, 2014 <sup>[28]</sup>	1/L	2 hours	CE	-	Conservative mx	-
Levecq, 2014 <sup>[11]</sup>	1/L	10 yrs		1/20	No intervention	1/20
Kobayashi, 2015 <sup>[20]</sup>	4/2L, 2R	51.5 yr (46-53)/1M, 3F	Irritation and severe light sensation	HM-0.15 logMAR	DSAEK±IOL	0.02-0.6 logMAR
Scorcia, 2015 <sup>[33]</sup>	7/4R, 3L	49.2 yr (39-60)/4M, 3F	CE	20/800 to 20/100	DSAEK±IOL	20/200-20/40
Pecorella, 2015 <sup>[8]</sup>	1/L	51 yr/F	Recurrent painful ulcers, Cloudy cornea	CF at 30 cm	PKP+IOL	1/6
Idoate, 2016 <sup>[9]</sup>	1	2 days/M	CE	-	Hyperosmolar solution	Resolved edema, astigmatism 6D
Kancherla, 2017 <sup>[21]</sup>	1/L	3 days/M	CE	-	Puncture wounds in DM with air injection	Resolved edema
Yadav, 2017 <sup>[15]</sup>	1/L	Adolescent/F	DOV	20/200	No intervention	20/100
Siwec Proscinska, 2017 <sup>[35]</sup>	1/R	4 yr/M	DOV	6/48	Spectacle correction, amblyopia therapy	-
Szigiato, 2019 <sup>[34]</sup>	1	69 years/M	--	20/150	DMEK followed by laser capsulotomy	20/30, amblyopia

\*DM - Descemet's membrane; DOV - Diminution of vision; CE - corneal edema CF - Counting finger; HM - Hand motion; PKP - penetrating keratoplasty; DSAEK - Descemet stripping automated endothelial keratoplasty; CXL - collagen cross -linking; IOL - Intraocular lens; DMEK - Descemet membrane endothelial keratoplasty

*et al.*<sup>[22]</sup> and Scorcia *et al.*<sup>[33]</sup>, respectively). Therefore, DSAEK might be considered to be an appropriate surgical technique in cases of FIDMTs with mild-to-moderate amblyopia. As successful corneal clearing after DSAEK requires an absence of preoperative stromal opacity, PKP may be preferred in eyes with anterior stromal scarring.<sup>[6]</sup> During concomitant cataract surgery, the choice of IOL usually remains a conventional monofocal IOL because amblyopic eyes may have minimal benefit with premium IOLs. In eyes undergoing DSAEK, toric IOLs can also be implanted to correct high- or even low-degree astigmatism. Presently, further prospective randomized studies are needed to elucidate the long-term outcomes of both

surgeries in these disorders. Szigiato *et al.*<sup>[34]</sup> recently reported good surgical results after Descemet Membrane endothelial keratoplasty (DMEK) in a pseudophakic adult with FIDMT. The patient was subsequently subjected to laser capsulotomy.

A comparative evaluation between different surgical and nonsurgical modalities employed for FIDMTs is yet awaited.

## Prevention

FIDMTs can be prevented in developing countries by providing the right medical and surgical care at the right time. Avoiding the use of forceps may not be feasible in developing



countries and is therefore not recommended considering the low incidence of this complication.<sup>[2,3]</sup> Therefore, awareness needs to be created among the consulting obstetricians and health care workers who employ forceps-assisted deliveries to examine the neonatal eyes by themselves or refer them to pediatricians or ophthalmologists for ruling out any such traumatic issues. Early diagnosis followed by accurate refractive correction and masking of the healthy eye within one year of birth may limit the visual morbidity associated with these tears.<sup>[14,16,20,35]</sup>

## Future Considerations

Early diagnosis of these disorders can be enhanced by a routine ophthalmic examination of the suspected infants, particularly those presenting with prolonged corneal clouding, under the magnification of an ophthalmic microscope. Whenever available, microscopes with an inbuilt real-time optical coherence tomography technology (i-OCT) can also be utilized for this purpose.<sup>[36,37]</sup> i-OCT may also improve the surgical success of posterior endothelial keratoplasty in eyes with hazy corneas.<sup>[38]</sup> Recent advances in the medical and surgical management of endothelial disorders in adults, such as Rho-kinase inhibitors, DMEK, and gene therapy, may also prove helpful for timely recovery of such lesions.<sup>[39-42]</sup>

## Conclusion

Despite its low incidence, FIDMTs can damage the eye with subsequent visual morbidity and recalcitrant amblyopia, which can be prevented by improved perinatal care. Once diagnosed, these injuries prompt urgent management of astigmatism to prevent dense and recalcitrant amblyopia in affected children. Surgical management can be reserved for symptomatic individuals, albeit with poor visual outcomes.

## Acknowledgement

We thank our institute for allowing us to continue with our research work.

## Key statement

Obstetrical forceps-induced Descemet membrane tears, though rare, can lead to a significant loss in affected children. The present review may aid in their better diagnosis and management.

## Financial support and sponsorship

Nil.

## Conflicts of interest

There are no conflicts of interest.

## References

1. Truc H. Lesions ostetricales de l'oeil et de ses annexes. *Ann Ocul* 1898;119:161.
2. Jain IS, Singh YP, Gupta SL, Gupta A. Ocular hazards during birth. *J Pediatr Ophthalmol Strabismus* 1980;17:14-6.
3. Dupuis O, Silveira R, Redarce T, Dittmar A, Rudigoz RC. Instrumental extraction in 2002 in the "aurore" hospital network: Incidence and serious neonatal complications. *Gynecol Obstet Fertil* 2003;31:920-6.
4. Sridhar MS. Anatomy of cornea and ocular surface. *Indian J Ophthalmol* 2018;66:190-4.
5. McAnena L, O-Keefe M, Kirwan C. Forceps delivery-related ophthalmic injuries: A case series. *J Pediatr Ophthalmol Strabismus* 2015;52:355-9.
6. McDonald MB, Burgess SK. Contralateral occipital depression related to obstetric forceps injury to the eye. *Am J Ophthalmol* 1992;114:318-21.
7. Lesueur L, Arne JL, Mignon-Conte M, Malecaze F. Structural and ultrastructural changes in the developmental process of premature infants' and children's corneas. *Cornea* 1994;13:331-8.
8. Pecorella I, Tiezzi A, Appolloni R, Plateroti A, Plateroti R. Late corneal decompensation after obstetrical forceps ocular trauma at birth: Corneal decompensation after forceps delivery. *Clin Exp Optom* 2015;98:387-9.
9. Idoate A, Ascaso F, Perez D, Remón L, Perez I, Almenara C, et al. Rupture of Descemet's membrane associated with forceps delivery. *Acta Ophthalmologica* 2016;94. doi: 10.1111/j.1755-3768.2016.0608.
10. Ganesh S, Arora P, Arora K. Descemet membrane breaks following forceps delivery. *Indian Pediatr* 2013;50:257.
11. Levecq L, Francart D, Van Hollebeke I. Ruptures in Descemet's membrane due to forceps injuries: Appearance clinically and on optical coherence tomography. *J Fr Ophthalmol* 2014;37:173-5.
12. Nelson MD. Rupture of Descemet's membrane secondary to presumed forceps trauma. *Clin Eye Vision Care* 7 1995;195-201.
13. Haddock LJ, Dubovy SR, Perez VL. Histopathological findings after Descemet's stripping automated endothelial keratoplasty for the management of Descemet's membrane breaks secondary to obstetrical forceps injury. *Case Rep Ophthalmol Med* 2012;2012:474795.
14. Ponchel C, Malecaze F, Arné J-L, Fournié P. Descemet stripping automated endothelial keratoplasty in a child with Descemet membrane breaks after forceps delivery. *Cornea* 2009;28:338-41.
15. Yadav S, Singh A, Tandon R. Folds in Descemet membrane associated with forceps-induced injury. *JAMA Ophthalmol* 2017;135:e170669.
16. Lambert SR, Drack AV, Hutchinson AK. Longitudinal changes in the refractive errors of children with tears in Descemet's membrane following forceps injuries. *J AAPOS* 2004;8:368-70.
17. Angell L, Robb RM, Berson FG. Visual prognosis in patients with ruptures in Descemet's membrane due to forceps injuries. *Arch Ophthalmol* 1981;99:2137-9.
18. Gnanaraj L, Rao VJ. Corneal birth trauma: A cause for sensory exotropia. *Eye (Lond)* 2000;14(Pt 5):791-2.
19. Tetsumoto K, Kubota T, Rummelt V, Holbach LM, Naumann GO. Epithelial transformation of the corneal endothelium in forceps birth-injury-associated keratopathy. *Cornea* 1993;12:65-71.
20. Kobayashi A, Yokogawa H, Mori N, Sugiyama K. Case series and techniques of Descemet's stripping automated endothelial keratoplasty for severe bullous keratopathy after birth injury. *BMC Ophthalmol* 2015;15:92.
21. Kancherla S, Shue A, Pathan MF, Sylvester CL, Nischal KK. Management of descemet membrane detachment after forceps birth injury. *Cornea* 2017;36:375-6.
22. Hayashi T, Hirayama Y, Yamada N, Shimazaki-Den S, Shimazaki J. Descemet stripping automated endothelial keratoplasty for bullous keratopathy with an irregular posterior surface. *Cornea* 2013;32:1183-8.
23. Simpson SM, Yau G, Nischal KK, Strube YNJ. Forceps trauma in a newborn presenting as iris heterochromia. *J AAPOS* 2017;21:425-6.
24. Diaz-Aljaro P, Monés-Liivina A, Romanic-Bubalo N, Castillo Capponi F, Sabala-Llopart A. Management of Descemet membrane detachment secondary to forceps assisted delivery in a newborn. *Arch Soc Esp Oftalmol* 2020;95:447-50.
25. Alobaidy R, Srinivasan S. Forceps-induced birth injury to the

- cornea. *BMJ Case Rep* 2014;2014:bcr2013201786. doi: 10.1136/bcr-2013-201786.
26. Kaur S, Kaushik S, Singh Pandav S. Traumatic glaucoma in children. *J Curr Glaucoma Pract* 2014;8:58-62.
  27. Szaflik JP, Ołdak M, Kwiecień S, Udziela M, Szaflik J. Optical coherence tomography and *in vivo* confocal microscopy features of obstetric injury of the cornea. *Cornea* 2008;27:1070-3.
  28. Casamenti V, Benedetti S, Benedetti M. Obstetrical forceps injury to the eye: *In vivo* confocal microscopy evaluation. *Invest Ophthalmol Vis Sci* 2005;46:2729.
  29. Honig MA, Barraquer J, Perry HD, Riquelme JL, Green WR. Forceps and vacuum injuries to the cornea: Histopathologic features of twelve cases and review of the literature. *Cornea* 1996;463-72.
  30. Mandal AK, Gothwal VK. Obstetric forceps injury mimicking unilateral congenital glaucoma. *Arch Dis Child Fetal Neonatal Ed.* 2014;99:F308.
  31. Bhagat S, Mikhail M, Boyle N. Rupture of Descemet's membrane secondary to presumed non-accidental injury. *Eye (Lond)* 2015;29:716-8.
  32. Kanellopoulos AJ, Skouteris VS. Secondary ectasia due to forceps injury at childbirth: Management with combined topography-guided partial PRK and collagen cross-linking (Athens Protocol) and subsequent phakic IOL implantation. *J Refract Surg* 2011;27:635-6.
  33. Scordia V, Pietropaolo R, Carnevali A, De Luca V, Lucisano A, Busin M, et al. Results of descemet stripping automated endothelial keratoplasty for the treatment of late corneal decompensation secondary to obstetrical forceps trauma. *Cornea* 2016;35:305-7.
  34. Sziagiato AA, Choremis J, Talajic JC. Repair of forceps-induced Descemet's rupture with Descemet's membrane endothelial keratoplasty. *Ophthalmology* 2019;126:551.
  35. Siwiec-Prościńska J, Szczapa-Jagustyn J, Gotz-Więckowska A, Kocięcki J. High myopic astigmatism secondary to Descemet's membrane tears after forceps-assisted delivery. *Clin Exp Optom* 2018;101:611-2.
  36. Siebelmann S, Hermann M, Dietlein T, Bachmann B, Steven P, Cursiefen C. Intraoperative optical coherence tomography in children with anterior segment anomalies. *Ophthalmology* 2015;122:2582-4.
  37. Sharma N, Priyadarshini K, Agarwal R, Bafna RK, Nagpal R, Sinha R, et al. Role of microscope-intraoperative optical coherence tomography in paediatric keratoplasty: A comparative study. *Am J Ophthalmol* 2020;221:190-198.
  38. Sharma N, Devi C, Agarwal R, Bafna RK, Agarwal A. i-PDEK: Microscope-integrated optical coherence tomography assisted pre-descemet endothelial keratoplasty. *J Cataract Refract Surg* 2021. doi: 10.1097/j.jcrs.0000000000000603.
  39. Kinoshita S, Koizumi N, Ueno M, Yokota I, Teramukai S, Sotozono C, et al. Injection of cultured cells with a ROCK inhibitor for bullous keratopathy. *N Engl J Med* 2018;378:995-1003.
  40. Gonnermann J, Klamann MKJ, Maier AK, Bertelmann E, Schroeter J, von Au K, et al. Descemet membrane endothelial keratoplasty in a child with corneal endothelial dysfunction in Kearns-Sayre syndrome. *Cornea* 2014;33:1232-4.
  41. Moloney G, Petsoglou C, Ball M, Kerdraon Y, Höllhumer R, Spiteri N, et al. Descemetorhexis without grafting for fuchs endothelial dystrophy-supplementation with topical ripasudil. *Cornea* 2017;36:642-8.
  42. Davies E, Jurkunas U, Pineda R 2<sup>nd</sup>. Predictive factors for corneal clearance after descemetorhexis without endothelial keratoplasty. *Cornea* 2018;37:137-40.