

All-Inside Anterior Cruciate Ligament Reconstruction with Suture Tape Augmentation: Button Tie-Over Technique (BTOT)



Ahmed Hassan Waly, M.D., Hosam Ibraheiem ElShafie, M.D.,
Mohamed Gamal Morsy, M.D., Marwan Hosam ElShafie, M.D., Mostafa Ashraf Galal,
El Hussein Mohamed Ayman, and Hesham Mohamed Gawish, M.D.

Abstract: The anterior cruciate ligament (ACL) is the most common ligamentous knee injury in pivoting sports. There are multiple techniques described for ACL reconstruction; however, still there is an ongoing debate regarding the optimal technique with minimal residual laxity and least risk of rerupture. All-inside ACL reconstruction with suture tape augmentation (InternalBrace) is a newly developed method of ACL reconstruction to help address these issues. Suture tape protects the graft during ligamentization process. The aim of this article is to describe a modified all-inside ACL reconstruction technique with suture tape augmentation in which the internal brace is tied distally over the distal TightRope button without an extra method of fixation.

Introduction (With Video Illustration)

Anterior cruciate ligament reconstruction (ACLR) with a full tibial tunnel is the most commonly used technique. Despite its high success rates, it is still challenged by residual laxity and graft rupture.¹

In the all-inside ACLR technique, the tibial tunnel is replaced by bone socket.² To help prevent future anterior cruciate ligament (ACL) failures with the all-inside technique, new modifications have been employed that incorporate suture augmentation.³⁻⁵ This augmentation uses an ultra-high molecular-weight polyethylene/polyester tape that serves as an internal brace. The tape integrates flawlessly into a quadrupled semitendinosus tendon graft construct. This

enhances the biomechanical properties of the ACL GraftLink construct.⁶

The goal of this augmentation is to protect the newly reconstructed ligament during the ligamentization process and the accelerated rehabilitation. The internal bracing techniques described incorporate a braided suture tape inside the graft that is independently fixed with a knotless bone anchor to reinforce the ligament acting hence as a secondary stabilizer.⁷⁻⁹

The aim of this article is to provide a new surgical technique for suture tape augmentation in ACLR where the internal brace strands are tied distally over the distal TightRope button (Arthrex, Naples, FL) without an extra method of fixation like the SwiveLock anchor (Arthrex) ([Video 1](#)).

From the Department of Orthopaedic Surgery and Traumatology, Arthroscopy and Sports Injury Unit, Alexandria University, Alexandria (A.H.W., H.I.E., M.G.M., M.H.E., M.A.G., E.H.M.A.); and Department of Orthopaedic Surgery and Traumatology, Kafr El Sheikh University, Kafr El Sheikh (H.M.G.), Egypt.

The authors report that they have no conflicts of interest in the authorship and publication of this article. Full ICMJE author disclosure forms are available for this article online, as [supplementary material](#).

Received May 14, 2021; accepted July 27, 2021.

Address correspondence to Mohamed Gamal Morsy, M.D., 8 Toson Street, Flat 206, 21411 Gleim, Alexandria, Egypt. E-mail: morsimoh@gmail.com

© 2021 THE AUTHORS. Published by Elsevier Inc. on behalf of the Arthroscopy Association of North America. This is an open access article under the CC BY-NC-ND license (<http://creativecommons.org/licenses/by-nc-nd/4.0/>).
2212-6287/21734

<https://doi.org/10.1016/j.eats.2021.07.040>

Surgical Technique

Patient Setup

The patient is placed supine with a lateral post just proximal to the knee for access into the medial compartment and prevention of hip external rotation. Examination under anesthesia is performed first to exclude other ligamentous injuries. Standard anterolateral and anteromedial arthroscopic portals are used. A diagnostic arthroscopy is performed, and any concurrent intraarticular pathology is tackled. The femoral footprint is identified and prepared with preservation of the ACL remnant. The tibial ACL stump is partially

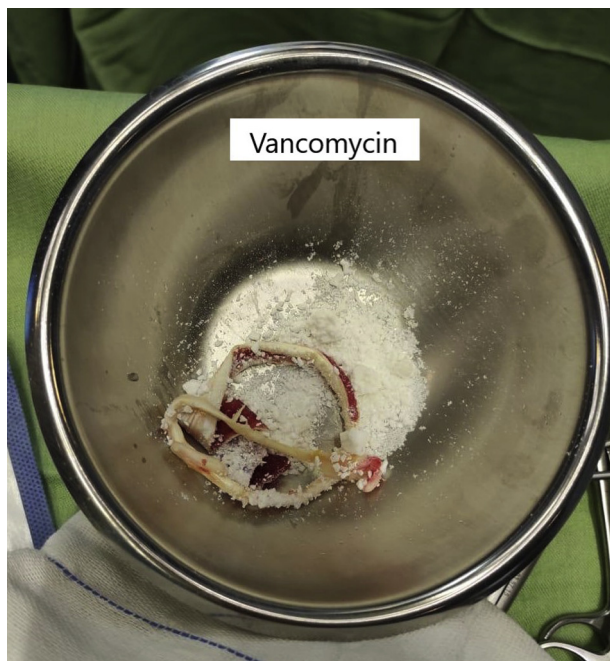


Fig 1. The semitendinosus graft is soaked in vancomycin powder.

excised to prevent graft dislodgement during graft passage from inside the knee.

Graft Harvest

Only the semitendinosus is harvested using an open-ended tendon stripper (Pigtail Hamstring Tendon Stripper; Arthrex). The gracilis is usually preserved in this technique unless the semitendinosus is not of adequate length or prematurely amputated. The graft is soaked with 1 g of vancomycin powder before and after its preparation (Figs 1 and 2).

GraftLink Preparation

GraftLink is prepared according to Lubowitz et al.^{6,10} High-strength suture (FiberWire No.2-0; Arthrex) is used to secure the graft in a loop fashion between ACL femoral and tibial TightRopes (Arthrex) (Fig 3).

The graft is then quadrupled over itself and tubularized with no. 2-0 FiberWire. The graft length should be approximately 65 to 70 mm. The graft length must be less than the sum of femoral socket length plus intra-articular graft distance plus tibial socket length. This prevents slackness of the graft after fixation (Fig 4).

The first distance that should be measured and marked on the GraftLink construct is the length of collagen within the femoral socket. The goal is to maximize collagen in the socket and to ensure that the graft is not bottoming out during tensioning. A typical amount of graft in the femoral socket is 20 mm. This distance is marked on the graft itself, measuring from the femoral graft end. When the mark on the graft itself reaches the femoral socket orifice during graft passage,

gets the surgeon to know that the femoral graft tensioning is complete. This is repeated for the tibial side of the graft (Fig 5).

FiberTape Augmentation

A FiberTape (Arthrex) is shuttled through each hole of the button of the femoral TightRope fixation device. Shuttling of the FiberTape through the button can be assisted by a nitinol suture passer (Fig 6). The strands of the FiberTape (Arthrex) suture are then crossed and wrapped around the graft bundles, creating a self-reinforcing suture noose when tied (Figs 7 and 8).

ACL Femoral Socket

Minimal soft-tissue notchplasty is performed. It is essential to precisely identify the anatomic ACL footprint. The scope is then shifted to the anteromedial (AM) portal. The AM portal viewing provides an improved perspective for analyzing the ACL femoral footprint anatomy. After that, the FlipCutter ACL femoral marking hook (FlipCutter; Arthrex) is locked in the FlipCutter guide ring at an angle of approximately 100° to 110°. The FlipCutter guide pin sleeve is advanced to the level of the skin at a point approximately 1 cm anterior to the posterior border of the iliotibial band and 2.5 cm proximal to the lateral femoral condyle. A stab incision is made through the skin and the iliotibial band, and the cannulated guide pin sleeve for the FlipCutter is pushed hard to the bone by the usage of a blunt trocar. A laser mark indicates the femoral intraosseous distance (about 7 mm). The FlipCutter is advanced with forward drilling into the knee. The FlipCutter handle is loosened, and a handle switch flips the guide pin tip into the retrograde drilling position. With continued forward drilling using retrograde force, the femoral socket is drilled in a retrograde manner until reaching the appropriate length of the femoral socket. A shuttle suture is then advanced through a cannulated guide pin sleeve.

Alternatively, the ACL femoral socket can be drilled from accessory AM portal. The Spade tip drill (Arthrex)

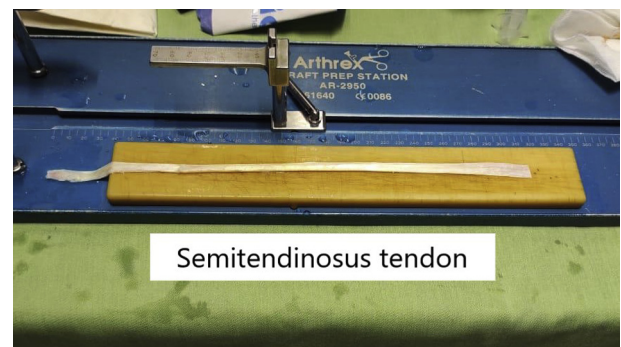
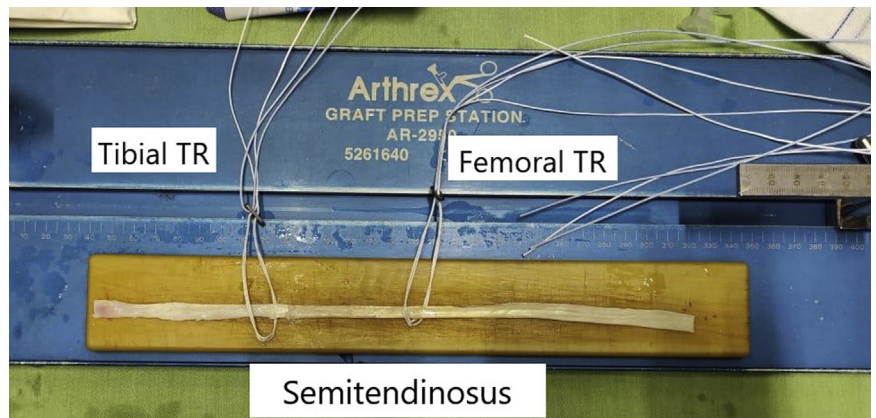


Fig 2. The semitendinosus graft is used alone in this technique. All muscular tissues and connections are removed.

Fig 3. The GraftLink is prepared using 2 TightRopes (TR). The graft is secured in a loop fashion between the 2 buttons.



is used to drill the femoral tunnel. A low-profile reamer of the same graft size is then used to drill femoral socket. The low-profile reamers facilitate femoral socket preparation through the medial portal. It has a thin shaft and “2-flute” design that provide a flat profile that easily passes through the portal and avoids damaging the femoral condyle and the posterior cruciate ligament. The reduced length of the flutes allows the drill to spin without contacting the posterior cruciate ligament fibers (Fig 9).

ACL Tibial Socket

With the arthroscope in the anterolateral portal, the FlipCutter ACL tibial C-guide (Arthrex) is locked on the FlipCutter guide ring at an angle of approximately 55° to 60°. The guide position and the angle are optimized

to maximize the tibial interosseous distance so that the graft would not bottom out during tensioning. A distance of at least 37 mm will result in a 30-mm socket depth with a 7-mm cortical bone bridge. The distance may be read before drilling by the use of the laser marks on the FlipCutter guide pin sleeve. As a preventative measure, if the distance is short, the guide should be readjusted before drilling.

A second-generation retrograde drill (FlipCutter; Arthrex) is used to create the socket. The FlipCutter guide pin is drilled through a unique graduated-tip guide pin sleeve with a stepped 7-mm-long narrow tip. This tip should be tapped inside the AM tibial metaphyseal cortex until it reaches palpable resistance to further tip advancement. Further advancement more than 7 mm may lead to cortical blow out and

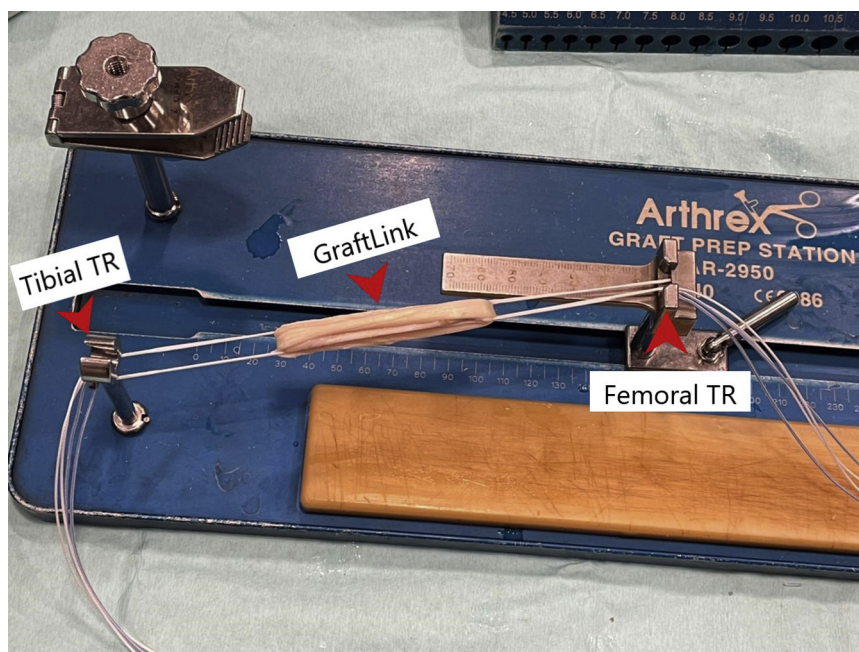


Fig 4. The prepared GraftLink measuring about 65-mm folded between femoral and tibial TightRopes (TR; red arrows).




Fig 5. The GraftLink is marked using FiberWire 2-0 suture at a distance of 20 mm at both femoral and tibial sides.

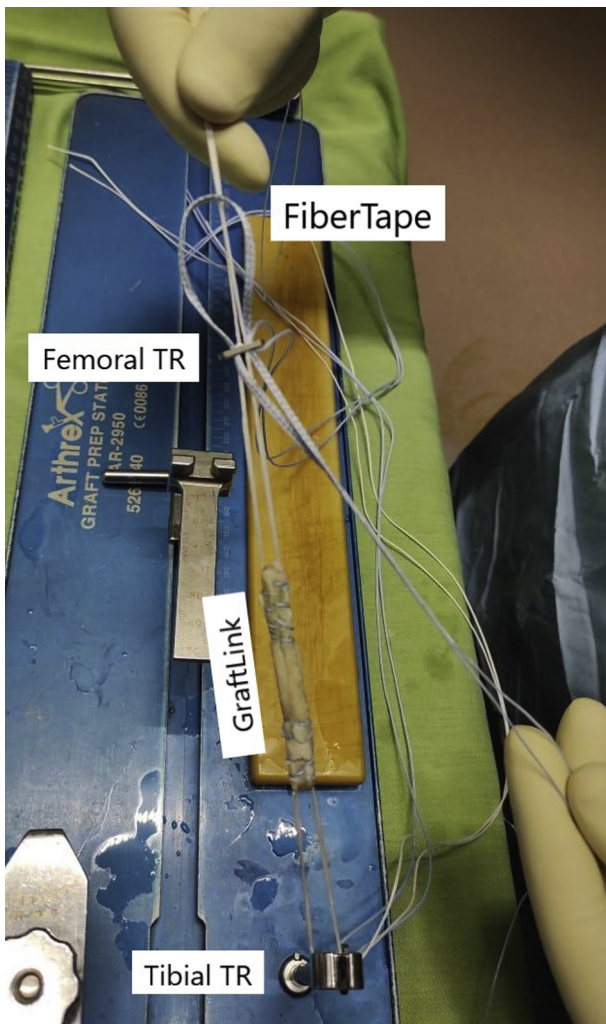


Fig 6. The FiberTape is loaded over femoral TightRope (TR) through the holes of the suspensory sutures.

conversion of the socket into a tibial tunnel. The Flip-Cutter is advanced with forward drilling into the knee. The FlipCutter handle is loosened, and a handle switch flips the guide pin tip into the retrograde drilling position. Next, the FlipCutter cannulated guide pin sleeve with the graduated 7-mm stepped tip is tapped with a mallet and advanced until resistance is felt when the step hits the cortex and the laser mark indicates 7 mm. The guide pin sleeve is firmly held in place at the proper angle and not removed. With continued forward drilling but with retrograde force, the tibial socket is drilled in a retrograde manner to create a 30-mm socket. The FlipCutter is pushed back into the knee, flipped back into the guide pin mode, and then removed. The cannulated guide pin sleeve is not removed. Cortical

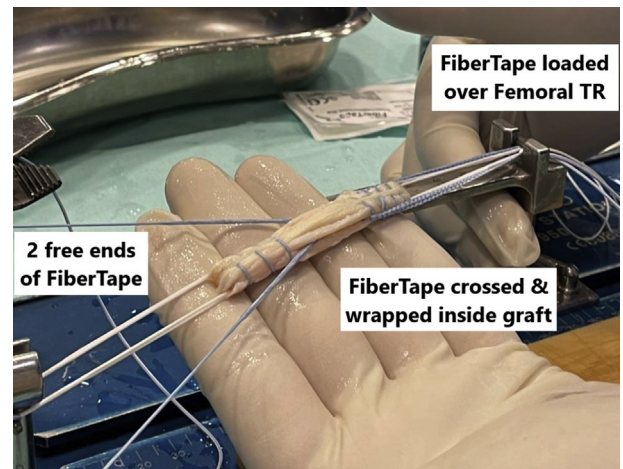
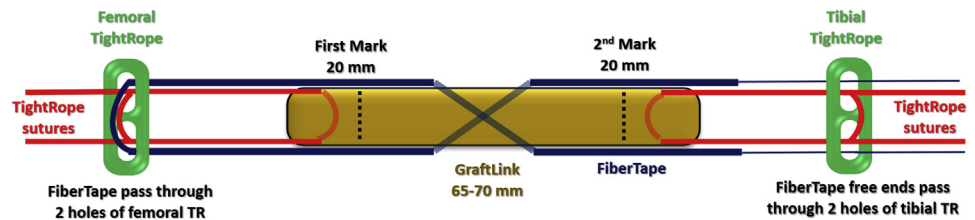


Fig 7. The FiberTape suture is crossed and wrapped inside the GraftLink construct. (TR, TightRope.)

Fig 8. An illustration showing the augmentation of the GraftLink with FiberTape (blue suture). The FiberTape is loaded over femoral TightRope (TR) through the holes of the suspensory sutures (red sutures). The tape is then wrapped and crossed inside the graft. The 2 free ends of the tape (blue sutures) are loaded later over tibial TightRope.



preservation is required for cortical suspensory fixation by use of TightRope (Fig 10).

After the FlipCutter is removed, the sleeve is left in place, facilitating simple and reproducible passage of the graft-passing sutures for later graft passage, and serving also as a cannula.

Suture Shuttling

The use of a flexible silicone cannula (PassPort; Arthrex) in the AM arthroscopic portal facilitates suture shuttling from femoral and tibial sockets by preventing soft-tissue interposition. Grafts up to 9.5 mm in diameter can be passed through the AM portal through a 10-mm-diameter PassPort cannula. For larger-diameter grafts, the cannula should be removed before graft passage.

Femoral and tibial graft-passing sutures are retrieved. A technical pearl is to retrieve the femoral and tibial graft-passing sutures from the AM arthroscopic portal at the same time to avoid suture tangling or soft-tissue interposition. To further ensure that the sutures are not tangled, a sliding, open-loop suture retriever can be used. This device should run the length

of the femoral and tibial sutures independently from intra-articular to extra-articular through the cannula (Fig 11).

Graft Passage Into the Femoral Socket

Once the sutures are absolutely not tangled, the femoral TightRope sutures are shuttled through the AM portal. Generally, A flip-then-fill technique is used. The femoral adjustable loop is retrieved from AM portal until the graft is seen at tibial orifice intra-articularly indicating that the button has exited the femoral cortex proximally and is ready to flip. Once the button flips, the graft is then pulled hard into femoral socket. Next, a back-and-forth tension is applied on each free end of the femoral pull suture, tensioning the graft up into the socket until the graft reaches the socket orifice. A technical pearl technique is to partially seat the femoral side of the graft and then pass the tibial side so that the graft depth in the sockets can be “fine-tuned” during tensioning. Usually only 1 to 1.5 cm of the graft is pulled inside femoral socket during femoral TightRope tensioning (Fig 12).

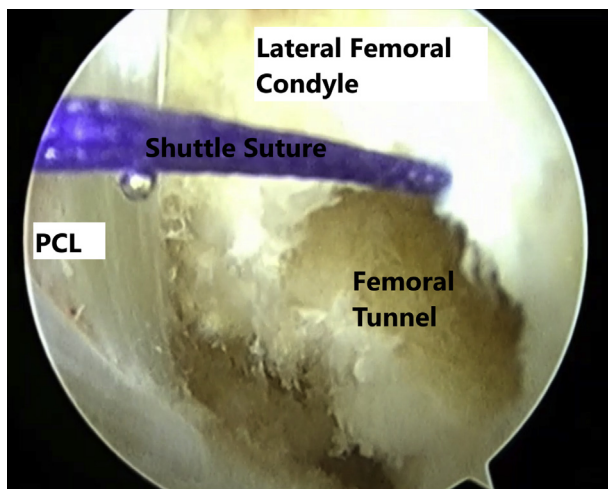


Fig 9. Arthroscopic view through the anteromedial portal in left knee showing the anterior cruciate ligament femoral socket on its anatomical footprint. A no. 2 VICRYL shuttle suture passed through the femoral socket. (PCL, posterior cruciate ligament.)

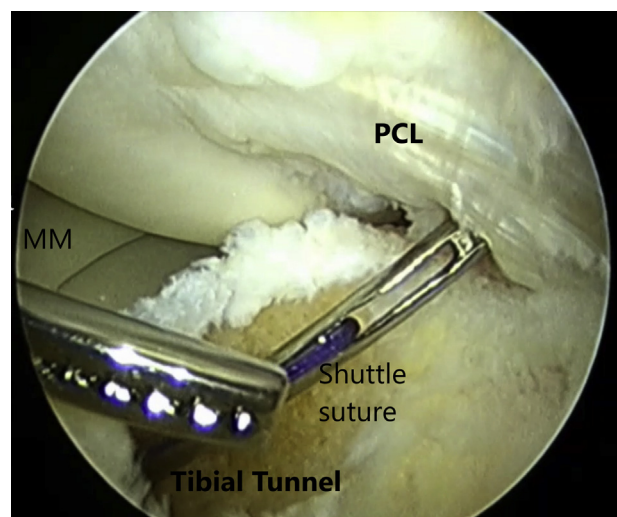


Fig 10. Arthroscopic view through the anterolateral portal of left knee showing the anterior cruciate ligament tibial socket with a no. 2 VICRYL shuttle suture. (MM, medial meniscus; PCL, posterior cruciate ligament.)

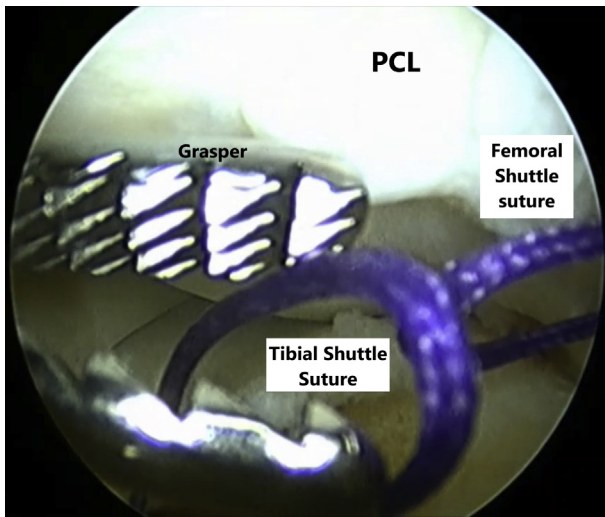


Fig 11. Arthroscopic view through anterolateral portal of left knee showing that the femoral and tibial shuttle sutures are retrieved through the same portal (medial portal) using a grasper forceps. (PCL, posterior cruciate ligament.)

Passing the Internal Brace Through the Tibial TightRope

The tibial TightRope and internal brace sutures are then retrieved through the tibial socket to the outside. Once the tibial TightRope and the internal brace sutures are outside the tibial cortex, the FiberTape strands are then shuttled through the TightRope holes alongside the TightRope sutures (Figs 13 and 14). Now, the tibial TightRope is loaded with 2 white sutures for graft tensioning and 2 blue sutures for internal brace tensioning (Fig 15).

GraftLink and Internal Brace Tensioning

The graft is then pulled through the tibial socket after tensioning the white strands of the tibial TightRope.

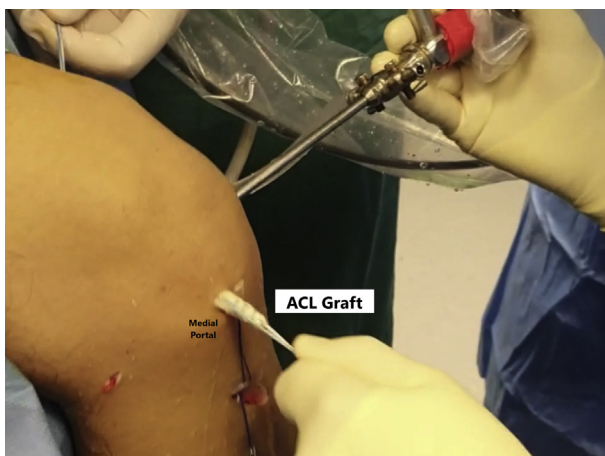


Fig 12. The anterior cruciate ligament (ACL) graft is pulled through the medial portal of the left knee into the femoral socket.

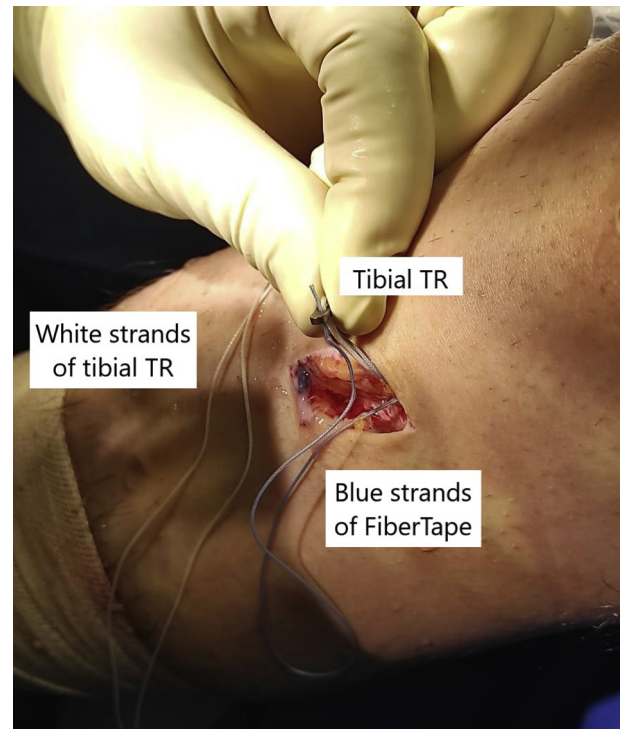


Fig 13. Shuttling the first blue strand of FiberTape alongside with the white strand of tibial TightRope (TR) through same holes.

Care should be taken to avoid any soft-tissue interposition between the tibial cortex and the TightRope.

Final femoral and tibial tensioning is performed in 15 to 20° of knee flexion, allowing at least 2 cm of the graft inside each socket. An overly long graft will bottom out on the socket floor and is therefore not acceptable. The

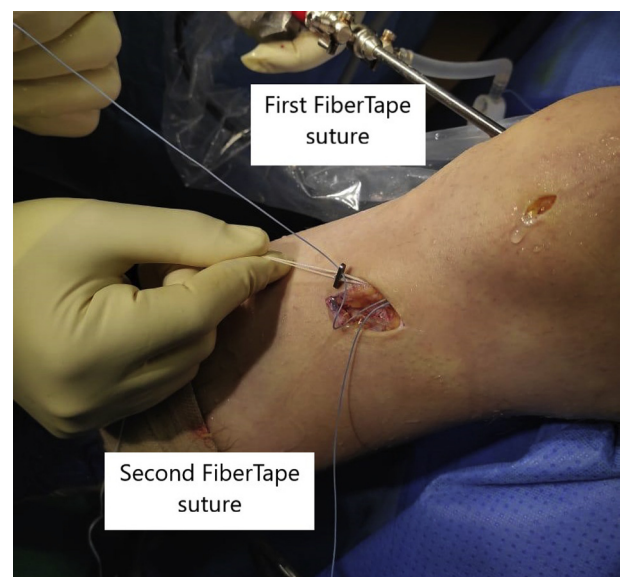


Fig 14. Passing the second FiberTape suture through the tibial TightRope.

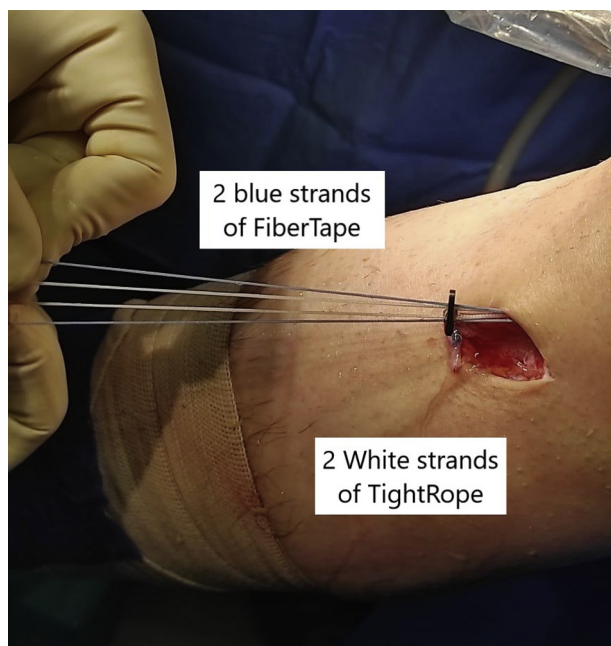


Fig 15. The tibial TighTRope is now loaded with 2 FiberTape sutures (blue) and 2 suspensory sutures (white).

knee is moved through its range of motion, and additional tension may be applied by pulling the femoral or tibial pull sutures by hand. A reverse Lachman maneuver is performed as tensioning is applied (Fig 16).

This is followed by suture tape (InternalBrace; Arthrex) tensioning in full/hyper extension and neutral rotation to prevent any over constraining of the knee and to avoid “capturing” the joint in flexion deformity. Internal brace tensioning in this technique is done by pulling the 2 FiberTape blue strands exiting from TighTRope holes and tying them over the tibial TighTRope. Importantly, the FiberTape internal brace should be tensioned after the GraftLink construct is fully secured and tensioned to both femur and tibia. The knee should be checked after internal brace tensioning to ensure that full range of motion is present. The suspensory white sutures are then tied onto the top of the button (Fig 17).

Closure

The 2 arthroscopic portals are closed with No. 3-0 PROLENE sutures. The hamstring harvest incision is closed with multiple interrupted vertical mattress No. 3-0 PROLENE sutures.

Rehabilitation

Rehabilitation is the same as standard ACL rehabilitation using any other technique. Full weight-bearing and progressive range of motion exercises are encouraged. Early rehabilitation is focused on obtaining full extension and quadriceps activity. Closed-chain strengthening is emphasized. A gradual return to sports activities is allowed as rehabilitation progresses.

Discussion

Arthroscopic ACLR has become the standard care for the ACL-deficient knee. Numerous techniques have been described for ACLR trying to improve the knee stability, restore joint kinematics (normal anatomy and function), and prevent early joint degeneration in the ACL-deficient knee.¹¹

Multiple techniques for ACLR are currently available using different fixation methods; however, the most successful technique used to effectively resist rotatory loads with least anterior tibial translation is still a matter of debate.^{12,13} All-inside ACLR was first described by Morgan et al.¹⁴ in 1995; they eliminate the use of complete transtibial tunnel by using high anteromedial portal making a tibial socket and fixing the graft by interference screw from the same portal.

In 2006, Lubowitz¹⁵ described a technique that used a Dual RetroCutter (Arthrex), a cannulated arthroscopic drill capable of both antegrade and retrograde drilling. In 2011, Lubowitz et al.^{6,10} described a “second-generation” all-inside ACL reconstruction using the GraftLink technique. Retrograde drills independently create tibial and femoral sockets and the graft is fixed by cortical suspension button devices on both the tibia and femur. The development of second-generation cortical suspensory fixation devices was pivotal in the evolution of the all-inside ACL reconstruction to the current GraftLink technique.

The all-inside ACLR has many advantages, including improved cosmesis by eliminating the larger incision over the proximal medial tibia required for tunnel

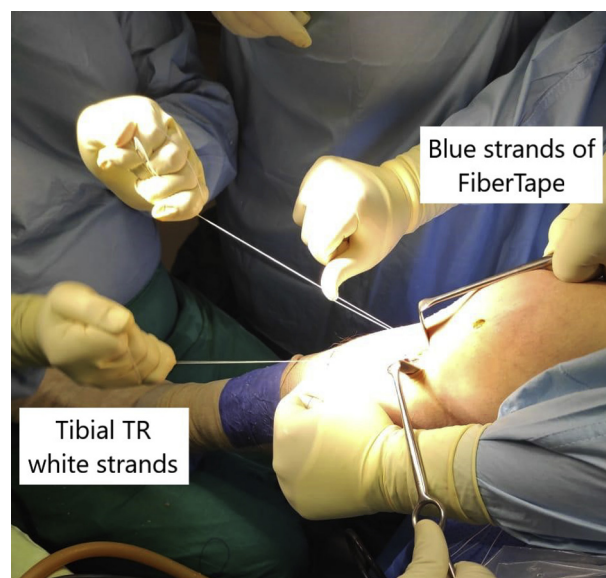


Fig 16. Tensioning the tibial TighTRope (TR; 2 white sutures) by the main surgeon with the knee in flexion. The assistant holds the 2 FiberTape sutures (blue sutures) with both hands.

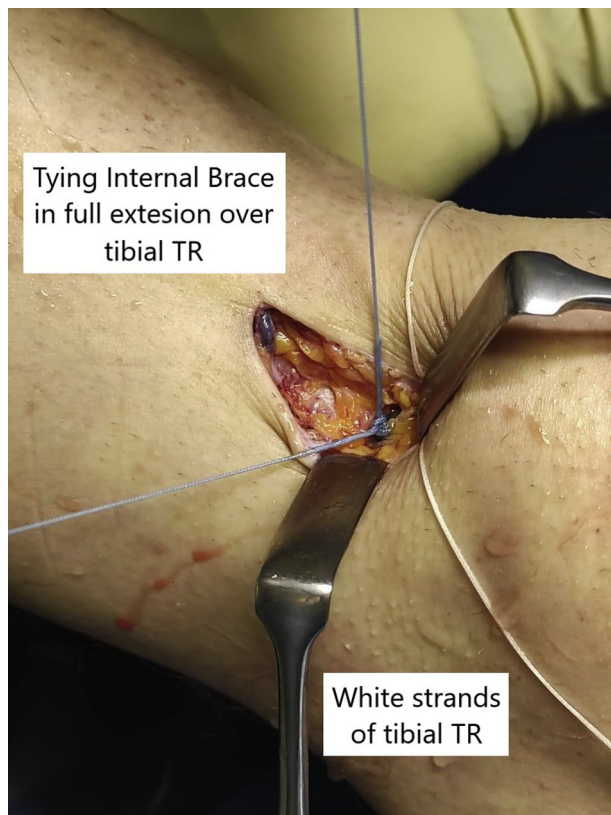


Fig 17. Tying the FiberTape sutures over the tibial TightRope (TR) in full extension.

drilling and tibial graft fixation. The use of sockets, rather than full bone tunnels, preserves the bone, which may be helpful if subsequent revision reconstruction is required or in the setting of multiple ligament reconstruction surgery. In addition, postoperative pain and swelling may be reduced since the extra-articular cortices and periosteum are not violated with this technique. The retrograde drill and the suspensory fixation on the femoral side eliminates the need for knee hyperflexion since the technique is performed with the knee flexed to 90°. In addition, femoral tunnels created using this outside-in technique have a longer interosseous distance than those created via an anteromedial portal technique which may be beneficial in small statured patients. The GraftLink technique using a single semitendinosus tendon is required for most cases; hence, the preservation of the gracilis tendon results in improved postoperative knee flexion strength and leaves this tendon available for subsequent or concurrent ligament reconstructions.^{2,9,10} However, all-inside ACL reconstruction is technically demanding regarding graft preparation using GraftLink technique, socket creation, graft fixation and tensioning.⁹

Internal bracing for ACL surgery is a relatively new concept. Mackay et al.¹⁶ first described the use of a

synthetic suture tape (FiberTape; Arthrex) as a reinforcing adjunct for primary ACL repair. Smith et al.¹⁷ further described internal bracing for pediatric ACL repair. Suture augmentation for all-inside adult ACLR has been reported by many authors.³⁻⁵

The ACL graft can be protected by using a 2-mm polyethylene tape (InternalBrace; Arthrex), bridging from tibia to femur, which protects the graft during early postoperative period with early accelerated rehabilitation program. The InternalBrace protects the graft and prevents attenuation during early phases of healing and remodeling. The FiberTape may act as a secondary stabilizer of the knee, thus preventing reinjury or graft elongation over time. It also may add to the thickness of small diameter grafts of <8 mm.^{13,16}

Bachmaier et al.⁸ found that independent suture tape reinforcement of soft-tissue grafts for ACLR leads to significantly reduced elongation and greater ultimate failure load without stress-shielding the soft-tissue graft. This may decrease the risk of graft tears, particularly in the case of small diameter soft-tissue grafts.

Lavender and Bishop¹⁸ described all inside ACLR augmented with suture tape and fertilized by bone marrow concentrate. However, they used an allograft and fixed the internal brace with 4.75-mm SwiveLock (Arthrex) into the anterior medial tibia at full extension of the knee.

Anderson et al.⁵ described all inside ACLR augmented with suture tape. They used bone patellar tendon autograft, which was fixed distally with an interference screw. The suture tape passed through the tibial screw and was then fixed using a small button over tibial cortex.

Daggett et al.⁴ described all inside ACLR with suture tape augmentation. They used a semitendinosus autograft, which was fixed distally to tibia using interference screw. A LabralTape (Arthrex) was used to augment the graft and was fixed with SwiveLock anchor in full extension and neutral rotation.

Benson et al.¹⁹ described ACLR with bone patellar tendon bone autograft augmented with suture tape. The tape was fixed independently using SwiveLock knotless anchor distal to tibial tunnel.

Smith and Bley³ performed an all-inside allograft ACLR augmented with an internal brace. The tape was fixed using a 4.75-mm absorbable Bio-Composite SwiveLock (Arthrex) anchor.

In this article, an all-inside ACLR was done and augmented with internal brace FiberTape in a crossed fashion; however, it was fixed distally with the same tibial TightRope. The fixation was done independently and the suspensory sutures of tibial TightRope were tensioned first in 15 to 20° of flexion. This was followed by tying the FiberTape sutures over the same button in full extension. Finally, the suspensory sutures are then

Table 1. Pearls and Pitfalls for All-Inside ACLR a With Button Tie-Over Technique

Step	Pearls	Pitfalls
GraftLink preparation	<p>The graft length must be less than the sum of the femoral socket length plus intra-articular graft distance plus the tibial socket length. This prevents slackness of the graft after fixation.</p> <p>Mark graft from both sides at 20 mm distance to ensure the adequate collagen in contact with the socket during the graft passage.</p>	Graft length more than 70 mm may lead to graft slackness after maximal tensioning of both buttons.
FiberTape augmentation	<p>Shuttling of the FiberTape through the femoral button can be assisted by a nitinol suture passer.</p> <p>Make sure that the FiberTape is completely wrapped and buried inside the graft to avoid intra-articular exposure and possible synovitis or irritation of the articular surface.</p>	<p>Ensure that the FiberTape has not inadvertently incorporated one of the suspension sutures of femoral TightRope.</p> <p>Shuttling the suture tape though the loop of TightRope and not through the button holes may lead to suture entanglement and the graft rupture during internal brace tensioning.</p>
ACL femoral socket	<p>An accessory AM portal should be used to help properly visualize the whole femoral footprint.</p> <p>Ream femoral socket at least 30 mm. The socket length must be more than the anticipated graft length inside the femoral socket to avoid slackness of the graft after its fixation.</p> <p>The socket diameter should be a snug fit to ensure the graft biological incorporation</p> <p>Make sure the tunnel measuring using FlipCutter is taken when the flip cutter is flush with the joint surface.</p> <p>A spade-tip drill with low-profile reamers can be used instead of the FlipCutter technique to avoid losing the femoral tunnel after removal of the FlipCutter.</p>	<p>Short socket length may lead to graft slackness after its fixation</p> <p>If the FlipCutter cannulated guide sleeve is not hammered and fixed properly, the hole may be lost and an incision may be needed to search for it.</p>
ACL tibial socket	<p>The C-guide position and angle are optimized to maximize tibial socket length so that the graft will not bottom out during tensioning. A distance of at least 37 mm will result in a 30-mm socket depth with a 7-mm cortical bone bridge.</p> <p>Ream at least a 30-mm tibial socket to avoid the slackness of the graft after its passage.</p> <p>Ensure that the FlipCutter is not in ream mode before its removal from the joint to avoid cortical blow out.</p> <p>Cortical preservation is required for the cortical suspensory fixation by the use of TightRope.</p>	<p>If the tibial socket is short, the graft may bottom out during its tensioning.</p> <p>Further advancement of the sleeve guide tip more than 7 mm cortical bridge may lead to cortical blow out and conversion of the socket into a tibial tunnel</p>
Suture shuttling	<p>The use of the PassPort cannula in the AM portal facilitates suture shuttling from femoral and tibial sockets by preventing soft-tissue interposition.</p> <p>For larger-diameter grafts more than 9.5 mm, the cannula should be removed before the graft passage.</p> <p>The use of 2 different colors of shuttling sutures may decrease shuttling problems.</p> <p>Retrieve the femoral and tibial graft-passing sutures from the AM arthroscopic portal at the same time to avoid suture tangling or soft-tissue interposition.</p> <p>Make sure that there are 6 suture ends exiting through the tibial tunnel orifice with no slackness to the FiberTape (2 strands of FiberTape, 2 suspensory sutures of TightRope, 2 traction sutures of TightRope)</p> <p>Use sliding, open-loop suture retriever to run the length of the femoral and tibial sutures independently from intra-articular to extra-articular through the cannula to ensure that there is no soft tissue bridge between both loops and that the loops are not inside each other.</p>	<p>Suture shuttling without cannula may lead to 2 common problems: soft-tissue bridges and cross looping.</p> <p>Soft tissue bridge between the 2 loops may lead to the failure of the technique and the premature TightRope tensioning.</p> <p>One loop may be retrieved through the other loop. this may lead to the suture entanglement at the anteromedial portal.</p>

(continued)

Table 1. Continued

Step	Pearls	Pitfalls
Graft passage into femoral tunnel	Avoid undersizing tunnel diameter. If the graft stuck at the orifices, the use tunnel dilators or curettes to enlarge the tunnel is recommended. Once the graft is seen at the tibial orifice intra-articularly, this indicates that the button has exited the femoral cortex proximally and is ready to flip. The flip-then-fill technique is a safe and easy technique to avoid far button flipping. Partially seat the femoral side of the graft and then pass the tibial side so that the graft depth in the sockets can be “fine-tuned” during tensioning. Maintain gentle tension on FiberTape sutures during the graft passage to prevent bundling at the tunnel orifice or within the ACL remnant stump.	The diameter of the graft should be the same as that of the socket to avoid graft stuck at the orifices after button is flipped. Too much and rapid pulling of the graft may lead to the button flipping over the iliotibial band. During tensioning of the femoral TightRope, the femoral socket may irreversibly engulf most of the graft. This may lead to empty tibial socket and failure of the technique. Usually only 1-1.5 cm of the graft is pulled inside femoral socket during the femoral TightRope tensioning.
Passing internal brace through tibial tightrope	Pass the internal brace FiberTape free ends through holes of the tibial TightRope before tensioning the graft.	The tibial TightRope tensioning before passing the internal brace sutures through it may lead to the need for an extra-fixation for the internal brace like SwiveLock anchor.
Graft passage into tibial tunnel	ACL tibial stump should be excised to prevent the graft dislodgement during the graft passage from inside	ACL tibial footprint preservation may lead to the graft dislodgement during all inside graft passage. The fibers of the tibial ACL stump may act as a barrier that prevents graft passing from inside.
GraftLink and internal brace tensioning	Care should be taken to avoid any soft tissue interposition between the tibial cortex and the TightRope An independent tensioning technique is advised. Final of the femoral and tibial TightRope tensioning should be in 15-20° of knee flexion. This is followed by the internal brace tensioning in full/hyper extension and neutral rotation to prevent any over-tensioning of the knee and to avoid “capturing” the joint in flexion deformity. The suspensory white sutures of tibial TightRope should be tied after internal brace tying to make sure that the internal brace is directly tied over button	A long graft will bottom out on the socket floor and is not accepted. Tensioning the internal brace in knee flexion may lead to knee flexion deformity. The knee should be checked after the internal brace tensioning to ensure that the full range of motion is present.

ACR, anterior cruciate ligament; AM, anteromedial.

tied over the button to secure fixation more (Tables 1 and 2).

Smith et al.²⁰ have raised the concern about the intra-articular biocompatibility of the multistranded, long-chain polyethylene suture tape during ACLR in canine. No animal developed lameness or clinical dysfunction, and there were no severe inflammatory or immune responses, cartilage erosions, or premature osteoarthritis noted. Arthroscopic assessments revealed no to mild synovitis and no apparent cartilage damage.

Suture tape augmentation for all inside ACLR promises the merits of both techniques. It is a “safety belt” reinforcement of the soft-tissue grafts that should theoretically improve the time zero biomechanical behavior of the ACL graft while supporting the graft until its mature incorporation and remodeling.²¹ However, the addition of a suture tape augmentation intra-articularly may expose the knee to allergic reactions and effusions. Moreover, the use of the suture tape augmentation carries the potential risk of overconstraining the knee if not fixed in full or even hyper extension. Several studies are needed to evaluate

the value of the suture augmentation to ACLR regarding its risk of reinjury in high-risk athletes and its potential complications.

Parkes et al.²² performed a retrospective comparative study to compare the results and complications of suture augmented ACLR versus isolated ACLR. They found that ACLR with hamstring autograft and independent suture tape reinforcement was performed safely with low rates of complications, graft failure, and reoperations with similar patient reported outcomes, function, and return-to-sport rates when compared with hamstring autograft ACLR without suture tape reinforcement at a minimum 2-year follow-up.

Bodendorfer et al.²³ performed a matched comparative analysis to compare suture augmented versus standard ACLR. They found that suture augmented hamstring ACLRs were associated with improved patient reported outcomes, less pain, and a greater percentage of and earlier return to preinjury activity level when compared with standard hamstring ACLRs without evidence of overconstraint.

Table 2. Advantages and Disadvantages of the All-Inside ACLR With the Button Tie-Over Technique (AI-BTO)

Advantages of (AI-BTO)	Disadvantages of AI-BTO
Only semitendinosus is used preserving gracilis for better knee proprioception during jumping with better knee postoperative flexion strength and leaves this tendon available for subsequent or concurrent ligament reconstructions in cases of multiligament injury where a paucity of grafts is common.	Difficulty in shuttling the FiberTape sutures alongside the TightRope sutures in the same holes
No need for an added method of fixation of the internal brace like SwiveLock anchor distally	Technically demanding regarding graft preparation using graft link technique, socket creation, graft fixation, and tensioning
Suture tape augmentation protects the graft and allows secured faster rehabilitation	All-inside with suture augmentation adds more cost compared with conventional ACLR methods
Improved cosmesis by eliminating the larger incision over the proximal medial tibia required for tunnel drilling, tibial graft fixation and SwiveLock fixation.	Addition of intra-articular FiberTape with hamstring graft may develop concern on postoperative effusions or allergic reactions
Use of sockets instead of tunnels is more bone preserving	Increased the graft preparation time and the total operative time
Postoperative pain and swelling may be reduced since the extra-articular cortices and periosteum are not violated with this technique	Theoretical risk for over constraining if internal brace over tensioned or tensioned with knee in flexion.
The retrograde drill and suspensory fixation on the femoral side eliminates the need for knee hyperflexion, since the technique is performed with the knee flexed to 90°	Concern about graft stress shielding
Femoral tunnels created using this outside-in technique have a longer interosseous distance than those created via an anteromedial portal technique which may be beneficial in small statured patients	No long-term comparison with clinical outcome data for suture tape augmentation with ACLR
Dual suspensory fixation of the hamstring tendon graft on both the tibia and femur assures the best biomechanical performance.	
More secure fixation especially in patients with high risk of retears like contact and professional athletes and in patients with a high body mass index, and in osteoporotic females.	
Use small ACL graft site incision with less donor-site morbidity	

ACL, anterior cruciate ligament; ACLR, anterior cruciate ligament reconstruction.

References

1. Takazawa Y, Ikeda H, Saita Y, et al. Return to play of rugby players after anterior cruciate ligament reconstruction using hamstring autograft: Return to sports and graft failure according to age. *Arthroscopy* 2017;33:181-189.
2. Lubowitz JH, Schwartzberg R, Smith P. Randomized controlled trial comparing all-inside anterior cruciate ligament reconstruction technique with anterior cruciate ligament reconstruction with a full tibial tunnel. *Arthroscopy* 2013;29:1195-1200.
3. Smith PA, Bley JA. Allograft anterior cruciate ligament reconstruction utilizing internal brace augmentation. *Arthrosc Tech* 2016;5:e1143-e1147.
4. Daggett M, Redler A, Witte K. Anterior cruciate ligament reconstruction with suture tape augmentation. *Arthrosc Tech* 2018;7:e385-e389.
5. Anderson SR, Youssefzadeh KA, Limpisvasti O. Anterior cruciate ligament reconstruction with suture tape augmentation: A surgical technique. *Arthrosc Tech* 2019;8:e1579-e1582.
6. Lubowitz JH, Ahmad CS, Anderson K. All-inside anterior cruciate ligament graft-link technique: Second-generation, no-incision anterior cruciate ligament reconstruction. *Arthroscopy* 2011;27:717-727.
7. Dabis J, Wilson A. Repair and augmentation with internal brace in the multiligament injured knee. *Clin Sports Med* 2019;38:275-283.
8. Bachmaier S, Smith PA, Bley J, Wijdicks CA. Independent suture tape reinforcement of small and standard diameter grafts for anterior cruciate ligament reconstruction: A biomechanical full construct model. *Arthroscopy* 2018;34:490-499.
9. Jones PE, Schuett DJ. All-inside anterior cruciate ligament reconstruction as a salvage for small or attenuated hamstring grafts. *Arthrosc Tech* 2018;7:e453-e457.
10. Lubowitz JH. All-inside anterior cruciate ligament graft link: Graft preparation technique. *Arthrosc Tech* 2012;1:e165-e168.
11. Wilson AJ, Yasen SK, Nancoo T, Stannard R, Smith JO, Logan JS. Anatomic all-inside anterior cruciate ligament reconstruction using the translateral technique. *Arthrosc Tech* 2013;2:e99-e104.
12. Smith PA, Schwartzberg RS, Lubowitz JH. No tunnel 2-socket technique: All-inside anterior cruciate ligament double-bundle retroconstruction. *Arthroscopy* 2008;24:1184-1189.
13. Smith PA, Bradley JP, Konicek J, Bley JA, Wijdicks CA. Independent suture tape internal brace reinforcement of bone-patellar tendon-bone allografts: Biomechanical assessment in a full-ACL reconstruction laboratory model. *J Knee Surg* 2020;33:1047-1054.

14. Morgan CD, Stein DA, Leitman EH, Kalman VR. Anatomic tibial graft fixation using a retrograde bio-interference screw for endoscopic anterior cruciate ligament reconstruction. *Arthroscopy* 2002;18:E38.
15. Lubowitz JH. No-tunnel anterior cruciate ligament reconstruction: The transtibial all-inside technique. *Arthroscopy* 2006;22:900.e1-11.
16. Mackay GM, Blyth MJ, Anthony I, Hopper GP, Ribbans WJ. A review of ligament augmentation with the InternalBrace™: The surgical principle is described for the lateral ankle ligament and ACL repair in particular, and a comprehensive review of other surgical applications and techniques is presented. *Surg Technol Int* 2015;26:239-255.
17. Smith JO, Yasen SK, Palmer HC, Lord BR, Britton EM, Wilson AJ. Paediatric ACL repair reinforced with temporary internal bracing. *Knee Surg Sports Traumatol Arthrosc* 2016;24:1845-1851.
18. Lavender C, Bishop C. The fertilized anterior cruciate ligament: An all-inside anterior cruciate ligament reconstruction augmented with amnion, bone marrow concentrate, and a suture tape. *Arthrosc Tech* 2019;8:e555-e559.
19. Benson DM, Hopper GP, Wilson WT, Mackay GM. Anterior cruciate ligament reconstruction using bone–patellar tendon–bone autograft with suture tape augmentation. *Arthrosc Tech* 2021;10:e249-e255.
20. Smith PA, Bozynski CC, Kuroki K, Henrich SM, Wijdicks CA, Cook JL. Intra-articular biocompatibility of multistranded, long-chain polyethylene suture tape in a canine ACL model. *J Knee Surg* 2019;32:525-531.
21. Bedi A. Editorial commentary: Buckle up surgeons: "safety belt" reinforcement of knee anterior cruciate ligament reconstruction grafts. *Arthroscopy* 2018;34:500-501.
22. Parkes CW, Leland DP, Levy BA, et al. Hamstring autograft anterior cruciate ligament reconstruction using an all-inside technique with and without independent suture tape reinforcement. *Arthroscopy* 2021;37:609-616.
23. Bodendorfer BM, Michaelson EM, Shu HT, et al. Suture augmented versus standard anterior cruciate ligament reconstruction: A matched comparative analysis. *Arthroscopy* 2019;35:2114-2122.