




Since January 2020 Elsevier has created a COVID-19 resource centre with free information in English and Mandarin on the novel coronavirus COVID-19. The COVID-19 resource centre is hosted on Elsevier Connect, the company's public news and information website.

Elsevier hereby grants permission to make all its COVID-19-related research that is available on the COVID-19 resource centre - including this research content - immediately available in PubMed Central and other publicly funded repositories, such as the WHO COVID database with rights for unrestricted research re-use and analyses in any form or by any means with acknowledgement of the original source. These permissions are granted for free by Elsevier for as long as the COVID-19 resource centre remains active.



Nervous system manifestations related to COVID-19 and their possible mechanisms

Zhen Xie^{a,b,1}, Hao Hui^{c,1}, Zhihan Zhao^{a,1}, Wenjin Yu^h, Rui Wu^d, Yanzhao Zhu^a, Yuan Song^a, Bingqing Cao^e, Wenzhen Shi^b, Di Zhao^d, Yunsong Zhao^d, Junchao Lv^d, Qian Yao^a, Yan Duan^a, Jingwen Li^f, Haijun Zhang^d, Linfu Zhou^a, Xiaotian Wang^g, Ye Tian^{b,*}, Gang Zhao^{a,*}

^a The College of Life Sciences and Medicine, Northwest University, No. 229 Taibai North Road, Xi'an, Shaanxi 710069, PR China

^b Medical Research Center; Xi'an Key Laboratory of Cardiovascular and Cerebrovascular Diseases, Xi'an No.3 Hospital, the Affiliated Hospital of Northwest University, No.10 Eastern section of the third FengCheng Rd., WeiYang District, Xi'an City, Shaanxi Province, P.R. China

^c Department of Spine Surgery, Honghui Hospital, The Affiliated Hospital of Xi'an Jiaotong University, No. 555 Youyi East Road, Xi'an, Shaanxi 710054, PR China

^d Department of Neurology, Xijing Hospital, Air Force Medical University, No. 15 Changle West Road, Xi'an, Shaanxi 710032, PR China

^e The No.2 Department of Neurology, Shaanxi Provincial People's Hospital, No.256 Youyi West Road, Xi'an, Shaanxi 710068, PR China

^f Department of Neurology, Xiang'an Hospital of Xiamen University, School of Medicine, Xiamen University, No. 2000 Xiang'an East Road, Xiamen, Fujian 361101, PR China

^g School of Information and Communication Engineering, Xi'an Jiaotong University, No.28 Xianning West Road, Xi'an 710049, PR China

^h Department of Neurology, Yan'an University Medical College No. 3 Affiliated Hospital, Xianyang, China

ARTICLE INFO

Keywords:

COVID-19
SARS-CoV-2
Neuroinvasion
CNS
PNS
Neurology
Neuropsychiatry

ABSTRACT

In December 2019, the novel coronavirus disease (COVID-19) due to severe acute respiratory syndrome coronavirus 2 (SARS-CoV-2) infection broke. With the gradual deepening understanding of SARS-CoV-2 and COVID-19, researchers and clinicians noticed that this disease is closely related to the nervous system and has complex effects on the central nervous system (CNS) and peripheral nervous system (PNS). In this review, we summarize the effects and mechanisms of SARS-CoV-2 on the nervous system, including the pathways of invasion, direct and indirect effects, and associated neuropsychiatric diseases, to deepen our knowledge and understanding of the relationship between COVID-19 and the nervous system.

1. Introduction

SARS-CoV-2 was first appeared in December 2019 (Huang et al., 2020a). It is an RNA virus, which belongs to the coronavirus family (Khailany et al., 2020). Viruses invade the body by binding to Angiotensin-converting enzyme 2 (ACE2) through Spike protein (S

protein), at the same time, there are other binding sites, too (Salamanna et al., 2020). In addition to respiratory and pulmonary infections, it has now been observed that nearly one-third of COVID-19 patients have neurological symptoms or only manifested as neurological symptoms (Taquet et al., 2021a; Mao et al., 2020). Among severely infected patients, this proportion is as high as 88 % (Mao et al., 2020), and all

List of Abbreviations: ACE2, Angiotensin-converting enzyme 2; AD, Alzheimer's disease; ADRD, Alzheimer's disease and related dementia; AIDP, acute inflammatory demyelinating polyneuropathy; AMAN, acute motor axonal neuropathy; AMSAN, acute motor sensory axonal neuropathy; ANE, acute necrotizing encephalopathy; AT1 receptor, Angiotensin Type 1 receptor; BBB, Blood-brain barrier; BLS, brain lymphatic systems; CDC, Centers for Disease Control and Prevention; CNS, Central Nervous System; COVID-19, novel coronavirus disease; CS, Cytokine storm; CSF, cerebrospinal fluid; CVT, Cerebral Venous Thrombosis; CK, creatine kinase; CVS, cerebral venous system; DAMP, damage-related molecular patterns; DMT, disease modification therapy; EMG/NCS, Electromyography/nerve conduction; GBS, Guillain-Barré syndrome; ICH, Intracranial hemorrhage; LMWH, low molecular weight heparin; MFS, miller fisher syndrome; MG, myasthenia gravis; MS, Multiple sclerosis; nACh, nicotine-type acetylcholine; NMOSD, neuromyelitis optica spectrum disorders; OB, Olfactory bulb; PNS, Peripheral nervous system; PRR, pattern recognition receptors; PTSD, post-traumatic stress disorder; RAS, renin-angiotensin system; S protein, Spike protein; SARS-CoV-2, severe acute respiratory syndrome coronavirus 2; SN, Substantia nigra; UFH, unfractionated heparin; VE, Vascular endothelium.

* Corresponding authors.

E-mail addresses: chhty@sina.com (Y. Tian), 8683219@qq.com (G. Zhao).

¹ These authors contributed equally to this study

² These authors contributed equally to this study

<https://doi.org/10.1016/j.brainresbull.2022.06.014>

Received 21 June 2021; Received in revised form 23 May 2022; Accepted 26 June 2022

Available online 28 June 2022

0361-9230/© 2022 The Authors. Published by Elsevier Inc. This is an open access article under the CC BY-NC-ND license (<http://creativecommons.org/licenses/by-nc-nd/4.0/>).

common types of neurological diseases were observed by researchers between them (Mao et al., 2020; Keyhanian et al., 2020). However, the specific mechanism that causes this phenomenon and its clinical manifestations still needs to be explored. In this review, we have collected and sorted out the literature on the relationship between COVID-19, SARS-CoV-2 and the nervous system, and summarized its mechanisms, as well as its clinical manifestations.

2. How does SARS-CoV-2 affect the nervous system?

How does SARS-CoV-2 affect the nervous system? There are two hypotheses: 1) Direct infection of the nervous system. 2) SARS-CoV-2 affects the nervous system through its systemic effects on the whole body.

2.1. SARS-CoV-2 directly infects the nervous system

2.1.1. The expression and distribution of virus-infected binding sites in the nervous system

Most studies have shown that the human ACE2 protein is limited to the endothelial and smooth muscle cells of cerebral blood vessels (Hamming et al., 2004). But, many studies have also confirmed that ACE2 and TMPRSS2 may be expressed at low levels in the brain (Rothan and Byrareddy, 2020; Butowt and Bilinska, 2020), and the cell types include glial cells, neurons (Wu et al., 2020; Guo et al., 2020), and epithelial cells from the veins (Jacob et al., 2020). ACE is expressed in the following brain regions: nucleus tractus solitarius, ventral region of the medulla oblongata, substantia nigra (SN), olfactory bulb (OB), ventricle, middle temporal gyrus, cingulate cortex, motor cortex, and other cerebral cortex areas (Flores, 2021; Wang et al., 2021; Faried et al., 2020). Therefore, the virus should theoretically be able to infect nerve cells and possibly spread throughout the brain.

2.1.2. Neuronal retrograde dissemination

Peripheral nerves may spread SARS-CoV-2 into the brain through the retro-neural route. Current theory believed that the possible pathway is afferent parts of the olfactory nerve, trigeminal nerve, glossopharyngeal nerve, vagus nerve, dorsal root ganglion, etc., allowing the virus to spread from the surrounding to the CNS (Burks et al., 2021). Some studies show that the complete SARS-CoV-2 virus particle and its RNA are found in the olfactory mucosa and the neuroanatomical area that receives the olfactory projection (Meinhardt et al., 2021). However, it is very difficult to detect the virus in the form of a single particle in the axon (Meinhardt et al., 2021).

2.1.3. Damage to the blood-brain barrier and endothelial system

An intact blood brain barrier (BBB) and endothelial system are essential lines of defense to protect the health of the brain. However, SARS-CoV-2 receptor ACE2 is widely distributed in intracranial blood vessels, this will facilitate the SARS-CoV-2 to invade the CNS by destroy the tight junctions between BBB endothelium, or penetrate BBB endothelial cells (Achar and Ghosh, 2020). Vascular endothelial dysfunction has been proposed as an essential complication of COVID-19 (Zhou et al., 2020).

(1) Inflammation and immune mechanism.

When SARS-CoV-2 invades cells, it can induce damage-related molecular patterns (DAMP), thereby interact with pattern recognition receptors (PRR) and produces cytokines (Azkur et al., 2020). At the same time, SARS-CoV-2 caused the activation of inflammasome complexes and the release of various inflammatory factors such as interferon and interleukin (Brenner, 2021; Hadjadj et al., 2020). If this process is out of control, it will cause cytokine storm (CS) and systemic inflammatory syndrome throughout the body. These can lead to an increase in the permeability of the blood vessel wall, and the severely damage in endothelium and BBB (Coperchini et al., 2020). Besides, anti-SARS-CoV-2 antibodies may cross-react with specific molecules of

brain microvascular endothelial cells and damage the BBB by activating the complement system (C3 and C4) (Skendros et al., 2020).

(2) Trojan horse mechanism.

Under physiological conditions, the number of immune cells that enter the CNS from the peripheral circulation is small and limited to specific innate and adaptive immune cell subgroups (Engelhardt and Ransohoff, 2012). However, during infection, SARS-CoV-2 can be swallowed and hide in host immune cells and sneak into the CNS with the help of the increased BBB permeability (Achar and Ghosh, 2020). Another possibility is that SARS-CoV-2 spreads via extracellular microvesicles sloughed off from infected cells (Ratajczak et al., 2006; Rozmyslowicz et al., 2003). But this remains to be confirmed.

(3) Brain lymphatic drainage system.

The third way for SARS-CoV-2 to enter the CNS may be through the brain lymphatic drainage system (Bostancıklıoğlu, 2020). There are endothelial cells in the lymphatic drainage system of the brain, and their histological structure is very similar to that of vascular endothelium (Aspelund et al., 2015). The presence of viral inclusion bodies in the epithelium can also be observed by electron microscopy (Varga et al., 2020). But there are also different opinions. Because the lymphatic drainage system of the brain is a unidirectional transport system from intracranial to extracranial (Aspelund et al., 2015), how does the virus enter the CNS in this unidirectional transport system? So further research is still needed.

2.1.4. Gastrointestinal route

The gastrointestinal tract is also an important possibility for the spread of SARS-CoV-2 to the nervous system, but this possibility may be underestimated (Uversky et al., 2021). There is a higher expression of ACE2 receptors in the epithelium of the gastrointestinal tract than in the lung. SARS-CoV-2 can directly infect intestinal cells and replicate efficiently in them (Uversky et al., 2021). Also, SARS-CoV-2 can directly invade the vagus nerve and retrograde into the CNS, or indirectly stimulate the enteric nervous system through immune pathways (Esposito et al., 2020).

2.2. Cytokine storm and immune system disorders

As described above, the CS formed during SARS-CoV-2 infection can affect the function of endothelium and BBB. In the brain parenchyma, glia are the most common cells involved in the inflammatory response (Vargas et al., 2020). In addition, the inflammatory response, accompanied by an overactivated complement system and a disturbed immune system, can also lead to CNS and PNS damage, as well as vascular disease (Uversky et al., 2021). This excessive inflammatory response is very similar to the state when sepsis occurs (Wilson et al., 2020). In addition, severe inflammation and endothelial dysfunction can also change the body's coagulation state, forming a hypercoagulable state to promote the formation of microthrombus (Varga et al., 2020). Hypercoagulability is one of the main causes of COVID-19-related vascular complications.

2.3. Hypoxia

COVID-19 patients often suffer from hypoxia, which is directly related to the patient's lung damage. Hypoxia can cause a variety of neurological complications (Solomon et al., 2020a). The reasons include, hypoxia causes inflammation of the endothelium and triggers cytokines release (Eltzschig and Carmeliet, 2011), thus aggravating the hypoxia and dysfunction of capillaries and endothelium (Noris et al., 2020), then forming a hypercoagulable state, promoting microthrombi, increasing vascular permeability, and increasing the risk of thrombosis and bleeding (Østergaard and CoV-2, 2021).

2.4. ACE2 and renin-angiotensin system

ACE2 is an important part of the renin-angiotensin system (RAS) (Abiodun and Ola, 2020). RAS is closely related to blood pressure regulation. After the S protein binds to ACE2, it down-regulates the ACE2 receptor and the Angiotensin Type 2 receptor (AT2 receptor) of angiotensin. At the same time, the Angiotensin Type 1 receptor (AT1 receptor) is over-activated, and the level of angiotensin II increases (Zou et al., 2020). Angiotensin II is a powerful angiotensin in capillary and arteriole vasoconstrictor, affecting blood pressure and cerebral blood flow regulation, and its increase may lead to cerebral hemorrhage and ischemic stroke (Wang et al., 2021). ACE2 expression on endothelial cells is higher in COVID-19 patients with dementia and hypertension, and these patients have generally poorer prognosis (Buzhdygan et al., 2020a). In addition, nicotine can increase the expression of ACE2 in nerve cells by stimulating nicotine-type acetylcholine (nACh) receptors. Therefore, smokers are at higher risk of developing neurological complications after infection with SARS-CoV-2 (Kabbani and Olds, 2020).

2.5. Coagulation abnormalities

Coagulation disorder is a typical feature and complication of SARS-CoV-2 infection (Zhou et al., 2020), which can cause a high incidence of thrombosis (Cui et al., 2020). SARS-CoV-2 infection can destroy the antithrombotic state of vascular endothelium through the above-mentioned CS, hypoxia, ACE2 and RAS system abnormalities (Connors and Levy, 2020). In addition, the virus itself also has a specific procoagulant effect (Connors and Levy, 2020). After virus infection, the body will form immune thrombus to assist the immune process (Henry et al., 2020). But if it is out of control, it will lead to disorders of the coagulation system and extensive microvascular thrombosis (Kitchens,

2009).

The coagulopathy of SARS-CoV-2 infection is characterized by a significant increase in D-dimer, high fibrinogen levels, prolonged prothrombin time, mild reduction of platelets or normal platelets, and other hypercoagulable states (Tang et al., 2020). Sometimes it also manifests as antiphospholipid antibody syndrome (lupus anticoagulant) (Levi et al., 2020). Fig. 1 and Fig. 2.

3. Nervous system diseases related to SARS-CoV-2

3.1. Cerebrovascular disease

3.1.1. Ischemic stroke

Studies have shown that the incidence of ischemic stroke in COVID-19 patients is 5%–6.92% (Taquet et al., 2021a; Mao et al., 2020). Most of them are men (62%), with a median age of 63 years (Tan et al., 2020). COVID-19 patients are more likely to suffer stroke and have worse symptoms and prognosis (Maury et al., 2021). COVID-19 with ischemic stroke is divided into two categories based on occurrence mechanism.

The first category is elderly patients who have a history of multiple cardiovascular and cerebrovascular risk factors or have potential comorbidities before infection. They are more likely to have vascular embolism events (Carod-Artal, 2020). When such patients develop SARS-CoV-2 infection, they tend to with severe and more types of complications (Avula et al., 2020). The second category tends to be relatively young patients who have almost no cardiovascular and cerebrovascular risk factors or related comorbidities before being infected with SARS-CoV-2. This may be related to the effects of SARS-CoV-2 on multiple systems throughout the body (Zhou et al., 2020; Oxley et al., 2020; Wang et al., 2020). Coagulation is a key factor of it, about a quarter of cases have evidence of systemic thrombosis (Morassi et al.,

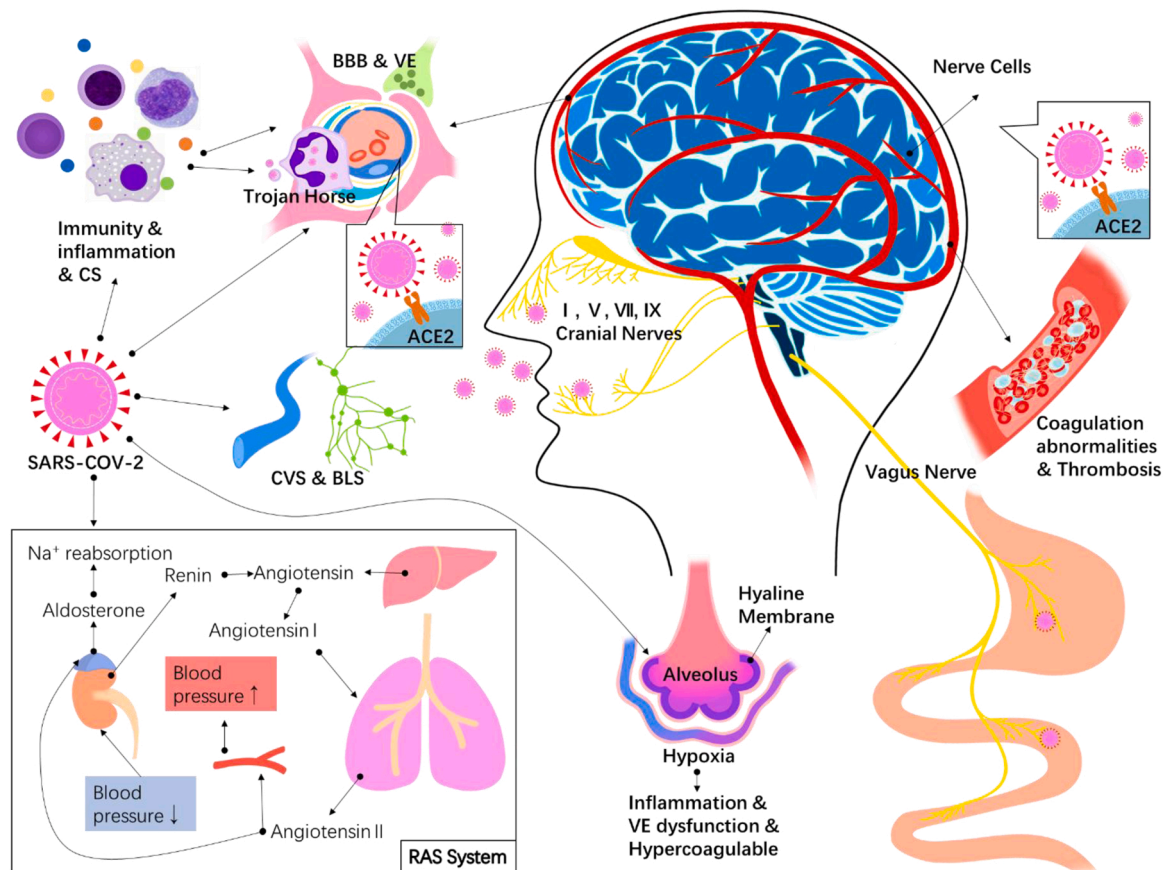


Fig. 1. The mechanism of SARS affecting the nervous system SARS-CoV-2 directly infects the nervous system: (1) Virus-infected binding sites in thenervous system, (2) Neuronal retrograde dissemination, (3) Damage to the BBB and endothelial system,(4) Gastrointestinal route.

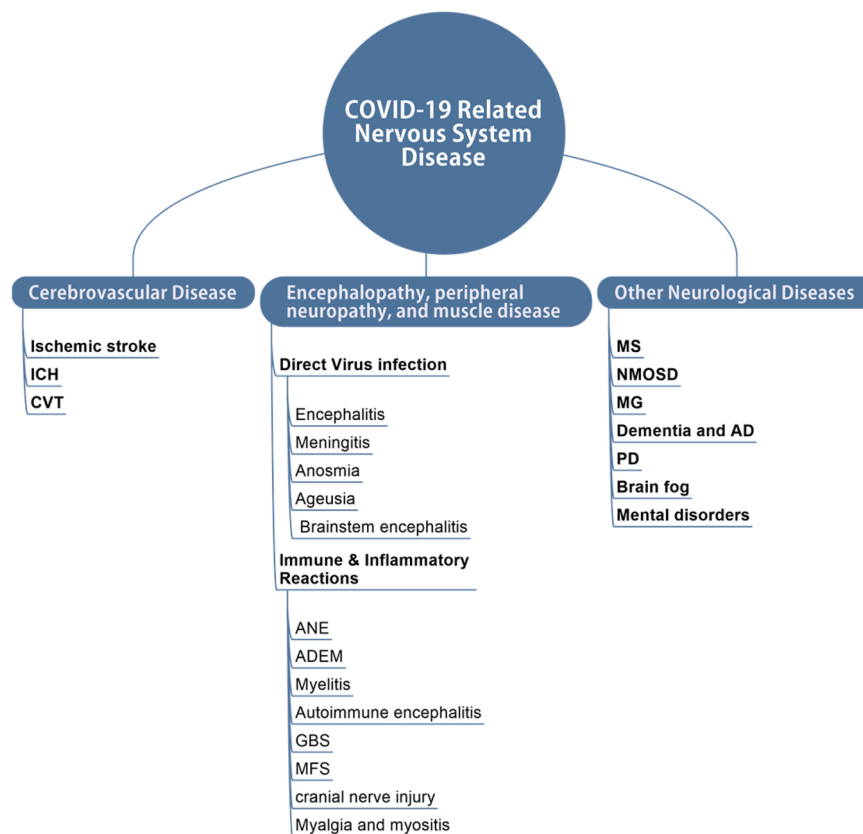


Fig. 2. COVID related disease.

2020). These younger (<50 years) stroke cases have some unique clinical features (Oxley et al., 2020; Vogrig et al., 2021): ① Previous risk factors and comorbidities seem to be few/non-existent; ② Strokes in younger patients were most likely to occur before the onset of COVID-19 symptoms; ③ Occlusion of large blood vessels seems to be very common.

COVID-19 patients complicated by cerebral infarction has the following tendency (Vogrig et al., 2021): ① Large vessel occlusion (Siegler et al., 2020; Escalard et al., 2020). ② Multivessel occlusion and multiregional stroke (26 % of cases), and the infarct core volume is also larger (Escalard et al., 2020). ③ Acute ischemic stroke in the vertebral base area is also common and can be observed in 35 % of patients (Hernández-Fernández et al., 2020). ④ Neurological deficits are usually severe (median of the NIHSS is 19–21) (Morassi et al., 2020). ⑤ The incidence of small vessel occlusion is relatively low, accounting for only 9 % of reported cases (Tan et al., 2020; Siegler et al., 2020). ⑥ More than 40 % of patients are diagnosed with cryptogenic stroke, but there is evidence of embolism in imaging (Vogrig et al., 2021). ⑦ It may be accompanied by multiple cerebral microhemorrhage (Varatharaj et al., 2020; Keller et al., 2020). ⑧ It may be accompanied by systemic thrombosis (Tan et al., 2020; Morassi et al., 2020).

Laboratory tests: CS and abnormal blood clotting is very common (Zhou et al., 2020). In addition, anti-phospholipid antibodies can be detected in a large number of cases (Connors and Levy, 2020; Tan et al., 2020). The incidence of liver and kidney insufficiency is also high, and lactate dehydrogenase (LDH) is often elevated (Morassi et al., 2020). Imaging: Floating thrombus in the ascending aorta, common carotid artery, and internal carotid artery can be observed in CTA of some patients (de Carranza et al., 2021; Viguier et al., 2020). MR vascular wall imaging of some patients showed contrast enhancement of large and medium-sized cerebral arteries (Vogrig et al., 2021; Dixon et al., 2020). In addition, multiple ischemic foci in the brain parenchyma can often be observed (Varatharaj et al., 2020; Keller et al., 2020; Beyrouiti et al., 2020). It is also often accompanied by multiple cerebral

microhemorrhage and subarachnoid hemorrhages (Keller et al., 2020). Autopsy results: Multiple cerebral microhemorrhage is an unmistakable feature (Keller et al., 2020; Jensen et al., 2021). In addition, intracranial lymphocytic endotheliitis can be observed in many severe cases (Varga et al., 2020). Acute hemorrhagic cerebral infarction and microthrombosis can be observed in a large number of autopsies (Meinhardt et al., 2021; Jensen et al., 2021). At the same time, in most autopsies, the SARS-CoV-2 virus test result is negative (Solomon et al., 2020b; Kremer et al., 2020a).

3.1.2. Intracranial hemorrhage

The estimated incidence of a intracranial hemorrhage (ICH) in COVID-19 patients is 2.66 % (Taquet et al., 2021a). In addition, a large part of bleeding-related problems is hemorrhagic stroke, with an incidence of 21.7 %–25.7 % (Hernández-Fernández et al., 2020; Jain et al., 2020). The average age of ICH in COVID-19 patients is 52.2 years, which is lower than the average expected age of ICH (Rodriguez et al., 2020). It is currently believed that cerebral hemorrhage is related to vascular endothelial damage and multiple cerebral microhemorrhages caused by various reasons.

Among them, hypertension is a common complication of COVID-19 (Zhou et al., 2020; Keller et al., 2020). Abnormalities in the ACE2 and RAS systems can lead to hypertension and disruption of the BBB (Buzhdygan et al., 2020b; Setiadi et al., 2018). However, the distribution range of cerebral microbleeds in most patients is different from that of typical hypertensive microbleeds (Keller et al., 2020). In COVID-19 patients, the microhemorrhage is more concentrated in the brain stem area (three-quarters of the cases) (Kirschenbaum et al., 2021), especially at the gray-white intersection of neocortex and brainstem. Besides, bleeding points are occasionally observed in the corpus callosum (Kirschenbaum et al., 2021). Another consideration for the cause of bleeding is that because many COVID-19 patients are at increased risk of thrombosis in pulmonary embolism and are in a hypercoagulable state,

they have received preventive anticoagulants and/or antiplatelet therapy, which may make them prone to intracranial hemorrhage (Kirschenbaum et al., 2021).

Brain microhemorrhage and vascular damage can cause a variety of intracranial hemorrhages (Hernández-Fernández et al., 2020): ① Mass hemorrhage involving extensive cerebral hemispheres (Jain et al., 2020; Giorgianni et al., 2020). ② Multiple hematomas and hemorrhages in the upper and lower tentorial (Morassi et al., 2020; Giorgianni et al., 2020; Gonçalves et al., 2020). ③ Spontaneous cerebral hemorrhage, especially in critically ill patients (Morassi et al., 2020; Gonçalves et al., 2020). ④ Hemorrhagic transformation of acute ischemic stroke (Al Saiegh et al., 2020). ⑤ Rupture of pseudoaneurysm (Brundin et al., 2020). ⑥ Hemorrhagic infarction related to cerebral venous sinus thrombosis (CVT) (Poillon et al., 2021). ⑦ Subarachnoid hemorrhage related to arterial dissection and aneurysm (Al Saiegh et al., 2020).

At present, the largest COVID-19 autopsy study pointed out that many patients have microthrombosis, acute hemorrhagic infarction, and multiple cerebral microhemorrhage (Bryce et al., 2020). Evidence of diffuse intravascular thrombosis can be observed (Kirschenbaum et al., 2021; Kremer et al., 2020b). In most autopsies, the reverse transcription-polymerase chain reaction of SARS-CoV-2 in the cerebrospinal fluid (CSF) was negative, but there were also positive cases (Solomon et al., 2020b; Menter et al., 2020).

3.1.3. Cerebral venous thrombosis

Compared with cerebral infarction and hemorrhage, the occurrence of cerebral venous thrombosis (CVT) is relatively rare (Siegler et al., 2020; Sharifian-Dorche et al., 2020), and the combined prevalence is 0.3 % (Favas et al., 2020). A study showed that among patients with severe COVID-19, 5–15 % of patients had venous and arterial thromboembolism complications (Speeckaert et al., 2020). CVT is part of the hypercoagulable state and systemic thrombosis caused by COVID-19. Patients without any risk factors for congenital CVT can develop hypercoagulability and thrombosis under the influence of COVID-19, resulting in CVT (Rigamonti et al., 2021; Chougar et al., 2020).

The clinical manifestations of CVT caused by COVID-19 are not significantly different from CVT caused by other coagulopathy. Based on the available evidence, low molecular weight heparin (LMWH) seems to be more effective than unfractionated heparin (UFH) and has a lower mortality rate. Therefore, LMWH is recommended as the first-line treatment (Kow et al., 2020; Thachil et al., 2020). But as mentioned above, this also brings about the problem of increased risk of bleeding. Currently, there are no reports of positive SARS-CoV-2 detection in CSF (Siegler et al., 2020; Sharifian-Dorche et al., 2020; Sweid et al., 2020).

3.2. Encephalopathy, peripheral neuropathy, and muscle disease

3.2.1. Nervous system damage caused by direct virus infection

(1) Encephalitis and meningitis.

Among COVID-19 patients who exhibit at least one neurological symptom, the prevalence of encephalitis is approximately 0–27.9 % (Pezzini and Padovani, 2020). Beijing Ditan Hospital reported a case for the first time CNS infection caused by SARS-CoV-2, This was confirmed by genetic testing of the CSF (Xiang et al., 2020). Later, many people proved this (Moriguchi et al., 2020; Huang et al., 2020b; Mardani et al., 2020). The symptoms, imaging, and CSF examination of this meningoencephalitis are similar to those of ordinary one.

But there are not as many reports about meningoencephalitis as we estimated. In these reports, brain damage caused by immune inflammatory response is more than that caused by direct SARS-CoV-2 invasion. This is because existing detection methods are not sufficient to prove that brain parenchymal damage is directly caused by SARS-CoV-2 (von Weyhern et al., 2020). In fact, several studies have shown that positive SARS-CoV-2 RNA results have been observed in cerebrospinal fluid specimens and autopsy by RT-PCR, but this does not mean that there must be a complete virus particle in it (von Weyhern et al., 2020).

This is due to the limitations of PCR technology (Uversky et al., 2021). Alternatively, a positive result may come from a virus directly penetrating the brain or from viral RNA in the blood (Solomon et al., 2020a). CSF's cytological and biochemical tests are similar to the characteristics of common viral encephalitis, manifested by mild protein and cell count abnormalities (Moriguchi et al., 2020; Huang et al., 2020b; Sun and Guan, 2020). It indicates that there may be other factors (such as peripheral infectious inflammation and neurotransmitter changes) that lead to meningoencephalitis (Wang et al., 2021). In addition, the neurological prognosis of most patients with encephalitis or encephalopathy is generally favorable (Wang et al., 2021).

Some autopsy results show lymphocytic panencephalitis and meningitis (von Weyhern et al., 2020), brain edema, and partial neuronal degeneration (Xu et al., 2020a). In addition, sparse or moderate aggregates composed of chronic inflammatory cells such as monocytes have been observed around the cerebral blood vessels (Serrano et al., 2021). Focal soft meningitis can also be seen (Solomon et al., 2020a). Common MR findings are contrast enhancement of the pia mater and abnormal cortical FLAIR signal (Helms et al., 2020). These abnormalities requires extensive differential diagnosis (Gulko et al., 2020). Some of these patients may also have limited cortical diffusion or cortical blooming artifacts (Kandemirli et al., 2020).

(2) Anosmia and ageusia.

Among COVID-19 patients, the incidence of anosmia and ageusia is very high. Anosmia is more than 85.6 %, while ageusia is 88.0 % (Lechien et al., 2020). Due to such a high incidence, and anosmia and ageusia may be the only signs and symptoms of infection (Lechien et al., 2020; Baig, 2020), the Centers for Disease Control and Prevention (CDC) has now added the sudden appearance of anosmia and ageusia to the typical symptoms of COVID-19. It is now generally believed that the possible main reason is that SARS-CoV-2 can infect local epithelial cells through ACE2 receptors in the tongue epithelium and olfactory epithelium, thereby destroying the receptors for smell and taste (Xu et al., 2020b; Klingenstein et al., 2021). Some researchers believe this is due to loss of olfactory sensory neurons from a variety of causes, including supportive cell dysfunction, inflammation-related apoptosis, or possible direct infection (Welge-Lüssen and Wolfensberger, 2006), but the mechanism is still not very clear. The duration of these symptoms in mild COVID-19 subjects was reported to be approximately 10 days, and 89 % of patients recovers 4 weeks after diagnosis (Boscolo-Rizzo et al., 2020). It can be seen on MRI that most of the anosmia patients have basically normal OB morphology (Galougahi et al., 2020; Politi et al., 2020).

(3) Brainstem encephalitis.

Although many experiments and animal models suggest that SARS CoV-2 may pass into the brainstem nucleus through the olfactory nerve, trigeminal nerve, glossopharyngeal nerve, facial nerve, vagus nerve, dorsal root ganglia, etc., but the evidence is not sufficient (Román et al., 2020). In the results of brain autopsy, only neuronal cell loss and axon degeneration were observed in the brain stem (von Weyhern et al., 2020). It is not ruled out that it is caused by systemic hyperinflammatory syndrome and autoimmune abnormalities (Jensen et al., 2021).

3.2.2. Nervous system damage caused by abnormal immune and inflammatory reactions

Excessive inflammation and immune abnormalities caused by infection are important causes of a variety of neurological diseases. It is no exception in COVID-19. Due to the low incidence of these diseases, there are no precise statistics for some types. In a study involving 2533 patients: 4 cases of Acute Necrotizing Encephalopathy (ANE), 13 cases of Acute disseminated encephalomyelitis (ADEM), 7 cases of acute transverse myelitis; 9 cases of limbic encephalitis, 31 cases of Guillain-Barré syndrome (GBS), 3 cases of Miller Fisher syndrome (MFS), 2 cases of multiple cranial neuritides, 2 cases of facial paralysis; 6 cases of isolated oculomotor neuropathy; 6 cases of critically ill myopathy (Maury et al., 2021). However, because these are mainly concentrated in case

reports, there is no systematic research and summary.

(1) ANE.

ANE is a rare disease characterized by brain damage (encephalopathy) that usually follows an acute febrile disease, mostly viral infections. ANE may be related to intracranial CS and BBB damage (Zubair et al., 2020; Rossi, 2008). The most typical imaging features are symmetrical multifocal lesions and involvement of the thalamus (Poyiadji et al., 2020). Other commonly involved areas include the brain stem, white matter, and cerebellum. The CT image showed a low signal. MR showed a high signal on T2 and FLAIR with internal bleeding. Post-contrast images may demonstrate a ring of contrast enhancement (Poyiadji et al., 2020). Autopsy revealed extensive vasculitis (endothelitis), with varying degrees of segmental and complete endothelial destruction; thrombosis is mainly in the microcirculation of the vascular bed; substantial hemorrhagic necrosis and inflammation (encephalitis) can be seen, as well as severe necrotizing neuronal damage; isolated brain edema may also be observed (Mao et al., 2020; Ermilov et al., 2021).

(2) ADEM.

ADEM is a rare kind of inflammation that affects the brain and spinal cord, usually in children. ADEM is also associated with immune abnormalities and inflammation after infection (Pusch et al., 2018; Pohl et al., 2016). No CSF virus test report was found in ADEM related to COVID-19 (Reichard et al., 2020). Existing imaging and autopsy results suggest that they are similar to other ADEMs (Najjar et al., 2020). The autopsy results showed that similar to vascular disease and demyelination changes (Reichard et al., 2020; Jaunmuktane et al., 2020).

(3) Myelitis.

Autoimmune response and CS after viral infection result in myelitis (Karakike and Giamarellos-Bourboulis, 2019), primarily manifested as acute transverse myelitis. There are not many related reports, some cases manifested as simple myelitis or brain involvement (AlKetbi et al., 2020). Similar to ordinary myelitis, MRI of the spinal cord is the most commonly used method of diagnosis (Sotoca and Rodríguez-Álvarez, 2020). Current cases indicate that CSF changes are similar to viral encephalitis and are normal or mildly abnormal (Sotoca and Rodríguez-Álvarez, 2020).

(4) Autoimmune encephalitis.

Autoimmune encephalitis refers to a group of conditions that occur when the body's immune system mistakenly attacks healthy brain cells, leading to inflammation of the brain. Autoimmune encephalitis is also rarely seen in COVID-19 (Paterson et al., 2020; Pilotto et al., 2021). The main manifestations are similar to ordinary autoimmune encephalitis (Bernard-Valnet et al., 2020; Dogan et al., 2020). The vast majority of existing cases show that the autoantibody group in serum and CSF has no abnormalities (Pizzanelli et al., 2021). However, some studies have detected autoimmune antibodies such as CASPR2 (Pizzanelli et al., 2021; Delamarre et al., 2020). The routine cytology and biochemical tests of CSF are negative or mildly abnormal, and the cell count or protein level is elevated. So far, the PCR test results of SARS-CoV-2 are all negative (Bernard-Valnet et al., 2020; Dogan et al., 2020; Pizzanelli et al., 2021). The brain MRI of some cases showed bilateral symmetrical limbic system hyperintensity in FLAIR, T2, and DWI sequences (Bernard-Valnet et al., 2020; Dogan et al., 2020; Pizzanelli et al., 2021). Electroencephalography shows universal slow waves (Bernard-Valnet et al., 2020; Dogan et al., 2020; Pizzanelli et al., 2021).

(5) GBS, MFS, and cranial nerve injury.

GBS is a rare, autoimmune disorder in which a person's own immune system damages the nerves, causing muscle weakness and sometimes paralysis. It has several subtypes, including acute inflammatory demyelinating polyneuropathy (AIDP), acute motor axonal neuropathy (AMAN), acute motor sensory axonal neuropathy (AMSAN), and MFS. In COVID-19 patients, most variants of GBS have been observed (Keyhanian et al., 2020; Rahimi, 2020; Padroni et al., 2020). Some studies show partial to complete recovery in 60 % of cases (Alberti et al., 2020). In addition to binding to ACE2, SARS-CoV-2 can also need sialic acid-containing glycoproteins and gangliosides to get into cell (Fantini

et al., 2020). These two sites are also closely related to the pathogenesis of GBS. Therefore, a cross-reactivity may occur, which is a potential mechanism for SARS-CoV-2 to trigger autoimmune GBS (Fantini et al., 2020).

The involved nerves show enhancement and high signal in MRI (Khalifa et al., 2020; Berciano and Gallardo, 2020). CSF is characterized by cell-albumin dissociation (Tiet and AlShaikh, 2020; Sancho-Saldaña et al., 2020), but the RT-PCR result of SARS-CoV-2 is negative (Keyhanian et al., 2020). The results of the electrophysiological examination are usually consistent with demyelinating polyneuropathy and axonal injury. Most appear to be demyelinating electrophysiological subtypes (Tatu et al., 2021; Caress et al., 2020).

In addition, COVID-19 lead to other cranial nerve injuries. For example, ① optic neuritis (Mao et al., 2020). ② Pure motor third cranial nerve palsy [273]. ③ Non-MFS multiracial nerve injuries (De Gennaro et al., 2021).

Common treatments include intravenous immune globulin (IVIG) or plasma exchange. Generally speaking, GBS and MFS show an excellent response to immunoglobulin therapy (Harapan and Yoo, 2021). In addition, some reported cases of GBS caused by SARS-CoV-2 have also received hydroxychloroquine treatment. A combination of chloroquine with sialic acid and GM1 ganglioside can prevent SARS-CoV-2 from entering cells through S protein (Keyhanian et al., 2020), which may be an interesting treatment direction.

(6) Myalgia and myositis.

Myalgia is a common symptom observed in COVID-19 patients. The prevalence is ranging from 3.36 % to 64 %, and the combined prevalence is estimated to be 19.3 % (Favas et al., 2020; Tsai et al., 2020). Severe patients (19.3 %) may be more prone to muscle damage than ordinary patients (4.8 %) (Mao et al., 2020). In rare cases, myalgia and muscle damage may progress to rhabdomyolysis (Jin and Tong, 2020). The underlying mechanism of myalgia may be the expression of ACE on skeletal muscle and CS (Cabello-Verrugio et al., 2015; Jiang et al., 2020).

Most patients showed increased creatine kinase (CK) (Sharifian-Dorche et al., 2020; Borah et al., 2021). There are case reports of CK up to > 11,000 U/L and rhabdomyolysis (Jin and Tong, 2020; Suwanwongse and Shabarek, 2020). Electromyography/nerve conduction (EMG/NCS) results indicate features of myopathy (Keyhanian et al., 2020). Therefore, COVID-19 patients with signs of skeletal muscle damage need to do further tests, such as muscle biopsy and antibody screening, because IVIG treatment may improve the functional outcome of these patients, and there are also cases of using hydroxychloroquine treatment (Keyhanian et al., 2020).

3.3. Other neurological diseases related to COVID-19

3.3.1. Multiple sclerosis and neuromyelitis optica spectrum disorders

New cases of Multiple sclerosis (MS) and neuromyelitis optica spectrum disorders (NMOSD) observed in COVID-19 patients are rare. In a recent report, only 2 cases were observed among nearly 11,000 patients (Yuksel et al., 2021). Almost all cases of NMOSD caused by COVID-19 are case reports (Batum and Kisabay, 2020). In MS and NMOSD, it is necessary to consider whether disease modification therapy (DMT) treatment for MS and NMOSD patients will increase their risk of COVID-19. According to existing research, whether MS or NMOSD patients receive DMT or not, no increased risk of COVID-19 infection has been observed (Fan et al., 2020; Zrzavy et al., 2020). For patients with NMOSD, the medication did not increase their chances of contracting COVID-19 or aggravate the signs of infection. Still, patients who interrupted their medicines due to the epidemic had an increased recurrence rate (Yin et al., 2021). However, the overall amount of data on NMOSD is relatively small, so many studies suggest that NMOSD treatment recommendations should be guided by MS (Fan et al., 2020).

3.3.2. Myasthenia gravis

Myasthenia gravis (MG) is a chronic autoimmune disorder in which antibodies destroy the communication between nerves and muscle, resulting in weakness of the skeletal muscles. In a survey of about 11,000 COVID-19 patients, 2 new MG patients were found (Yüksel et al., 2021). The mechanism may be related to the immune disorder and inflammation caused by infection (Galassi and Marchioni, 2021; Qin et al., 2020). Research on MG patients infected with COVID-19 showed that among 3558 MG patients, 34 patients (0.96 %) were infected with COVID-19 (Solé et al., 2021). After MG patients are infected with COVID-19, most of them are more serious. 87 % needed ICU treatment, 73 % required mechanical ventilation, and 30 % died (Camelo-Filho et al., 2020). In addition, after suffering from COVID-19, the initial symptoms of MG may be aggravated or cause MG crisis (Županić et al., 2021).

The treatment of MG is also a challenge (Galassi and Marchioni, 2021; Valencia-Sanchez and Wingerchuk, 2020). Current research shows that immunosuppressive drugs and corticosteroids frequently used in MG treatment are not risk factors for poor outcomes (Solé et al., 2021). At the same time, in the MG associated with SARS-CoV-2 infection, the assessment of respiratory muscle function is critical to determine the timing of tracheal intubation (Galassi and Marchioni, 2021).

3.3.3. Dementia and Alzheimer's disease

Current research shows that the incidence of dementia in COVID-19 patients is 0.67 % (Taquet et al., 2021a). Among people over 65 years old, the incidence of dementia diagnosed for the first time within 14–90 days after COVID-19 is 1.6 % (Taquet et al., 2021b). In an observational study conducted in France, more than one-third (15/45) of patients had cognitive impairment when discharged from the ICU (Helms et al., 2020).

There is a close relation between dementia and COVID-19. Some symptoms of Alzheimer's disease and related dementia (ADRD) may increase the risk of COVID-19 infection, including the inability to implement or comply with COVID-19 prevention guidelines and requirements due to comprehension, personality changes, and memory changes (Brown et al., 2020; Suzuki et al., 2020). Older people with chronic diseases such as dementia can develop the more powerful and often fatal form of COVID-19 (Miyashita et al., 2020). They have a higher probability of suffering from comorbidities and a higher mortality rate (Bianchetti et al., 2020; Bauer et al., 2014).

3.3.4. Parkinson's disease

COVID-19 may cause Parkinson's disease (PD) in healthy individuals, the prevalence is about 0.67 % (Taquet et al., 2021a). The mechanism involved may be related to hyposmia and anosmia (Rey et al., 2018). In addition, researchers speculated that there are ACE2 receptors in the SN (Brundin et al., 2020), but after 20 autopsies, no virus was found in the SN (Serrano et al., 2021).

In addition, research on PD patients with COVID-19 shows that 11.7 % of PD patients are admitted to the ICU or suffer from severe pneumonia (Kubota and Kuroda, 2021) and face a higher risk of death, with a mortality rate ranging from 19.7 % to 50 % (Amruta et al., 2021). One hypothesis to explain this is that dysphagia can cause aspiration pneumonia (Amruta et al., 2021). COVID-19 may also aggravate the neurological and motor symptoms of PD patients. Part of the reason is that COVID-19 can cause diarrhea, which reduces the absorption of oral medications (Amruta et al., 2021). But PD itself does not seem to increase the risk of SARS-CoV-2 infection (Ferini-Strambi and Salsone, 2021; Brundin et al., 2020).

3.3.5. Brain fog

Brain fog is a problem that has re-entered people's vision with the epidemic of COVID-19, and its incidence can be as high as 81 %. The main manifestations of brain fog are memory problems and difficulty concentrating (Graham et al., 2021). Brain fog first appeared in the 1980 s. In the 1990 s, it was believed to be related to chronic fatigue

syndrome caused by infections, and a set of diagnostic criteria was established (Sharpe et al., 1991). Symptoms are similar to those of cancer patients (chemofog or chemobrain) undergoing or after chemotherapy, as well as patients with muscular encephalomyelitis/chronic fatigue syndrome (ME/CFS) or mast cell activation syndrome (Sharpe et al., 1991). The pathogenesis of brain fog is currently unclear, but it may involve stimulating mast cells through pathogens and stress, activating microglia through neuroinflammation and causing inflammation of the hypothalamus (Theoharides et al., 2021). It is also believed that this is related to mitochondrial dysfunction caused by cerebral hypoxia (Stefano, 2021). At present, the diagnosis of brain fog is mainly exclusive diagnosis based on clinical symptoms (Marshall, 2020).

3.3.6. Mental disorders

Mental complications after COVID-19, especially depression, anxiety, and post-traumatic stress disorder are very common. The incidence of anxiety disorders is 17.39–34.7 % (Taquet et al., 2021a; Kong et al., 2020). Among patients with no previous history of mental illness, approximately 4.6 % will develop a new type of anxiety disorder within 90 days of infection (Taquet et al., 2021b). The incidence of depression is 28.5 % (Kong et al., 2020). The incidence of post-traumatic stress disorder (PTSD) is 96.2 % (Bo et al., 2020). In addition, 30 days after the patient was discharged from the hospital, the incidence of PTSD, depression, anxiety, obsessive-compulsive disorder, and insomnia were 28 %, 31 %, 42 %, 20 %, and 40 %, respectively (Mazza et al., 2020). Two to three months after the onset, COVID-19 patients are more likely to experience moderate to severe symptoms of anxiety and depression than the control group (Raman et al., 2021).

In addition to the changes in the social and medical environment caused by the SARS-CoV-2 pandemic, the high incidence of mental and psychological abnormalities in COVID-19 may be closely related to immune and inflammatory mechanisms, such as immune activation caused by microorganisms (Steardo et al., 2020). This is also the focus of research on the pathogenesis of mental illness in recent years. A large number of inflammatory factors are produced during SARS-CoV-2 infection, including IL-1 β , IL-6, TNF- α , et.al, they are closely related to depression and anxiety. In particular, the pro-inflammatory mediator IL-6 promotes the synthesis and secretion of other inflammatory factors and acute-phase proteins through astrocytes and microglia (Wohleb et al., 2016; Chen et al., 2020; Raony et al., 2020).

Similar neuropsychiatric manifestations have also been reported between the general public and medical workers (Amruta et al., 2021). Due to the worldwide pandemic of SARS-CoV-2, it has also caused a great psychological burden to medical staff. The incidence of anxiety and depression symptoms is high (12 %–67.5 %), and there are also a lot of insomnia and emotional trauma (Vizheh et al., 2020; Pappa et al., 2020). In addition, in the general population, due to lockdown and other reasons, the social isolation, uncertainty and low control of various risks have led to an increase in mood disorders, drug abuse, and suicidal tendencies (De Boni et al., 2020; Czeisler et al., 2020).

4. Conclusion

The neurological complications of COVID-19 cover almost all known neurological diseases, affecting more than one-third of COVID-19 patients, and can occur in various periods of infection. Therefore, the nervous system is closely related to COVID-19. We summarize the most recent research results on COVID-19 and neurological diseases, hoping to help people deepen their understanding of the pathogenic mechanism and clinical symptoms of COVID-19 and its associated neurological diseases.

Funding

This work was supported by grants from 1) Natural Science Basic Research Program of Shaanxi (Program No. 2022JM-539); 2) Natural

Science Basic Research Program of Shaanxi (Program No. 2022JM-541); 3) Hospital-level project of Xi'an Internatil Medical Center (Program No. 2020ZD007); 4) Natural Science Basic Research Program of Xi'an (Program No. 2020qn17); 5) Key Research and Development Program of Shaanxi (Program No. 2021SF-096); 6) Key Research and Development Program of Shaanxi (Program No. 2021SF-356).

Author's contribution

ZX, HH, ZHZ, WJY, RW, BQC, WZS, DZ, YSZ, JCL, QY, YD, JWL, and HJZ, performed literature searches and drafted the literature review. YZZ, YS, LFZ and XTW assisted in the revision of the article. GZ, YT revised and finalized the manuscript. ZX was the major contributor in writing the manuscript. All authors read and approved the final manuscript.

Conflicts of Interest

The authors declare no commercial or financial conflict of interests.

Acknowledgements

The authors thank all laboratory members for ongoing discussions and all the financial support of the above funds.

References

- Abiodun, O.A., Ola, M.S., 2020. Role of brain renin angiotensin system in neurodegeneration: an update. *Saudi J. Biol. Sci.* 27, 905–912.
- Achar, A., Ghosh, C., 2020. COVID-19-associated neurological disorders: the potential route of CNS invasion and blood-brain relevance. *Cells* 9.
- Al Saiegh, F., Ghosh, R., Leibold, A., Avery, M.B., Schmidt, R.F., Theofanis, T., Mouchtouris, N., Philipp, L., Peiper, S.C., Wang, Z.X., Rincon, F., Tjoumakaris, S.I., Jabbour, P., Rosenwasser, R.H., Gooch, M.R., 2020. Status of SARS-CoV-2 in cerebrospinal fluid of patients with COVID-19 and stroke. *J. Neurol., Neurosurg., Psychiatry* 91, 846–848.
- Alberti, P., Beretta, S., Piatti, M., Karantzoulis, A., Piatti, M.L., Santoro, P., Viganò, M., Giovannelli, G., Pirro, F., Montisano, D.A., Appollonio, L., Ferrarese, C., 2020. Guillain-Barré syndrome related to COVID-19 infection. *Neurol. R. Neuroimmunol. Neuroinflamm.* 7.
- AlKetbi, R., AlNuaimi, D., AlMulla, M., AlTalal, N., Samir, M., Kumar, N., AlBastaki, U., 2020. Acute myelitis as a neurological complication of Covid-19: A case report and MRI findings. *Radiol. Case Rep.* 15, 1591–1595.
- Amruta, N., Chastain, W.H., Paz, M., Solch, R.J., Murray-Brown, I.C., Befeler, J.B., Gressett, T.E., Longo, M.T., Engler-Chiurazzi, E.B., Bix, G., 2021. SARS-CoV-2 mediated neuroinflammation and the impact of COVID-19 in neurological disorders. *Cytokine Growth Factor Rev.* 58, 1–15.
- Aspelund, A., Antila, S., Proulx, S.T., Karlens, T.V., Karaman, S., Detmar, M., Wiig, H., Alitalo, K., 2015. A dural lymphatic vascular system that drains brain interstitial fluid and macromolecules. *J. Exp. Med.* 212, 991–999.
- Avula, A., Nalleballe, K., Narula, N., Sapozhnikov, S., Dandu, V., Toom, S., Glaser, A., Elsayegh, D., 2020. COVID-19 presenting as stroke. *Brain Behav. Immun.* 87, 115–119.
- Azkur, A.K., Akdis, M., Azkur, D., Sokolowska, M., van de Veen, W., Brügggen, M.-C., O'Mahony, L., Gao, Y., Nadeau, K., Akdis, C.A., 2020. Immune response to SARS-CoV-2 and mechanisms of immunopathological changes in COVID-19. *Allergy* 75, 1564–1581.
- Baig, A.M., 2020. Updates on what ACS reported: emerging evidences of COVID-19 with nervous system involvement. *ACS Chem. Neurosci.* 11, 1204–1205.
- Batum, M., Kisabay Ak, A., Mavioglu, H., 2020. Covid-19 infection-induced neuromyelitis optica: a case report. *Int. J. Neurosci.* 1–7.
- Bauer, K., Schwarzkopf, L., Graessel, E., Holle, R., 2014. A claims data-based comparison of comorbidity in individuals with and without dementia. *BMC Geriatr.* 14, 10.
- Berciano, J., Gallardo, E., 2020. Spinal nerve pathology in Guillain-Barré syndrome associated with COVID-19 infection. *Muscle Nerve* 62, E74–e75.
- Bernard-Valnet, R., Pizzarotti, B., Anichini, A., Demars, Y., Russo, E., Schmidhauser, M., Cerutti-Sola, J., Rossetti, A.O., Pasquier, R.D., 2020. Two patients with acute meningoencephalitis concomitant with SARS-CoV-2 infection. *Eur. J. Neurol.* 2020.2004.2017.20060251.
- Beyroufi, R., Adams, M.E., Benjamin, L., Cohen, H., Farmer, S.F., Goh, Y.Y., Humphries, F., Jäger, H.R., Losseff, N.A., Perry, R.J., Shah, S., Simister, R.J., Turner, D., Chandratheva, A., Werring, D.J., 2020. Characteristics of ischaemic stroke associated with COVID-19. *J. Neurol. Neurosurg. Psychiatry* 91, 889–891.
- Bianchetti, A., Rozzini, R., Guerini, F., Boffelli, S., Ranieri, P., Minelli, G., Bianchetti, L., Trabucchi, M., 2020. Clinical presentation of COVID19 in Dementia Patients. *J. Nutr. Health Aging* 24, 560–562.
- Bo, H.X., Li, W., Yang, Y., Wang, Y., Zhang, Q., Cheung, T., Wu, X., Xiang, Y.T., 2020. Posttraumatic stress symptoms and attitude toward crisis mental health services among clinically stable patients with COVID-19 in China. *Psychol. Med.* 1–2.
- Borah, P., Deb, P.K., Chandrasekaran, B., Goyal, M., Bansal, M., Hussain, S., Shinu, P., Venugopala, K.N., Al-Shar'i, N.A., Deka, S., Singh, V., 2021. Neurological Consequences of SARS-CoV-2 infection and concurrence of treatment-induced neuropsychiatric adverse events in COVID-19 patients: navigating the uncharted. *Front. Mol. Biosci.* 8, 627723–627723.
- Boscò-Rizzo, P., Borsetto, D., Fabbris, C., Spinato, G., Frezza, D., Menegaldo, A., Mularoni, F., Gaudio, P., Cazzador, D., Marciari, S., Frascioni, S., Ferraro, M., Berro, C., Varago, C., Nicolai, P., Tirelli, G., Da Mosto, M.C., Obholzer, R., Rigoli, R., Polese, J., Hopkins, C., 2020. Evolution of altered sense of smell or taste in patients with mildly symptomatic COVID-19. *JAMA Otolaryngol. Head. Neck Surg.* 146, 729–732.
- Bostancioglu, M., 2020. SARS-CoV2 entry and spread in the lymphatic drainage system of the brain. *Brain Behav. Immun.* 87, 122–123.
- Brenner, S.R., 2021. Erythropoietin-induced hemoglobin subunit beta may stimulate innate immune RNA virus pattern recognition, suppress reactive oxygen species, reduce ACE2 viral doorway opening, and neutrophil extracellular traps against COVID-19. *J. Med. Virol.* 93, 180–181.
- Brown, E.E., Kumar, S., Rajji, T.K., Pollock, B.G., Mulsant, B.H., 2020. Anticipating and mitigating the impact of the COVID-19 pandemic on Alzheimer's disease and related dementias. *Am. J. Geriatr. Psychiatry Off. J. Am. Assoc. Geriatr. Psychiatry* 28, 712–721.
- Brunin, P., Nath, A., Beckham, J.D., 2020. Is COVID-19 a perfect storm for Parkinson's disease? *Trends Neurosci.* 43, 931–933.
- Bryce, C., Grimes, Z., Pujadas, E., Ahuja, S., Beasley, M.B., Albrecht, R., Hernandez, T., Stock, A., Zhao, Z., Rasheed, M.A., Chen, J., Li, L., Wang, D., Corben, A., Haines, K., Westra, W., Umphlett, M., Gordon, R.E., Reidy, J., Petersen, B., Salem, F., Fiel, M., El Jamal, S.M., Tsankova, N.M., Houldsworth, J., Mussa, Z., Liu, W.-C., Veremis, B., Sordillo, E., Gitman, M.R., Nowak, M., Brody, R., Harpaz, N., Merad, M., Gnjatic, S., Donnelly, R., Seigler, P., Keys, C., Cameron, J., Moultrie, I., Washington, K.-L., Treatman, J., Sebra, R., Jhang, J., Firpo, A., Lednický, J., Paniz-Mondolfi, A., Cordon-Cardo, C., Fowkes, M., 2020. Pathophysiology of SARS-CoV-2: targeting of endothelial cells renders a complex disease with thrombotic microangiopathy and aberrant immune response. *Mt. Sinai COVID-19 Autops. Exp. medRxiv Prepr. Serv. Health Sci.* 2020.2005.2018.20099960.
- Burks, S.M., Rosas-Hernandez, H., Alenjandro Ramirez-Lee, M., Cuevas, E., Talpos, J.C., 2021. Can SARS-CoV-2 infect the central nervous system via the olfactory bulb or the blood-brain barrier? *Brain Behav. Immun.* S0889–1591 (0820), 32489–32482.
- Butowt, R., Bilinska, K., 2020. SARS-CoV-2: olfaction, brain infection, and the urgent need for clinical samples allowing earlier virus detection. *ACS Chem. Neurosci.* 11, 1200–1203.
- Buzhdygan, T.P., DeOre, B.J., Baldwin-Leclair, A., Bullock, T.A., McGary, H.M., Khan, J. A., Razmpour, R., Hale, J.F., Galie, P.A., Potula, R., Andrews, A.M., Ramirez, S.H., 2020a. The SARS-CoV-2 spike protein alters barrier function in 2D static and 3D microfluidic in-vitro models of the human blood-brain barrier. *Neurobiol. Dis.* 146, 105131–105131.
- Buzhdygan, T.P., DeOre, B.J., Baldwin-Leclair, A., Bullock, T.A., McGary, H.M., Khan, J. A., Razmpour, R., Hale, J.F., Galie, P.A., Potula, R., Andrews, A.M., Ramirez, S.H., 2020b. The SARS-CoV-2 spike protein alters barrier function in 2D static and 3D microfluidic in-vitro models of the human blood-brain barrier. *Neurobiol. Dis.* 146, 105131.
- Cabello-Verrugio, C., Morales, M.G., Rivera, J.C., Cabrera, D., Simon, F., 2015. Renin-angiotensin system: an old player with novel functions in skeletal muscle. *Med. Res. Rev.* 35, 437–463.
- Camelo-Filho, A.E., Silva, A.M.S., Estephan, E.P., Zambon, A.A., Mendonça, R.H., Souza, P.V.S., Pinto, W.B.V.R., Oliveira, A.S.B., Dangoni-Filho, I., Pouza, A.F.P., Valerio, B.C.O., Zanoteli, E., 2020. Myasthenia gravis and COVID-19: clinical characteristics and outcomes. *Front. Neurol.* 11, 1053–1053.
- Caress, J.B., Castoro, R.J., Simmons, Z., Scelsa, S.N., Lewis, R.A., Ahlawat, A., Narayanaswami, P., 2020. COVID-19-associated Guillain-Barré syndrome: the early pandemic experience. *Muscle Nerve* 62, 485–491.
- Carod-Artal, F.J., 2020. Neurological complications of coronavirus and COVID-19. *Rev. De Neurol.* 70, 311–322.
- de Carranza, M., Salazar, D.E., Troya, J., Alcázar, R., Peña, C., Aragón, E., Domínguez, M., Torres, J., Muñoz-Rivas, N., 2021. Aortic thrombus in patients with severe COVID-19: review of three cases. *J. Thromb. Thrombolysis* 51, 237–242.
- Chen, G., Wu, D., Guo, W., Cao, Y., Huang, D., Wang, H., Wang, T., Zhang, X., Chen, H., Yu, H., Zhang, X., Zhang, M., Wu, S., Song, J., Chen, T., Han, M., Li, S., Luo, X., Zhao, J., Ning, Q., 2020. Clinical and immunological features of severe and moderate coronavirus disease 2019. *J. Clin. Investig.* 130, 2620–2629.
- Chougar, L., Mathon, B., Weiss, N., Degos, V., Shor, N., 2020. Atypical deep cerebral vein thrombosis with hemorrhagic venous infarction in a patient positive for COVID-19. *Ajnr. Am. J. Neuroradiol.* 41, 1377–1379.
- Connors, J.M., Levy, J.H., 2020. COVID-19 and its implications for thrombosis and anticoagulation. *Blood* 135, 2033–2040.
- Coperchini, F., Chiovato, L., Croce, L., Magri, F., Rotondi, M., 2020. The cytokine storm in COVID-19: an overview of the involvement of the chemokine/chemokine-receptor system. *Cytokine Growth Factor Rev.* 53, 25–32.
- Cui, S., Chen, S., Li, X., Liu, S., Wang, F., 2020. Prevalence of venous thromboembolism in patients with severe novel coronavirus pneumonia. *J. Thromb. Haemost.: JTH* 18, 1421–1424.
- M. Czeisler, R.I. Lane, E. Petrosky, J.F. Wiley, A. Christensen, R. Njai, M.D. Weaver, R. Robbins, E.R. Facer-Childs, L.K. Barger, C.A. Czeisler, M.E. Howard, S.M.W. Rajaratnam, Mental Health, Substance Use, and Suicidal Ideation During the COVID-

- 19 Pandemic - United States, June 24–30, 2020, *MMWR. Morbidity and mortality weekly report*, 69, 2020, pp. 1049–1057.
- De Boni, R.B., Balanzá-Martínez, V., Mota, J.C., Cardoso, T.A., Ballester, P., Atienza-Carbonell, B., Bastos, F.L., Kapczynski, F., 2020. Depression, anxiety, and lifestyle among essential workers: a web survey from Brazil and Spain during the COVID-19 pandemic. *J. Med. Internet Res.* 22, e22835.
- De Gennaro, R., Gastaldo, E., Tamborino, C., Baraldo, M., Casula, N., Pedrali, M., Iovino, S., Michieletto, L., Violo, T., Ganzerla, B., Martinello, I., Quatrala, R., 2021. Selective cranial multinucleitis in severe COVID-19 pneumonia: two cases and literature review. *Neurol. Sci.* 42, 1643–1648.
- Delamarre, L., Gollion, C., Grouteau, G., Rousset, D., Jimena, G., Roustan, J., Gaussiat, F., Aldige, E., Gaffard, C., Duplantier, J., Martin, C., Fourcade, O., Bost, C., Fortenfant, F., Delobel, P., Martin-Blondel, G., Pauriente, J., Bonneville, F., Geeraerts, T., 2020. COVID-19-associated acute necrotising encephalopathy successfully treated with steroids and polyvalent immunoglobulin with unusual IgG targeting the cerebral fibre network. *J. Neurol., Neurosurg., Psychiatry* 91, 1004–1006.
- L. Dixon, C. Coughlan, K. Karunarathne, N. Gorgoraptis, J. Varley, J. Husselbee, D. Mallon, R. Carroll, B. Jones, C. Boynton, J. Pritchard, T. Youngstein, J. Mason, C. Gabriel, **Immunosuppression for intracranial vasculitis associated with SARS-CoV-2: therapeutic implications for COVID-19 cerebrovascular pathology, Journal of neurology, neurosurgery, and psychiatry**, 2020.
- Dogan, L., Kaya, D., Sarikaya, T., Zengin, R., Dincer, A., Akinci, I.O., Afsar, N., 2020. Plasmapheresis treatment in COVID-19-related autoimmune meningoencephalitis: case series. *Brain Behav. Immun.* 87, 155–158.
- Eltzschig, H.K., Carmeliet, P., 2011. Hypoxia and inflammation. *N. Engl. J. Med.* 364, 656–665.
- Engelhardt, B., Ransohoff, R.M., 2012. Capture, crawl, cross: the T cell code to breach the blood-brain barriers. *Trends Immunol.* 33, 579–589.
- Ermilov, V.V., Barkanov, V.B., Barkanova, O.N., Dorofeev, N.A., Filatov, V.E., 2021. [Clinical and anatomical features of SARS-CoV-2 with acute hemorrhagic necrotizing encephalopathy]. *Arkhiv Patol.* 83, 35–43.
- Escalard, S., Chalumeau, V., Escalard, C., Redjem, H., Delvoe, F., Hébert, S., Smajda, S., Ciccio, G., Desilles, J.P., Mazighi, M., Blanc, R., Maier, B., Piotin, M., 2020. Early Brain Imaging Shows Increased Severity of Acute Ischemic Strokes With Large Vessel Occlusion in COVID-19 Patients. *Stroke; a J. Cereb. Circ.* 51, 3366–3370.
- Esposito, G., Pesce, M., Seguela, L., Sanseverino, W., Lu, J., Sarnelli, G., 2020. Can the enteric nervous system be an alternative entrance door in SARS-CoV2 neuroinvasion? *Brain, Behav., Immun.* 87, 93–94.
- Fan, M., Qiu, W., Bu, B., Xu, Y., Yang, H., Huang, D., Lau, A.Y., Guo, J., Zhang, M.-N., Zhang, X., Yang, C.-S., Chen, J., Zheng, P., Liu, Q., Zhang, C., Shi, F.-D., 2020. Risk of COVID-19 infection in MS and neuromyelitis optica spectrum disorders. *Neurol. (R.) Neuroimmunol. Neuroinflamm.* 7, e787.
- Fantini, J., Di Scala, C., Chahinian, H., Yahi, N., 2020. Structural and molecular modelling studies reveal a new mechanism of action of chloroquine and hydroxychloroquine against SARS-CoV-2 infection. *Int. J. Antimicrob. Agents* 55, 105960.
- Fariéd, A., Dian, S., Halim, D., Hermanto, Y., Pratama, D.M.A., Arifin, M.Z., 2020. The neurological significance of COVID-19: Lesson learn from the pandemic. *Inter. Neurosurg.* 22, 100809–100809.
- Favas, T.T., Dev, P., Chaurasia, R.N., Chakravarty, K., Mishra, R., Joshi, D., Mishra, V.N., Kumar, A., Singh, V.K., Pandey, M., Pathak, A., 2020. Neurological manifestations of COVID-19: a systematic review and meta-analysis of proportions. *Neurol. Sci.: Off. J. Ital. Neurol. Soc. Ital. Soc. Clin. Neurophysiol.* 41, 3437–3470.
- Ferini-Strambi, L., Salsone, M., 2021. COVID-19 and neurological disorders: are neurodegenerative or neuroimmunological diseases more vulnerable? *J. Neurol.* 268, 409–419.
- Flores, G., 2021. SARS-CoV-2 (COVID-19) has neurotropic and neuroinvasive properties. *Int. J. Clin. Pract.* 75, e13708.
- Galassi, G., Marchioni, A., 2021. Myasthenia gravis at the crossroad of COVID-19: focus on immunological and respiratory interplay. *Acta Neurol. Belg.* 1–10.
- Galougahi, M.K., Ghorbani, J., Bakshshayeshkaram, M., Naeini, A.S., Haseli, S., 2020. Olfactory Bulb Magnetic Resonance Imaging in SARS-CoV-2-Induced Anosmia: The First Report. *Acad. Radiol.* 27, 892–893.
- Giorgianni, A., Vinacci, G., Agosti, E., Mercuri, A., Baruzzi, F., 2020. Neuroradiological features in COVID-19 patients: First evidence in a complex scenario. *J. Neuroradiol.* = *J. De. Neuroradiol.* 47, 474–476.
- Gonçalves, B., Righy, C., Kurtz, P., 2020. Thrombotic and Hemorrhagic Neurological Complications in Critically Ill COVID-19 Patients. *Neurocritical care* 33, 587–590.
- Graham, E.L., Clark, J.R., Orban, Z.S., Lim, P.H., Szymanski, A.L., Taylor, C., DiBiase, R. M., Jia, D.T., Balabanov, R., Ho, S.U., Batra, A., Liotta, E.M., Koralnik, I.J., 2021. Persistent neurologic symptoms and cognitive dysfunction in non-hospitalized Covid-19 “long haulers”. *Ann. Clin. Transl. Neurol.*
- Guiko, E., Oleksk, M.L., Gomes, W., Ali, S., Mehta, H., Overby, P., Al-Mufti, F., Rozenstein, A., 2020. MRI Brain Findings in 126 Patients with COVID-19: Initial Observations from a Descriptive Literature Review. *Am. J. Neuroradiol.* 41, 2199–2203.
- Guo, Y.-R., Cao, Q.-D., Hong, Z.-S., Tan, Y.-Y., Chen, S.-D., Jin, H.-J., Tan, K.-S., Wang, D.-Y., Yan, Y., 2020. The origin, transmission and clinical therapies on coronavirus disease 2019 (COVID-19) outbreak - an update on the status. *Mil. Med Res* 7, 11–11.
- Hadjadji, J., Yatim, N., Barnabei, L., Corneau, A., Boussier, J., Smith, N., Péré, H., Charbit, B., Bondet, V., Chenavier-Gobeaux, C., Breillat, P., Carlier, N., Gaudiz, R., Mordieu, C., Pène, F., Marin, N., Roche, N., Szeibel, T.-A., Merklung, S.H., Treluyer, J.-M., Veyer, D., Mouthon, L., Blanc, C., Tharaux, P.-L., Rozenberg, F., Fischer, A., Duffy, D., Rieux-Laucat, F., Kernéis, S., Terrier, B., 2020. Impaired type I interferon activity and inflammatory responses in severe COVID-19 patients. *Sci. (N. Y., N. Y.)* 369, 718–724.
- Hamming, I., Timens, W., Bulthuis, M.L.C., Lely, A.T., Navis, G.J., van Goor, H., 2004. Tissue distribution of ACE2 protein, the functional receptor for SARS coronavirus. A first step in understanding SARS pathogenesis. *The. J. Pathol.* 203, 631–637.
- Harapan, B.N., Yoo, H.J., 2021. Neurological symptoms, manifestations, and complications associated with severe acute respiratory syndrome coronavirus 2 (SARS-CoV-2) and coronavirus disease 19 (COVID-19). *J. Neurol.* 1–13.
- Helms, J., Kremer, S., Merdji, H., Clere-Jehl, R., Schenck, M., Kummerlen, C., Collange, O., Boulay, C., Fafi-Kremer, S., Ohana, M., Anheim, M., Meziani, F., 2020. Neurologic Features in Severe SARS-CoV-2 Infection. *The. N. Engl. J. Med.* 382, 2268–2270.
- Henry, B.M., Vikse, J., Benoit, S., Favaloro, E.J., Lippi, G., 2020. Hyperinflammation and derangement of renin-angiotensin-aldosterone system in COVID-19: A novel hypothesis for clinically suspected hypercoagulopathy and microvascular immunothrombosis. *Clin. Chim. Acta; Int. J. Clin. Chem.* 507, 167–173.
- Hernández-Fernández, F., Sandoval Valencia, H., Barbella-Aponte, R.A., Collado-Jiménez, R., Ayo-Martín, Ó., Barrena, C., Molina-Nuevo, J.D., García-García, J., Lozano-Setién, E., Alcahut-Rodríguez, C., Martínez-Martín, A., Sánchez-López, A., Segura, T., 2020. Cerebrovascular disease in patients with COVID-19: neuroimaging, histological and clinical description. *Brain: a J. Neurol.* 143, 3089–3103.
- Huang, C., Wang, Y., Li, X., Ren, L., Zhao, J., Hu, Y., Zhang, L., Fan, G., Xu, J., Gu, X., Cheng, Z., Yu, T., Xia, J., Wei, Y., Wu, W., Xie, X., Yin, W., Li, H., Liu, M., Xiao, Y., Gao, H., Guo, L., Xie, J., Wang, G., Jiang, R., Gao, Z., Jin, Q., Wang, J., Cao, B., 2020a. Clinical features of patients infected with 2019 novel coronavirus in Wuhan, China. *Lancet* 395, 497–506.
- Huang, Y.H., Jiang, D., Huang, J.T., 2020b. SARS-CoV-2 Detected in Cerebrospinal Fluid by PCR in a Case of COVID-19 Encephalitis. *Brain, Behav., Immun.* 87, 149.
- Jacob, F., Pather, S.R., Huang, W.-K., Zhang, F., Wong, S.Z.H., Zhou, H., Cubitt, B., Fan, W., Chen, C.Z., Xu, M., Pradhan, M., Zhang, D.Y., Zheng, W., Bang, A.G., Song, H., Carlos de la Torre, J., Ming, G.-L., 2020. Human Pluripotent Stem Cell-Derived Neural Cells and Brain Organoids Reveal SARS-CoV-2 Neurotropism Predominates in Choroid Plexus Epithelium. *Cell Stem Cell* 27, 937-950.e939.
- Jain, R., Young, M., Dogra, S., Kennedy, H., Nguyen, V., Jones, S., Bilaloglu, S., Hochman, K., Raz, E., Galetta, S., Horwitz, L., 2020. COVID-19 related neuroimaging findings: A signal of thromboembolic complications and a strong prognostic marker of poor patient outcome. *J. Neurol. Sci.* 414, 116923.
- Jaunmuktane, Z., Mahadeva, U., Green, A., Sekhawat, V., Barrett, N.A., Childs, L., Shankar-Hari, M., Thom, M., Jäger, H.R., Brandner, S., 2020. Microvascular injury and hypoxic damage: emerging neuropathological signatures in COVID-19. *Acta Neuropathol.* 140, 397–400.
- Jensen, M.P., Le Quesne, J., Officer-Jones, L., Teodósio, A., Thaventhiran, J., Ficken, C., Goddard, M., Smith, C., Menon, D., Allinson, K.S.J., 2021. Neuropathological findings in two patients with fatal COVID-19. *Neuropathol. Appl. Neurobiol.* 47, 17–25.
- Jiang, X., Coffee, M., Bari, A., Wang, J., Jiang, X., Huang, J., Shi, J., Dai, J., Cai, J., Zhang, T., Wu, Z., He, G., Huang, Y., 2020. Towards an Artificial Intelligence Framework for Data-Driven Prediction of Coronavirus Clinical Severity. *Comput., Mater. \ Contin.* 63, 537–551.
- Jin, M., Tong, Q., 2020. Rhabdomyolysis as Potential Late Complication Associated with COVID-19. *Emerg. Infect. Dis.* 26, 1618–1620.
- Kabbani, N., Olds, J.L., 2020. Does COVID19 Infect the Brain? If So, Smokers Might Be at a Higher Risk. *Mol. Pharmacol.* 97, 351–353.
- Kandemirli, S.G., Dogan, L., Sarikaya, Z.T., Kara, S., Akinci, C., Kaya, D., Kaya, Y., Yildirim, D., Tuzuner, F., Yildirim, M.S., Ozluk, E., Gucyetmez, B., Karaarslan, E., Koyuloglu, I., Demirel Kaya, H.S., Mammadov, O., Kisa Ozdemir, I., Afsar, N., Citci Yalcinkaya, B., Rasimoglu, S., Guduk, D.E., Kadir Juma, A., Ilksoz, A., Ersoz, V., Yonca Eren, M., Celtik, N., Arslan, S., Korkmaz, B., Dincer, S.S., Gulek, E., Dikmen, I., Yazici, M., Unsal, S., Ljama, T., Demirel, I., Ayıldiz, A., Kesimci, I., Bolsay Deveci, S., Tutuncu, M., Kizilkilic, O., Telci, L., Zengin, R., Dincer, A., Akinci, I.O., Kocer, N., 2020. Brain MRI Findings in Patients in the Intensive Care Unit with COVID-19 Infection. *Radiology* 297, E232–E235.
- Karakike, E., Giamarellos-Bourboulis, E.J., 2019. Macrophage Activation-Like Syndrome: A Distinct Entity Leading to Early Death in Sepsis. *Front. Immunol.* 10, 55.
- Keller, E., Brandi, G., Winkhofer, S., Imbach, L.L., Kirschenbaum, D., Frontzek, K., Steiger, P., Dietler, S., Haerberlin, M., Willms, J., Porta, F., Waeckerlin, A., Huber, M., Abela, I.A., Lutterotti, A., Stippich, C., Globas, C., Varga, Z., Jelcic, I., 2020. Large and Small Cerebral Vessel Involvement in Severe COVID-19: Detailed Clinical Workup of a Case Series. *Stroke; a J. Cereb. Circ.* 51, 3719–3722.
- Keyhanian, K., Umeton, R.P., Mohit, B., Davoudi, V., Hajjighasemi, F., Ghasemi, M., 2020. SARS-CoV-2 and nervous system: From pathogenesis to clinical manifestation. *J. Neuroimmunol.* 350, 577436.
- Khailany, R.A., Safdar, M., Ozaslan, M., 2020. Genomic characterization of a novel SARS-CoV-2. *Gene Rep.* 19, 100682-100682.
- Khalifa, M., Zakaria, F., Ragab, Y., Saad, A., Bamaga, A., Emad, Y., Rasker, J.J., 2020. Guillain-Barré Syndrome Associated With Severe Acute Respiratory Syndrome Coronavirus 2 Detection and Coronavirus Disease 2019 in a Child. *J. Pediatr. Infect. Dis. Soc.* 9, 510–513.
- Kirschenbaum, D., Imbach, L.L., Rushing, E.J., Frauenknecht, K.B.M., Gascho, D., Ineichen, B.V., Keller, E., Kohler, S., Lichtblau, M., Reimann, R.R., Schreiber, K., Ulrich, S., Steiger, P., Aguzzi, A., Frontzek, K., 2021. Intracerebral endothelitis and microbleeds are neuropathological features of COVID-19. *Neuropathol. Appl. Neurobiol.* 47, 454–459.
- Kitchens, C.S., 2009. Thrombocytopenia and thrombosis in disseminated intravascular coagulation (DIC). *Hematol. Am. Soc. Hematol. Educ. Program* 240–246.

- Klingenstein, M., Klingenstein, S., Neckel, P.H., Mack, A.F., Wagner, A.P., Kleger, A., Liebau, S., Milazzo, A., 2021. Evidence of SARS-CoV-2 Entry Protein ACE2 in the Human Nose and Olfactory Bulb. *Cells, Tissues, Organs* 1–10.
- Kong, X., Zheng, K., Tang, M., Kong, F., Zhou, J., Diao, L., Wu, S., Jiao, P., Su, T., Dong, Y., 2020. Preval. Factors Assoc. *Depress Anxiety Hosp. Patients COVID-19*, medRxiv: Prepr. *Serv. Health Sci.* 2020.2003.2024.20043075.
- Kow, C.S., Zaihan, A.F., Hasan, S.S., 2020. Anticoagulant approach in COVID-19 patients with cerebral venous thrombosis. *J. Stroke Cerebrovasc. Dis.: Off. J. Natl. Stroke Assoc.* 29, 105222.
- Kremer, S., Lersy, F., de Sèze, J., Ferré, J.C., Maamar, A., Carsin-Nicol, B., Collange, O., Bonneville, F., Adam, G., Martin-Blondel, G., Rafiq, M., Geeraerts, T., Delamarre, L., Grand, S., Krainik, A., Caillard, S., Constans, J.M., Metanbou, S., Heintz, A., Helms, J., Schenck, M., Lefèvre, N., Boutet, C., Fabre, X., Forestier, G., de Beaupaire, I., Bornet, G., Lacalm, A., Oesterlé, H., Bolognini, F., Messié, J., Hmeydia, G., Benzakoun, J., Oppenheim, C., Bapst, B., Megdiche, I., Henry Feugas, M.C., Khalil, A., Gaudemer, A., Jager, L., Nesser, P., Talla Mba, Y., Hemmert, C., Feuerstein, P., Sebag, N., Carré, S., Alleg, M., Lecocq, C., Schmitt, E., Anxionnat, R., Zhu, F., Comby, P.O., Ricolfi, F., Thouant, P., Desal, H., Boulouis, G., Berge, J., Kazémi, A., Pyatigorskaya, N., Lecler, A., Saleme, S., Edjlali-Goujon, M., Kerleroux, B., Zorn, P.E., Mathieu, M., Baloglu, S., Ardellier, F.D., Willaume, T., Brisset, J.C., Boulay, C., Mutschler, V., Hansmann, Y., Mertes, P.M., Schneider, F., Fafi-Kremer, S., Ohana, M., Meziani, F., David, J.S., Meyer, N., Anheim, M., Cotton, F., 2020a. Brain MRI Findings in Severe COVID-19: A Retrospective Observational Study. *Radiology* 297, E242–e251.
- Kremer, S., Lersy, F., Anheim, M., Merdji, H., Schenck, M., Oesterlé, H., Bolognini, F., Messié, J., Khalil, A., Gaudemer, A., Carré, S., Alleg, M., Lecocq, C., Schmitt, E., Anxionnat, R., Zhu, F., Jager, L., Nesser, P., Mba, Y.T., Hmeydia, G., Benzakoun, J., Oppenheim, C., Ferré, J.C., Maamar, A., Carsin-Nicol, B., Comby, P.O., Ricolfi, F., Thouant, P., Boutet, C., Fabre, X., Forestier, G., de Beaupaire, I., Bornet, G., Desal, H., Boulouis, G., Berge, J., Kazémi, A., Pyatigorskaya, N., Lecler, A., Saleme, S., Edjlali-Goujon, M., Kerleroux, B., Constans, J.M., Zorn, P.E., Mathieu, M., Baloglu, S., Ardellier, F.D., Willaume, T., Brisset, J.C., Caillard, S., Collange, O., Mertes, P.M., Schneider, F., Fafi-Kremer, S., Ohana, M., Meziani, F., Meyer, N., Helms, J., Cotton, F., 2020b. Neurologic and neuroimaging findings in patients with COVID-19: A retrospective multicenter study. *Neurology* 95, e1868–e1882.
- Kubota, T., Kuroda, N., 2021. Exacerbation of neurological symptoms and COVID-19 severity in patients with preexisting neurological disorders and COVID-19: A systematic review. *Clin. Neurol. Neurosurg.* 200, 106349.
- Lechien, J.R., Chiesa-Estomba, C.M., De Siat, D.R., Horoi, M., Le Bon, S.D., Rodriguez, A., Dequanter, D., Blecic, S., El Afia, F., Distinguin, L., Chekkoury-Idrissi, Y., Hans, S., Delgado, I.L., Calvo-Henriquez, C., Lavigne, P., Falanga, C., Barillari, M.R., Cammaroto, G., Khalife, M., Leich, P., Souchay, C., Rossi, C., Journe, F., Hsieh, J., Edjlali, M., Carlier, R., Ris, L., Lovato, A., De Filippis, C., Coppee, F., Fakhry, N., Ayad, T., Saussez, S., 2020. Olfactory and gustatory dysfunctions as a clinical presentation of mild-to-moderate forms of the coronavirus disease (COVID-19): a multicenter European study. *Eur. Arch. Oto-Rhino-Laryngol.: Off. J. Eur. Fed. Oto-Rhino-Laryngol. Soc. (EUFOS): Affil. Ger. Soc. Oto-Rhino-Laryngol. - Head. Neck Surg.* 277, 2251–2261.
- Levi, M., Thachil, J., Iba, T., Levy, J.H., 2020. Coagulation abnormalities and thrombosis in patients with COVID-19. *Lancet Haematol.* 7, e438–e440.
- Mao, L., Jin, H., Wang, M., Hu, Y., Chen, S., He, Q., Chang, J., Hong, C., Zhou, Y., Wang, D., Miao, X., Li, Y., Hu, B., 2020. Neurologic Manifestations of Hospitalized Patients With Coronavirus Disease 2019 in Wuhan, China. *JAMA Neurol.* 77, 683–690.
- Mardani, M., Nadji, S.A., Sarhangipor, K.A., Sharifi-Razavi, A., Baziboroun, M., 2020. COVID-19 infection recurrence presenting with meningoencephalitis. *N. Microbes N. Infect.* 37, 100732.
- Marshall, M., 2020. The lasting misery of coronavirus long-haulers. *Nature* 585, 339–341.
- Maury, A., Lyoubi, A., Peiffer-Smadja, N., de Broucker, T., Meppiel, E., 2021. Neurological manifestations associated with SARS-CoV-2 and other coronaviruses: A narrative review for clinicians. *Rev. Neurol.* 177, 51–64.
- Mazza, M.G., De Lorenzo, R., Conte, C., Poletti, S., Vai, B., Bollettini, I., Melloni, E.M.T., Furlan, R., Ciceri, F., Rovere-Querini, P., Benedetti, F., 2020. Anxiety and depression in COVID-19 survivors: Role of inflammatory and clinical predictors. *Brain, Behav., Immun.* 89, 594–600.
- Meinhardt, J., Radke, J., Dittmayer, C., Franz, J., Thomas, C., Mothes, R., Laue, M., Schneider, J., Brünink, S., Greuel, S., Lehmann, M., Hassan, O., Aschman, T., Schumann, E., Chua, R.L., Conrad, C., Eils, R., Stenzel, W., Windgassen, M., Rößler, L., Goebel, H.-H., Gelderblom, H.R., Martin, H., Nitsche, A., Schulz-Schaeffer, W.J., Hakroush, S., Winkler, M.S., Tampe, B., Scheibe, F., Kortvélyessy, P., Reinhold, D., Siegmund, B., Kühn, A.A., Elezkuraj, S., Horst, D., Oesterhelweg, L., Tsokos, M., Ingold-Heppner, B., Stadelmann, C., Drosten, C., Corman, V.M., Radbruch, H., Heppner, F.L., 2021. Olfactory transmucoasal SARS-CoV-2 invasion as a port of central nervous system entry in individuals with COVID-19. *Nat. Neurosci.* 24, 168–175.
- Menter, T., Haslbauer, J.D., Nienhold, R., Savic, S., Hopfer, H., Deigendesch, N., Frank, S., Turek, D., Willi, N., Pargger, H., Bassetti, S., Leuppi, J.D., Cathomas, G., Tolnay, M., Mertz, K.D., Tzankov, A., 2020. Postmortem examination of COVID-19 patients reveals diffuse alveolar damage with severe capillary congestion and variegated findings in lungs and other organs suggesting vascular dysfunction. *Histopathology* 77, 198–209.
- Miyashita, S., Yamada, T., Mikami, T., Miyashita, H., Chopra, N., Rizk, D., 2020. Impact of dementia on clinical outcomes in elderly patients with coronavirus 2019 (COVID-19): an experience in New York. *Geriatr. Gerontol. Int.* 20, 732–734.
- Morassi, M., Bagatto, D., Cobelli, M., D'Agostini, S., Gigli, G.L., Bnà, C., Vogrig, A., 2020. Stroke in patients with SARS-CoV-2 infection: case series. *J. Neurol.* 267, 2185–2192.
- Moriguchi, T., Harii, N., Goto, J., Harada, D., Sugawara, H., Takamino, J., Ueno, M., Sakata, H., Kondo, K., Myose, N., Nakao, A., Takeda, M., Haro, H., Inoue, O., Suzuki-Inoue, K., Kubokawa, K., Ogihara, S., Sasaki, T., Kinouchi, H., Kojin, H., Ito, M., Onishi, H., Shimizu, T., Sasaki, Y., Enomoto, N., Ishihara, H., Furuya, S., Yamamoto, T., Shimada, S., 2020. A first case of meningitis/encephalitis associated with SARS-Coronavirus-2. *Int. J. Infect. Dis.: IJID: Off. Publ. Int. Soc. Infect. Dis.* 94, 55–58.
- Najjar, S., Najjar, A., Chong, D.J., Pramanik, B.K., Kirsch, C., Kuzniecky, R.I., Pacia, S.V., Azhar, S., 2020. Central nervous system complications associated with SARS-CoV-2 infection: integrative concepts of pathophysiology and case reports. *J. Neuroinflamm.* 17, 231.
- Noris, M., Benigni, A., Remuzzi, G., 2020. The case of complement activation in COVID-19 multiorgan impact. *Kidney Int.* 98, 314–322.
- Østergaard, L., CoV-2, S.A.R.S., 2021. related microvascular damage and symptoms during and after COVID-19: Consequences of capillary transit-time changes, tissue hypoxia and inflammation. *Physiol. Rep.* 9, e14726.
- Oxley, T.J., Mocco, J., Majidi, S., Kellner, C.P., Shoirah, H., Singh, L.P., De Leacy, R.A., Shigematsu, T., Ladner, T.R., Yaeger, K.A., Skliut, M., Weinberger, J., Dangayach, N. S., Bederson, J.B., Tuhim, S., Fifi, J.T., 2020. Large-Vessel Stroke as a Presenting Feature of Covid-19 in the Young. *The N. Engl. J. Med.* 382, e60.
- Padroni, M., Mastrangelo, V., Asioli, G.M., Pavolucci, L., Abu-Rumeileh, S., Piscaglia, M. G., Querzani, P., Callegari, C., Foschi, M., 2020. Guillain-Barré syndrome following COVID-19: new infection, old complication? *J. Neurol.* 267, 1877–1879.
- Pappa, S., Ntella, V., Giannakas, T., Giannakoulis, V.G., Papoutsis, E., Katsaounou, P., 2020. Prevalence of depression, anxiety, and insomnia among healthcare workers during the COVID-19 pandemic: A systematic review and meta-analysis. *Brain, Behav., Immun.* 88, 901–907.
- Paterson, R.W., Brown, R.L., Benjamin, L., Nortley, R., Wiethoff, S., Bharucha, T., Jayaseelan, D.L., Kumar, G., Raftopoulos, R.E., Zambrenan, L., Vivekanandam, V., Khoo, A., Galdes, R., Chinthapalli, K., Boyd, E., Tuzlali, H., Price, G., Christofi, G., Morrow, J., McNamara, P., McLoughlin, B., Lim, S.T., Mehta, P.R., Levee, V., Keddie, S., Yong, W., Trip, S.A., Foulkes, A.J.M., Hotton, G., Miller, T.D., Everitt, A. D., Carswell, C., Davies, N.W.S., Yoong, M., Attwell, D., Sreedharan, J., Silber, E., Schott, J.M., Chandratheva, A., Perry, R.J., Simister, R., Checkley, A., Longley, N., Farmer, S.F., Carletti, F., Houlihan, C., Thom, M., Lunn, M.P., Spillane, J., Howard, R., Vincent, A., Werring, D.J., Hoskote, C., Jäger, H.R., Manji, H., Zandi, M. S., 2020. The emerging spectrum of COVID-19 neurology: clinical, radiological and laboratory findings. *Brain: a J. Neurol.* 143, 3104–3120.
- Pezzini, A., Padovani, A., 2020. Lifting the mask on neurological manifestations of COVID-19. *Nat. Rev. Neurol.* 16, 636–644.
- Pilotto, A., Masciocchi, S., Volonghi, I., Crabbio, M., Magni, E., De Giuli, V., Caprioli, F., Rifino, N., Sessa, M., Gennuso, M., Cotelli, M.S., Turla, M., Balducci, U., Mariotto, S., Ferrari, S., Ciccone, A., Fiacco, F., Imarisio, A., Risi, B., Benussi, A., Premi, E., Focà, E., Caccuri, F., Leonardi, M., Gasparotti, R., Castelli, F., Zanusso, G., Pezzini, A., Padovani, A., 2021. Clinical Presentation and Outcomes of Severe Acute Respiratory Syndrome Coronavirus 2-Related Encephalitis: The ENCOVID Multicenter Study. *The J. Infect. Dis.* 223, 28–37.
- Pizzanelli, C., Milano, C., Canovetti, S., Tagliaferri, E., Turco, F., Verdenelli, S., Nesti, L., Franchi, M., Bonanni, E., Menichetti, F., Volterrani, D., Cosottini, M., Siciliano, G., 2021. Autoimmune limbic Enceph. *Relat. SARS-CoV-2 Infect.: Case-Rep. Rev. Lit., Brain, Behav., Immun. - Health* 12, 100210–100210.
- Pohl, D., Alper, G., Van Haren, K., Kornberg, A.J., Lucchinetti, C.F., Tenenbaum, S., Belman, A.L., 2016. Acute disseminated encephalomyelitis: Updates on an inflammatory CNS syndrome. *Neurology* 87, S38–S45.
- Poillon, G., Obadia, M., Perrin, M., Savatovsky, J., Lecler, A., 2021. Cerebral venous thrombosis associated with COVID-19. *Infect.: Causal Or. coincidence?* *J. Neuroradiol. = J. De. Neuroradiol.* 48, 121–124.
- Politi, L.S., Salsano, E., Grimaldi, M., 2020. Magnetic Resonance Imaging Alteration of the Brain in a Patient With Coronavirus Disease 2019 (COVID-19) and Anosmia. *JAMA Neurol.* 77, 1028–1029.
- Poyiadji, N., Shahin, G., Noujaim, D., Stone, M., Patel, S., Griffith, B., 2020. COVID-19-associated Acute Hemorrhagic Necrotizing Encephalopathy: Imaging Features. *Radiology* 296, E119–e120.
- Pusch, E., Renz, H., Skevaki, C., 2018. Respiratory virus-induced heterologous immunity: Part of the problem or part of the solution? *Allergo Journal: interdisziplinäre Zeitschrift für Allergologie und Umweltmedizin. Organ der Dtsch. Ges. für Allerg. - und Immun.* 27, 28–45.
- Qin, C., Zhou, L., Hu, Z., Zhang, S., Yang, S., Tao, Y., Xie, C., Ma, K., Shang, K., Wang, W., Tian, D.S., 2020. Dysregulation of Immune Response in Patients With Coronavirus 2019 (COVID-19) in Wuhan, China. *Clin. Infect. Dis.: Off. Publ. Infect. Dis. Soc. Am.* 71, 762–768.
- Rahimi, K., 2020. Guillain-Barre syndrome during COVID-19 pandemic: an overview of the reports. *Neurol. Sci.: Off. J. Ital. Neurol. Soc. Ital. Soc. Clin. Neurophysiol.* 41, 3149–3156.
- Raman, B., Cassar, M.P., Tunnicliffe, E.M., Filippini, N., Griffanti, L., Alfaro-Almagro, F., Okell, T., Sheerin, F., Xie, C., Mahmood, M., Mózes, F.E., Lewandowski, A.J., Ohuma, E.O., Holdsworth, D., Lamlum, H., Woodman, M.J., Krasopoulos, C., Mills, R., McConnell, F.A.K., Wang, C., Arthofer, C., Lange, F.J., Andersson, J., Jenkinson, M., Antoniades, C., Channon, K.M., Shanmuganathan, M., Ferreira, V.M., Piechnik, S.K., Klennerman, P., Brightling, C., Talbot, N.P., Petousi, N., Rahman, N. M., Ho, L.P., Saunders, K., Geddes, J.R., Harrison, P.J., Pattinson, K., Rowland, M.J., Angus, B.J., Gleeson, F., Pavlides, M., Koychev, I., Miller, K.L., Mackay, C., Jezzard, P., Smith, S.M., Neubauer, S., 2021. Medium-term effects of SARS-CoV-2

- infection on multiple vital organs, exercise capacity. *Cogn., Qual. life Ment. Health, Post-Hosp. Disch., EClinicalMedicine* 31, 100683.
- Raony, I., de Figueiredo, C.S., Pandolfo, P., Giestal-de-Araujo, E., Oliveira-Silva Bomfim, P., Savino, W., 2020. Psycho-Neuroendocrine-Immune Interactions in COVID-19: Potential Impacts on Mental Health. *Front. Immunol.* 11, 1170.
- Ratajczak, J., Wyszczynski, M., Hayek, F., Janowska-Wieczorek, A., Ratajczak, M.Z., 2006. Membrane-derived microvesicles: important and underappreciated mediators of cell-to-cell communication. *Leukemia* 20, 1487–1495.
- Reichard, R.R., Kashani, K.B., Boire, N.A., Constantopoulos, E., Guo, Y., Lucchinetti, C.F., 2020. Neuropathology of COVID-19: a spectrum of vascular and acute disseminated encephalomyelitis (ADEM)-like pathology. *Acta Neuropathol.* 140, 1–6.
- Rey, N.L., Wesson, D.W., Brundin, P., 2018. The olfactory bulb as the entry site for prion-like propagation in neurodegenerative diseases. *Neurobiol. Dis.* 109, 226–248.
- Rigamonti, A., Mantero, V., Piamarta, F., Spena, G., Salmaggi, A., 2021. Cerebral venous thrombosis associated with coronavirus infection: an underestimated entity? *Neurol. Sci.: Off. J. Ital. Neurol. Soc. Ital. Clin. Neurophysiol.* 42, 317–318.
- Rodriguez, M., Soler, Y., Perry, M., Reynolds, J.L., El-Hage, N., 2020. Impact of Severe Acute Respiratory Syndrome Coronavirus 2 (SARS-CoV-2) in the Nervous System: Implications of COVID-19 in Neurodegeneration. *Front. Neurol.* 11, 583459–583459.
- Román, G.C., Spencer, P.S., Reis, J., Buguet, A., Faris, M.E.A., Katrak, S.M., Láinez, M., Medina, M.T., Meshram, C., Mizusawa, H., Öztürk, S., Wasay, M., Group, W.F.N.E.N.S., 2020. The neurology of COVID-19 revisited: A proposal from the Environmental Neurology Specialty Group of the World Federation of Neurology to implement international neurological registries. *J. Neurol. Sci.* 414, 116884–116884.
- Rossi, A., 2008. Imaging of acute disseminated encephalomyelitis. *Neuroimaging Clin. North Am.* 18, 149–161.
- Rothan, H.A., Byrareddy, S.N., 2020. The epidemiology and pathogenesis of coronavirus disease (COVID-19) outbreak. *J. Autoimmun.* 109, 102433–102433.
- Rozmyslowicz, T., Majka, M., Kijowski, J., Murphy, S.L., Conover, D.O., Poncz, M., Ratajczak, J., Gaulton, G.N., Ratajczak, M.Z., 2003. Platelet- and megakaryocyte-derived microparticles transfer CXCR4 receptor to CXCR4-null cells and make them susceptible to infection by X4-HIV. *AIDS (Lond., Engl.)* 17, 33–42.
- Salamanna, F., Maglio, M., Landini, M.P., Fini, M., 2020. Body Localization of ACE-2: On the Trail of the Keyhole of SARS-CoV-2. *Front Med (Lausanne)* 7, 594495–594495.
- Sancho-Saldaña, A., Lambea-Gil, Á., Liesa, J.L.C., Caballo, M.R.B., Garay, M.H., Celada, D.R., Serrano-Ponz, M., 2020. Guillain-Barré syndrome associated with leptomenigeal enhancement following SARS-CoV-2 infection. *Clin. Med. (Lond., Engl.)* 20, e93–e94.
- Serrano, G.E., Walker, J.E., Arce, R., Glass, M.J., Vargas, D., Sue, L.I., Intorcchia, A.J., Nelson, C.M., Oliver, J., Papa, J., Russell, A., Suszczewicz, K.E., Borja, C.I., Belden, C., Goldfarb, D., Shprecher, D., Atri, A., Adler, C.H., Shill, H.A., Driver-Dunckley, E., Mehta, S.H., Readhead, B., Huentelman, M.J., Peters, J.L., Alevritis, E., Bimi, C., Mizgerd, J.P., Reiman, E.M., Montine, T.J., Desforges, M., Zehnder, J.L., Sahoo, M.K., Zhang, H., Solis, D., Pinsky, B.A., Deture, M., Dickson, D.W., Beach, T. G., 2021. Mapping of SARS-CoV-2 Brain Invasion and Histopathology in COVID-19 Disease. *medRxiv: Prepr. Serv. Health Sci.*
- Setiadi, A., Korim, W.S., Elsaafien, K., Yao, S.T., 2018. The role of the blood-brain barrier in hypertension. *Exp. Physiol.* 103, 337–342.
- Sharifian-Dorche, M., Huot, P., Oshero, M., Wen, D., Saveriano, A., Giacomini, P.S., Antel, J.P., Mowla, A., 2020. Neurological complications of coronavirus infection: a comparative review and lessons learned during the COVID-19 pandemic. *J. Neurol. Sci.* 417, 117085.
- Sharpe, M.C., Archard, L.C., Banatvala, J.E., Borysiewicz, L.K., Clare, A.W., David, A., Edwards, R.H., Hawton, K.E., Lambert, H.P., Lane, R.J., 1991. A report—chronic fatigue syndrome: guidelines for research. *J. R. Soc. Med.* 84, 118–121.
- Siegler, J.E., Cardona, P., Arenillas, J.F., Talavera, B., Guillen, A.N., Chavarría-Miranda, A., de Lera, M., Khandelwal, P., Bach, I., Patel, P., Singla, A., Requena, M., Ribo, M., Jillella, D.V., Rangaraju, S., Nogueira, R.G., Haussen, D.C., Vazquez, A.R., Urria, X., Chamorro, Á., Román, S., Thon, J.M., Then, R., Sanborn, E., de la Ossa, N. P., Millán, M., Ruiz, I.N., Mansour, O.Y., Megahed, M., Tiu, C., Terceosa, E.O., Radu, R.A., Nguyen, T.N., Curiale, G., Kaliaev, A., Czup, A.L., Sebaugh, J., Zha, A.M., Liebskind, D.S., Ortega-Gutierrez, S., Farooqui, M., Hassan, A.E., Preston, L., Patterson, M.S., Bushnaq, S., Zaidat, O., Jovin, T.G., 2020. Cerebrovascular events and outcomes in hospitalized patients with COVID-19: The SVIN COVID-19 Multinational Registry. *Int. J. Stroke: Off. J. Int. Stroke Soc.* 1747493020959216.
- Skendros, P., Mitsios, A., Chrysanthopoulou, A., Mastellos, D.C., Metallidis, S., Rafailidis, P., Ntinopoulou, M., Sertaridou, E., Tsironidou, V., Tsigalou, C., Tektonidou, M., Konstantinidis, T., Papagoras, C., Mitroulis, I., Germanidis, G., Lambris, J.D., Ritis, K., 2020. Complement and tissue factor-enriched neutrophil extracellular traps are key drivers in COVID-19 immunothrombosis. *The. J. Clin. Investig.* 130, 6151–6157.
- Solé, G., Mathis, S., Friedman, D., Salort-Campana, E., Tard, C., Bouhour, F., Magot, A., Annane, D., Clair, B., Le Masson, G., Soulages, A., Duval, F., Carla, L., Violleau, M.H., Saulnier, T., Segovia-Kueny, S., Kern, L., Antoine, J.C., Beaudonnet, G., Audic, F., Kremer, L., Chanson, J.B., Nadaj-Pakleza, A., Stojkovic, T., Cintas, P., Spinazzi, M., Foubert-Samier, A., Attarian, S., 2021. Impact of Coronavirus Disease 2019 in a French Cohort of Myasthenia Gravis. *Neurology.*
- Solomon, I.H., Normandin, E., Bhattacharyya, S., Mukerji, S.S., Keller, K., Ali, A.S., Adams, G., Hornick, J.L., Padera Jr., R.F., Sabeti, P., 2020a. Neuropathological Features of Covid-19. *The. N. Engl. J. Med.* 383, 989–992.
- Solomon, I.H., Normandin, E., Bhattacharyya, S., Mukerji, S.S., Keller, K., Ali, A.S., Adams, G., Hornick, J.L., Padera Jr., R.F., Sabeti, P., 2020b. Neuropathological Features of Covid-19. *The. N. Engl. J. Med.* 383, 989–992.
- Sotoca, J., Rodríguez-Alvarez, Y., 2020. COVID-19-associated acute necrotizing myelitis. *Neurol. (R.) Neuroimmunol. Neuroinflamm.* 7.
- Speeckaert, M.M., Speeckaert, R., Delanghe, J.R., 2020. Potential underlying mechanisms of cerebral venous thrombosis associated with COVID-19. *J. Neuroradiol. = J. De. Neuroradiol.* 47, 473–474.
- Steardo Jr., L., Steardo, L., Verkhatsky, A., 2020. Psychiatric face of COVID-19. *Transl. Psychiatry* 10, 261.
- Stefano, G.B., 2021. Historical Insight into Infections and Disorders Associated with Neurological and Psychiatric Sequelae Similar to Long COVID. *Med. Sci. Monit.: Int. Med. J. Exp. Clin. Res.* 27, e931447.
- Sun, T., Guan, J., 2020. Novel coronavirus and the central nervous system. *Eur. J. Neurol.: Off. J. Eur. Fed. Neurol. Soc.* 27, e52.
- Suwanwongse, K., Shabarek, N., 2020. Rhabdomyolysis as a Presentation of 2019 Novel Coronavirus Disease. *Cureus* 12, e7561.
- Suzuki, M., Hotta, M., Nagase, A., Yamamoto, Y., Hirakawa, N., Satake, Y., Nagata, Y., Suehiro, T., Kanemoto, H., Yoshiyama, K., Mori, E., Hashimoto, M., Ikeda, M., 2020. The behavioral pattern of patients with frontotemporal dementia during the COVID-19 pandemic. *Int. Psychogeriatr.* 32, 1231–1234.
- Sweid, A., Hammoud, B., Weinberg, J.H., Oneissi, M., Raz, E., Shapiro, M., DePrince, M., Tjoumakaris, S., Gooch, M.R., Herial, N.A., Zarzour, H., Romo, V., Rosenwasser, R. H., Jabbour, P., 2020. Letter: Thrombotic Neurovascular Disease in COVID-19 Patients. *Neurosurgery* 87, E400–e406.
- Tan, Y.K., Goh, C., Leow, A.S.T., Tambyah, P.A., Ang, A., Yap, E.S., Tu, T.M., Sharma, V. K., Yeo, L.L.L., Chan, B.P.L., Tan, B.Y.Q., 2020. COVID-19 and ischemic stroke: a systematic review and meta-summary of the literature. *J. Thromb. Thrombolysis* 50, 587–595.
- Tang, N., Li, D., Wang, X., Sun, Z., 2020. Abnormal coagulation parameters are associated with poor prognosis in patients with novel coronavirus pneumonia. *J. Thromb. Haemost.: JTH* 18, 844–847.
- Taquet, M., Geddes, J.R., Husain, M., Luciano, S., Harrison, P.J., 2021a. 6-month neurological and psychiatric outcomes in 236 379 survivors of COVID-19: a retrospective cohort study using electronic health records. *The Lancet. Psychiatry.*
- Taquet, M., Luciano, S., Geddes, J.R., Harrison, P.J., 2021b. Bidirectional associations between COVID-19 and psychiatric disorder: retrospective cohort studies of 62 354 COVID-19 cases in the USA. *The Lancet. Psychiatry* 8, 130–140.
- Tatu, L., Nono, S., Grácio, S., Koçer, S., 2021. Guillain-Barré syndrome in the COVID-19 era: another occasional cluster? *J. Neurol.* 268, 1198–1200.
- Thachil, J., Tang, N., Gando, S., Falanga, A., Cattaneo, M., Levi, M., Clark, C., Iba, T., 2020. ISTH interim guidance on recognition and management of coagulopathy in COVID-19. *J. Thromb. Haemost.: JTH* 18, 1023–1026.
- Theoharides, T.C., Cholevas, C., Polyzoidis, K., Politis, A., 2021. Long-COVID syndrome-associated brain fog and chemofog: Luteolin to the rescue. *BioFactors (Oxf., Engl.)* 47, 232–241.
- Tiet, M.Y., AlShaikh, N., 2020. Guillain-Barré syndrome associated with COVID-19 infection: a case from the UK. *BMJ case Rep.* 13.
- Tsai, S.T., Lu, M.K., San, S., Tsai, C.H., 2020. The Neurologic Manifestations of Coronavirus Disease 2019 Pandemic: A Systemic Review. *Front. Neurol.* 11, 498.
- Uversky, V.N., Elrashdy, F., Aljadawi, A., Ali, S.M., Khan, R.H., Redwan, E.M., 2021. Severe acute respiratory syndrome coronavirus 2 infection reaches the human nervous system: How? *J. Neurosci. Res.* 99, 750–777.
- Valencia-Sanchez, C., Wingerchuk, D.M., 2020. A fine balance: Immunosuppression and immunotherapy in a patient with multiple sclerosis and COVID-19. *Mult. Scler. Relat. Disord.* 42, 102182.
- Varatharaj, A., Thomas, N., Ellul, M.A., Davies, N.W.S., Pollak, T.A., Tenorio, E.L., Sultan, M., Easton, A., Breen, G., Zandi, M., Coles, J.P., Manji, H., Al-Shahi Salman, R., Menon, D.K., Nicholson, T.R., Benjamin, L.A., Carson, A., Smith, C., Turner, M.R., Solomon, T., Kneen, R., Pett, S.L., Galea, I., Thomas, R.H., Michael, B. D., 2020. Neurological and neuropsychiatric complications of COVID-19 in 153 patients: a UK-wide surveillance study. *The Lancet. Psychiatry* 7, 875–882.
- Varga, Z., Flammer, A.J., Steiger, P., Haberecker, M., Andermatt, R., Zinkernagel, A.S., Mehra, M.R., Schuepbach, R.A., Ruschitzka, F., Moch, H., 2020. Endothelial cell infection and endotheliitis in COVID-19. *Lancet* 395, 1417–1418.
- Vargas, G., Medeiros Geraldo, L.H., Gedeão Salomão, N., Viana Paes, M., Regina Souza Lima, F., Carvalho, F., 2020. Alcantara Gomes, Severe acute respiratory syndrome coronavirus 2 (SARS-CoV-2) and glial cells: Insights and perspectives. *Brain, Behav., Immun. - Health* 7, 100127.
- Viguier, A., Delamarre, L., Duplantier, J., Olivot, J.M., Bonneville, F., 2020. Acute ischemic stroke complicating common carotid artery thrombosis during a severe COVID-19 infection. *J. Neuroradiol. = J. De. Neuroradiol.* 47, 393–394.
- Vizheh, M., Qorbani, M., Arzaghi, S.M., Muhidin, S., Javanmard, Z., Esmaili, M., 2020. The mental health of healthcare workers in the COVID-19 pandemic: A systematic review. *J. Diabetes Metab. Disord.* 19, 1–12.
- Vogrig, A., Gigli, G.L., Bnà, C., Morassi, M., 2021. Stroke in patients with COVID-19: Clinical and neuroimaging characteristics. *Neurosci. Lett.* 743, 135564–135564.
- Wang, D., Hu, B., Hu, C., Zhu, F., Liu, X., Zhang, J., Wang, B., Xiang, H., Cheng, Z., Xiong, Y., Zhao, Y., Li, Y., Wang, X., Peng, Z., 2020. Clinical Characteristics of 138 Hospitalized Patients With 2019 Novel Coronavirus-Infected Pneumonia in Wuhan, China. *Jama* 323, 1061–1069.
- Wang, L., Ren, Z., Ma, L., Han, Y., Wei, W., Jiang, E., Ji, X.-Y., 2021. Progress in Research on SARS-CoV-2 Infection Causing Neurological Diseases and Its Infection Mechanism. *Front. Neurol.* 11, 592888–592888.
- Welge-Lüssen, A., Wolfensberger, M., 2006. Olfactory disorders following upper respiratory tract infections. *Adv. oto-rhino-laryngol.* 63, 125–132.
- von Weyhern, C.H., Kaufmann, I., Neff, F., Kremer, M., 2020. Early evidence of pronounced brain involvement in fatal COVID-19 outcomes. *Lancet* 395, e109.
- Wilson, J.G., Simpson, L.J., Ferreira, A.M., Rustagi, A., Roque, J., Asuni, A., Ranganath, T., Grant, P.M., Subramanian, A., Rosenberg-Hasson, Y., Maecker, H.T.,

- Holmes, S.P., Levitt, J.E., Blish, C.A., Rogers, A.J., 2020. Cytokine profile in plasma of severe COVID-19 does not differ from ARDS and sepsis. *JCI Insight* 5.
- Wohleb, E.S., Franklin, T., Iwata, M., Duman, R.S., 2016. Integrating neuroimmune systems in the neurobiology of depression. *Nat. Rev. Neurosci.* 17, 497–511.
- Wu, Y., Xu, X., Chen, Z., Duan, J., Hashimoto, K., Yang, L., Liu, C., Yang, C., 2020. Nervous system involvement after infection with COVID-19 and other coronaviruses. *Brain, Behav., Immun.* 87, 18–22.
- Xiang, P., Xu, X., Gao, L., Wang, H., Xiong, H., Li, R., 2020. First case of 2019 novel coronavirus disease with encephalitis. *ChinaXiv* 202003, 00015.
- Xu, H., Zhong, L., Deng, J., Peng, J., Dan, H., Zeng, X., Li, T., Chen, Q., 2020b. High expression of ACE2 receptor of 2019-nCoV on the epithelial cells of oral mucosa. *Int. J. Oral. Sci.* 12, 8.
- Xu, Z., Shi, L., Wang, Y., Zhang, J., Huang, L., Zhang, C., Liu, S., Zhao, P., Liu, H., Zhu, L., Tai, Y., Bai, C., Gao, T., Song, J., Xia, P., Dong, J., Zhao, J., Wang, F.S., 2020a. Pathological findings of COVID-19 associated with acute respiratory distress syndrome. *The Lancet. Respir. Med.* 8, 420–422.
- Yin, H., Zhang, Y., Xu, Y., Peng, B., Cui, L., Zhang, S., 2021. The Impact of COVID-19 on Patients With Neuromyelitis Optica Spectrum Disorder Beyond Infection Risk. *Front. Neurol.* 12, 657037.
- Yuksel, H., Gursoy, G.T., Dirik, E.B., Kenar, S.G., Bektas, H., Yamanel, L., Guner, H.R., 2021. Neurological manifestations of COVID-19 in confirmed and probable cases: A descriptive study from a large tertiary care center. *J. Clin. Neurosci.: Off. J. Neurosurg. Soc. Australas.* 86, 97–102.
- Zhou, F., Yu, T., Du, R., Fan, G., Liu, Y., Liu, Z., Xiang, J., Wang, Y., Song, B., Gu, X., Guan, L., Wei, Y., Li, H., Wu, X., Xu, J., Tu, S., Zhang, Y., Chen, H., Cao, B., 2020. Clinical course and risk factors for mortality of adult inpatients with COVID-19 in Wuhan, China: a retrospective cohort study. *Lancet (Lond., Engl.)* 395, 1054–1062.
- Zou, L., Ruan, F., Huang, M., Liang, L., Huang, H., Hong, Z., Yu, J., Kang, M., Song, Y., Xia, J., Guo, Q., Song, T., He, J., Yen, H.L., Peiris, M., Wu, J., 2020. SARS-CoV-2 Viral Load in Upper Respiratory Specimens of Infected Patients. *The N. Engl. J. Med.* 382, 1177–1179.
- Zrzavy, T., Wimmer, I., Rommer, P.S., Berger, T., 2020. Immunology of COVID-19 and disease-modifying therapies: the good, the bad and the unknown. *Eur. J. Neurol.* <https://doi.org/10.1111/ene.14578>.
- Zubair, A.S., McAlpine, L.S., Gardin, T., Farhadian, S., Kuruvilla, D.E., Spudich, S., 2020. Neuropathogenesis and Neurologic Manifestations of the Coronaviruses in the Age of Coronavirus Disease 2019: A Review. *JAMA Neurol.* 77, 1018–1027.
- Županić, S., Perić Šitum, M., Majdak, M., Karakaš, M., Bašić, S., Sporiš, D., 2021. Case series of COVID-19 in patients with myasthenia gravis: a single institution experience. *Acta Neurol. Belg.* 1–6.