

# Spine and Spinal Cord Injury Associated with a Fracture in Elderly Patients with Ankylosing Spondylitis

Norihiro ISOGAI,<sup>1</sup> Shunji ASAMOTO,<sup>1,2</sup> Satoshi NAKAMURA,<sup>1</sup> Kiminori SAKURAI,<sup>1,2</sup>  
Shinichi ISHIHARA,<sup>1</sup> Masayuki ISHIKAWA,<sup>1</sup> Makoto NISHIYAMA,<sup>1</sup>  
Fumitaka YOSHIOKA,<sup>2</sup> Kazuhiro SAMURA,<sup>2</sup> and Masatou KAWASHIMA<sup>2</sup>

<sup>1</sup>Spine and Spinal Cord Center, School of Medicine, International University of Health and Welfare, Mita Hospital, Tokyo, Japan;

<sup>2</sup>Department of Neurosurgery, School of Medicine, International University of Health and Welfare, Mita Hospital, Tokyo, Japan

## Abstract

There are few cases of spinal cord injury with ankylosing spondylitis (AS). This study investigated the clinical results of a spinal cord injury with a fracture in elderly patients with AS. Nine patients who had sustained a spinal cord injury with vertebral fractures in ankylosed spines were included in this study. The mean age was 79.3 years; two were male and seven were female. The mechanism of injury, the level of vertebral fractures, clinical methods, the follow-up period, and treatment outcomes were investigated. The mechanism of injury of six cases was a fall and in the others was a slip. The levels of vertebral fractures were a cervical lesion ( $n = 5$ ), a thoracic lesion ( $n = 3$ ), and a lumbar lesion ( $n = 1$ ). Six cases underwent a surgical procedure with posterior fusion and decompression, two cases were treated only with a brace, and one case was treated with a halo vest. The mean follow-up period was 4.3 years. The neurological deficit treatment outcomes were improved or no change in four cases each and one case had died. There was not much difference in treatment outcomes between a surgical treatment and a conservative treatment. Computed tomography imaging to evaluate the entire spine is required in all patients with AS with a possible spinal fracture. A surgical treatment and early rising and rehabilitation should be recommended for patients with fractures and AS to avoid further complications, not from the standpoint of improving the neurological status.

Key words: ankylosing spondylitis, spinal fracture, pulmonary complication

## Introduction

The incidence of spinal cord injury has increased in the elderly,<sup>1)</sup> and it can develop with minimal injury because of degenerative spinal changes such as cervical stenosis, ossification of the posterior longitudinal ligament, and osteoporosis. Although there are many reports on the clinical outcomes of spinal cord injury associated with a fracture in elderly patients,<sup>2)</sup> there is not enough evidence on the treatment policy for a spinal fracture with ankylosing spondylitis (AS), considering that it is an uncommon condition.

AS is an inflammatory rheumatic disease that affects the skeleton, particularly the spine.<sup>3)</sup> Substantial evidence strongly favors a direct role of HLA-B27 and a genetic susceptibility to AS.<sup>4)</sup> The precise prevalence of AS is unclear and is estimated to be between 0.1% and 1.4%.<sup>5)</sup> Some authors have argued that the prevalence is equal in both genders;<sup>6)</sup> however, others have reported it to be 10 times more common in men than in women.<sup>7)</sup> Furthermore, it typically begins before the age of 30 and has a slow but steady progression.<sup>8)</sup>

In patients with AS, a spinal injury poses serious dangers because of the completely different responses of the spine to a mechanical load. Further, the clinical outcome of a neurological prognosis of this type of fracture and the treatment policy are still unclear. The aim of this study was to investigate the clinical results of a spinal cord injury in elderly patients with AS.

Received May 15, 2017; Accepted October 19, 2017

Copyright© 2018 by The Japan Neurosurgical Society  
This work is licensed under a Creative Commons Attribution-NonCommercial-NoDerivatives International License.

## Methods

Nine patients who had suffered a spinal cord injury with vertebral fractures in ankylosed spines were included in this study. A retrospective cohort of the patients admitted to a hospital between 2008 and 2015 was followed up at the end of 2015. Neurological deficits were classified according to the American Spinal Injury Association (ASIA) grading system,<sup>9)</sup> and preoperative and postoperative ASIA grade changes were documented. The mechanism of injury, level of vertebral fractures, clinical methods, follow-up period, and treatment outcomes were investigated.

Not all patients were diagnosed with AS before the injury by Modified New York Criteria<sup>10)</sup> (Table 1). The criteria included clinical factors such as lumbar pain, limitation of lumbar spine motion, or limitation of chest expansion. Therefore, it is difficult to diagnose AS and distinguish diffuse idiopathic skeletal hyperostosis (DISH) according to the criteria after spinal cord injury. In this study, the diagnosis of AS was determined by a designated doctor using the radiological definition of DISH<sup>11)</sup> (Table 2). Using computed tomography (CT) scanning at the start of treatment,

**Table 1 Modified New York criteria for the diagnosis of ankylosing spondylitis**

Diagnosis	
<b>Definite AS:</b>	1 radiologic criterion + at least 1 clinical criterion
<b>Probable AS:</b>	Radiologic criteria without clinical criteria or 3 clinical criteria without radiologic criteria
Clinical criteria	
<b>Inflammatory back pain:</b>	Lower back pain for >3 months, improved by exercise, not relieved by rest
	Limitation of lumbar spine motion in both the sagittal and frontal planes
	Limitation of chest expansion relative to normal values for age and sex
Radiologic criterion	
	Sacroiliitis grade >2 bilaterally

**Table 2 Radiological findings of ankylosing spondylitis and diffuse idiopathic skeletal hyperostosis**

Site	Disease	
	Ankylosing spondylitis	Diffuse idiopathic skeletal hyperostosis
Vertebral bodies	Thin syndesmophytes; osteitis with squaring	Flowing ossification and hyperostosis; large osteophytes
Intervertebral discs	Normal or convex in shape	Normal or mild decrease in height
Apophyseal joints	Erosion, sclerosis, and bony ankylosis	Normal or mild sclerosis
Sacroiliac joints	Erosion, sclerosis, and bony ankylosis	Para-articular osteophytes

three patients were diagnosed with AS by bony ankylosis of apophyseal joint and sacroiliac joint and thin syndesmophytes without osteophytes. In addition, six patients were accurately diagnosed with AS by the evaluation of sacroiliac joint after the acute phase.

The mean age was 79.3 years (range, 74–83 years); two were male and seven were female. Six patients underwent surgery because of different individual factors that included the level of fractures, fracture pattern with or without spinal cord compression, spondylitic changes of the spine, neurological deficit, and general condition such as respiratory complication and disturbance of consciousness.

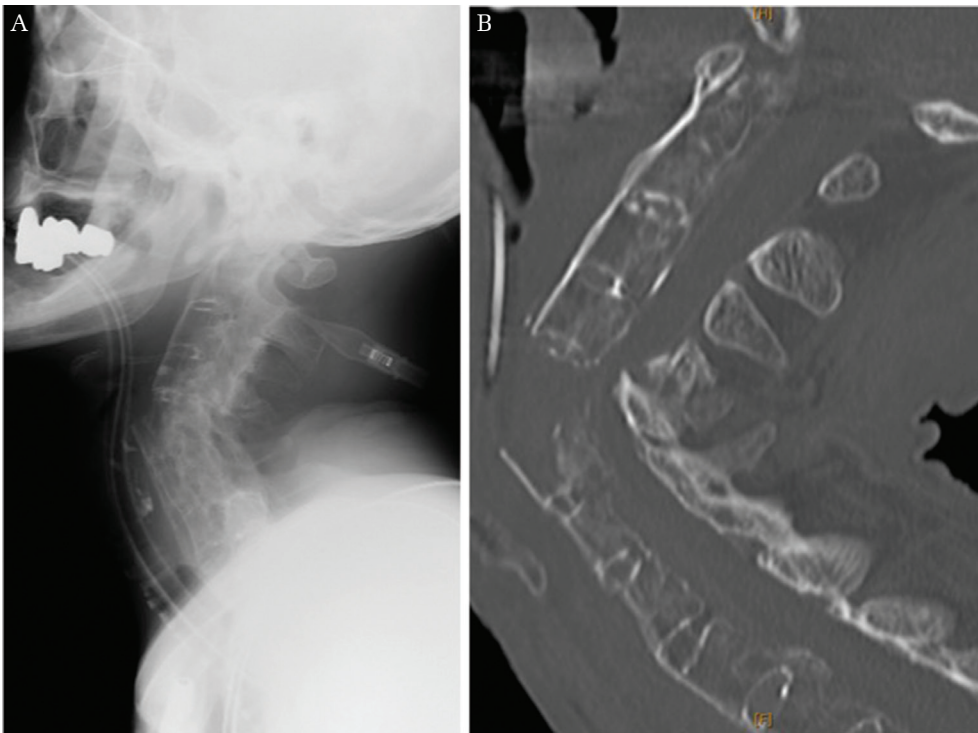
## Results

The mechanism of injury was a fall in six patients and a slip in the remaining three. The level of vertebral fractures was a cervical lesion in five cases, a thoracic lesion in three cases, and a lumbar lesion in one case.

All fractures were located on the vertebral level, not on the disc level. The surgical treatment was planned for all nine cases; however, lung pneumonia was diagnosed in three cases before surgery. They were unable to undergo the surgery and prolonged bed rest for more than a month was advised. The six cases who had surgery underwent a posterior fusion and decompression with instrumentation including at least two segments above and below the injury level, two cases were treated only with a brace, and one case was treated with a halo vest. The mean follow-up period was 4.3 years (range, 0.25–8 years). The deficits were classified as ASIA C in eight cases and as ASIA A in one case. At the time of discharge, their neurological deficit treatment outcomes were improved or no change in four cases each and one case had died (Table 3). In the six patients who underwent surgery, two patients improved and four showed no changes. In the three patients who were treated conservatively, two cases were improved and one case had died.

**Table 3** Clinical outcomes of nine patients with a spinal fracture and ankylosing spondylitis

	Age	Sex	Mechanism	Injury level	Surgical level	ASIA	Final ASIA	Follow-up (years)
1	74	M	Slip	C6	C3-T2	C	E	8
2	83	M	Fall	T12	T9-L3	C	E	0.3
3	82	M	Slip	C7	(-)	C	E	5
4	83	F	Fall	C5	Halo vest	A	A	Dead
5	75	M	Fall	T12	T10-L2	C	C	3
6	78	M	Fall	C6	C4-T1	C	C	4
7	82	M	Fall	T7	T5-T9	C	C	4
8	80	F	Slip	L1	(-)	C	E	5
9	77	M	Fall	C7	C5-T2	C	C	6



**Fig. 1** Case 4. Lateral radiography (A) and computed tomography scanning (B) reveal a severe dislocated fracture of the C5 level and so-called bamboo spine resulting from ankylosing spondylitis.

## Cases

### Case 4: Halo Vest

This 83-year-old woman had no history of treating AS. She sustained a fall injury on the stairs at home and was transported to a hospital with a disturbance of consciousness. Radiography and CT scanning revealed a severe dislocated fracture at the C5 level and bony ankylosis of the cervical apophyseal joint (Fig. 1). Lung pneumonia and a pelvic fracture were also pointed out. She underwent intubation, ventilation, and a halo vest. Cervical radiography showed an inadequate reposition of the fracture (Fig. 2). She died 10 days after the injury without recovering consciousness.

### Case 1: Posterior fusion and decompression

This 74-year-old man who also had no history of treating AS sustained an injury as a result of a slip and was transported to a hospital. CT scanning revealed a three-column injury at the C6 level and bony ankylosis of the cervical apophyseal joint (Fig. 3). His neurological deficit severity was classified as ASIA C. Posterior fusion and decompression surgery were undertaken from C3 to T2 (Figs. 4A and 4B). Six months after surgery, he could walk alone, and his neurological deficit severity was classified as ASIA E. CT scanning at the time revealed a radiological bony union (Fig. 4C). No perioperative complications including implant failure were encountered.

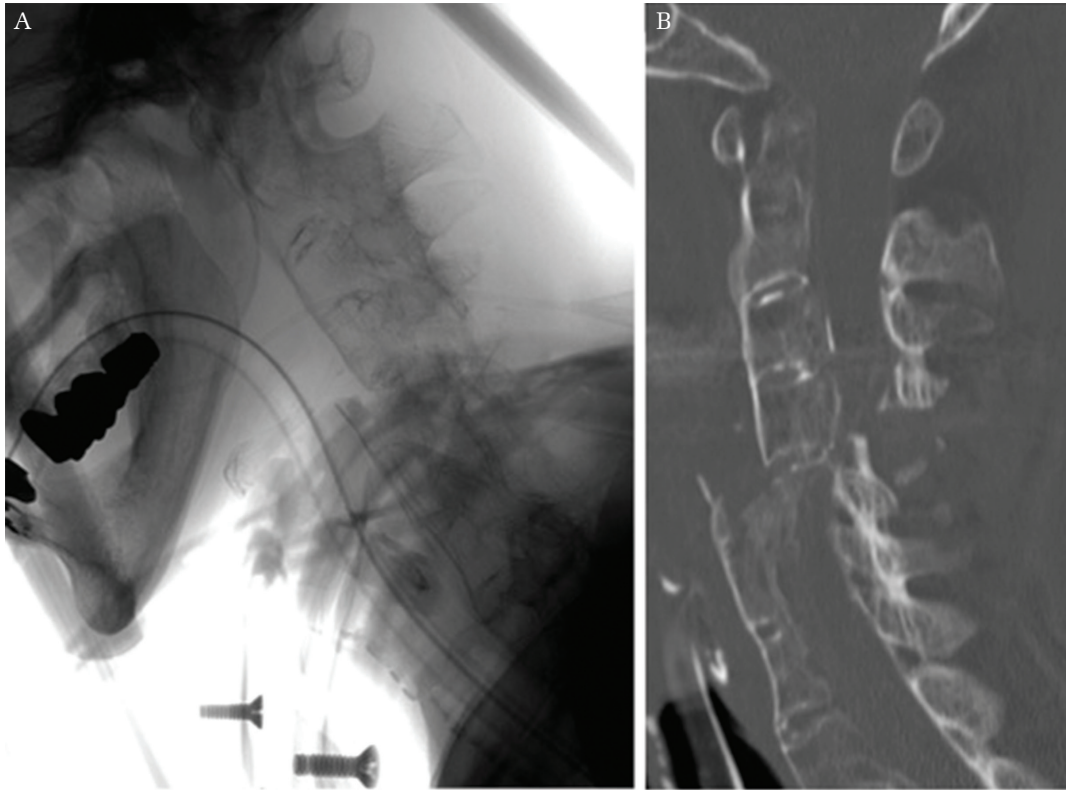


Fig. 2 Case 4. Lateral radiography (A) and computed tomography scanning (B) show an inadequate reposition of a dislocated fracture with a halo vest.

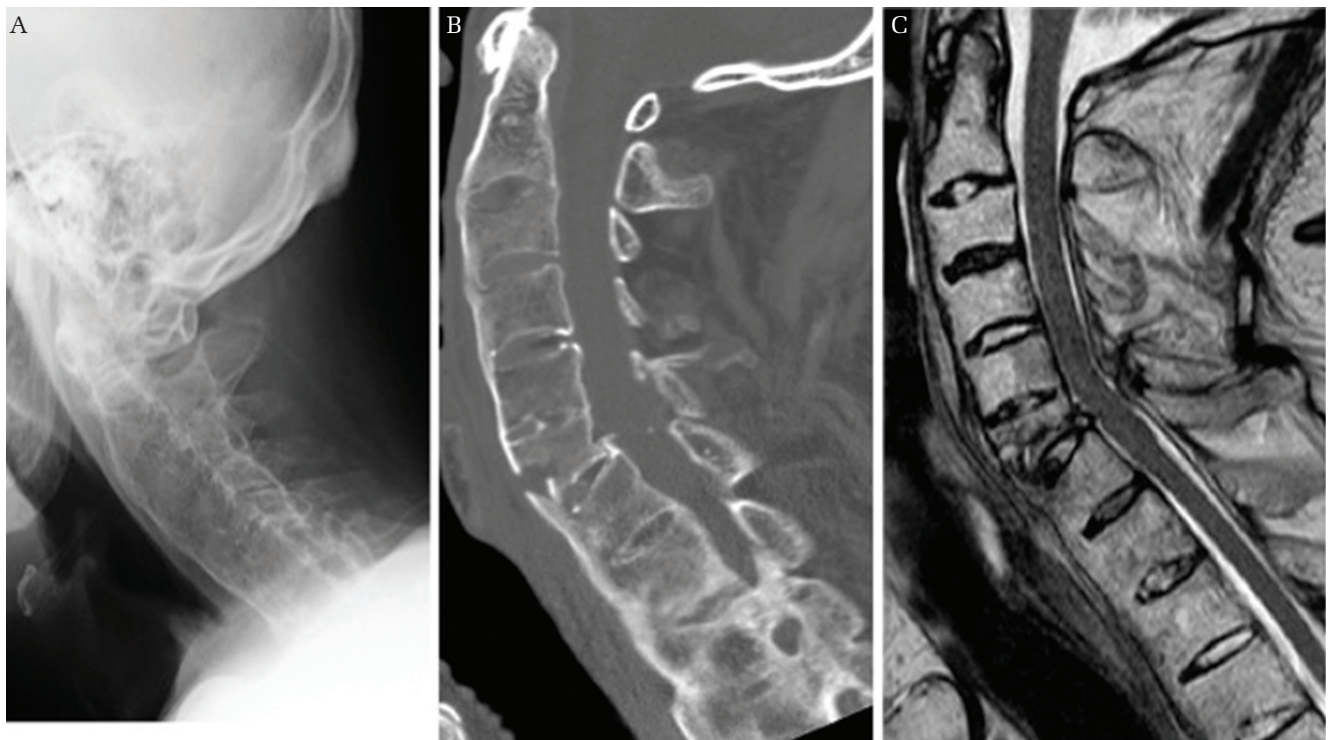


Fig. 3 Case 1. Lateral radiography (A) and computed tomography scanning (B) reveal a vertebral fracture of the C6 level, and a magnetic resonance imaging (C) reveals a spinal cord injury at the same level.

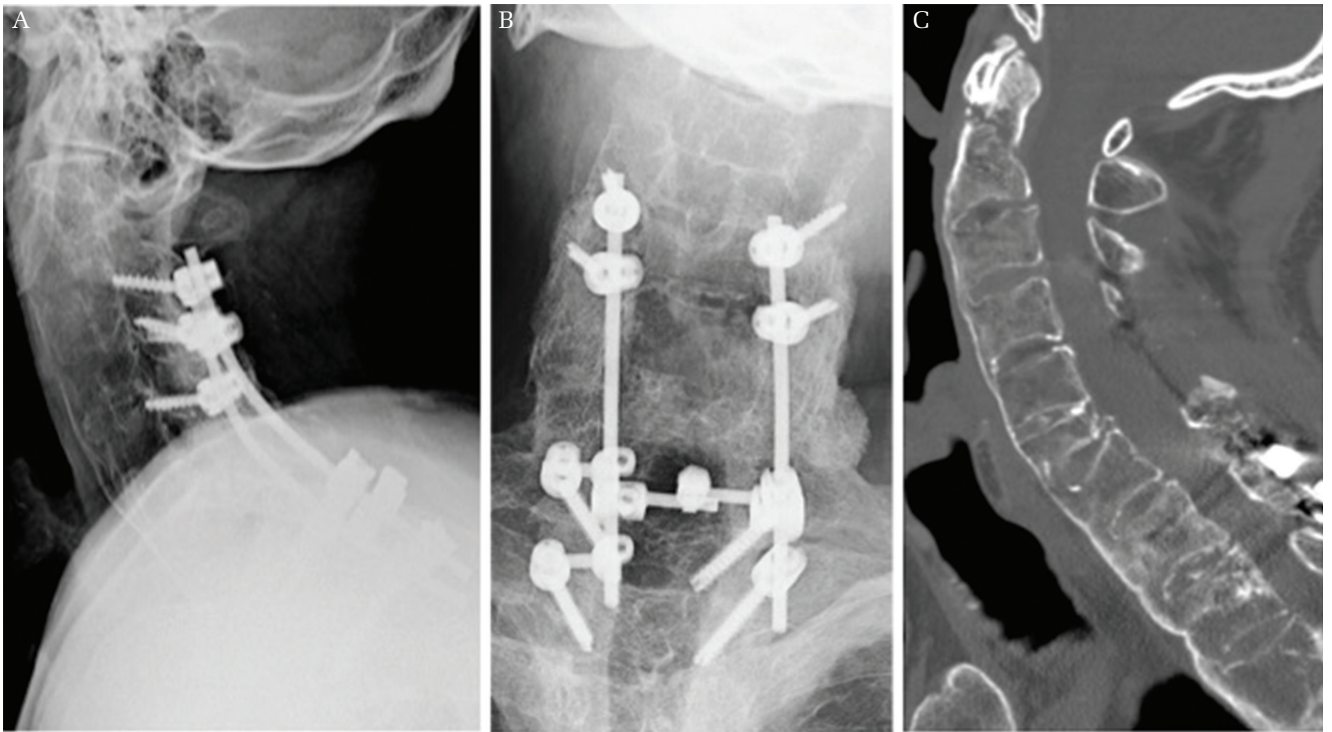


Fig. 4 Case 1. Postoperative plain radiography (A and B) and computed tomography scanning 6 months after surgery (C) show a bony union.

## Discussion

Compared with the general population, patients with AS are at high risk for spinal fracture and spinal cord injury.<sup>12)</sup> Individuals with AS are known to have an increased incidence of hypertension, cardiovascular mortality, and pulmonary involvement.<sup>13,14)</sup> Therefore, this type of fracture has a poorer predicted clinical outcome. However, because AS is a rare condition and the demographics remain unclear, details of clinical outcomes and an established treatment for this type of fracture have not been elucidated.

Previous reports showed that the cervical spine was the most common site of fracture with AS.<sup>15)</sup> Although the most common site was cervical spine in this study as well, thoracic and lumbar fractures were also seen. An evaluation of the entire spine is needed in all patients with AS with a possible spinal fracture. CT imaging is also recommended to evaluate the fracture, because occult fractures in AS were not apparent during routine plain radiographic and magnetic resonance imaging studies.<sup>16)</sup>

All fractures were located on the vertebral level. Osteoporosis is a well-known complication of AS<sup>17)</sup>, and ligamentous ossification occurred on the disc and joint capsule in patients with AS. The mechanical strength may then be weakened, especially on the vertebral level. This pathognomonic location was

considered as a result of osteoporosis and ligamentous ossification.

All of the patients in this study were over 70 years of age, and they were not diagnosed with AS before their injury although AS typically starts before the age of 30.<sup>8)</sup> It was considered that the progression of AS would result in an increased risk of spinal fractures and that this type of fracture might increase more and more in an aging society.

Although one study showed that a surgical treatment could improve a neurological status of patient with spinal fracture and AS,<sup>18)</sup> there was not much difference in neurological treatment outcomes between a surgical treatment and a conservative treatment in this study, and a few patients (Cases 3 and 8) showed a good neurological recovery without a surgical treatment. A conservative treatment for a fracture with AS not involving a dislocation or a neurological deficit has been described.<sup>19–21)</sup> However, they were associated with a significant problem such as skin ulcerations or a pulmonary problem due to a prolonged immobilization with a rigid cervical collar or a halo brace.<sup>20)</sup> In this study, severe pneumonia was diagnosed before surgery in the conservative cases, and they were unable to undergo the surgical treatment. Therefore, early surgical interventions for treatment of spine fracture with AS may be effective in avoiding pulmonary

complication, not from the standpoint of improving the neurological status.

While some surgeons reported a higher risk of postoperative complications in 1980s,<sup>22)</sup> more recently, surgical fixation such as a long segment posterior fixation with screws and rods to avoid risks related to a conservative treatment is preferred.<sup>18)</sup> This might be the result of progress in spinal implant and surgical techniques. As such, the treatment policy of spinal fractures with AS should be decided based on preventive measures of the surgical complication, not from the standpoint of improving the neurological status. Today, it is also considered that a surgical treatment is superior to a conservative treatment to avoid further complications. Thus, a surgical treatment and early rising and rehabilitation should be recommended for fractures with AS.

## Conclusion

A CT imaging evaluation of the entire spine is needed in all patients with AS with a possible spinal fracture. Although there was not much difference in neurological treatment outcomes between a surgical treatment and a conservative treatment for fractures with AS, a surgical treatment and early rising and rehabilitation should be recommended to avoid further complications.

## Conflicts of Interest Disclosure

All authors certify that they have no affiliations with or involvement in any organization or entity with any financial interest (e.g., honoraria; educational grants; participation in speakers' bureaus; membership, employment, consultancies, stock ownership, or other equity interest; and expert testimony or patent-licensing arrangements) or non-financial interest (e.g., personal or professional relationships, affiliations, knowledge, or beliefs) in the subject matter or materials discussed in this manuscript.

## Informed Consent

Informed consent was obtained from all individual participants included in the study.

## References

- 1) Devivo MJ: Epidemiology of traumatic spinal cord injury: trends and future implications. *Spinal Cord* 50: 365–372, 2012
- 2) van den Berg ME, Castellote JM, Mahillo-Fernandez I, de Pedro-Cuesta J: Incidence of spinal cord injury worldwide: a systematic review. *Neuroepidemiology* 34: 184–192; discussion 192, 2010
- 3) Lee HS, Kim TH, Yun HR, et al.: Radiologic changes of cervical spine in ankylosing spondylitis. *Clin Rheumatol* 20: 262–266, 2001
- 4) Khan MA, Ball EJ: Genetic aspects of ankylosing spondylitis. *Best Pract Res Clin Rheumatol* 16: 675–690, 2002
- 5) Braun J, Bollow M, Remlinger G, et al.: Prevalence of spondylarthropathies in HLA-B27 positive and negative blood donors. *Arthritis Rheum* 41: 58–67, 1998
- 6) El Tecle NE, Abode-Iyamah KO, Hitchon PW, Dahdaleh NS: Management of spinal fractures in patients with ankylosing spondylitis. *Clin Neurol Neurosurg* 139: 177–182, 2015
- 7) Einsiedel T, Schmelz A, Arand M, et al.: Injuries of the cervical spine in patients with ankylosing spondylitis: experience at two trauma centers. *J Neurosurg Spine* 5: 33–45, 2006
- 8) Feldtkeller E, Khan MA, van der Heijde D, van der Linden S, Braun J: Age at disease onset and diagnosis delay in HLA-B27 negative vs. positive patients with ankylosing spondylitis. *Rheumatol Int* 23: 61–66, 2003
- 9) Maynard FM, Bracken MB, Creasey G, et al.: International standards for neurological and functional classification of spinal cord injury. American spinal injury association. *Spinal Cord* 35: 266–274, 1997
- 10) van der Linden S, Valkenburg HA, Cats A: Evaluation of diagnostic criteria for ankylosing spondylitis. A proposal for modification of the New York criteria. *Arthritis Rheum* 27: 361–368, 1984
- 11) Resnick D, Niwayama G: Radiographic and pathologic features of spinal involvement in diffuse idiopathic skeletal hyperostosis (DISH). *Radiology* 119: 559–568, 1976
- 12) Lukasiewicz AM, Bohl DD, Varthi AG, et al.: Spinal fracture in patients with ankylosing spondylitis: cohort definition, distribution of injuries, and hospital outcomes. *Spine* 41: 191–196, 2016
- 13) Peters MJ, van der Horst-Bruinsma IE, Dijkmans BA, Nurmohamed MT: Cardiovascular risk profile of patients with spondylarthropathies, particularly ankylosing spondylitis and psoriatic arthritis. *Semin Arthritis Rheum* 34: 585–592, 2004
- 14) Feltelius N, Hedenström H, Hillerdal G, Hällgren R: Pulmonary involvement in ankylosing spondylitis. *Ann Rheum Dis* 45: 736–740, 1986
- 15) Westerveld LA, Verlaan JJ, Oner FC: Spinal fractures in patients with ankylosing spinal disorders: a systematic review of the literature on treatment, neurological status and complications. *Eur Spine J* 18: 145–156, 2009
- 16) Harrop JS, Sharan A, Anderson G, et al.: Failure of standard imaging to detect a cervical fracture in a patient with ankylosing spondylitis. *Spine* 30: E417–E419, 2005

- 17) Magrey M, Khan MA: Osteoporosis in ankylosing spondylitis. *Curr Rheumatol Rep* 12: 332–336, 2010
- 18) Lu ML, Tsai TT, Lai PL, et al.: A retrospective study of treating thoracolumbar spine fractures in ankylosing spondylitis. *Eur J Orthop Surg Traumatol* 24 Suppl 1: S117–S123, 2014
- 19) Bessant R, Keat A: How should clinicians manage osteoporosis in ankylosing spondylitis? *J Rheumatol* 29: 1511–1519, 2002
- 20) Alaranta H, Luoto S, Konttinen YT: Traumatic spinal cord injury as a complication to ankylosing spondylitis. An extended report. *Clin Exp Rheumatol* 20: 66–68, 2002
- 21) Rose KA, Kim WS: The effect of chiropractic care for a 30-year-old male with advanced ankylosing spondylitis: a time series case report. *J Manipulative Physiol Ther* 26: E1–E9, 2003
- 22) Murray GC, Persellin RH: Cervical fracture complicating ankylosing spondylitis: a report of eight cases and review of the literature. *Am J Med* 70: 1033–1041, 1981

---

*Address reprint requests to:* Norihiro Isogai, MD, Spine and Spinal Cord Center, School of Medicine, International University of Health and Welfare, Mita Hospital, 1-4-3 Mita, Minato-ku, Tokyo 108-8329, Japan.  
*e-mail:* n.isogai@live.jp