

Lomitapide treatment in a female with homozygous familial hypercholesterolaemia: a case report

Karin Littmann ^{1,2}, Karolina Szummer³, Hannes Hagström ⁴,
Karoly Dolapcsiev ⁵, Jonas Brinck ^{6,7}, and Mats Eriksson^{6,7*}

¹Division of Clinical Chemistry, Department of Laboratory Medicine, Karolinska Institutet, Stockholm, Sweden; ²Department of Clinical Chemistry, Karolinska University Laboratory, Karolinska University Hospital, Stockholm, Sweden; ³Department of Medicine, Karolinska Institutet at Karolinska University Hospital Huddinge, Stockholm, Sweden; ⁴Division of Hepatology, Department of Upper GI, Karolinska University Hospital, Stockholm, Sweden; ⁵Department of Pathology, Karolinska University Laboratory, Karolinska University Hospital, Stockholm, Sweden; ⁶Metabolism Unit, Department of Medicine, Karolinska Institutet at Karolinska University Hospital Huddinge, Stockholm, Sweden; and ⁷Patient Area Endocrinology and Nephrology, Inflammation and Infection Theme, Karolinska University Hospital, Stockholm, Sweden

Received 27 June 2019; first decision 20 August 2019; accepted 20 January 2020; online publish-ahead-of-print 13 February 2020

Background

Homozygous familial hypercholesterolaemia (FH) is an autosomal-dominant inherited disease presenting with highly elevated low-density lipoprotein cholesterol (LDL-C) levels. Untreated, the patient can develop atherosclerosis and cardiovascular disease already in adolescence. Treatment with statins and ezetimibe is usually not sufficient and LDL apheresis is often required. Lomitapide, an inhibitor of the microsomal triglyceride transfer protein, reduces LDL-C and triglyceride levels and can be used alone or in combination with other therapies in homozygous FH. However, experience with this agent is still limited.

Case summary

We present a young female who was diagnosed with homozygous FH at 6 years of age. She shows a complete lack of normal LDL receptor activity and no cholesterol-lowering effect from statins. The patient was treated with LDL apheresis from 7 years of age. When LDL apheresis treatment extended to twice a week, she began to experience adverse effects, including catheter-related complications, infections, and hospital admissions. When lomitapide treatment was initiated, the frequency of apheresis reduced, the LDL-C levels improved and she has not had any further hospital admissions since. Initially, she suffered from gastrointestinal disturbances. However, after 3 years of treatment with lomitapide 20 mg/day, the patient has not experienced any adverse effects.

Discussion

In this female with homozygous FH adding lomitapide treatment to LDL apheresis has contributed to improved LDL-C levels, a reduction in LDL apheresis sessions and enhanced quality of life. No adverse effects have been reported. These findings suggest that lomitapide can be a drug of choice in patients with homozygous FH.

Keywords

Homozygous familial hypercholesterolaemia • Lomitapide • Case report • LDL apheresis • Hypercholesterolaemia treatment

Learning points

- Homozygous familial hypercholesterolaemia (FH) is a rare autosomal-dominant inherited disease presenting with highly elevated low-density lipoprotein cholesterol (LDL-C) levels.
- Frequent administration of LDL apheresis is often required to lower the LDL-C levels, and if untreated, the patient can develop atherosclerosis and cardiovascular disease already in adolescence.
- Lomitapide is an inhibitor of microsomal triglyceride transfer protein; its mechanism of action is to decrease plasma LDL-C and triglyceride levels. The drug is approved for the treatment of homozygous FH.

* Corresponding author. Tel: +46 8 58582362, Email: Mats.Eriksson@ki.se

Handling Editor: Timothy C. Tan

Peer-reviewers: Dejan Milasinovic, Elad Asher, and Riccardo Ligga

Compliance Editor: Rahul Mukherjee

Supplementary Material Editor: Vassilios Parisis Memtsas

© The Author(s) 2020. Published by Oxford University Press on behalf of the European Society of Cardiology.

This is an Open Access article distributed under the terms of the Creative Commons Attribution Non-Commercial License (<http://creativecommons.org/licenses/by-nc/4.0/>), which permits non-commercial re-use, distribution, and reproduction in any medium, provided the original work is properly cited. For commercial re-use, please contact journals.permissions@oup.com

Introduction

Familial hypercholesterolaemia (FH) is an autosomal-dominant inherited disease in which more than 2000 mutations located to the low-density lipoprotein (LDL) receptor, the apolipoprotein B, or proprotein convertase subtilisin kexin type 9 (PCSK9) protein, have been described. The prevalence of heterozygous FH ranges from 1:200 to 1:244, whereas homozygous FH is a very rare disease with a prevalence ranging from 1:160 000 to 1:300 000.¹ Patients with homozygous FH present with very high LDL cholesterol (LDL-C) levels, tendon xanthomas, and early clinical signs of atherosclerosis.^{1,2}

Cholesterol lowering with statins and PCSK9-inhibitors is dependent on LDL receptors. These treatments are often ineffective in patients with homozygous FH because of their low number of, or in rare cases, the complete absence of functioning LDL receptors.^{1–3} Other classes of lipid-lowering drugs (i.e. ezetimibe, fibrates or bile acid sequestrants) are rarely successful at reducing LDL-C levels; in this case, LDL apheresis may be used to lower LDL-C levels.^{1,4,5}

Lomitapide (Lojuxta[®]) is an inhibitor of the microsomal triglyceride transfer protein and reduces both LDL-C and triglyceride levels independently of LDL receptor function. Lomitapide is approved for treatment in patients with homozygous FH and has been reported to be effective in combination with other lipid-lowering therapies, although the experience of lomitapide treatment in these patients is still limited.^{6–11} Here, we describe the combined treatment of lomitapide and LDL apheresis in a young female with homozygous FH and a rare genotype resulting in the complete absence of functional LDL receptor activity.

Timeline

Date	Medical information, treatment, or investigation
1992	Patient born.
1998	Patient diagnosed with familial hypercholesterolaemia homozygous.
1999	Patient started treatment with low-density lipoprotein (LDL) apheresis once a week.
2013	Low-density lipoprotein apheresis treatment increased to twice a week.
2015 June	Patient referred to a cardiologist because of dyspnoea. Echocardiogram and stress echocardiography with normal findings.
2015 September	Patient urgently referred to a cardiologist because of chest pain. Angiography showed spasm of the distal left anterior descending artery with possible atheromatosis but no obstructive coronary artery disease. The other coronary arteries appear normal.
2015 September	Patient starts treatment with Lomitapide. Initial regimen of 5 mg/day; increased to 20 mg/day in December 2015. Before treatment start, magnetic resonance tomography of the liver showed mild hepatosteatosis.
2016	The number of LDL apheresis sessions decreased to once a week and then further decreased to every second week. The lomitapide dose varied between 20 and 30 mg/day during 2016.
2017 March	The lomitapide dose increased to 40 mg/day, while LDL apheresis continued every second week.
2018 June	The lomitapide dose decreased to 20 mg/day, while LDL apheresis continued every second week.

Case presentation

The patient is a female born in 1992 who was diagnosed with homozygous FH in 1998 at 6 years of age. At diagnosis, xanthomas were noted on the Achilles tendons and on the skin of one hand (Figure 1), total cholesterol was 20 mmol/L and LDL-C (calculated with Friedewald's formula) was 18.5 mmol/L. Carotid ultrasound showed increased intima-media thickness, whereas echocardiography and a stress echocardiography were normal. A homozygous mutation (W556R) was identified in the LDL receptor gene, resulting in less than 5% of normal LDL receptor activity in her cultured fibroblasts.^{12,13}

Treatment with atorvastatin and ezetimibe was initiated at diagnosis but terminated because there was no effect on cholesterol levels. At 7 years of age, the patient received weekly LDL apheresis treatment and, in combination with dietary intervention, her LDL-C levels went from 10–12 mmol/L before to 3–4 mmol/L after apheresis therapy. From 13 years of age, the frequency of LDL apheresis treatment had to be periodically increased and from 21 years of age, LDL apheresis was performed regularly twice a week.

During the biweekly LDL apheresis treatment, the patient encountered frequent complications from the dialysis catheter, with bleedings, repeated infections and septicaemia, resulting in several hospital admissions and catheter changes. Because of these complications, additional therapy was considered and in the autumn of 2015 treatment with lomitapide 5 mg/day was initiated. The dose was slowly escalated, alternating between 20 and 30 mg/day because of gastrointestinal symptoms (stomach pain, diarrhoea, and nausea). In 2017, the lomitapide dose was uptitrated from 20–30 mg to 40 mg/day and now well-tolerated, which was probably the result of better dietary habits. Because of limited financial support from the city council, the dose was again decreased to 20 mg/day in 2018 (Figure 2).

The initiation of lomitapide treatment rendered a reduction in the frequency of apheresis while still maintaining acceptable LDL-C levels

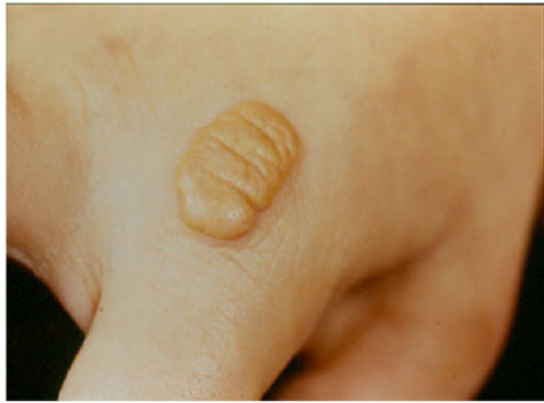

Figure 1 Xanthoma in the skin of one hand present at diagnosis.

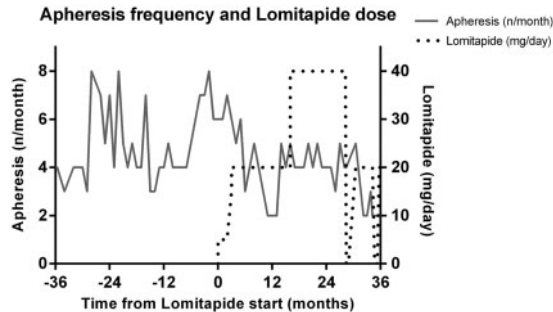


Figure 2 Frequency of apheresis treatment and lomitapide dose.

(Figure 3). Because of fewer apheresis treatments, infections and hospital admissions caused by catheter complications were eliminated. In 2016, the patient was temporarily without lomitapide for 2 months and the frequency of LDL apheresis therapy had to be increased to once a week during that period (Figure 2).

The presence of elevated transaminases, induced hepatic steatosis and the development of fibrosis have been reported as adverse effects of lomitapide treatment.^{3,14} In this patient, alanine transaminase and aspartate transaminase were slightly increased during the dose of 40 mg/day but almost normalized once the dose was decreased to 20 mg/day (Figure 4). A liver biopsy performed in 2009 showed mild fibrosis (Stage 1). The appearance of mild hepatic steatosis on magnetic resonance tomography was noted in 2015, just before lomitapide was initiated and, after 2 years of treatment, a new examination revealed slightly increased hepatic steatosis.

In June 2018, transient elastography, an ultrasound-based method using low-frequency elastic waves to estimate hepatic steatosis and liver fibrosis,¹⁵ was performed by an experienced investigator. At that time, the patient was on lomitapide 20 mg/day. The examination indicated a low grade of steatosis (controlled attenuation parameter 247 dB/m) but was suggestive of advanced fibrosis (19.3 kPa,

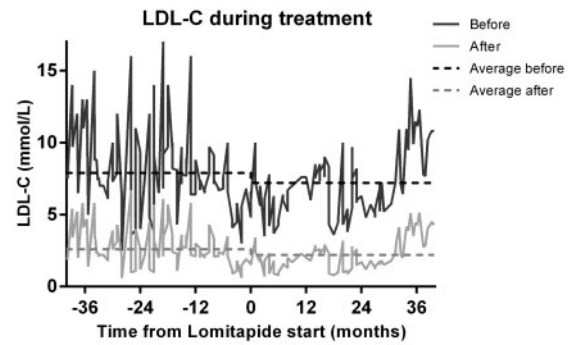


Figure 3 Low-density lipoprotein cholesterol levels during treatment. Low-density lipoprotein cholesterol levels before (black) and after (grey) low-density lipoprotein apheresis and calculated average Low-density lipoprotein cholesterol levels before and after apheresis 3 years before (7.9 mmol/L; 2.6 mmol/L) and 3 years from (7.2 mmol/L; 2.2 mmol/L) initiation of lomitapide treatment.

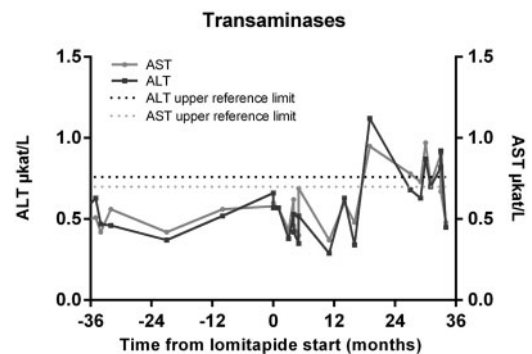


Figure 4 Monitoring of aspartate transaminase and alanine transaminase.

interquartile range 2.5 kPa, success rate 100%) and therefore a second liver biopsy was performed 3 months later. The biopsy showed low-grade microvesicular steatosis and fibrosis Stage 1 without inflammation or signs of steatohepatitis (Figure 5A and B), providing no evidence to support the notion that lomitapide had induced any serious adverse liver effects.

In 2015, the patient was investigated by a cardiologist because of periods of dyspnoea at exertion and bursts of chest pain. An echocardiogram revealed a tricuspid aortic valve with normal opening, mild scattered increased echogenicity, and mild to moderate central aortic insufficiency. During stress echocardiography, there were no segments with hypokinesia, although the apical segments had a late ventricular contraction pattern (tardokinesia). No obstructive coronary artery disease was present at a coronary angiography performed at the same time.

In 2018, a coronary computed tomography angiography was conducted for clinical evaluation and assessment before a possible pregnancy. Still, no obstructive coronary artery disease was present, but a

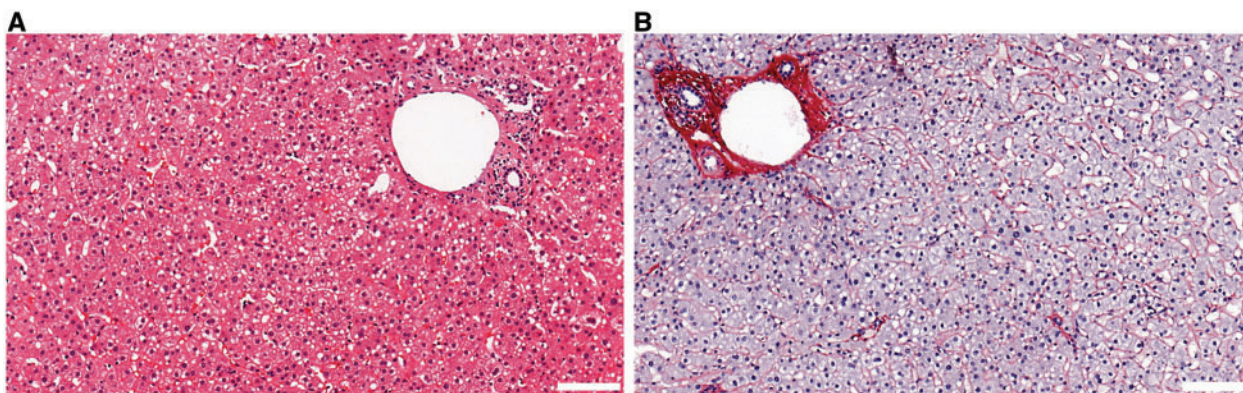


Figure 5 Liver biopsy performed in September 2018. (A) Haematoxylin and eosin-stained section (20 \times) showing mild to moderate microvesicular steatosis without inflammation (scale bar 100 μ m). (B) Sirius-stained section (20 \times) showing portal fibrosis and a discrete pericellular fibrosis consistent with fibrosis stage 1 (scale bar 100 μ m).

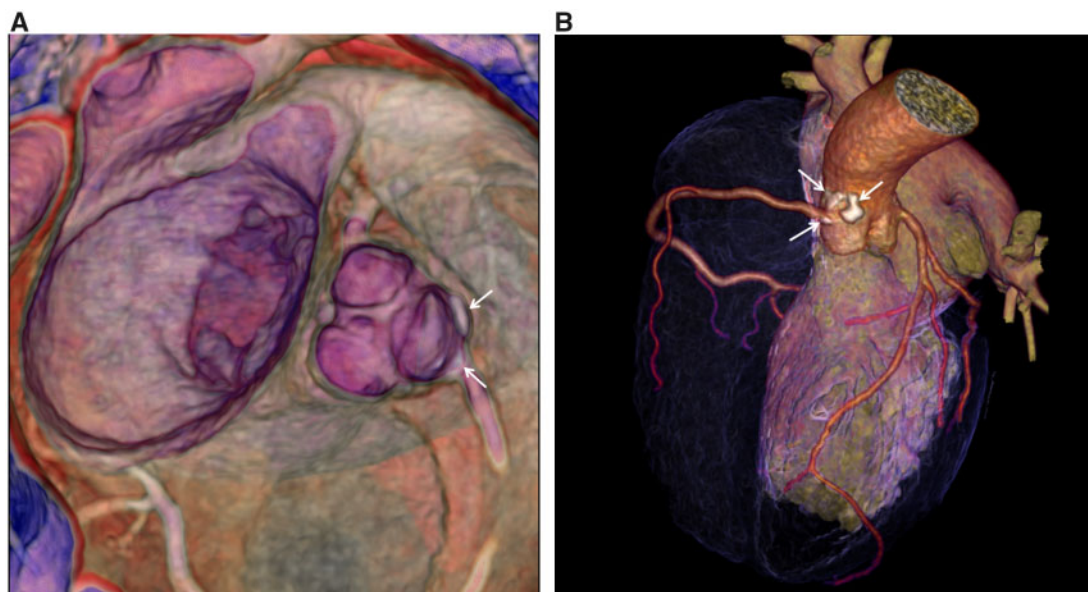


Figure 6 (A and B) Coronary computed tomography angiography. Coronary computer tomography angiography (January 2018) showing a calcified plaque ostially in the right coronary artery, indicated by arrows. Picture by Anders Svensson, Department of Radiology, Karolinska University Hospital, Stockholm, Sweden.

calcified plaque ostially in the right coronary artery and the thoracic aorta was noted (Figure 6A and B).

Since her diagnosis, the patient has been on a fat-restricted diet and has had normal growth and development. Her body mass index (BMI) just before lomitapide initiation was 28.2 kg/m²; after 2 years of treatment, her BMI was 26.9 kg/m². She is not participating in any regular physical activities, is not smoking and does not consume alcohol. Serum levels of alpha-tocopherol and retinol have been normal. Vitamin D deficiency occurred periodically and this condition was treated with supplements accordingly.

Discussion

The effect of lomitapide treatment in a young female with homozygous FH and a rare mutation resulting in no functional LDL receptor activity is presented in this case report. Before lomitapide treatment, the patient experienced frequent complications and emotional and social impairment from the biweekly LDL apheresis therapy. The lomitapide treatment reduced the frequency of LDL apheresis while still maintaining acceptable LDL-C levels. The patient had no serious risks or side effects of the new treatment. Moreover, hospital

admissions associated with side effects of frequent LDL apheresis were eliminated and her quality of life improved steadily. Finally, considering the diagnosis of homozygous FH, her cardiovascular status at the age of 26 years is surprisingly normal.


Hepatic adverse effects have been reported in patients treated with lomitapide. In our patient, no progression of low-grade fibrosis occurred during 9 years of follow-up, including 3 years with lomitapide treatment. We therefore conclude that lomitapide did not contribute to harmful liver side effects. However, the slight increase of hepatic steatosis observed in 2018 compared with the earlier examinations could be a result of lomitapide treatment, inappropriate dietary habits, or both. We also observed that the transient elastography falsely indicated an advanced fibrosis stage, which was contradicted by the liver biopsy. Consequently, the use of elastography in patients with homozygous FH must be further evaluated for use in clinical routine.

Lomitapide treatment (20 mg/day) costs approximately 200 000 Euros/year, which is equal to the cost of 1-year biweekly LDL apheresis treatment. When adding lomitapide, the frequency of LDL apheresis decreased to every second week and the total treatment cost increased approximately 25%. Considering the improved quality of life, reduced hospital admissions and complications, we believe there is a positive net effect for all actors: patients, the wider health-care system and society.

Patient perspective

Lomitapide treatment has been successful in this young woman with homozygous FH and a complete lack of functional LDL receptor activity, resulting in a reduction in LDL apheresis sessions, enhanced quality of life with few adverse events, good cardiovascular status and without clinically relevant liver side effects. Taken all together, Lomitapide might be considered as a drug of choice for patients with homozygous FH.

Lead author biography



Karin Littmann is a MD and PhD student. She work as a specialist in Clinical Chemistry at the Karolinska University Laboratory and part time in the outpatient clinic for patients with dyslipidaemias at the Endocrinology Unit, Karolinska University Hospital, Sweden. She is also a PhD student at the Department of Laboratory Medicine, Karolinska Institute, and her PhD project are focused on biomarkers for cardiometabolic diseases.

Supplementary material

Supplementary material is available at *European Heart Journal - Case Reports* online.

Slide sets: A fully edited slide set detailing this case and suitable for local presentation is available online as [Supplementary data](#).

Consent: The author/s confirm that written consent for submission and publication of this case report including image(s) and associated text has been obtained from the patient in line with COPE guidance.

Conflict of interest: K.S.: Vifor lecture fee. H.H.: independent research grant from Gilead Sciences Inc. Consulting for Novo Nordisk, Intercept and Gilead Sciences Inc. None of these are relevant to the current study. J.B.: independent research grant from Amgen. Advisory board member for Akcea Pharmaceuticals. None of these are relevant to the current study. M.E.: independent research grant from Amgen. Advisory board member for Sanofi and Amgen. None of these are relevant to the current study. All other authors have declared no conflict of interest.

References

- Cuchel M, Bruckert E, Ginsberg HN, Raal FJ, Santos RD, Hegele RA, Kuivenhoven JA, Nordestgaard BG, Descamps OS, Steinhausen-Thiessen E, Tybjaerg-Hansen A, Watts GF, Averna M, Boileau C, Boren J, Catapano AL, Defesche JC, Hovingh GK, Humphries SE, Kovanen PT, Masana L, Pajukanta P, Parhofer KG, Ray KK, Stalenhoef AFH, Stroes E, Taskinen M-R, Wiegman A, Wiklund O, Chapman MJ; European Atherosclerosis Society Consensus Panel on Familial Hypercholesterolaemia. Homozygous familial hypercholesterolaemia: new insights and guidance for clinicians to improve detection and clinical management. A position paper from the Consensus Panel on Familial Hypercholesterolaemia of the European Atherosclerosis Society. *Eur Heart J* 2014;**35**:2146–2157.
- Nordestgaard BG, Chapman MJ, Humphries SE, Ginsberg HN, Masana L, Descamps OS, Wiklund O, Hegele RA, Raal FJ, Defesche JC, Wiegman A, Santos RD, Watts GF, Parhofer KG, Hovingh GK, Kovanen PT, Boileau C, Averna M, Boren J, Bruckert E, Catapano AL, Kuivenhoven JA, Pajukanta P, Ray K, Stalenhoef AFH, Stroes E, Taskinen M-R, Tybjaerg-Hansen A; European Atherosclerosis Society Consensus Panel. Familial hypercholesterolaemia is underdiagnosed and undertreated in the general population: guidance for clinicians to prevent coronary heart disease: consensus statement of the European Atherosclerosis Society. *Eur Heart J* 2013;**34**:3478–3490a.
- Panno MD, Cefalu AB, Averna MR. Lomitapide: a novel drug for homozygous familial hypercholesterolemia. *Clin Lipidol* 2014;**9**:19–32.
- Thompson GR. Recommendations for the use of LDL apheresis. *Atherosclerosis* 2008;**198**:247–255.
- Schuff-Werner P, Fenger S, Kohlschein P. Role of lipid apheresis in changing times. *Clin Res Cardiol Suppl* 2012;**7**:7–14.
- D'Erasmo L, Cefalu AB, Noto D, Giammanco A, Averna M, Pintus P, Medda P, Vigna GB, Sirtori C, Calabresi L, Pavanello C, Bucci M, Sabbà C, Suppressa P, Natale F, Calabrò P, Sampietro T, Bigazzi F, Sbrana F, Bonomo K, Sileo F, Arca M. Efficacy of lomitapide in the treatment of familial homozygous hypercholesterolemia: results of a real-world clinical experience in Italy. *Adv Ther* 2017;**34**:1200–1210.
- Roeters van Lennep J, Averna M, Alonso R. Treating homozygous familial hypercholesterolemia in a real-world setting: experiences with lomitapide. *J Clin Lipidol* 2015;**9**:607–617.
- Stefanutti C, Morozzi C, Di Giacomo S, Sovrano B, Mesce D, Grossi A. Management of homozygous familial hypercholesterolemia in real-world clinical practice: a report of 7 Italian patients treated in Rome with lomitapide and lipoprotein apheresis. *J Clin Lipidol* 2016;**10**:782–789.
- Blom DJ, Averna MR, Meagher EA, Du Toit Theron H, Sirtori CR, Hegele RA, Shah PK, Gaudet D, Stefanutti C, Vigna GB, Larrey D, Bloedon LT, Foulds P, Rader DJ, Cuchel M. Long-term efficacy and safety of the microsomal triglyceride transfer protein inhibitor lomitapide in patients with homozygous familial hypercholesterolemia. *Circulation* 2017;**136**:332–335.
- Kolovou GD, Kolovou V, Papadopoulou A, Watts GF. MTP gene variants and response to lomitapide in patients with homozygous familial hypercholesterolemia. *J Atheroscler Thromb* 2016;**23**:878–883.
- deGoma EM. Lomitapide for the management of homozygous familial hypercholesterolemia. *Rev Cardiovasc Med* 2014;**15**:109–118.
- Eriksson M, Berglund L, Rudling M, Henriksson P, Angelin B. Effects of estrogen on low density lipoprotein metabolism in males. Short-term and long-term

- studies during hormonal treatment of prostatic carcinoma. *J Clin Invest* 1989;**84**: 802–810.
13. Lind S, Rudling M, Ericsson S, Olivecrona H, Eriksson M, Borgström B, Eggertsen G, Berglund L, Angelin B. Growth hormone induces low-density lipoprotein clearance but not bile acid synthesis in humans. *Arterioscler Thromb Vasc Biol* 2004;**24**:349–356.
14. Liu X, Men P, Wang Y, Zhai S, Zhao Z, Liu G. Efficacy and safety of lomitapide in hypercholesterolemia. *Am J Cardiovasc Drugs* 2017;**17**:299–309.
15. Sandrin L, Fourquet B, Hasquenoph J-M, Yon S, Fournier C, Mal F, Christidis C, Ziol M, Poulet B, Kazemi F, Beaugrand M, Palau R. Transient elastography: a new noninvasive method for assessment of hepatic fibrosis. *Ultrasound Med Biol* 2003;**29**:1705–1713.