

Research article

Open Access

Vascular mechanism of axonal degeneration in peripheral nerves in hemiplegic sides after cerebral hemorrhage: An experimental study

Cemal Gundogdu¹, Memet Dumlu Aydin*², Dilcan Kotan³, Nazan Aydin⁴, Ednan Bayram⁵, Hızır Ulvi³ and Recep Aygul³

Address: ¹Department of Pathology, Medical Faculty, Ataturk University, Erzurum, Turkey, ²Department of Neurosurgery, Medical Faculty, Ataturk University, Erzurum, Turkey, ³Department of Neurology, Medical Faculty, Ataturk University, Erzurum, Turkey, ⁴Department of Psychiatry, Medical Faculty, Ataturk University, Erzurum, Turkey and ⁵Cardiology Clinic of Erzurum State Hospital, Erzurum, Turkey

Email: Cemal Gundogdu - cemal@yahoo.com; Memet Dumlu Aydin* - nmda11@hotmail.com; Dilcan Kotan - diltankotan@yahoo.com; Nazan Aydin - naydin@atauni.edu.tr; Ednan Bayram - ednan1679@hotmail.com; Hızır Ulvi - hizir@yahoo.com; Recep Aygul - raygul@atauni.edu.tr

* Corresponding author

Published: 28 April 2008

Received: 5 December 2007

Journal of Brachial Plexus and Peripheral Nerve Injury 2008, **3**:13 doi:10.1186/1749-7221-3-13

Accepted: 28 April 2008

This article is available from: <http://www.jbppni.com/content/3/1/13>

© 2008 Gundogdu et al; licensee BioMed Central Ltd.

This is an Open Access article distributed under the terms of the Creative Commons Attribution License (<http://creativecommons.org/licenses/by/2.0>), which permits unrestricted use, distribution, and reproduction in any medium, provided the original work is properly cited.

Abstract

Background: Though retrograde neuronal death and vascular insufficiency have been well established in plegics following intracerebral hemorrhage, the effects of plegia on arterial nervorums of peripheral nerves have not been reported. In this study, the histopathological effects of the intracerebral hemorrhage on the dorsal root ganglions and sciatic nerves via affecting the arterial nervorums were investigated.

Methods: This study was conducted on 13 male hybrid rabbits. Three animals were taken as control group and did not undergo surgery. The remaining 10 subjects were anesthetized and were injected with 0.50 ml of autologous blood into their right sensory-motor region. All rabbits were followed-up for two months and then sacrificed. Endothelial cell numbers and volume values were estimated a three dimensionally created standardized arterial nervorums model of lumbar 3. Neuron numbers of dorsal root ganglions, and axon numbers in the lumbar 3 nerve root and volume values of arterial nervorums were examined histopathologically. The results were analyzed by using a Mann-Whitney-U test.

Results: Left hemiplegia developed in 8 animals. On the hemiplegic side, degenerative vascular changes and volume reduction in the arterial nervorums of the sciatic nerves, neuronal injury in the dorsal root ganglions, and axonal injury in the lumbar 3 were detected. Statistical analyses showed a significant correlation between the normal or nonplegic sides and plegic sides in terms of the neurodegeneration in the dorsal root ganglions ($p < 0.005$), axonal degeneration in the lumbar 3 nerve roots ($p < 0.005$), endothelial cell degeneration in the arterial nervorums ($p < 0.001$), and volume reduction in the arterial nervorums ($p < 0.001$).

Conclusion: Intracerebral hemorrhage resulted in neurodegeneration in the dorsal root ganglion and axonolysis in the sciatic nerves, endothelial injury, and volume reduction of the arterial nervorums in the sciatic nerves. The interruption of the neural network connection in the walls of

the arterial nervorums in the sciatic nerves may be responsible for circulation disorders of the arterial nervorums, and arterial nervorums degeneration could result in sciatic nerves injury.

Introduction

The peripheral nerves are supplied by arterial nervorums (ANs) and innervated by neural networks localized in the perivascular spaces. ANs are connected to each other with many anastomoses [8,9]. Autoregulation of nerve blood flow of peripheral nerves (PNs) is impaired and results in hypotension in the plegic side [10-12]. Decreased blood flow in ANs may result in degeneration of nerve fibers and loose of the myelin sheath [13]. Spinal cord injury results in impaired vascular control and circulation disorders at the extremities [2]. Nerve, muscle, and vascular atrophy are even possible after spinal cord injury [3,4]. Disordered central and spinal autonomic reflexes seem to play an important role in PN injury and polyneuropathy [5-7]. The diameters and blood flow velocity of the femoral arteries are significantly reduced in the paralytic site [1]. The femoral arteries are innervated by the L₁₋₆ segments of the spinal nerves in animals [14]. Intracerebral hemorrhage (ICH) causes descending neurodegeneration from the cortex to the dorsal root ganglion (DRG) [15]. Then, ICH causes destruction of the reflex arches of the ANs due to neurodegeneration in the DRG of L₁₋₆. Although PNs injury has been reported as a cause of power loss at the involved muscles, injury to the feeding vessels of the PNs has not been investigated in hemiplegic subjects after cerebral hemorrhage. In this study, we aimed to prove that the hemiplegia due to ICH results in histopathological changes in the ANs of the PNs.

Materials and methods

In the present study were included 13 male hybrid rabbits. Animals were 2 years old and weighed approximately 4 kg each. Animal experimentation was carried out according to the guidelines set by the ethical committee of our university. All animals were anaesthetized by subcutaneous injection of a mixture of ketamine hydrochloride (25 mg/kg), lidocaine hydrochloride (15 mg/kg), and acepromazine (1 mg/kg). After preparation of the operative site, a left parietal burr-hole of 3 mm diameter was created, and 0.25 cc venous blood from the same animal was injected into the right sensory-motor cortex. After the operation, the fascia and skin were sutured by 4.0 absorbable suture material. The rabbits were followed in their personal cages and given antibiotic (cefotaxime 125 mg/BID) and analgesic (methamisozol sodium 10 mg/kg) therapy for six days postoperatively. One month later, all animals were sacrificed, and their lumbar 3 (L₃) nerve roots were removed bilaterally. For light microscopic analysis, these specimens were preserved in 10% formalin solution. These specimens were embedded in paraffin blocks, and

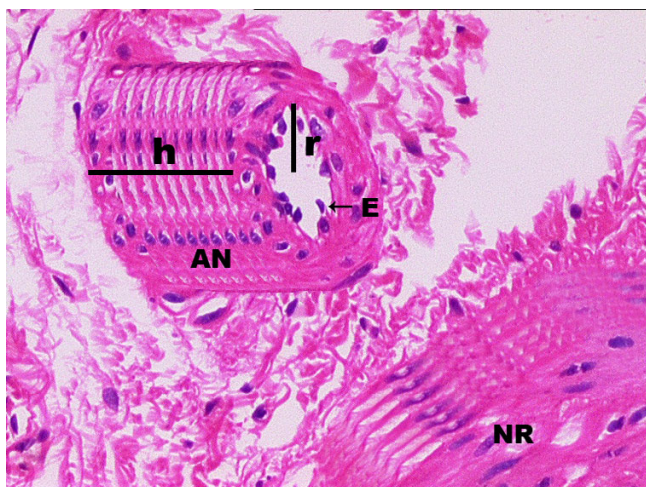
sections were stained with hematoxyline and eosin. ANs and L₃ roots were evaluated. The numbers of the normal and degenerated axons were determined, and the ANs were evaluated in all roots. Axonal degeneration criteria were defined as axonolysis or axonal loss, periaxonal halo formation, and Schwann cell necrosis. AN degeneration criteria were defined as endothelial cell shrinkage, angulation, cell necrosis or loss, muscular thinning, and intimal edema. The Cavalieri volume estimation method was used to obtain the total number of axons in each nerve root (NR). The total number of axons was estimated by multiplication of the volume (sample item area) and the numerical density of neurons in each L₃ NR. The statistical comparison was performed between the paraplegic and contralateral side roots at the L₃ level.

In histopathological examination, cytoplasmic condensation, cellular shrinking, cellular angulations secondary to cytoplasmic regression, endothelial cell loss, was accepted as the both endothelial and neuronal degeneration criteria. Also axonolysis, axonal loss, periaxonal halo formation and myelin loss were accepted as the axonal degeneration criteria. All of the degenerative findings were more prominent on the plegic side than on the non-plegic side.

Endothelial cell were arranged in the surface of the inner cavity of cylindrical. Endothelial cells arranged plane originally is a rectangle which forming inner surface of the cylindrical inner cavity of ANs. The borders long of the reference cylinder are given by $2 \pi r$ and h . Thus, the surface area of the reference plane is calculated by the following equation: $S = 2 \pi r \times h$. In the same way, the number of endothelial cells was estimated in each reference plane and accepted as the endothelial cells density (Figure 1). To calculate the volumetric changes of the ANs due to vasospasm or vasodilatating factors, a three-dimensional cylindrical AN model was created by the reconstruction of seven consecutive histological sections of each ANs (Figure 1). In the AN model, the luminal radius is represented by 'r', and the height is represented by 'h'. Geometrical volume calculation methods were used in the reconstructed cylindrical ANs sample. The standardized ANs volume was calculated with the following formula:

$$V = \pi r^2 h$$

Statistical analysis was performed using a nonparametric Mann Whitney-U Test.

**Figure 1**

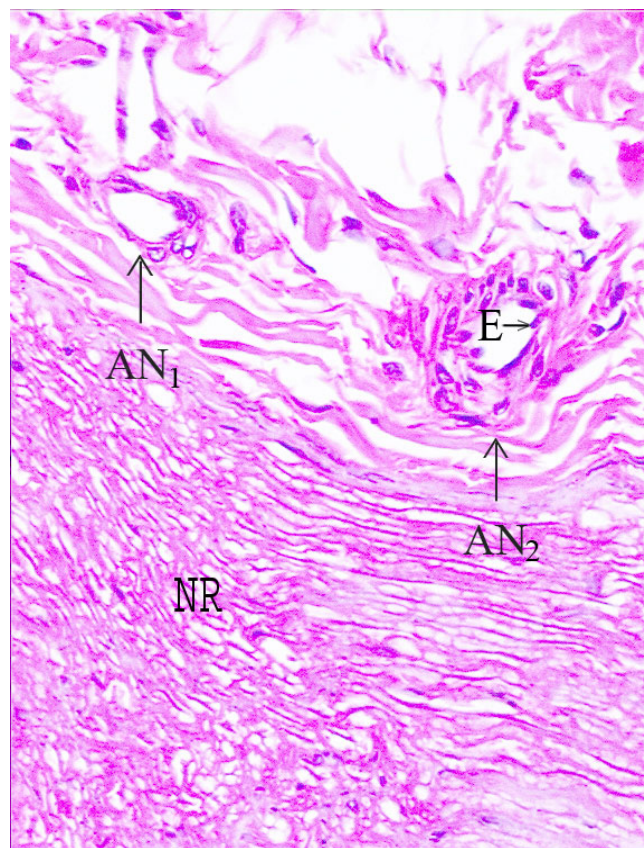
A nerve root and its supplying artery of a normal rabbit are represented, which were reconstructed three dimensionally by using consecutive sections of the same artery specimen. The reconstructed artery is accepted as a cylinder, and its surface area is calculated as: $S = 2\pi rh$; the endothelial cell density was calculated in a part of ANs. Volumetric changes of the ANs were calculated as the volume of the cylinder-shaped artery by the following formula: $V = \pi r^2 h$. Vascular luminal changes of the arteries were calculated by using volume changes of the ANs instead of changes in vessel diameter.

Results

Left hemiplegia developed in eight animals. The histological appearance of the normal rabbit NR and ANs is shown in Figure 2. Figure 3 shows a histopathological representation of an NR and AN on the nonplegic side, and Figure 4 shows a NR and AN on the plegic side.

The total number of normal axons of the L3 anterior root was estimated as $20,000 \pm 1500$ in normal animals ($N = 3$). The number of normal axons of L3 was $19,700 \pm 1000$ on the non-hemiplegic side and $13,000 \pm 700$ on the plegic side. Degenerated neuron numbers were estimated as 30 ± 5 in normal subjects, 200 ± 50 on the nonplegic side, and 7000 ± 500 on the plegic side. The difference in axonal degeneration between the normal and nonplegic sides was not statistically significant ($p < 0.05$), but the difference between the nonplegic and plegic sides was significant ($p < 0.005$). The difference between the plegic and normal sides was also significant ($p < 0.001$).

The endothelial cell density of the ANs was about 280 ± 20 cells/item area in normal animals. The endothelial cell density of the ANs was 260 ± 15 cells/item area on the nonplegic side of experimental animals and 150 ± 30 cells/item area on the plegic side. The difference between the normal and nonplegic sides was not significant ($p <$

**Figure 2**

Normal appearance of a nerve root and epineural arteries at the level of L₃ (H&E, $\times 100$, LM). (AN_{1,2}: Arterial nervorum, NR: Nerve Root, E: Endothel) (H&E, $\times 100$, LM).

0.5), but the difference between the plegic and nonplegic sides was significant ($p < 0.005$). The difference between the plegic and normal sides was also statistically significant ($p < 0.0001$). The volume of an imaginary AN was found to be 1000 item volume in normal animals, 900 item volume on the nonplegic side and 600 item volume on the plegic side. The difference in volume reduction of the AN was significant between the hemiplegic sides and the normal or non-plegic sides ($p < 0.001$).

Table 1 shows the average number of normal and degenerated axons, neurons of dorsal root ganglions (DRGs), endothelial cell numbers, and volumetric changes of the AN sample in each groups. Plegia caused endothelial cell necrosis, neuronal and axonal degeneration in the DRG and sciatic nerves (SNs), and volume reduction in the AN on the plegic sides.

Discussion

The peripheral nerves are supplied by ANs and innervated by neural networks longitudinally localised in the

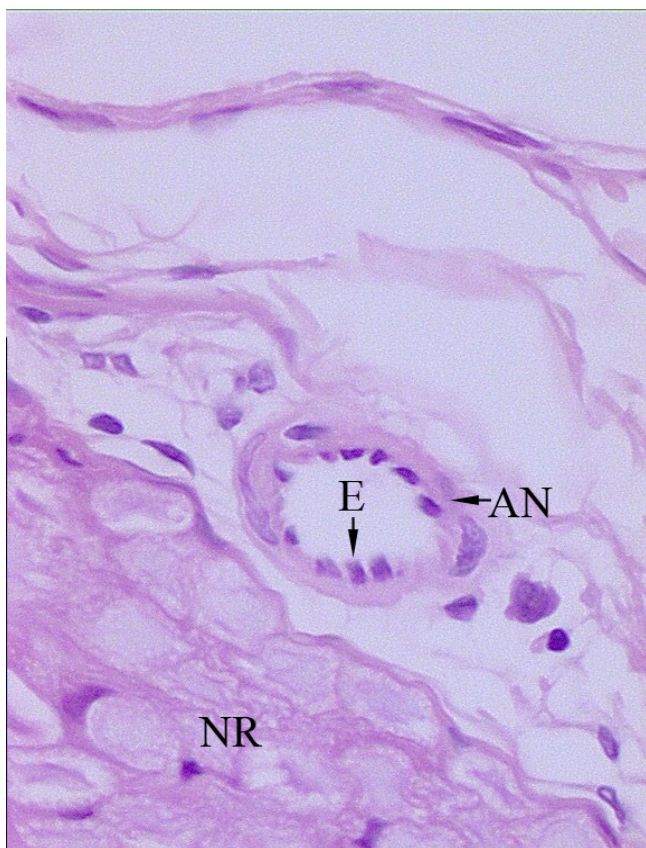


Figure 3
 Appearance of a nerve root (NR), arterial nervorum (AN), and endothelial cells of the ANs (E) at the L₃ level on the non-plegic side. Minimally endothelial swelling, cellular loss, and axonal injury are observed (H&E, ×200, LM).

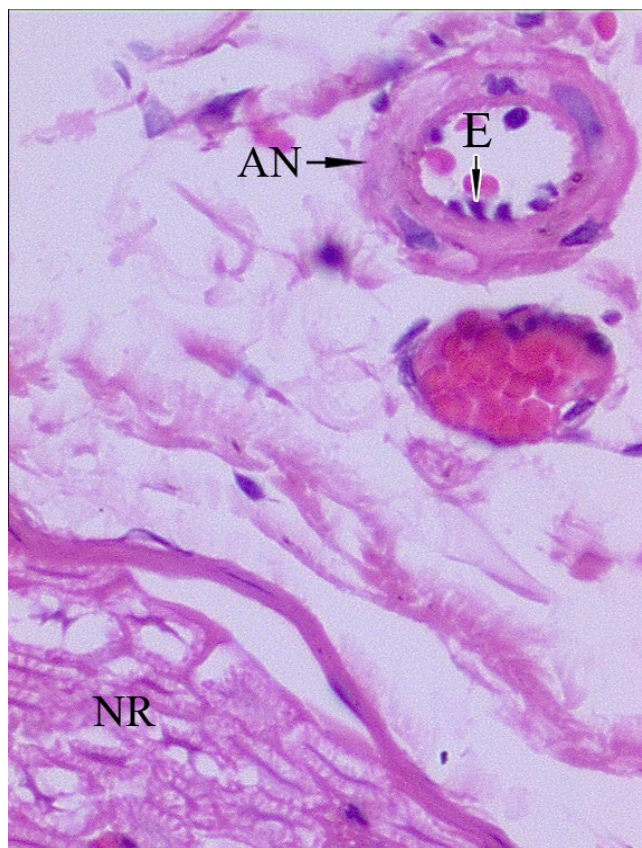


Figure 4
 Appearance of a nerve root (NR), arterial nervorum (AN), and endothelial cells of the ANs (E) at the L₃ level on the non-plegic side. Endothelial shrinkage, angulation, and cellular loss are seen in ANs of the nerve root at the level of L₆ on the plegic side (H&E, ×100, LM). Degenerated axons, myelin sheath derangements, and axonal loss are seen on the plegic side (H&E, ×200, LM).

endoneurium, perineurium, and epineurium. ANs are connected to each other and form many anastomoses in the subepineurial spaces [8,9]. Epineurial vessels contain smooth muscle, have large diameters, and are innervated by somatosensitive and autonomic plexuses of unmyelinated nerve endings [6,18,20,24,25]. Endoneurial vessels, however, have no smooth muscle and neural innervation, and the endoneurial blood flow is under the influence of vasoactive substances [6,16-23]. The density of the nerve axons decreases gradually from the epineurium to the endoneurium [18,20]. A degenerated perivascular plexus may result in disordered regulation of the PNs blood flow and result in PNs damage [31].

The diameters and blood flow velocities of the common femoral arteries decrease significantly secondary to inactivity of the paralytic state, and this process is largely completed within weeks [1]. Spinal cord injury results in impaired vascular control, circulation disorders, and muscle atrophy [2,3]. Transient spinal cord ischemia causes

degenerative changes in the motor and mixed PNs, with partial or total plegia [4]. Disordered centropinal sympathetic veno-arteriolar or myogenic reflexes play an important role in the development of PNs injuries [5].

Impaired innervation of blood vessels of PNs in patients with diabetes mellitus has been associated with the development of detrimental peripheral arterial disease [6,7]. Unfortunately, autoregulation of ANs can be corrupted and nerve blood flow can be reduced during hypotension in plegic conditions [10-12]. Decreased blood flow in PNs may result in degeneration of nerve fibers and loss of the myelin sheath. Also, neuropathic features are triggered in relation to the severity of ischemia in patients with peripheral arterial disease. Decreased innervation of ANs could lead to a disturbed oxygenation of the PNs and development of neuropathy [13].

Table 1: The total number of normal and degenerated axons of L₃ roots, the number of neurons in the DRGs, the volume values, and the number of endothelial cells of AN samples are given.

| | Normal animals | Non-plegic side | Plegic side |
|--|----------------|-----------------|----------------|
| Number of normal neurons of a DRG | 20.000 ± 100 | 19.700 ± 100 | 13.000 ± 7.300 |
| Degenerated neuron numbers of a DRG | 30 ± 5 | 200 ± 50 | 7500 ± 500 |
| Normal axon numbers of an L₃ | 6.000 ± 300 | 4.700 ± 200 | 3.150 ± 150 |
| Degenerated axon numbers of an L₃ | 20 ± 5 | 1200 ± 50 | 2500 ± 200 |
| Number of endothelial cells of a normal AN (Cell/item area) | 280 ± 20 | 260 ± 15 | 150 ± 30 |
| Number of degenerated endothelial cells of ANs (Cell/item area) | 10 ± 3 | 20 ± 5 | 120 ± 10 |
| Volume values of a standart part of an AN (item volume). | 1000 | 900 | 600 |

The differences in the number of degenerated axons between the normal and non plegic groups were not statistically significant ($p < 0.05$). In contrast, the differences between the non-plegic and plegic groups were significant ($p < 0.005$), but the differences between the normal and plegic groups were most significant ($p < 0.0001$). As for the endothelial cells of ANs, the difference between the normal and nonplegic side was not significant ($p < 0.5$), and the difference between the plegic and nonplegic side was significant ($p < 0.005$). The differences between the plegic side and normal groups, however, were most significant ($p < 0.0001$).

The existence of circulatory disturbances [26] and large myelinated fiber loss in the nerve roots of plegics is well established [27]. In such cases, neuronal death begins within the first day and mostly progresses within the first 2 months, and cell death is limited up to 6 months [28]. Severely damaged neurons and axons in PNs have also been observed in complicated cerebro-spinal traumas [29]. Neuronal degeneration of the PNs has been reported in autopsy studies of patients with perinatal hemorrhagic telencephalic necrosis [30]. Hemorrhagic lesions of the sensory motor cortex commonly cause power loss at the involved muscles, but feeding vessels of PNs has not been reported in plegic subjects.

It has been reported that brain or spinal cord injuries cause neuronal degeneration in spine ganglia and axonal degeneration in PNs by the mechanism of proximal axotomy [29]. Seven days after cerebral or spinal cord injuries, 24% of the dorsal root ganglion neurons were lost, and 54% were lost 28 days after axotomy [32]. The physical proximity of the lesion to the cell body is a critical factor for the development of PNs injury [33]. The microscopic and ultra-structural changes indicate that there are typical morphological changes similar to those of apoptosis, including condensed basophilic nuclei, formation of nuclear caps, cell shrinkage, and apoptotic body formation following sciatic nerve axotomy [34]. In degenerative disease of the brain and spinal cord, myelin loss with segmental demyelination and axonal degeneration has been observed in sensory and motor fibers of PNs [35].

In this study, we aimed to prove whether hemiplegia due to ICH may result in histopathological changes in ANs. It is not known whether the disordered blood flow of ANs causes neuronal degeneration in PNs after ICH. For this reason, we investigated the histomorphological changes of axons of the spinal nerve roots (NRs) on each side of normal rabbits. In our experiment, the centrally axot-

omised PNs model was created through intracranial hemorrhage as described by Taushev [29]. It has been shown previously that circulation disorders of ANs may result in PNs degeneration [13] and that ICH causing hemiplegia results in descendent degeneration from cortex to DRG [15]. Because the femoral arteries are innervated by the L₁₋₆ segments of the SNs [14], the hemiplegic condition may affect the neural innervation of the femoral arteries.

To estimate the number of normal or degenerated neurons in each DRGs and PNs, we used stereological methods described in previous studies [15,36-38]. In our study, intracerebral hemorrhage may have caused the destructions of reflex arches of ANs via its degenerative effects on the DRGs of L₁₋₆. Descending neurodegeneration of sensitive reflex pathways of ANs in SNs may be destroyed, and circulation disorders of ANs in SNs may be inevitable. Eventually, decreased blood flow in the ANs may result in degenerative changes in nerve fibers of SNs.

According to our experiments, ICH resulted in neurodegeneration and axonolysis in PNs, vascular injury, and volume reduction of the ANs. The interruption of the neural networks in the walls of the ANs may be responsible for circulation disorders of the ANs. Consequently, ANs degeneration could result in PNs injury.

In summary; by creating a centrally axotomised model through a hemorrhagic sensory-motor cortex lesion, endothelial cell injury, neuronal and axonal degeneration may occur in the PNs on the plegic sides. In the aetiology of PNs degeneration in plegic sides after intracerebral hemorrhage ANs injuries should be considered as an important factor.

Authors' contributions

MDA the pathological processes. MDA, NA, DK performed experiment procedure and surgery. CG evaluated

histopathology. HU and RA conducted clinical evaluation and interpreted results. EB explain peripheral vascular function All authors read and approved the final manuscript.

References

- De Groot PC, Van Kuppevelt DH, Pons C, Snoek G, Woude LH Van Der, Hopman MT: **Time course of arterial vascular adaptations to inactivity and paralysis in humans.** *Med Sci Sports Exerc* 2003, **35**:1977-85.
- Olive JL, McCully KK, Dudley GA: **Blood flow response in individuals with incomplete spinal cord injuries.** *Spinal Cord* 2002, **40**:639-45.
- Olive JL, Dudley GA: **Vascular remodeling after spinal cord injury.** *Med Sci Sports Exerc* 2003, **35**:901-7.
- Lackova M, Schreiberova A, Kolesar D, Lukacova N, Marsala J: **Moderately Different NADPH-Diaphorase Positivity in the Selected Peripheral Nerves after Ischemia/Reperfusion Injury of the Spinal Cord in Rabbit.** *Cell Mol Neurobiol* 2006, **26**:1309-23.
- Groothuis JT, Boot CR, Houtman S, van Langen H, Hopman MT: **Does peripheral nerve degeneration affect circulatory responses to head-up tilt in spinal cord-injured individuals?** *Clin Auton Res* 2005, **15**:99-106.
- Beggs J, Johnson PC, Olafsen A, Watkins CJ, Cleary C: **Transperineurial arterioles in human sural nerve.** *J Neuropathol Exp Neurol* 1991, **50**:704-18.
- Lincoln J, Milner P, Appenzeller O, Burnstock G, Qualls C: **Innervation of normal human sural and optic nerves by noradrenaline- and peptide-containing nervi vasorum and.** *Brain Res* 1993, **632**:48-56.
- Low PA, Lagerlund TD, Mc Manis PG: **Nerve blood flow and oxygen delivery in normal, diabetic, and ischemic neuropathy.** *Int Rev Neurobiol* 1989, **31**:355-438.
- Lundborg G: **Structure and function of the intraneural microvessels as related to trauma, edema formation, and nerve function.** *J Bone Joint Surg* 1975, **57**:938-48.
- Low PA, Tuck RR: **Effects of changes of blood pressure, respiratory acidosis and hypoxia on blood flow in the sciatic nerve of the rat.** *J Physiol Lond* 1984, **347**:513-24.
- Smith DR, Kobrine AI, Rizzoli HV: **Absence of autoregulation in peripheral nerve blood flow.** *J Neurol Sci* 1977, **33**:347-52.
- Sundqvist T, Oberg PA, Rapoport SI: **Blood flow in rat sciatic nerve during hypotension.** *Exp Neurol* 1985, **90**:138-43.
- Rodriguez Sanchez C, Medina Sanchez M, Malik RA, Ah See AK, Sharma AK: **Morphological abnormalities in the sural nerve from patients with peripheral vascular disease.** *Histol Histopathol* 1991, **6**:63-71.
- Ishikawa H, Honda T, Toriyama K, Torii S, Sugiura Y: **Origin and course of nerves immunoreactive for calcitonin gene-related peptide surrounding the femoral artery in rat.** *Anat Embryol* 2003, **207**:299-305.
- Aydin MD, Erdoğan AR, Cevli SC, Gundogdu C, Dane S, Diyarbakırlı S: **Ganglionic mechanism of spasticity and ileus in cerebral hemorrhage: An experimental study.** *Int J Dev Neurosci* 2006, **24**(7):455-9.
- Bell MA, Weddell AG: **A descriptive study of the blood vessels of the sciatic nerve in the rat, man and other mammals.** *Brain* 1984, **107**:871-98.
- Bell MA, Weddell AG: **A morphometric study of intrafascicular vessels of mammalian sciatic nerve.** *Muscle Nerve* 1993, **7**:524-34.
- Johnson PC, Beggs JL: **Pathology of the autonomic nerve innervating the vasa nervorum in diabetic neuropathy.** *Diabet Med* 1993, **10**:56-61.
- Kihara M, Low PA: **Regulation of rat nerve blood flow: role of epineurial α -receptors.** *J Physiol* 1990, **422**:145-52.
- Rechthand E, Hervonen A, Sato S, Rapoport SI: **Distribution of adrenergic innervation of blood vessels in peripheral nerve.** *Brain Res* 1986, **374**:185-9.
- Schaafsma L, Sun H, Zochodne D: **Exogenous opioids influence the microcirculation of injured peripheral nerves.** *Am J Physiol* 1997, **272**:H76-H82.
- Zochodne DW, Ho LT: **Influence of perivascular peptides on endoneurial blood flow and microvascular resistance in the sciatic nerve of the rat.** *J Physiol* 1991, **444**:615-30.
- Zochodne DW, Low PA: **Adrenergic control of nerve blood flow.** *Exp Neurol* 1990, **109**:300-7.
- Appenzeller O, Dhital K, Cowen T, Burnstock G: **The nerves to blood vessels supplying blood to nerves: The innervation vasa nervorum.** *Brain Res* 1984, **304**:383-6.
- Dhital K, Lincoln J, Appenzeller O, Burnstock G: **Adrenergic innervation of vasa and nervi nervorum of optic, sciatic, vagus and sympathetic nerve trunks in normal and streptozotocin-diabetic rats.** *Brain Res* 1986, **367**:39-44.
- Ma J, Novikov LN, Wiberg M, Kellerth JO: **Delayed loss of spinal motoneurons after peripheral nerve injury in adult rats: a quantitative morphological study.** *Exp Brain Res* 2001, **139**:216-23.
- Suzuki H, Oyanagi K, Takahashi H, Kono M, Yokoyama M, Ikuta FA: **Quantitative pathological investigation of the cervical cord, roots and ganglia after long-term amputation of the unilateral upper arm.** *Acta Neuropathol* 1993, **86**:546-8.
- McKay HA, Brannstrom T, Wiberg M, Terenghi G: **Primary sensory neurons and satellite cells after peripheral axotomy in the adult rat: timecourse of cell death and elimination.** *Exp Brain Res* 2002, **142**:308-18.
- Taushev KG: **Segment-by-segment histological analysis of the cervical part of the spinal cord, roots of the cerebrospinal nerves and ganglia in severe cranio-cerebral trauma.** *Arkh Anat Gistol Embriol* 1989, **96**:16-23.
- Ganchrow D, Ornoy A: **Possible evidence for secondary degeneration of central nervous system in the pathogenesis of anencephaly and brain dysraphia. A study in young human fetuses.** *Pathol Anat Histol* 1979, **384**:285-94.
- Teunissen L, Veldink J, Notermans NC, Bleys RL: **Quantitative assessment of the innervation of epineurial arteries in the peripheral nerve by immunofluorescence: differences between controls and patients with peripheral arterial disease.** *Acta Neuropathol* 2002, **103**:475-80.
- Tandrup T, Woolf CJ, Coggeshall RE: **Delayed loss of small dorsal root ganglion cells after transection of the rat sciatic nerve.** *Comp Neurol* 2000, **422**:172-80.
- Shi TJ, Tandrup T, Bergman E, Xu ZQ, Ulfhake B, Hokfelt T: **Effect of peripheral nerve injury on dorsal root ganglion neurons in the C57 BL/6J mouse: marked changes both in cell numbers and neuropeptide expression.** *Neuroscience* 2001, **105**:249-63.
- Bahadori MH, Al-Tiraihi T, Valojerdi MR: **Sciatic nerve transection in neonatal rats induces apoptotic neuronal death in L5 dorsal root ganglion.** *J Neurocytol* 2001, **30**:125-30.
- Tandan R, Bradley WG: **Amyotrophic lateral sclerosis: Part 2. Etiopathogenesis.** *Ann Neurol* 2000, **18**:419-31.
- Bendsen E, Byskov AG, Laursen SB, Larsen HP, Andersen CY, Westergaard LG: **Number of germ cells and somatic cells in human fetal testes during the first weeks after sex differentiation.** *Hum Reprod* 2003, **18**:13-8.
- Cruz-Orive LM, Weibel ER: **Recent stereological methods for cell biology: a brief survey.** *Am J Physiol* 1990, **258**:148-56.
- Sterio DC: **The unbiased estimation of number and sizes of arbitrary particles using the disector.** *J Microsc* 1984, **134**:127-36.

Publish with **BioMed Central** and every scientist can read your work free of charge

"BioMed Central will be the most significant development for disseminating the results of biomedical research in our lifetime."

Sir Paul Nurse, Cancer Research UK

Your research papers will be:

- available free of charge to the entire biomedical community
- peer reviewed and published immediately upon acceptance
- cited in PubMed and archived on PubMed Central
- yours — you keep the copyright

Submit your manuscript here:
http://www.biomedcentral.com/info/publishing_adv.asp

