

RMD Open

Rheumatic & Musculoskeletal Diseases

EXTENDED REPORT

What is the prevalence of MRI-detected inflammation and erosions in small joints in the general population? A collation and analysis of published data

Lukas Mangnus,¹ Jan W Schoones,² Annette H M van der Helm-van Mil¹

To cite: Mangnus L, Schoones JW, van der Helm-van Mil AHM. What is the prevalence of MRI-detected inflammation and erosions in small joints in the general population? A collation and analysis of published data. *RMD Open* 2015;1:e000005. doi:10.1136/rmdopen-2014-000005

► Prepublication history for this paper is available online. To view these files please visit the journal online (<http://dx.doi.org/10.1136/rmdopen-2014-000005>).

Received 7 October 2014
Revised 26 November 2014
Accepted 27 November 2014



CrossMark

¹Department of Rheumatology, Leiden University Medical Center, Leiden, The Netherlands

²Walaeus Library, Leiden University Medical Center, Leiden, The Netherlands

Correspondence to
Lukas Mangnus;
l.mangnus@lumc.nl

ABSTRACT

Introduction: MRI sensitively depicts erosions, bone marrow edema (BME) and synovitis in rheumatoid arthritis (RA). Recently developed European League Against Rheumatism (EULAR) recommendations stated that MRI is valuable to improve the certainty of a considered diagnosis and to detect structural damage at an early time point. However, these recommendations were mainly based on the data of patients with RA; prevalences of MRI features in the general population were not extensively explored. We reviewed the literature on MRI studies including symptom-free persons to assess the occurrence of MRI features.

Methods: Medical literature databases up to September 2013 were systematically reviewed for symptom-free persons with MRI data on metacarpophalangeal, wrist and metatarsophalangeal joints. Data were extracted and summarised. When allowed because of comparable scanning and scoring protocols, a mean frequency of features was calculated.

Results: Of the 338 articles screened, 31 studies evaluated MRI findings in symptom-free persons (n=516 in total). Both the imaging techniques (<1≥1 T, with/without contrast enhancement) and the scoring methods (non-validated or RA MRI score (RAMRIS)) varied widely, prohibiting direct comparisons of the results of many studies. 15 studies scored data according to RAMRIS; combining data of similar joint regions showed that erosions (RAMRIS ≥1) were present in 33–52% of symptom-free persons. Similarly, synovitis was present in 27% and BME in 0–16% of symptom-free persons. The prevalence of MRI-detected erosions increased with age.

Conclusions: MRI features, erosions in particular, occur frequently in symptom-free persons. Before MRI can be implemented in the diagnostic process, larger studies should be conducted determining the degree and combination of MRI features that are disease specific.

INTRODUCTION

Early treatment initiation in rheumatoid arthritis (RA) is associated with less radiographic progression and a higher chance to achieve

Key messages

- MRI detected erosions, synovitis and bone marrow edema occur frequently in symptom-free persons.
- Owing to the of heterogeneity in the studies, RA-specific MRI criteria cannot yet be defined.
- Before implementing MRI in the diagnostic process of joint symptoms, further research is needed.

disease-modifying antirheumatic drug-free sustained remission, illustrating the relevance of early diagnosis.^{1–6} To what extent MRI is valuable for early detection of RA is undetermined. However, the recently formulated European League Against Rheumatism (EULAR) recommendations for the use of imaging in the management of RA suggest that MRI can improve the certainty of the diagnosis of RA and detect structural damage at an earlier time point than radiographs.⁷ Additionally, an imaging task force of the American College of Rheumatology recently concluded that, of all imaging modalities, MRI serves best to ascertain structural damage in trials.⁸ These recommendations were mainly based on MRI data of patients with RA; MRI features that are present in the general population were scarcely considered.^{7 8}

Furthermore, many studies in RA are currently investigating the preclinical phases of the disease because the processes occurring in these phases may influence the long-term course of the disease. Potentially very early detection of RA may allow intervention in an asymptomatic preclinical disease phase. Indeed, several recent studies reported that MRI may play a role in the identification of joint inflammation in the phase before it becomes clinically detectable.^{9 10} More studies are needed to determine the value of novel imaging modalities in the early detection of

RA and their ability to differentiate patients with the disease from the normal situation.

Thus, to arrive at an evidence-based evaluation on the role of MRI in the diagnostic process in the early clinical and preclinical phases of RA, it is necessary to investigate the occurrence of MRI features in the general population. In case certain MRI features (to a certain degree) are also present in persons without joint symptoms, these lesions are presumably not indicative for RA. No large-scale studies have been performed to investigate the prevalence of these features in the general population. However, several MRI studies included symptom-free persons as controls.^{10–41} We aimed to (1) evaluate the prevalence of MRI features in symptom-free persons and (2), based on these observations, to make recommendations for future studies. To this end, we systematically reviewed the literature.

METHOD

The databases PubMed, EMBASE and Web of Science up until September 2013 were searched with the assistance of a medical librarian (JWS). Central terms in our search were MRI, healthy volunteers, wrist, metacarpal, metatarsal and RA (complete details of the search strategy can be obtained by the author). Titles and abstracts were screened on whether data on symptom-free persons and MRI of hands or feet were available. Subsequently, full-text articles were read and additional articles were identified through hand searching of reference lists. Articles were included when the studies contained (1) symptom-free persons and (2) information on MRI detected erosions, bone marrow edema (BME), synovitis or tenosynovitis of hands or feet. Since the symptom-free persons were generally used as the control group, the quality of the overall study design was not valued. Further, in order to get a comprehensive overview, we decided to include all studies fulfilling these two criteria and not to exclude studies based on the quality of the scanner, the scan protocol or scoring protocol that was used.

A standardised form was used to extract the following data: (1) study population (population size, age, recruitment method, description of study population, MRI scanner, MRI sequences, joint region scanned and scoring method), (2) MRI features (erosions, BME, synovitis and tenosynovitis) and quantitative aspects (number of patients affected, number of joints/bones affected and grading of the MRI features) and (3) relevant characteristics (location of MRI features, dominant or non-dominant hands, age and sex of symptom-free participants). MRI features were present ('positive') when recorded as such; studies using the RA MRI score (RAMRIS) generally considered a score of ≥ 1 for that feature as positive.^{10 27–40} Data were extracted and reported such as done by the authors: either by presenting the prevalence of a feature or by presenting summary measures of continuous RAMRIS. According to RAMRIS, the range per bone/joint of erosion, BME and synovitis

scores are 0–10, 0–3 and 0–3, respectively; scoring of the metacarpophalangeal (MCP) region and wrist region involved evaluation of 8 and 15 bones and 4 and 3 joints (radioulnar joint, radiocarpal joint and intercarpal-carpometacarpal joint), respectively, evaluation of the 5 metatarsophalangeal (MTP) joints involved evaluation of 10 bones. In case the same joint regions were assessed using similar scan protocols (ie, either with or without use of contrast enhancement) and similar scoring methodology (RAMRIS), it was considered acceptable to combine the results of different studies. Then mean frequencies (with 95% CIs) were calculated. Since it is known that contrast enhancement increases the reliability of assessment of synovitis,⁴² studies evaluating synovitis and tenosynovitis with and without contrast enhancement were not combined but analysed separately.

RESULTS

Selection of studies

The literature search yielded 338 studies; five additional articles were found by hand searching of reference lists (figure 1). After screening, 61 articles were selected. Two studies were excluded because of a language other than English. Of the remaining articles, 33 were eligible for inclusion. One article was excluded as it concerned a population that was used in two articles. Consequently, data were extracted of 32 articles. Whereas 31 studies provided data on patient level (joint region), one study analysed the data only on individual bone/joint level; therefore, this study was only used when analysing results on bone/joint level.⁴¹

Study description

The 31 included studies contained information on 3–42 (range) symptom-free persons per study; in total, 516 symptom-free persons were studied (table 1). Descriptions of the recruitment method is given in only seven studies.^{12 23 24 26 31 32 36} Most of these studies are reported to have studied hospital staff. Methods to exclude the target disease were described in 26 articles; four studies did not include this information and described their symptom-free persons as 'healthy volunteers'¹¹ or 'healthy controls'^{14 37 38} and one study was described to have performed MRIs of 'healthy volunteers' and persons with wrist instability.²⁶ The methods of excluding target disease differed. Thirteen studies described that there was no history of joint disease, arthritis or joint symptoms.^{15–17 19–22 24 28–30 36 39} Twenty studies mentioned that there were no current musculoskeletal/joint symptoms.^{10 12 13 18 20 21 23–25 27–34 36 39} In four studies, persons underwent clinical assessment by a rheumatologist,^{24 27 29 36} and in two studies laboratory investigations were done and persons were excluded in case they were rheumatoid factor positive or had increased C reactive protein levels.^{32 33}

Of the 31 included studies, 19 used an MRI with ≥ 1 T, 11 with an <1 T MRI and one study used two different

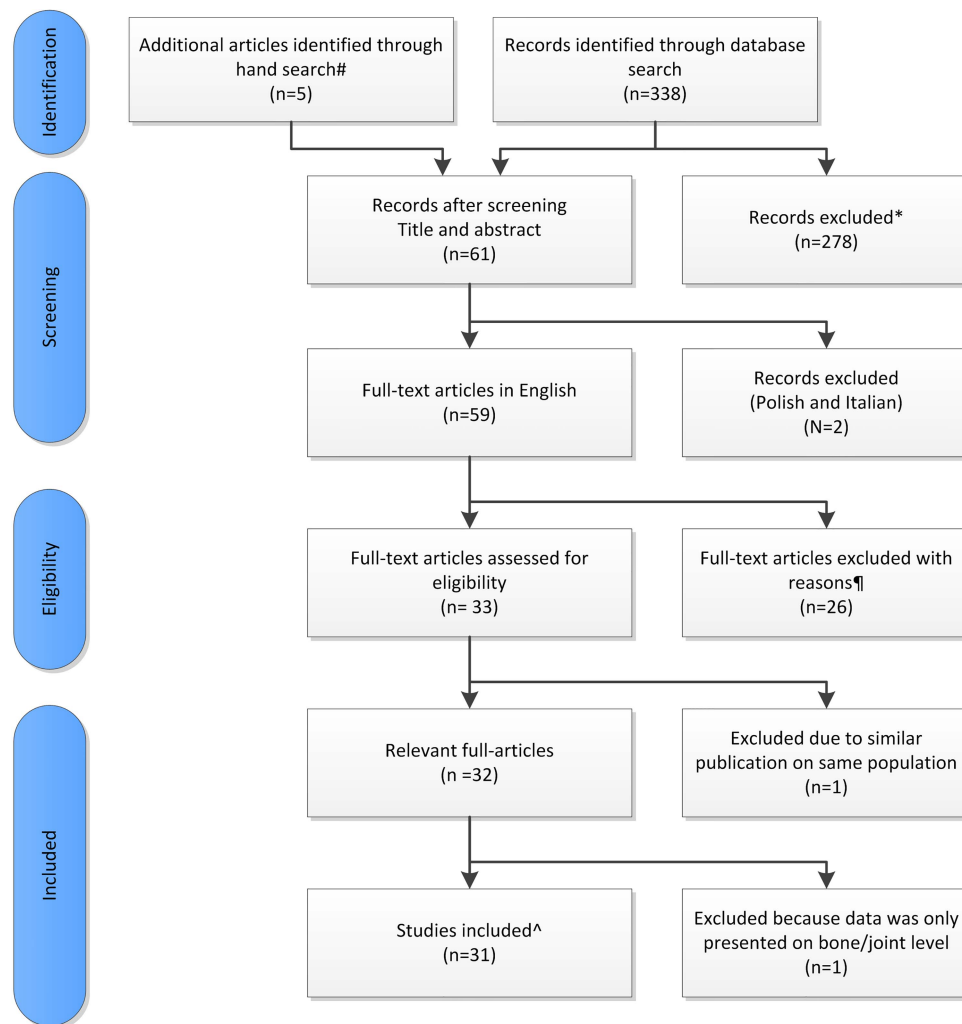


Figure 1 Overview of literature research. #Articles identified by hand searching of reference lists. *Articles were excluded when no data on symptom-free persons or MRI features of hands or feet were described. ¶Articles were excluded when no data were presented on erosions, BME, synovitis or tenosynovitis in symptom-free persons. ^The data of the 31 included studies provided data on patient level.

scanners (one with 1 T and one with 0.6 T).³⁴ Contrast enhancement was used in 17 of the 31 studies.

Sixteen studies did not use a validated scoring method; evaluations were done by experienced radiologists (in 12 studies), an experienced rheumatologist (1 study) and an ‘observer’ (2 studies), and in one study no information was provided. In 15 studies, MRIs were scored according to RAMRIS.⁴³ MRI scoring was done blinded for clinical status in 18 of the 31 studies. In seven studies, scoring of patients and controls was not performed blindly,^{10 15 20 23 27 34 40} and in six studies (140 symptom-free persons) only symptom-free persons were evaluated.^{22 23 28 30 32 36}

Prevalence of erosions

The studies that did not use a validated scoring method reported a lower prevalence of erosions than did the studies using RAMRIS (table 2). A wrist was scanned on one or both sides and assessed using RAMRIS in 69 and

44 persons, respectively. When combining data of the wrist, a total RAMRIS erosion score ≥ 1 was reported in 52.2% (mean, 95% CI 40.6 to 63.5, unilateral wrist)^{27 34 37} and 40.9% (95% CI 27.7% to 55.6%, both wrists)^{35 36} of symptom-free persons, respectively. Unilateral MCP joints were evaluated in 97 persons and revealed erosions in 33% (95% CI 24.4% to 42.9%).^{27 34 38 39} No studies described the prevalence of erosions when using higher cut-offs for positivity (for instance, a total RAMRIS erosion score of ≥ 2).

Prevalence of BME

The recorded prevalence of BME was higher in the studies using RAMRIS than in the studies using other methods. Combining the data of the 63 persons in whom unilateral wrists were scanned yielded a mean frequency of BME (RAMRIS BME score ≥ 1) of 15.9% (95% CI 8.7% to 27.0%).^{27 34} Similarly, BME was present in 9.5% (95% CI 4.1% to 19.6%)^{27 34} of persons

Table 1 Characteristics of the 31 selected studies

First author, year of publication	N=	Recruitment method*	Age	Female/ male	MRI	Contrast	Area scanned	Uni/ bilateral	Score Method	Blinded†
<i>Scored without a validated method</i>										
Wrist+MCP summed										
Nakahara <i>et al</i> , 1996 ¹¹	10	NP	NP	5/5	1.5T	Gd+	Wrist+MCP	NP	Described	+
Lindgaard <i>et al</i> , 2001 ¹²	3	Hospital staff	46 (34–55)	1/2	0.2T	Gd+	Wrist+MCP	Unilateral	Described	+
Yoshioka <i>et al</i> , 2006 ¹³	13	NP	34.1 (22–48)	5/8	0.21T	Gd–	Wrist+MCP+PIP	Bilateral	NP	+
Offidani <i>et al</i> , 1998 ¹⁴	12	NP	NP	NP	1.0T	Gd–	Wrist+MCP+IP	NP	Described	+
Wrist										
Beltran <i>et al</i> , 1987 ¹⁵	6	NP	NP	NP	1.5T	Gd–	Wrist	NP	Described	NP
Jorgensen <i>et al</i> , 1993 ¹⁶	4	NP	30	2/2	0.5T	Gd+	Wrist	NP	NP	+
Yanagawa <i>et al</i> , 1993 ¹⁷	10	NP	NP	7/3	1.5T	Gd+	Wrist	NP	NP	+
Østergaard <i>et al</i> , 1995 ¹⁸	3	NP	30 (28–31)	NP	1.5T	Gd+	Wrist	NP	NP	+
Tonolli-Serabian <i>et al</i> , 1996 ¹⁹	10	NP	59 (46–71)	5/5	1.0T	Gd+	Wrist	Bilateral	Described	+
Pierre-Jerome <i>et al</i> , 1997 ²⁰	42	NP	42.1	42/0	0.5T	Gd–	Wrist	Bilateral	Described	NP
Valeri <i>et al</i> , 2001 ²¹	12	NP	31	8/4	1.0T	Gd–	Wrist	Bilateral	Described	NP
Partik <i>et al</i> , 2002 ²²	18	NP	30.8 (24–34)	9/9	1.0T	Gd+	Wrist	NP	NP	NP
Robertson <i>et al</i> , 2006 ²³	30	Hospital staff and contacts	31 (22–49)	17/13	1.5T	Gd+	Wrist	Unilateral	Described	NP
MCP										
McGonagle <i>et al</i> , 1999 ²⁴	31	Hospital staff	48 (28–62)	18/13	1.5T	Gd–	MCP	Unilateral	Described	+
Klarlund <i>et al</i> , 1999 ²⁵	3	NP	31 (24–33)	NP	1.0T	Gd+	MCP	Unilateral	Described	+
Vlychou <i>et al</i> , 2013 ²⁶	5	2 volunteers and with 3 wrist instability<AQ: Please rephrase for clarity.>	41.2±3.2	3/2	3.0T	Gd+	MCP+PIP+DIP	Unilateral	Described	+
<i>Scored according to RAMRIS</i>										
Wrist+MCP summed										
Brown <i>et al</i> , 2006 ²⁹	17	NP	38	12/5	1.5T	Gd+	Wrist+MCP	Unilateral	RAMRIS	+
Ejbjerg <i>et al</i> , 2004 ³⁰	28	NP	47 (24–67)	20/8	1.0T	Gd+	Wrist+MCP	Unilateral	RAMRIS	NP
Olech <i>et al</i> , 2010 ³¹	40	Hospital staff	36.7 (20–64)	29/11	0.2T	Gd–	Wrist+MCP	Bilateral	RAMRIS	+
Parodi <i>et al</i> , 2006 ³²	23	Healthy relatives	59 (25–86)	16/7	0.2T	Gd–	Wrist+MCP+PIP	Bilateral	RAMRIS	NP
Ejbjerg <i>et al</i> , 2005 ³³	9	NP	NP	NP	0.2T	Gd–	Wrist+MCP+MTP	Bilateral	RAMRIS	+
Duer-Jensen <i>et al</i> , 2011 ³⁴	24	NP	46 (21–71)	17/7	0.6 T (12), 1.0 T (12)	Gd+	Wrist+MCP+PIP	Unilateral	RAMRIS	NP
Wrist										
Cimmino <i>et al</i> , 2011 ³⁵	13	NP	71 (57–86)	NP	0.2T	Gd–	Wrist	Bilateral	RAMRIS	+
Palosaari <i>et al</i> , 2009 ³⁶	31	Hospital staff	49 (32–64)	18/13	0.23T	Gd+ (10/31)	Wrist	Bilateral	RAMRIS	NP
Döhn <i>et al</i> , 2008 ³⁷	4	NP	36 (34–57)	3/1	0.6T	Gd–	Wrist	Unilateral	RAMRIS	+
MCP										
Döhn <i>et al</i> , 2006 ³⁸	4	NP	35.5 (34–57)	3/1	0.6T	Gd–	MCP	Unilateral	RAMRIS	+
Tan <i>et al</i> , 2003 ³⁹	28	NP	40	19/9	1.5T	Gd+ (8/28)	MCP	Unilateral	RAMRIS	+
Miese <i>et al</i> , 2012 ⁴⁰	13	NP	51±12 (25–66)	10/3	3T	Gd+	MCP (dig 2&3)	Unilateral	RAMRIS	NP
Mean grading (Wrist+MCP)										
Xie <i>et al</i> , 2008 ²⁷	14	NP	25±5 (19–33)	4/10	1.0T	Gd–	Wrist+MCP	Bilateral	RAMRIS	NP
	27	NP	62±7 (49–74)	22/5	1.0T	Gd–	Wrist+MCP	24/27 Bilateral	RAMRIS	NP
Krabben <i>et al</i> , 2013 ¹⁰	19	NP	46.2±11.8	15/4	1.5T	Gd–	Wrist+MCP+MTP	Unilateral	RAMRIS	NP
Rastogi <i>et al</i> , 2013 ²⁸	10	NP	(24–40)	7/3	3T	Gd+	Wrist	Unilateral	RAMRIS	NP

*Description of recruitment of symptom-free persons.

†Scoring was done blind for the status (patient/symptom-free person).

described, articles that do describe their scoring method but not according to the RAMRIS method; DIP, distal interphalangeal joint; Gd, gadolinium; IP, interphalangeal joint; MCP, metacarpophalangeal joints; MTP, metatarsophalangeal; NP, Not provided; PIP, proximal interphalangeal joint; T, tesla.

Table 2 Frequency of erosions, BME, synovitis and tenosynovitis in symptom-free persons

First author, year of publication	N=healthy	Uni/bilateral	Erosions (%)	BME (%)	Synovitis (%)	Tenosynovitis (%)
<i>Scored without a validated method</i>						
Wrist+MCP						
Nakahara et al, 1996¹¹	10	NP	NP	0.0	0.0	0.0
Lindgaard et al, 2001 ¹²	3	Unilateral	0.0	NP	NP	NP
Yoshioka et al, 2006 ¹³	13 (+PIP)	Bilateral	0.0	NP	0.0	0.0
Offidani et al, 1998 ¹⁴	12 (+IP)	NP	0.0	NP	0.0	0.0
Wrist						
Beltran et al, 1987 ¹⁵	6	NP	0.0	NP	0.0	0.0
Jorgensen et al, 1993¹⁶	4	NP	0.0	NP	0.0	0.0
Yanagawa et al, 1993¹⁷	10	NP	NP	NP	0.0	NP
Østergaard et al, 1995¹⁸	3	NP	NP	NP	0.0	NP
Tonolli-Serabian et al, 1996¹⁹	10	Bilateral	0.0	NP	0.0	NP
Pierre-Jerome et al, 1997 ²⁰	42	Bilateral	35.7%*	0.0	4.8	FI: 9.5 Ext: 7.1
Valeri et al, 2001 ²¹	12	Bilateral	NP	NP	NP	0.0
Partik et al, 2002²²	18	NP	NP	0.0	44.4	NP
Robertson et al, 2006²³	30	Unilateral	NP	13.3%	NP	NP
MCP						
McGonagle et al, 1999 ²⁴	31	Unilateral	25.8	9.7	NP	NP
Klarlund et al, 1999 ²⁵	3	Unilateral	0.0	NP	NP	NP
Vlychou et al, 2013²⁶	5 (+PIP, DIP)	Unilateral	0.0	0.0	0.0	0.0
<i>Scored according to RAMRIS</i>						
Wrist+MCP (2–5)						
Brown et al, 2006²⁹	17	Unilateral	NP	0.0	17.6	5.9
Ejbjerg et al, 2004³⁰	28	Unilateral	NP	0.0	32.1	NP
Olech et al, 2010 ³¹	40	Bilateral	65.0	17.5	42.5	NP
Parodi et al, 2006 ³²	23 (+PIP)	Bilateral	26.0	8.7%	NP	FI: 17.4 Ext: 4.3
Ejbjerg et al, 2005 ³³	9 (+MTP)	Bilateral	55.6	NP	NP	NP
Combined data ^{29 30}	0/45	Unilateral	BME mean 0% (95% CI 0.0% to 6.8%)			
Combined data ^{29 30}	12/45	Unilateral	Synovitis mean 26.7% (95% CI 15.8% to 41.2%)			
Wrist						
Cimmino et al, 2011 ³⁵	13	Bilateral	30.8	30.8	0.0	30.8
Palosaari et al, 2009³⁶	31	Bilateral	45.2	NP	60.0%	NP
Døhn et al, 2008 ³⁷	4	Unilateral	25.0	NP	NP	NP
Duer-Jensen et al, 2011†³⁴	24	Unilateral	45.8	4.5	81.8	0.0%
Xie et al, 2008‡ ²⁷	14	Unilateral	0.0	0.0	0.0	NP
	Age 25±5					
	27	Unilateral	88.9	33.3	3.7	NP
	Age 62±7					
Combined data ^{35 36}	18/44	Bilateral	Erosions mean 40.9% (95% CI 27.7% to 55.6%)			
Combined data ^{27 34 37}	36/69	Unilateral	Erosions mean 52.2% (95% CI 40.6% to 63.5%)			
Combined data ^{27 34}	10/63§	Unilateral	BME mean 15.9% (95% CI 8.7% to 27.0%)			
MCP (2–5)						
Døhn et al, 2006 ³⁸	4	Unilateral	0.0	NP	NP	NP
Tan et al, 2003 ³⁹	28	Unilateral	32.1	NP	NP	NP
Miese et al, 2012⁴⁰	13 MCP 2&3	Unilateral	NP	0.0	0.0	NP
Duer-Jensen et al, 2011†³⁴	24	Unilateral	45.8	4.5	45.5	0.0
Xie et al, 2008‡ ²⁷	14	Unilateral	0.0	14.3	0.0	NP
	Age 25±5					
	27	Unilateral	44.4	11.1	14.8	NP
	Age 62±7					
Combined data ^{27 34 38 39}	32/97	Unilateral	Erosions mean 33.0% (95% CI 24.4% to 42.9%)			
Combined data ^{27 34}	6/63§	Unilateral	BME mean 9.5% (95% CI 4.1% to 19.6%)			

0% is noted when no erosions are found or an abnormality is described in the patient group and the healthy control group is only described as 'no abnormalities' with no further specification.

Bolt—studies in which contrast was used to score synovitis and tenosynovitis.

*Contradicting data in original article, with 35.7% erosions in the table and 14.3% erosions in the text.

†Same study.

‡Same study.

§Duer-Jensen only assessed 22 patients for BME.

DIP, distal interphalangeal joint; Ext, extensor tendons; FI, flexor tendons; IP, interphalangeal joint; MCP, metacarpophalangeal joints; MTP, metatarsophalangeal; NP, Not provided; PIP, proximal interphalangeal joint.

in whom unilateral MCPs were evaluated. Combining studies assessing unilateral wrist and MCPs showed a mean frequency of BME of 0.0% (95% CI 0.0% to 6.8%).^{29 30} No studies categorised BME features with higher cut-off values.

Prevalence of synovitis and tenosynovitis

Synovitis was assessed without contrast enhancement in 8 studies and with contrast in 13 studies. In the studies that used no validated scoring method, synovitis was present in 0–4.8% (range) of persons when no contrast was used^{13–15 20} and 0–44.4% (range) when contrast was used.^{11 16–19 22 26} In the studies that were scanned with contrast enhancement and scored according to RAMRIS, synovitis was present (total synovitis score ≥ 1) in 26.7% (95% CI 15.8% to 41.2%); these studies assessed wrist and MCP joints together.^{29 30} Data on the studies that provided results of wrist or MCP joints separately were not combined due to differences in scanning or scoring protocols. Tenosynovitis was assessed infrequently (table 2).

Continuous RAMRIS-scores

Three studies did not report categorised data but reported continuous RAMRIS, incorporating a semi-quantitative evaluation of the severity of the features.^{10 27 28} The mean RAMRIS for erosions and BME were low (≤ 3.2 and 0.9, respectively, table 3). For synovitis, contrast enhancement was used in one study;²⁸ this study revealed higher mean RAMRIS synovitis scores than did the two studies without contrast (mean synovitis scores >3 vs <1 , respectively; table 3).^{10 27}

Prevalence of lesions at the bone and joint level

In the aforementioned studies, total scores per joint region were evaluated. Several studies evaluated the prevalence of MRI features on the level of individual bones and/or joints, all defining a RAMRIS of ≥ 1 as

positive.^{24 29–32 36 39 41} Erosions were analysed in six studies; among the 4696 bones evaluated, 161 showed erosions 3.4% (95% CI 2.9% to 4.0%).^{30–32 36 39 41} BME was analysed in only two studies; among the 1182 bones evaluated, five were positive for BME 0.4% (95% CI 0.2% to 1.0%).^{24 32} Three studies analysed 471 joints on synovitis and reported the prevalence of synovitis in 42 joints 8.9% (95% CI 6.6% to 11.9%).^{29 30 41}

The severity of the individual lesions was scarcely reported. Three studies contained information on the severity of erosions and reported that 80.8% (mean, 95% CI 72.8% to 86.9%) of the recorded erosions had a score of 1.^{31 32 36} None of the studies reported on the severity of BME or tenosynovitis at the local level. Two studies described the synovitis scores in more detail; 21 joints had a RAMRIS of 1 (95.5%), a RAMRIS synovitis score of 2 was seen in 1 joint (4.5%) and no joints had a RAMRIS of 3.^{29 30}

With regard to the location of the MRI features, erosions and synovitis were more often observed in the wrist than in the MCP joints.^{20 31 32} The locations of erosions were evaluated in seven studies at the bone level; most erosions were observed in the carpal bones; however, there was no clear agreement on which carpal bones showed erosions most frequently.^{30 32 35 36 41} Erosions were rarely scored on the metacarpal-1 and trapezium (bones that might also be affected by osteoarthritis).^{30–32 35 36} Locations of BME and synovitis were not clearly reported.

Relevant characteristics

We next evaluated to what extent differences in the scanner or differences in persons' characteristics influenced the results. No different prevalences were observed when comparing extremity-MRI^{10 12 13 27 31–33 35} with whole-body MRI.^{11 14–26 28–30 36–40} When comparing the prevalence of MRI features in studies that used MRI scanners with <1 Tesla (T)^{12 13 16 20 31–33 35–38} and those

Table 3 Mean RAMRIS score in symptom-free persons

First author, year of publication	N=healthy	Uni/bilateral	Erosions	BME	Synovitis	Tenosynovitis
Xie <i>et al</i> , 2008 ²⁷	14 Age 25 \pm 5	Bilateral	0 Pt	Dom MCP: 0.14	0 Pt	NP
	27 Age 62 \pm 7	24/27 Bilateral	Dom MCP: 1.51	Dom MCP: 0.29	Dom MCP: 0.29	NP
			Dom Wr: 3.11	Dom Wr: 0.85	Dom Wr: 0.03	
Krabben <i>et al</i> , 2013 ¹⁰	19 (+MTP)	Unilateral	MCP/PIP: 0.1	MCP/PIP: 0.1†		NP
			Wrist: 0.7	Wrist: 0.9		
Rastogi <i>et al</i> , 2013 ^{*28}	10	Unilateral	T0:0.8 \pm 1.3	T0:0.6 \pm 0.7	T0:3.5\pm2.6	NP
			T12:0.4 \pm 0.7	T12:0.2 \pm 0.5	T12:3.3\pm1.6	
			T24:0.4 \pm 0.7	T24:0.2 \pm 0.4	T24:3.7\pm2.0	
			T52:1.4 \pm 1.9	T52:0.3 \pm 0.6	T52:4.5\pm1.7	

Bolt—studies in which contrast was used to score synovitis and tenosynovitis. Erosions were scored on a scale from 0–10 for each location; BME and synovitis were scored from 0–3 for each location. Erosions and BME were scored in 23 locations in the hand and 10 in the foot; synovitis was scored in 7 locations in the hand and 5 in the foot.

†Krabben summed the BME and the synovitis into an inflammation score.

*Is a longitudinal study with T0 as baseline, T12 after 12 weeks, T24 after 24 weeks, T52 after 52 weeks.

Dom, dominant hand; MCP, metacarpophalangeal joints; MTP, metatarsophalangeal; NP, Not provided; Wr, wrist.

with >1 T,^{10 11 15 17 18 23 24 26 28 29 39 40} a higher prevalence of erosions was detected with <1 T scanners (mean 38% vs 24%). Owing to the heterogeneity between studies, no summary results can be provided with regard to the prevalence of MRI inflammatory features in relation to the field strength of the MRI. When comparing the studies that evaluated the MRIs blindly versus those that scored the MRIs knowing that the persons were symptom-free, no differences in the prevalences of the different MRI features were observed.^{11–14 16–19 23–26 29 31 33 35 37–39}

The dominant and non-dominant hands were evaluated in two studies and no significant differences were observed.^{31 36} Differences in the frequency of features between sexes were also not detected.³² Four studies compared the prevalence of MRI features between age categories and showed a non-significant tendency to^{27 32} or a significant^{31 36} higher prevalence of MRI erosions in older persons. Synovitis and BME were less frequently studied in relation to age, although a significant difference in two studies was observed with higher prevalences at older age.^{31 36} No information was provided on the location or the grading of the erosions and the inflammatory features observed in symptom-free persons of different age categories.

DISCUSSION

MRI is an imaging method that is very sensitive in detecting inflammation and also bone erosions. This makes MRI an interesting tool to measure the course of the disease in randomised clinical trials and this suggests that MRI may also be useful in the diagnostic process. When MRI would be implemented in practice in the diagnostic workup of joint symptoms, it is crucial to consider the prevalence of MRI features in the general population to prevent false-positive findings due to positive labelling of features that are (also) present in the normal situation. We reviewed the literature systematically to get an overview of the reported prevalence of features in symptom-free persons. The large majority of these studies were not designed to determine the frequencies of MRI features in the general population but used symptom-free persons as the control group. In addition, there were considerable differences in methodology of the selection of volunteers, MRI protocols and MRI scoring. This resulted in heterogeneous data. Indeed, considerable differences in the frequencies of MRI features in symptom-free persons were observed in the different studies. We combined the data of the studies that had similar scanning and scoring protocols and, based on the data available, we observed that all MRI features studied were present regularly and that MRI detected erosions were present most frequently (in 33–52% of symptom-free persons).

Most studies described their findings at the patient/joint region level and not at the level of individual bones or joints. However, studies that did include evaluation at the bone level showed that most lesions were mild

(RAMRIS of 1). Furthermore, we noted a lower prevalence of all MRI features (erosions in particular) in studies not using RAMRIS than in those using the RAMRIS method. This may possibly reflect that the RAMRIS method is sensitive and that radiologists evaluating the MRIs using clinical experience may more often report an MRI as normal. Additionally, most of the studies that did not use the RAMRIS method were done when MRI techniques were less developed.^{11 12 14–22 24 25 44}

Of all MRI features, the prevalence of synovitis varied the most between studies. This cannot be explained only by the absence or presence of contrast enhancement that may increase the sensitivity and specificity of identifying MRI-detected synovitis as both types of studies were evaluated separately.^{42 45 46} The reasons for these differences between studies are unclear to us.

The most important limitation of this review is the heterogeneity of the data collected, which is a result of the methods with which data were collected in the individual studies. For instance, in many studies the symptom-free persons were used as the control-group and information on how the symptom-free persons were recruited was missing. Some studies included symptom-free persons only and did not use the symptom-free persons as controls.^{22 23 28 30 32 36} A consequence of this latter approach is that the evaluators per definition were aware that they had evaluated scans of symptom-free persons. Hypothetically, awareness of the clinical status may affect the scoring with lower scores being given to symptom-free individuals. In addition, the methodology to rule out rheumatic diseases differed between the studies. A difficult issue is to what extent osteoarthritis was ruled out; joint space narrowing or other osteoarthritic features were not assessed in these studies, so no definite conclusions can be drawn as to what extent the presence of asymptomatic osteoarthritis has affected the results. Furthermore, recent studies indicated that ACPA can affect the bone in the absence of clinically apparent arthritis and that subclinical inflammation may precede clinical arthritis.^{9 10} In two studies, the symptom-free persons underwent laboratory testing and in three studies the symptom-free persons were even followed (for 1–5 years); none of these persons developed RA.

Another important limitation relates to the issue when it is allowed to combine the results of different studies. We combined results of studies that used similar scan protocols (same joints and uniformity in contrast enhancement) and similar scoring protocols. Still, the summary measures that we provided should be interpreted with care as the readers of the different studies were not trained together and inter-reader differences and other causes of heterogeneity most likely exist. Nevertheless, this review gives a first impression of the MRI features present in the general population.

It can be argued that more stringent quality criteria should be applied before it is acceptable to combine the results of different studies. For instance, the following quality criteria might be reasonable: (1) the recruitment

Box 1 Recommendations for high-quality studies, formulated based on the findings of this review

Include a large number of symptom-free persons
 Include persons of different age categories
 Apply population-based recruitment methods
 Describe the recruitment methodology
 Apply thorough anamnesis and physical examination to exclude the presence of joint symptoms or signs of joint disorders.
 Perform similar MRI scans in all persons
 MRI strength of ≥ 1 Tesla
 Use contrast enhancement
 Score the MRIs according to RAMRIS
 Also include MRIs of persons with joint diseases (eg RA) and score the MRIs blinded to the clinical status
 Perform analyses stratified for age

method was described, (2) appropriate methodology was used to exclude persons with joint symptoms or joint disease, (3) the field strength of the MRI was ≥ 1 T and (4) scans were scored according to the RAMRIS method. None of the 32 studies included in this review fulfilled all these four criteria. This underlines that large, high quality studies on this subject are needed. Recommendations for the set-up of such studies are proposed in box 1.

Furthermore, several questions still have to be answered. More detailed studies are needed on the prevalence of MRI-detected erosions, BME, synovitis and tenosynovitis in the symptom-free persons in relation to age. Furthermore, the location and the co-occurrence of erosions and inflammation (BME, synovitis or tenosynovitis) could be important for differentiation. In none of the studies was it reported whether the erosions were accompanied by inflammatory lesions, which may also be relevant to differentiate early disease from normal variants, as disease-specific erosions might presumably more often be accompanied by measures of inflammation. Also the extent or severity of the lesions may be useful to take into account. Ultimately, comparing a large number of MRI scans of healthy persons and early RA patients will reveal which combination of features are disease specific and will allow MRI criteria specific for early disease to be defined.

In conclusion, MRI features, erosions in particular, occur frequently in symptom-free persons and are more prevalent with increasing age. Before MRI can be implemented in the diagnostic process of arthritis, further evaluation of these features in symptom-free persons is required. Preferentially, this is done in large studies, ensuring homogeneity in the scan-protocol and scoring method, by evaluating scans of symptom-free persons as well as early arthritis patients blinded to the clinical status.

Contributors LM and AHMvdHvM contributed to the conception and design of the study. All authors acquired or analysed the data. LM and AHMvdHvM contributed to the interpretation of the data. All authors contributed to the final version of the manuscript.

Funding The research leading to these results was funded by a Vidi-grant of the Netherlands Organisation for Scientific Research, the FP7 HEALTH

program under the grant agreement FP7-HEALTH-F2-2012-305549, a grant of the Dutch Arthritis Foundation and the EU euroTEAM.

Competing interests None.

Provenance and peer review Not commissioned; externally peer reviewed.

Data sharing statement No additional data are available.

Open Access This is an Open Access article distributed in accordance with the Creative Commons Attribution Non Commercial (CC BY-NC 4.0) license, which permits others to distribute, remix, adapt, build upon this work non-commercially, and license their derivative works on different terms, provided the original work is properly cited and the use is non-commercial. See: <http://creativecommons.org/licenses/by-nc/4.0/>

REFERENCES

1. Nell VPK, Machold KP, Eberl G, *et al.* Benefit of very early referral and very early therapy with disease-modifying anti-rheumatic drugs in patients with early rheumatoid arthritis. *Rheumatology* 2004;43:906–14.
2. Van der Linden MPM, le Cessie S, Raza K, *et al.* Long-term impact of delay in assessment of patients with early arthritis. *Arthritis Rheum* 2010;62:3537–46.
3. Finckh A, Liang MH, van Herckenrode CM, *et al.* Long-term impact of early treatment on radiographic progression in rheumatoid arthritis: a meta-analysis. *Arthritis Care Res* 2006;55:864–72.
4. Green M, Marzo-Ortega H, McGonagle D, *et al.* Persistence of mild, early inflammatory arthritis: the importance of disease duration, rheumatoid factor, and the shared epitope. *Arthritis Rheum* 1999;42:2184–8.
5. Bosello S, Fedele AL, Peluso G, *et al.* Very early rheumatoid arthritis is the major predictor of major outcomes: clinical ACR remission and radiographic non-progression. *Ann Rheum Dis* 2011;70:1292–5.
6. Quinn MA, Emery P. Window of opportunity in early rheumatoid arthritis: possibility of altering the disease process with early intervention. *Clin Exp Rheumatol* 2003;21:S154–7.
7. Colebatch AN, Edwards CJ, Østergaard M, *et al.* EULAR recommendations for the use of imaging of the joints in the clinical management of rheumatoid arthritis. *Ann Rheum Dis* 2013;72:804–14.
8. Group AC of RRACTTFI, Group OM in RMRIIAW. Review: the utility of magnetic resonance imaging for assessing structural damage in randomized controlled trials in rheumatoid arthritis. *Arthritis Rheum* 2013;65:2513–23.
9. Steenbergen HW van, Nies JAB van, Huizinga TWJ, *et al.* Characterising arthralgia in the preclinical phase of rheumatoid arthritis using MRI. *Ann Rheum Dis* 2014. Published Online First: 9 Apr 2014. doi:10.1136/annrheumdis-2014-205522
10. Krabben A, Stomp W, Heijde DMFM van der, *et al.* MRI of hand and foot joints of patients with anticitrullinated peptide antibody positive arthralgia without clinical arthritis. *Ann Rheum Dis* 2013;72:1540–4.
11. Nakahara N, Uetani M, Hayashi K, *et al.* Gadolinium-enhanced MR imaging of the wrist in rheumatoid arthritis: value of fat suppression pulse sequences. *Skeletal Radiol* 1996;25:639–47.
12. Lindegaard H, Vallo J, Horslev-Petersen K, *et al.* Low field dedicated magnetic resonance imaging in untreated rheumatoid arthritis of recent onset. *Ann Rheum Dis* 2001;60:770–6.
13. Yoshioka H, Ito S, Handa S, *et al.* Low-field compact magnetic resonance imaging system for the hand and wrist in rheumatoid arthritis. *J Magn Reson Imaging* 2006;23:370–6.
14. Offidani A, Cellini A, Valeri G, *et al.* Subclinical joint involvement in psoriasis: magnetic resonance imaging and X-ray findings. *Acta Derm Venereol* 1998;78:463–5.
15. Beltran J, Caudill JL, Herman LA, *et al.* Rheumatoid arthritis: MR imaging manifestations. *Radiology* 1987;165:153–7.
16. Jorgensen C, Cyteval C, Anaya JM, *et al.* Sensitivity of magnetic resonance imaging of the wrist in very early rheumatoid arthritis. *Clin Exp Rheumatol* 1993;11:163–8.
17. Yanagawa A, Takano K, Nishioka K, *et al.* Clinical staging and gadolinium-DTPA enhanced images of the wrist in rheumatoid arthritis. *J Rheumatol* 1993;20:781–4.
18. Østergaard M, Gideon P, Sorensen K, *et al.* Scoring of synovial membrane hypertrophy and bone erosions by MR imaging in clinically active and inactive rheumatoid arthritis of the wrist. *Scand J Rheumatol* 1995;24:212–8.

19. Tonolli-Serabian I, Poet JL, Dufour M, *et al*. Magnetic resonance imaging of the wrist in rheumatoid arthritis: comparison with other inflammatory joint diseases and control subjects. *Clin Rheumatol* 1996;15:137–42.
20. Pierre-Jerome C, Bekkelund SI, Mellgren SI, *et al*. The rheumatoid wrist: bilateral MR analysis of the distribution of rheumatoid lesions in axial plan in a female population. *Clin Rheumatol* 1997;16:80–6.
21. Valeri G, Ferrara C, Ercolani P, *et al*. Tendon involvement in rheumatoid arthritis of the wrist: MRI findings. *Skeletal Radiol* 2001;30:138–43.
22. Partik B, Rand T, Pretterklieber ML, *et al*. Patterns of gadopentetate-enhanced MR imaging of radiocarpal joints of healthy subjects. *Am J Roentgenol* 2002;179:193–7.
23. Robertson PL, Page PJ, McColl GJ. Inflammatory arthritis-like and other MR findings in wrists of asymptomatic subjects. *Skeletal Radiol* 2006;35:754–64.
24. McGonagle D, Conaghan PG, O'Connor P, *et al*. The relationship between synovitis and bone changes in early untreated rheumatoid arthritis: a controlled magnetic resonance imaging study. *Arthritis Rheum* 1999;42:1706–11.
25. Klarlund M, Ostergaard M, Gideon P, *et al*. Wrist and finger joint MR imaging in rheumatoid arthritis. *Acta Radiol* 1999;40:400–9.
26. Vlychou M, Koutroumpas A, Alexiou I, *et al*. High-resolution ultrasonography and 3.0 T magnetic resonance imaging in erosive and nodal hand osteoarthritis: high frequency of erosions in nodal osteoarthritis. *Clin Rheumatol* 2013;32:755–62.
27. Xie X, Webber CE, Adachi JD, *et al*. Quantitative, small bore, 1 Tesla, magnetic resonance imaging of the hands of patients with rheumatoid arthritis. *Clin Exp Rheumatol* 2008;26:860–5.
28. Rastogi A, Kubassova O, Krasnoselskaia LV, *et al*. Evaluating automated dynamic contrast enhanced wrist 3 T MRI in healthy volunteers: One-year longitudinal observational study. *Eur J Radiol* 2013;82:1286–91.
29. Brown AK, Quinn MA, Karim Z, *et al*. Presence of significant synovitis in rheumatoid arthritis patients with disease-modifying antirheumatic drug-induced clinical remission: Evidence from an imaging study may explain structural progression. *Arthritis Rheum* 2006;54:3761–73.
30. Ejbjerg B, Narvestad E, Rostrup E, *et al*. Magnetic resonance imaging of wrist and finger joints in healthy subjects occasionally shows changes resembling erosions and synovitis as seen in rheumatoid arthritis. *Arthritis Rheum* 2004;50:1097–106.
31. Olech E, Crues JV, Yocum DE, *et al*. Bone marrow edema is the most specific finding for Rheumatoid Arthritis (RA) on noncontrast magnetic resonance imaging of the hands and wrists: a comparison of patients with RA and healthy controls. *J Rheumatol* 2010;37:265–74.
32. Parodi M, Silvestri E, Garlaschi G, *et al*. How normal are the hands of normal controls? A study with dedicated magnetic resonance imaging. *Clin Exp Rheumatol* 2006;24:134–41.
33. Ejbjerg BJ, Vestergaard A, Jacobsen S, *et al*. The smallest detectable difference and sensitivity to change of magnetic resonance imaging and radiographic scoring of structural joint damage in rheumatoid arthritis finger, wrist, and toe joints: a comparison of the omeract rheumatoid arthritis magnetic resonance imaging score applied to different joint combinations and the sharp/van der heijde radiographic score. *Arthritis Rheum* 2005;52:2300–6.
34. Duer-Jensen A, Hørslev-Petersen K, Hetland ML, *et al*. Bone edema on magnetic resonance imaging is an independent predictor of rheumatoid arthritis development in patients with early undifferentiated arthritis. *Arthritis Rheum* 2011;63:2192–202.
35. Cimmino MA, Parodi M, Zampogna G, *et al*. Polymyalgia rheumatica is associated with extensor tendon tenosynovitis but not with synovitis of the hands: a magnetic resonance imaging study. *Rheumatology* 2011;50:494–9.
36. Palosaari K, Vuotila J, Soini I, *et al*. Small bone lesions resembling erosions can frequently be found in bilateral wrist MRI of healthy individuals. *Scand J Rheumatol* 2009;38:450–4.
37. Döhn UM, Ejbjerg BJ, Hasselquist M, *et al*. Detection of bone erosions in rheumatoid arthritis wrist joints with magnetic resonance imaging, computed tomography and radiography. *Arthritis Res Ther* 2008;10:R25.
38. Döhn UM, Ejbjerg BJ, Court-Payen M, *et al*. Are bone erosions detected by magnetic resonance imaging and ultrasonography true erosions? A comparison with computed tomography in rheumatoid arthritis metacarpophalangeal joints. *Arthritis Res Ther* 2006;8:R110.
39. Tan AL, Tanner SF, Conaghan PG, *et al*. Role of metacarpophalangeal joint anatomic factors in the distribution of synovitis and bone erosion in early rheumatoid arthritis. *Arthritis Rheum* 2003;48:1214–22.
40. Miese F, Buchbender C, Scherer A, *et al*. Molecular imaging of cartilage damage of finger joints in early rheumatoid arthritis with delayed gadolinium-enhanced magnetic resonance imaging. *Arthritis Rheum* 2012;64:394–9.
41. Szkudlarek M, Klarlund M, Narvestad E, *et al*. Ultrasonography of the metacarpophalangeal and proximal interphalangeal joints in rheumatoid arthritis: a comparison with magnetic resonance imaging, conventional radiography and clinical examination. *Arthritis Res Ther* 2006;8:R52.
42. Ostergaard M, Conaghan PG, O'Connor P, *et al*. Reducing invasiveness, duration, and cost of magnetic resonance imaging in rheumatoid arthritis by omitting intravenous contrast injection — does it change the assessment of inflammatory and destructive joint changes by the OMERACT RAMRIS? *J Rheumatol* 2009;36:1806–10.
43. Brown AK, Conaghan PG, Karim Z, *et al*. An explanation for the apparent dissociation between clinical remission and continued structural deterioration in rheumatoid arthritis. *Arthritis Rheum* 2008;58:2958–67.
44. Ai T, Morelli JN, Hu X, *et al*. A historical overview of magnetic resonance imaging, focusing on technological innovations. *Investig Radiol* 2012;47:725–41.
45. Tamai M, Kawakami A, Uetani M, *et al*. Magnetic resonance imaging (MRI) detection of synovitis and bone lesions of the wrists and finger joints in early-stage rheumatoid arthritis: comparison of the accuracy of plain MRI-based findings and gadolinium-diethylenetriamine pentaacetic acid-enhanced MRI-based findings. *Mod Rheumatol* 2012;22:654–8.
46. Tehranzadeh J, Ashikyan O, Anavim A, *et al*. Enhanced MR imaging of tenosynovitis of hand and wrist in inflammatory arthritis. *Skeletal Radiol* 2006;35:814–22.