

Short Communication

Effect of Testosterone on Bone Mineral Gain: Observations of Male Patients with Growth Hormone Deficiency and Normal Gonadotropin Secretion

Sanae Kanazawa, Megumi Kojima, Satomi Koyama and Osamu Arisaka

Department of Pediatrics, Dokkyo University School of Medicine, Tochigi-ken, Japan

Key words: testosterone, growth hormone, bone mineral density, puberty

Introduction

Growth hormone (GH) and sex steroids are the major determinants of bone mineral density (BMD). Over the past several years, the dominant role of androgens in male bone physiology has been increasingly questioned as data have emerged suggesting an important role for estrogens in male skeletal development and homeostasis, but some reports elucidate the effects of androgen on skeletal development and maintenance (1-4). We consider that more clinical evidence on the effects of androgens on actual bone growth is needed to clarify their possible physiological roles in the regulation of bone formation and mineralization (5).

Recently, we encountered three pubertal boys with complete isolated GH deficiency (IGHD) whose cases had been detected and diagnosed after the patient had reached puberty. An analysis of the bone mineral status in these patients allowed us to determine the extent to which testosterone contributes to bone mineral gain in GH deficient children.

Patients and Methods

The profiles of three patients are shown in Table 1. A diagnosis of IGHD was made after the peak stimulated GH response to two provocative tests, including insulin-induced hypoglycemia, was less than 5.0 ng/ml in each patient. All pituitary hormones other than GH were normal. None of the patients showed evidence of a pituitary stalk transection on brain magnetic resonance imaging examination.

Patient 3 (Table 1) developed optic glioma at the age of 4 yr and received an operation and irradiation treatment. The presence of IGHD became evident (stimulated peak in GH response 3.3 ng/ml) in an endocrinological study performed at the age of 5 yr, but GH replacement therapy was not started because of the risk of tumor recurrence. Thereafter, pubic hair developed at the age of 6 yr in association with other secondary sexual characteristics and an increased growth velocity. The precocious puberty of the present patients was thought to result from sequela produced by brain irradiation, and the increased growth velocity of the patients was thought to result from the increase in testosterone.

We compared the BMD of the present three patients to those of six adult patients with GH deficiency (21-26 yr) who had received GH

Received: April 15, 2003

Accepted: March 5, 2004

Correspondence: Dr. Sanae Kanazawa, Department of Pediatrics, Dokkyo University School of Medicine, Mibu, Tochigi-ken 321-0293, Japan

E-mail: kanazawa@dokkyomed.ac.jp

Table 1 Profile of three patients with isolated growth hormone deficiency associated with pubertal development

Patients	1	2	3
Age at diagnosis (yr)	14.8	14.1	12.5
Bone age (yr)	13.1	13.5	14.5
Height SD score (SD)	-5.2	-3.5	-1.0
Genital Tanner Stage	III	III	IV
Testis volume (ml)	10	15	20
Testosterone (ng/dl)*	255	308	223
Stimulated growth** hormone peak (ng/ml)	4.1	2.5	0.6
IGF-1 (ng/ml)***	51	56	79
Causes****	①	①	②

*Testosterone: prepubertal level < 10 ng/dl, adult male range 350~800 ng/dl. **GH (peak value): normal \geq 10 ng/ml. ***IGF-1: normal range for age 13~14 yr, 178~686 ng/ml. ****①: Idiopathic (breech delivery). ②: Optic glioma (post operation).

treatment (0.3 U/kg/week) between the ages of 11.1 ± 2.3 (mean \pm SD) and 18.9 ± 1.5 yr. All 6 adult patients had exhibited gonadotropin deficiency without spontaneous pubertal development. Therefore androgen replacement therapy was started after 16–17 yr of age, they had received a testosterone enanthate 125 mg/dose every 4 wk for 2 to 4 yr. But the serum testosterone level may not have been enough to achieve normal genital development (genital development at the present examinations were Tanner stages III–IV). All patients had reached adult bone age.

To determine the BMD, dual-energy x-ray absorptiometry was performed with a Hologic QDR-2000 (Hologic Inc., Waltham, Mass.). Bone mineral content was measured in grams per centimeter, and the BMD (measured in grams per square centimeter) was calculated for the right femoral neck and the second, third and fourth lumbar (L2–4) vertebrae. The precision errors of the bone mineral content and BMD measurements were 0.5% and 1.0%, respectively. Normal Japanese boys, aged 13 to 15 yr, and Japanese adult

males aged 20–23 yr, with no systemic diseases, including renal disease and growth disorders, were used as age-matched controls (6, 7).

Results

The BMD of the lumbar vertebrae and the femoral neck in the 3 pediatric and 6 adult patients are shown in Fig. 1. The vertebral BMD of the three boy patients were within the normal range for a chronological age of 13–15 yr. The vertebral and femoral neck BMD reached the BMD range in the adult patients with GH and gonadotropin deficiencies.

Comments

In the present study, the BMD of the boy patients with IGHD who had already reached puberty was within the same range as that of the adult patients with GH and gonadotropin deficiencies who had completed GH replacement therapy. Several recent reports have demonstrated a relationship between GH deficiency (GHD) and impaired bone and mineral metabolism and have found GH therapy increase their BMD. Therefore, our observations indicate that testicular hormone plays an important role in increasing the BMD, even in a state of GH deficiency during childhood. Although testosterone may affect the bone after being converted to estrogen (1–3), a recent report suggests that androgen may play a direct role in the regulation of bone formation in men (8). Moreover women with androgen insensitivity syndrome (AIS) have 46,XY genotypes with androgen receptor abnormalities and have undergone gonadectomy, even if they were in excellent compliance with exogenous estrogen replacement therapy, the average lumbar spine BMD z-scores of complete AIS was significantly lower than zero but that of partial AIS who also have undergone gonadectomy and taking estrogen replacement therapy did not differ significantly from zero. This

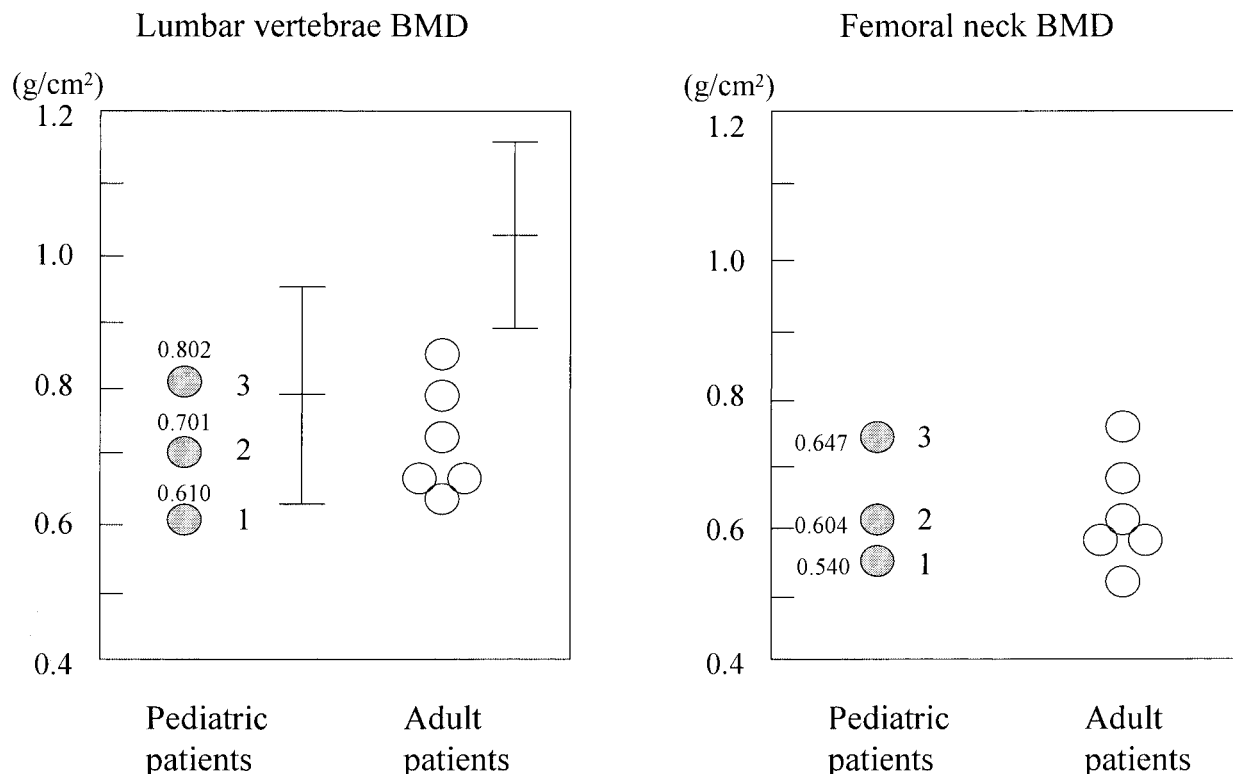


Fig. 1 Bone mineral density (BMD) values in three boys with isolated growth hormone deficiency (IGHD) associated with pubertal development and in adult patients with GH deficiency who had not developed spontaneous pubertal development. The bars in the panel indicate the normal range (mean \pm SD) of lumbar vertebrae BMD for that age. Actual BMD values and the numbers of patients are indicated.

result suggest a direct skeletal action of androgen (5).

In this respect, our findings are the exact opposite of those found in patients with precocious puberty who are treated with gonadotropin-releasing hormone (GnRH) analogues for gonadal steroids suppression. Patients with central precocious puberty or GH-deficient children who are diagnosed late in childhood often have a decreased height potential, and a strategy to increase their adult height is to use GnRH analogues or add GnRH analogues to the GH treatment regimen, thereby delaying puberty and slowing skeletal maturation. These treatments raise concern that the suppression of puberty with GnRH analogues might have an adverse effect on

bone mineral acquisition during puberty, although this strategy has recently been demonstrated to have no adverse effect on bone mineralization (9–11). From our observations, however, we propose that the build-up of bone mass in boys as a result of the effects of testosterone should not be neglected, and this issue remains to be further clarified.

References

1. Arisaka O, Hoshi M, Kanazawa S, Numata M, Kanno H, Negishi M, *et al.* Effect of adrenal androgen and estrogen on bone maturation and bone mineral density. *Metabolism* 2001;50:377–9.
2. Frank GR. The role of estrogen in pubertal skeletal physiology: epiphyseal maturation and mineralization of skeleton. *Acta Paediatr*

- 1995;84:627-30.
3. Khosla S. Oestrogen, bones and men: when testosterone just isn't enough. *Clin Endocrinol* 2002;56:291-3.
 4. Kanazawa S. Bone maturation and bone mineralization in precocious puberty: relation to estrogen receptor gene polymorphisms. *Clin Pediatr Endocrinol* 2002;11:11-7.
 5. Marcus R, Leary D, Schneider DL, Shane E, Favus M, Quigley CA. The contribution of testosterone to skeletal development and maintenance: lessons from the androgen insensitivity syndrome. *J Clin Endocrinol Metab* 2000;85:1032-7.
 6. Nishiyama S, Inomoto T, Tomoeda S, Matsuda I, Fukuoka H, Hirota H, *et al.* Spinal bone mineral density in 249 normal children—Evidence of sex differences and exercise. *J Jpn Pediatr Sci* 1994;98:23-6 (English abstract).
 7. Tokita A, Miura Y, Arisaka O. Estrogen receptor gene RFLP and peak bone density in Japanese. *J Bone Miner Res* 1996;11 (Suppl 1):s43.
 8. Leder BZ, Leblank KM, Schoenfeld DA, Eastell R, Finkelstein JS. Differential effect of androgens and estrogens on bone turnover in normal men. *J Clin Endocrinol Metab* 2003;88:204-10.
 9. Bertelloni S, Baroncelli GI, Ferdeghini M, Menchini-Fabris F, Saggese G. Final height, gonadal function and bone mineral density of adolescent males with central precocious puberty after therapy with gonadotropin-releasing hormone analogues. *Eur J Pediatr* 2000;159:369-74.
 10. Mericq V, Gajardo H, Eggers M, Avila A, Cassorla F. Effects of treatment with GH alone or in combination with LHRH analog on bone mineral density in pubertal GH-deficient patients. *J Clin Endocrinol Metab* 2002;87:84-9.
 11. Neely EK, Bachrach LK, Hintz RL, Habiby RL, Slemenda CW, Feezle L, *et al.* Bone mineral density during treatment of central precocious puberty. *J Pediatr* 1995;127:819-22.