

# Outcomes After Management of Subspine and Femoroacetabular Impingement Using a Direct Anterior Mini-Open Approach

Liu-yang Xu,\* MD, Kang-ming Chen,<sup>†</sup> MD, PhD, Jian-ping Peng,\* MD, PhD, Jun-feng Zhu,\* MD, PhD, Chao Shen,\*<sup>‡</sup> MD, PhD, and Xiao-dong Chen,\* MD, PhD

*Investigation performed at Xin-hua Hospital, affiliated with Shanghai Jiao Tong University School of Medicine, Shanghai, People's Republic of China*

**Background:** Subspine impingement (SSI) has been commonly managed with arthroscopic decompression. However, arthroscopic decompression is a demanding technique, as under- or over-resection of the anterior inferior iliac spine (AIIS) could lead to inferior outcomes. An anterior mini-open approach has also been used in the management of femoroacetabular impingement (FAI), and it could provide adequate visualization of the anterior hip joint without a long learning curve.

**Purpose/Hypothesis:** The objective of the current study was to compare the outcomes of SSI patients with FAI who underwent arthroscopic subspine decompression and osteoplasty with a group undergoing subspine decompression and osteoplasty using a modified direct anterior mini-open approach. It was hypothesized that there would be no significant difference in outcomes between the groups.

**Study Design:** Cohort study; Level of evidence, 3.

**Methods:** We reviewed the records of SSI patients who underwent decompression surgery (arthroscopic or mini-open) at our institution from June 1, 2015 to December 31, 2016. Both groups underwent the same postoperative rehabilitation protocol. Preoperative and 2-year postoperative patient-reported outcomes were compared using the modified Harris Hip Score (mHHS), International Hip Outcome Tool-33 (iHOT-33), and Hip Outcome Score—Activities of Daily Living (HOS-ADL). Major and minor complications as well as reoperation rates were recorded.

**Results:** Included were 47 patients (49 hips) who underwent subspine decompression using an anterior mini-open approach and 35 patients (35 hips) who underwent arthroscopic subspine decompression. There were no differences in demographic and radiological parameters between the groups, and patients in both groups showed significant improvement in all outcome scores at follow-up. The pre- to postoperative improvement in outcome scores was also similar between groups (mini-open vs arthroscopy: mHHS, 26.30 vs 27.04 [ $P = .783$ ]; iHOT-33, 35.76 vs 31.77 [ $P = .064$ ]; HOS-ADL, 26.09 vs 22.77 [ $P = .146$ ]). In the mini-open group, 10 of the 47 patients had temporary meralgia paresthetica, and fat liquefaction was found in 1 female patient. There were no reoperations in the mini-open group.

**Conclusion:** Subspine decompression using the anterior mini-open approach had similar outcomes to arthroscopic decompression in the management of SSI. The lateral femoral cutaneous nerve should be protected carefully during use of the anterior mini-open approach.

**Keywords:** anterior iliac inferior spine; anterior mini-open approach; extra-articular hip impingement; subspine impingement

It has been acknowledged that femoroacetabular impingement (FAI) can induce hip pain and cartilage degeneration in young, active patients.<sup>10</sup> Both open and arthroscopic surgery have shown satisfactory results in FAI patients.<sup>4,25,30</sup> With improvements in instruments and techniques, the results of FAI treatment using arthroscopy have become more satisfactory. However, several studies

have reported that arthroscopy fails in some patients if extra-articular deformities are left untreated.<sup>11-13,16,17</sup> The most common extra-articular deformity is subspine impingement (SSI).<sup>1,16</sup>

The subspine space is a concave, smooth space between the caudad border of the anterior inferior iliac spine (AIIS) and the acetabular rim, which provides the recoil area for anterior hip soft tissue during hip flexion.<sup>6</sup> An abnormal AIIS caudad border can decrease the subspine space and trigger SSI between the AIIS and femoral head-neck junction.<sup>14</sup> Furthermore, SSI is usually combined with FAI,

The Orthopaedic Journal of Sports Medicine, 9(12), 23259671211055723

DOI: 10.1177/23259671211055723

© The Author(s) 2021

This open-access article is published and distributed under the Creative Commons Attribution - NonCommercial - No Derivatives License (<https://creativecommons.org/licenses/by-nc-nd/4.0/>), which permits the noncommercial use, distribution, and reproduction of the article in any medium, provided the original author and source are credited. You may not alter, transform, or build upon this article without the permission of the Author(s). For article reuse guidelines, please visit SAGE's website at <http://www.sagepub.com/journals-permissions>.

thereby inducing labral tearing and impairment of the femoral cartilage.<sup>2</sup> There have been reports suggesting that arthroscopic decompression of the AIIS and femoroplasty results in significant improvement in hip function.<sup>6,23,24,33</sup> However, arthroscopic subspine decompression is a demanding technique. Under- or over-resection of the subspine because of poor visualization could lead to inferior outcomes.<sup>32</sup>

The direct anterior mini-open approach has been introduced in the treatment of FAI over recent decades.<sup>4,8,18,30</sup> This approach takes advantage of an intermuscular approach with a limited incision and has shown good results with rapid recovery in FAI patients. Compared with arthroscopy and hip surgical dislocation, the mini-open anterior approach requires neither excessive hip traction nor extensive surgical exposure for hip dislocation.<sup>7</sup> This approach provides direct visualization of the insertion of the direct head of the rectus femoris and anterior capsule. Therefore, adequate subspine decompression can be confirmed without fluoroscopic imaging. The risk of incomplete capsule repair and transection of the rectus femoris could also be minimized using this approach. However, there have been no reports on the outcomes of SSI management using the anterior mini-open approach.

The objective of the current study was to compare the outcomes of SSI patients with FAI who underwent arthroscopic subspine decompression with a group undergoing subspine decompression using a modified direct anterior mini-open approach. It was hypothesized that there would be no significant difference in outcomes between the arthroscopic and mini-open group.

## METHODS

The diagnosis of SSI in our hospital depended on the patient history, findings of physical and radiological examinations, and an extra-articular subspine corticosteroid injection. Typically, patients with SSI complained of anterior hip pain around the AIIS with the hip under passive hyperflexion with or without internal rotation. SSI tests, which were performed in supine position with passive maximum hip flexion with neutral adduction, could reproduce anterior hip pain in patients with SSI.<sup>28</sup> Patients with SSI had AIIS hypertrophy according to the classification of the AIIS in 3-dimensional (3-D) computed tomography (CT) imaging (Figure 1).<sup>13</sup> Once SSI was highly suspected, patients received an extra-articular hip injection for diagnostic purposes. The injection mixture consisted of 40 mg of

betamethasone and 4 mL of lidocaine. The injection was performed using fluoroscopy to place the mixture at the intersection between the borderline of the AIIS and the iliocapsularis. Only those patients who experienced a significant relief of the anterior groin pain (more than 50%) after the extra-articular subspine injection received a final diagnosis of SSI.

With the diagnosis of SSI, patients then received hip-specific physical therapy for no less than 12 weeks. If physical therapy failed, surgical interventions were indicated. In our institution, subspine decompression was performed with an arthroscopic or mini-open approach. Before surgery, each patient with SSI was fully informed about both the advantages and potential complications of the 2 methods and made their decision.

## Study Patients

After approval was obtained from the institutional review board of our hospital, patients with SSI who underwent decompression surgery from June 2015 to December 2016 were reviewed retrospectively. Inclusion criteria consisted of symptomatic patients with SSI who underwent surgical treatment and had at least 2 years of follow-up. We excluded patients with a lateral center-edge angle less than 20°, a positive anterior apprehension test, other extra-articular impingement (such as greater trochanter impingement or ischiofemoral impingement), and advanced osteoarthritis (Tönnis grade  $\geq 1$ ).

A total of 95 patients were included in the current study. Of these, 84 patients fulfilled the criteria; 2 were lost to follow-up and excluded from the current study. As such, 82 SSI patients who underwent subspine decompression were included in the final analysis, with 47 undergoing the anterior mini-open approach and 35 receiving arthroscopic subspine decompression (Figure 2). In the mini-open group, 21 patients (19 female and 2 male, 21 hips) had a history of failed hip arthroscopic surgery. All patients needed revision surgery because of a lack of subspine decompression.

## Surgical Techniques

All mini-open decompression procedures were performed by the same senior author (C.S.), and all arthroscopic decompression were performed by another well-trained arthroscopic physician (J.-p.P.). The approach was similar to the anterior mini-open approach described by Cohen et al<sup>7</sup> in 2012. Patients were in the supine position on a normal operating table. After preparation, a 5-cm incision

†Address correspondence to Chao Shen, MD, PhD, Department of Orthopedics, Xin-hua Hospital, 1665 Kongjiang Road, Shanghai, 200092, People's Republic of China (email: shenchao@xinhua.com.cn).

\*Department of Orthopedics, Xin-hua Hospital, affiliated with Shanghai Jiao Tong University School of Medicine, Shanghai, People's Republic of China.

†Department of Orthopedics, Huashan Hospital, Fudan University School of Medicine, Shanghai, People's Republic of China.

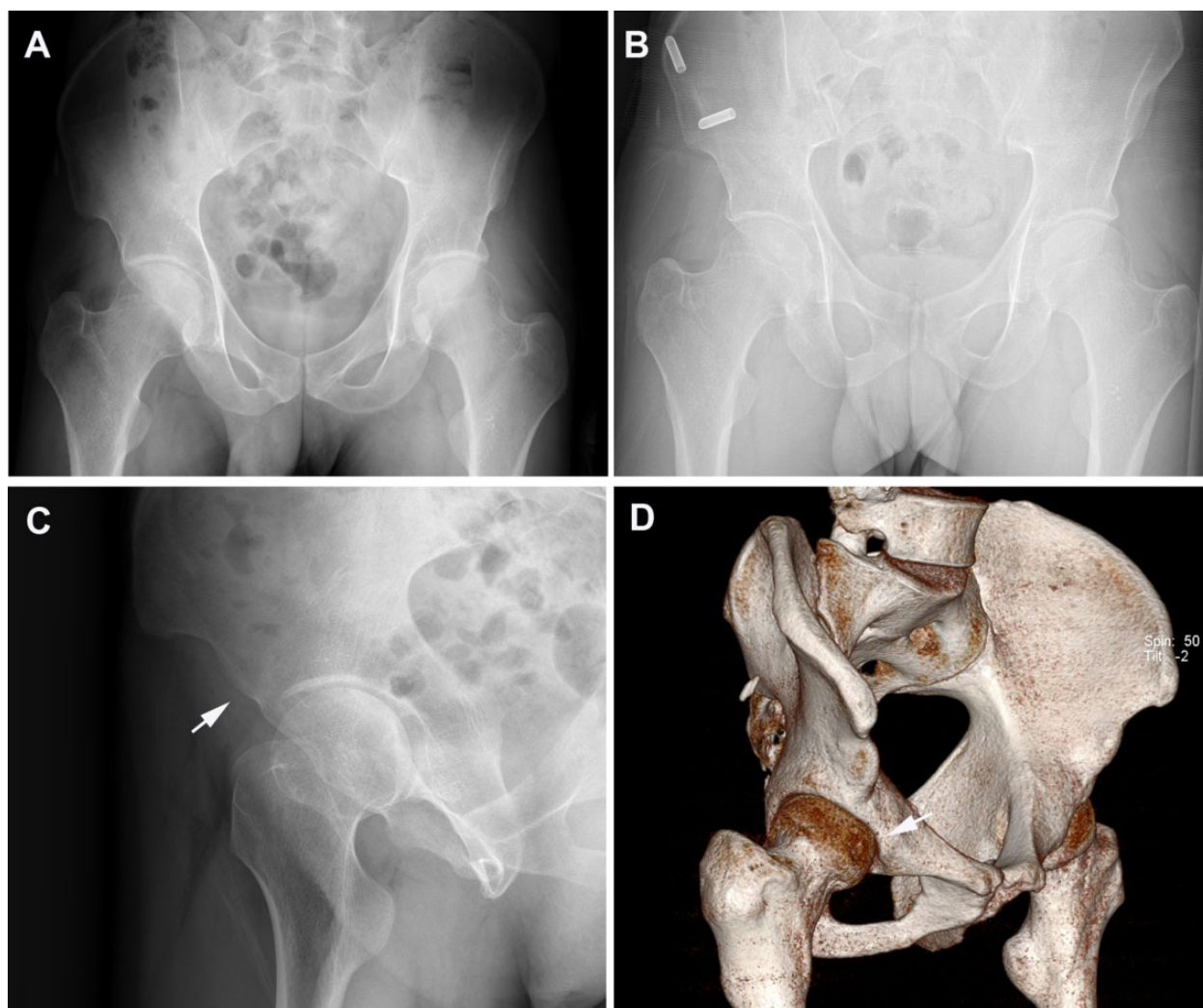
L.-y.X. and K.-m.C. contributed equally to this study.

C.S. and X.-d.C. contributed equally to this study.

Final revision submitted July 16, 2021; accepted August 4, 2021.

One or more of the authors has declared the following potential conflict of interest or source of funding: the study was supported by National Natural Science Foundation of China (Project number 82172471). AOSSM checks author disclosures against the Open Payments Database (OPD). AOSSM has not conducted an independent investigation on the OPD and disclaims any liability or responsibility relating thereto.

Ethical approval for this study was obtained from Xin-hua Hospital.



**Figure 1.** Imaging material of a 28-year-old male patient with subspine impingement: (A) supine anteroposterior view of pelvis, (B) standing anteroposterior view of pelvis, and (C) false profile view of right hip; the white arrow indicates anterior inferior iliac spine (AIIS) hypertrophy. (D) Three-dimensional reconstruction of pelvis with femoral torsion measurement, indicating type 2 AIIS impingement in the right hip (arrow).

was made 2 cm distal to the inferior border of the anterior superior iliac spine and parallel to the sartorius. The deep fascia over the sartorius and tensor fascia lata muscle was divided, and the tensor fascia lata was split and retracted laterally to expose the AIIS and iliocapsularis. The remaining sartorius and underlying psoas tendon were retracted medially to protect the femoral nerve and artery. The lateral femoral cutaneous nerve (LFCN) was kept intact in the interval between the fascia lata and bundle of sartorius muscle. The iliocapsularis was detached sharply from the anterior capsule along the femoris rectus to expose the anterior capsule and subspine space.

A T-shaped capsulotomy was then performed to expose the acetabular rim, labrum, and femoral head (Figure 3). The intact labrum was identified with a nerve hook. The labrum was repaired using anchor sutures if needed. The cartilage lesion in the anterior part of the femoral head

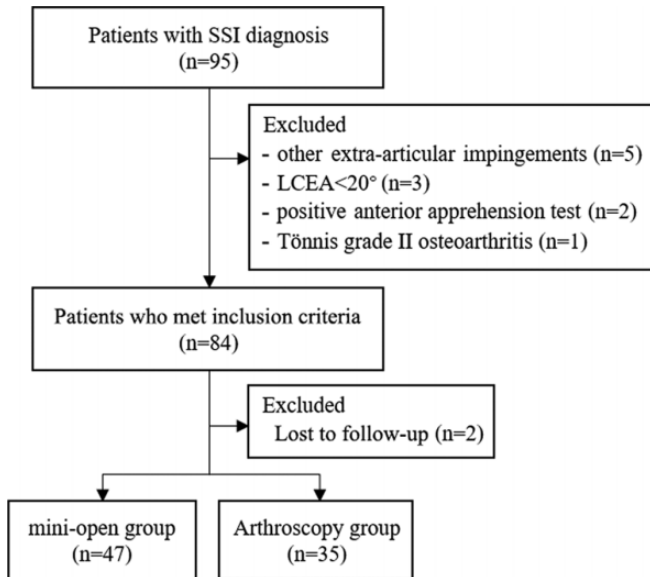
was investigated with manual traction of the extremity. The distal section of the head-neck junction was also checked. Femoroplasty was performed with a bur under direct visualization. The capsule and iliocapsularis muscle were detached carefully from the acetabular rim. A retractor was placed between the femoris rectus and the acetabular rim to protect the insertion of the direct head of the femoris rectus. Subspine decompression was performed between the inferior pole of the AIIS and the acetabular rim, and the subspine space was recreated according to the preoperative 3-D CT reconstruction using a bur. Then, the hip joint was thoroughly irrigated and the capsule carefully closed.

The arthroscopic procedures were performed similarly to previous studies.<sup>9,24,32</sup> Anterolateral and midanterior portals were used to perform femoroplasty, acetabuloplasty, and labral repair. Subspine decompression was performed

under the guide of fluoroscopy. Capsular closure was performed in every patient.

### Assessment of Outcomes

Preoperatively, all patients underwent radiographic evaluation. In addition, all patients completed the modified Harris Hip Score (mHHS), International Hip Outcome Tool—3 (iHOT—33), and Hip Outcome Score—Activities of Daily Living (HOS—ADL), both preoperatively and at the 2-year follow-up. These scores have been used in the investigation



**Figure 2.** Flowchart of patient inclusion in the study. SSI, subspine impingement; LCEA, lateral center-edge angle.

of hip function in several studies.<sup>26</sup> The mHHS investigates domains of hip function, pain, and hip range of motion with 10 items.<sup>3</sup> The iHOT—33 consists of 33 items covering symptoms, functional limitations, and lifestyle concerns and has been proven to be a valid, reliable tool.<sup>22,34</sup> The HOS—ADL is also a commonly used self-reported instrument with evidence of reliability and responsiveness for hip preserving procedures.<sup>21</sup> Finally, major and minor complications, along with reoperation rates, were recorded in both groups.

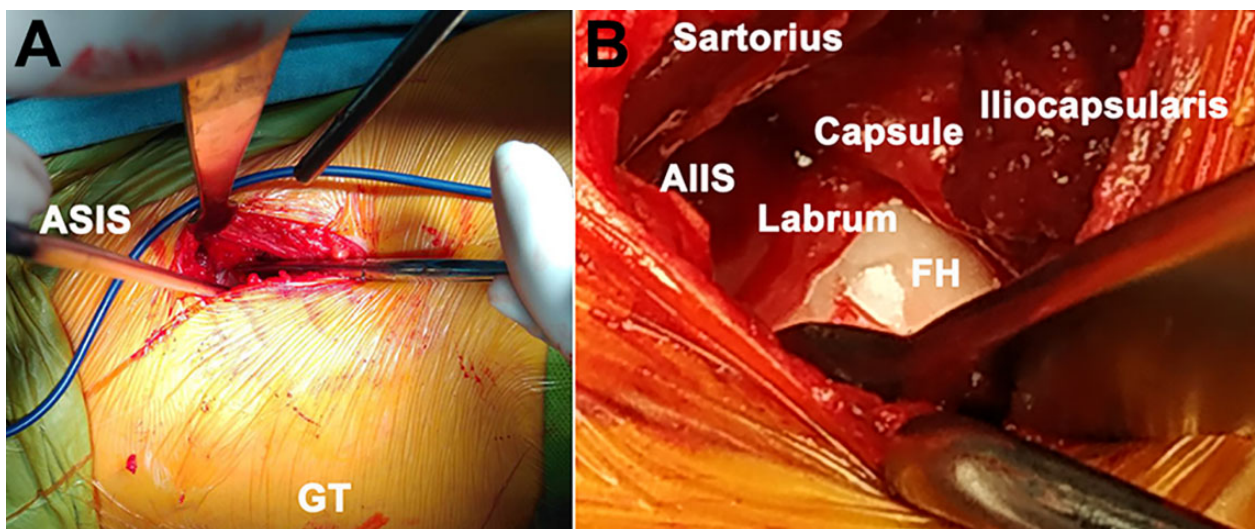
### Statistical Analysis

For overall group comparisons, the independent *t* test was used for continuous variables, and the Pearson chi-square test was used for categorical variables. Preoperative and postoperative mHHS, iHOT—33, and HOS—ADL scores in each group were compared using paired-samples Student *t* test. The mean changes in mHHS, iHOT—33, and HOS—ADL scores between the mini-open group and arthroscopy group were compared using independent *t* test. *P* < .05 was considered significant. Statistical analyses were performed using SPSS Version 20 software (SPSS).

### RESULTS

A total of 47 patients (49 hips) underwent subspine decompression surgery using an anterior mini-open approach, and 35 patients (35 hips) underwent arthroscopic subspine decompression (Figure 3). Demographic and radiographic information for the mini-open and arthroscopy groups are provided in Table 1. There were no significant differences between the groups regarding demographic and radiographic characteristics (Table 1).

During the operation, cam deformities were detected in all included patients, and osteoplasty of the femoral head-



**Figure 3.** Anterior mini-open approach to explore the anterior subspinal space and femoral neck. (A) The mini-open approach incision 2 cm distal to the inferior border of the ASIS and parallel to the sartorius. (B) After detaching the iliocapsularis muscle, a T-shaped capsulotomy was made to explore the subspinal space, acetabular rim, labrum, and femoral neck. AIIS, anterior inferior iliac spine; ASIS, anterior superior iliac spine; FH, femoral head; GT, greater trochanter.

TABLE 1  
Comparison of Demographic and Radiographic Information Between Groups<sup>a</sup>

	Mini-open (n = 47 patients, 49 hips)	Arthroscopy (n = 35 patients, 35 hips)	P
Demographic information			
Sex, male/female, n	21/26	14/21	.673
Age, years	30.53 ± 4.93 (28.24-33.17)	27.93 ± 3.84 (26.10-30.00)	.118
BMI, kg/m <sup>2</sup>	23.82 ± 3.04 (22.95-24.64)	22.92 ± 2.50 (21.96-23.87)	.209
Side involved, left/right, n	27/22	16/19	.293
Radiographic information			
LCEA, deg	28.84 ± 5.01 (27.38-30.24)	30.35 ± 2.87 (29.33-31.50)	.115
Anterior coverage, %	22.68 ± 4.09 (21.36-23.81)	22.77 ± 3.39 (21.46-24.06)	.927
Posterior coverage (%)	42.86 ± 4.23 (40.90-44.68)	41.58 ± 6.14 (39.21-44.00)	.406
Acetabular index, deg	2.69 ± 4.10 (1.49-3.88)	3.81 ± 1.79 (3.21-4.58)	.120
Femoral anteversion, deg	20.14 ± 5.97 (18.15-21.73)	19.42 ± 4.02 (17.79-20.89)	.591

<sup>a</sup>Data are reported as mean ± SD (range) unless otherwise indicated. BMI, body mass index; LCEA, lateral center-edge angle.

TABLE 2  
Intraoperative Findings<sup>a</sup>

	Mini-Open Group (n = 49 hips)	Arthroscopy Group (n = 35 hips)
Labral tear	35	31
Outerbridge score		
Acetabulum		
0	46	31
I	3	4
Femur		
I	48	32
II	1	3
Capsule closure	49	35
Acetabuloplasty	6	9
Femoroplasty	49	35
Subspine decompression	49	35

<sup>a</sup>Data are reported as number of hips.

neck junction was performed in both groups. The intraoperative findings in both groups are provided in Table 2. Labral tearing or ossification was detected in 35 hips in the mini-open group and 31 hips in the arthroscopic group, and all of these hips underwent labral repair using 1 or 2 bioabsorbable suture anchors.

### Patient-Reported Outcomes

At the 2-year follow-up, there were significant improvements in the HOS-ADL, mHHS, and iHOT-33 scores between preoperative and postoperative follow-up evaluations in both groups (all  $P < .001$ ) (Table 3). There was no significant difference between the mini-open and arthroscopy groups in the amount of improvement in scores (Table 4).

### Complications and Reoperations

The total complications rate was 23.4% (11/47) in the mini-open group and 22.8% (8/35) in the arthroscopy group. In the mini-open group, 10 of the 47 patients had transient

meralgia paresthetica after surgery, which resolved in 9 patients within 2 months of surgery. Paresthesia in the distribution of the LFCN, seen in 1 patient, disappeared after 14 months. Fat liquefaction was found in 1 female patient and resolved after debridement. In the arthroscopy group, 4 cases had transient pudendal nerve paresthesias that resolved within 6 to 8 weeks postoperatively.

Major complications included 3 patients in the arthroscopy group who underwent revision surgery because of inadequate subspine decompression. There was 1 patient in the arthroscopic group who felt weakness during hip flexion due to over-resection of the inferior border of the AIIS. The patient underwent open surgery to refix the direct head of the rectus femoris. There were no cases of conversion to hip joint arthroplasty in either group.

### DISCUSSION

The purpose of the current study was to investigate outcomes after subspine decompression and osteoplasty using an anterior mini-open approach in comparison with a control group undergoing arthroscopic treatment. Our results indicated that patients who underwent SSI decompression using a modified direct anterior mini-open approach showed significant postoperative improvement in functional outcomes. The results also suggested that patients in the mini-open group had similar improvements in patient-reported outcome measures compared with patients in the arthroscopic decompression group. No major complication or reoperation was recorded in the mini-open group. Therefore, our results suggest that use of the modified anterior mini-open approach could have similar outcomes compared with the arthroscopic technique in the treatment of SSI with FAI.

SSI was first introduced in 2008 by Pan et al<sup>27</sup> and managed using open decompression, with improved outcomes. Although surgical hip dislocation surgery could be used to treat most cases of FAI, no studies were published regarding management of SSI using surgical hip dislocation methods. Recently, with the development of hip arthroscopic techniques, most cases of SSI have been managed with

TABLE 3  
Comparison of Preoperative and 2-Year Postoperative Patient-Reported Outcome Scores in Both Groups<sup>a</sup>

	Preoperative	Postoperative	P
Mini-open			
mHHS	53.30 ± 8.35 (50.81-55.71)	79.59 ± 10.79 (76.33-82.76)	<.001
iHOT-33	46.69 ± 7.52 (44.32-48.89)	82.46 ± 5.71 (80.78-84.16)	<.001
HOS-ADL	57.11 ± 7.61 (54.85-59.35)	83.2 ± 4.43 (81.92-84.45)	<.001
Arthroscopy			
mHHS	50.58 ± 6.01 (48.40-53.16)	77.88 ± 6.54 (75.37-80.33)	<.001
iHOT-33	48.73 ± 5.10 (46.79-50.55)	80.50 ± 3.49 (78.07-81.78)	<.001
HOS-ADL	58.54 ± 8.14 (55.35-61.61)	81.31 ± 4.88 (79.44-83.07)	<.001

<sup>a</sup>Data are presented as mean ± SD (95% CI). Bold P values indicate statistically significant difference between groups ( $P < .05$ ). HOS-ADL, Hip Outcome Score-Activities of Daily Living; iHOT-33, International Hip Outcome Tool-33; mHHS, modified Harris Hip Score. ;

TABLE 4  
Comparison of the Improvement in Patient-Reported Outcome Scores Between Groups<sup>a</sup>

	Mini-Open	Arthroscopy	P
mHHS	26.30 ± 14.81 (21.84-30.65)	27.04 ± 7.59 (23.96-29.77)	.783
iHOT-33	35.76 ± 9.54 (33.05-38.54)	31.77 ± 6.64 (29.07-34.38)	.064
HOS-ADL	26.09 ± 8.68 (23.59-28.58)	22.77 ± 9.84 (18.88-26.64)	.146

<sup>a</sup>Data are presented as mean ± SD (95% CI). HOS-ADL, Hip Outcome Score-Activities of Daily Living; iHOT-33, International Hip Outcome Tool-33; mHHS, modified Harris Hip Score.

arthroscopic decompression. These SSI patients have been reported to recover quickly, with satisfactory functional outcomes.<sup>6,16,23,24</sup> However, in the current study, there were a few active patients with SSI whose symptoms persisted after inadequate arthroscopic decompression. Furthermore, as SSI involves extra-articular abnormalities, it has become the most common risk factor for failure of hip arthroscopic surgery.<sup>16</sup> In addition, extra-articular deformities, such as lower femoral torsion, could also trigger SSI even in normal AIIS.<sup>1</sup> Therefore, questions in the management of SSI still remain.

Several studies have reported good results in the management of patients with FAI using an anterior Hueter approach.<sup>5,20,29,30</sup> However, the anterior Hueter approach might make it difficult to access the subspine space. Cohen et al<sup>7</sup> managed FAI in athletes using a direct mini-open approach and demonstrated significant improvement in functional outcomes. This direct anterior mini-open approach made it possible to expose the anterior capsule through the interval between the tensor fascia lata and sartorius muscles. Because the muscular structures remained intact during surgery, patients needed only a short recovery period before returning to sports activities. The satisfactory functional outcomes prompted us to think about the application of this approach for patients with SSI. In the current study, this approach was also used to expose the subspine space. Both subspine space reconstruction and osteoplasty could be performed accurately with this approach under direct visualization, even in the distal portion of the medial femoral neck.<sup>15</sup> Moreover, the capsule could be carefully repaired during surgery so that all structures maintaining the anterior stability of the hip

joint remained intact postoperatively. No anterior micro-instability was detected in any of the patients 6 months after surgery. Therefore, we consider that patients with SSI and FAI could be managed with this modified anterior mini-open approach.

SSI involves abnormal morphologies of both the acetabulum and proximal femur.<sup>1</sup> Because hypertrophy of the AIIS could contribute to the crossover sign in anteroposterior pelvic radiographs, patients with SSI might be misdiagnosed with and treated for local pincer impingement.<sup>15</sup> Unlike in classic pincer impingement, the lesion on the femoral side might be located more distal to the articular cartilage.<sup>1,15</sup> Therefore, more distal exposure is needed in patients with SSI to perform an ideal femoroplasty, especially in patients with retroversion of the femur.<sup>1,19,31</sup> With the anterior direct mini-open approach, the anterior portion of the femoral neck could be fully exposed, and the head-neck offset could be re-established. On the acetabular side, the subspine space could be re-created without additional injury to the direct head of the rectus femoris (Appendix Figure A1). In the current study, the patients were satisfied with the improvement in hip flexion postoperatively. Thus, the functional outcomes indicated that the anterior mini-open approach might be a useful tool in the management of SSI.

Most of the complications in the mini-open group were minor. LFCN still accounted for most complications of the anterior mini-open approach. In the current study, approximately 21% of patients had transient meralgia paresthetica in the first 2 months after surgery. No revision was found in the mini-open approach group at 24 month follow-up. Therefore, the results indicated that the LFCN

should be protected carefully when using the anterior mini-open approach.

Certain limitations of the current study should be mentioned, the first being the study design. This was a retrospective study with a limited sample size (N = 82) at a single center. Future research involving data from more centers and adequate samples would be our next target. The follow-up time was also short; long-term study will be needed to determine clinical outcomes in the treatment of SSI using the anterior mini-open approach. In addition, 21 patients in the mini-open group had received previous arthroscopic treatment, thereby increasing the potential soft tissue complication rate in this group. Future studies should address this limitation through detailed patient selection.

## CONCLUSION

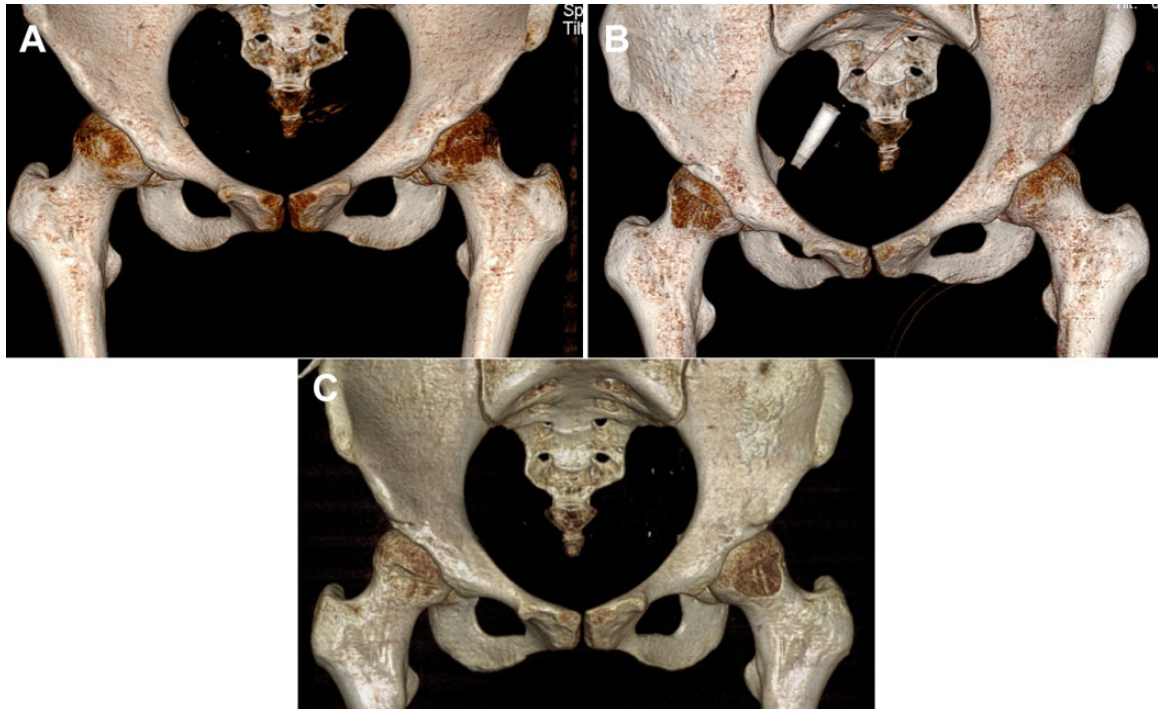Overall, the treatment outcomes of patients with SSI and FAI following use of the anterior mini-open approach were similar to those of patients undergoing arthroscopic decompression and osteoplasty. LFCN should be protected carefully during use of the anterior mini-open approach in the management of SSI and FAI.

## REFERENCES

- Aguilera-Bohorquez B, Brugiatti M, Coaquira R, Cantor E. Frequency of subspine impingement in patients with femoroacetabular impingement evaluated with a 3-dimensional dynamic study. *Arthroscopy*. 2019;35(1):91-96.
- Amar E, Warschawski Y, Sharfman ZT, et al. Pathological findings in patients with low anterior inferior iliac spine impingement. *Surg Radiol Anat*. 2016;38(5):569-575.
- Aprato A, Jayasekera N, Villar RN. Does the modified Harris Hip Score reflect patient satisfaction after hip arthroscopy? *Am J Sports Med*. 2012;40(11):2557-2560.
- Barton C, Banga K, Beaulé PE. Anterior Hueter approach in the treatment of femoroacetabular impingement: rationale and technique. *Orthop Clin North Am*. 2009;40(3):389-395.
- Bellotti V, Cardenas C, Astarita E, et al. Mini-open approach for femoroacetabular impingement: 10 years experience and evolved indications. *Hip Int*. 2016;26(suppl 1):38-42.
- Carton P, Filan D. Anterior inferior iliac spine (AIIS) and subspine hip impingement. *Muscles Ligaments Tendons J*. 2016;6(3):324-336.
- Cohen SB, Huang R, Ciccotti MG, Dodson CC, Parvizi J. Treatment of femoroacetabular impingement in athletes using a mini-direct anterior approach. *Am J Sports Med*. 2012;40(7):1620-1627.
- Fink B, Sebens P. [Treatment of femoroacetabular impingement using a minimally invasive anterior approach]. Article in German. *Oper Orthop Traumatol*. 2010;22(1):17-27.
- Flores SE, Chambers CC, Borak KR, Zhang AL. Arthroscopic treatment of acetabular retroversion with acetabuloplasty and subspine decompression: a matched comparison with patients undergoing arthroscopic treatment for focal pincer-type femoroacetabular impingement. *Orthop J Sports Med*. 2018;6(7):2325967118783741.
- Ganz R, Parvizi J, Beck M, et al. Femoroacetabular impingement: a cause for osteoarthritis of the hip. *Clin Orthop Relat Res*. 2003;417:112-120.
- Hapa O, Bedi A, Gursan O, et al. Anatomic footprint of the direct head of the rectus femoris origin: cadaveric study and clinical series of hips after arthroscopic anterior inferior iliac spine/subspine decompression. *Arthroscopy*. 2013;29(12):1932-1940.
- Hetsroni I, Larson CM, Dela Torre K, et al. Anterior inferior iliac spine deformity as an extra-articular source for hip impingement: a series of 10 patients treated with arthroscopic decompression. *Arthroscopy*. 2012;28(11):1644-1653.
- Hetsroni I, Poultides L, Bedi A, Larson CM, Kelly BT. Anterior inferior iliac spine morphology correlates with hip range of motion: a classification system and dynamic model. *Clin Orthop Relat Res*. 2013;471(8):2497-2503.
- Karns MR, Adeyemi TF, Stephens AR, et al. Revisiting the antero-inferior iliac spine: is the subspine pathologic? A clinical and radiographic evaluation. *Clin Orthop Relat Res*. 2018;476(7):1494-1502.
- Larson CM. Editorial commentary: subspine hip abnormalities: exploring the difference between "morphology" and "impingement." *Arthroscopy*. 2019;35(1):97-98.
- Larson CM, Giveans MR, Samuelson KM, Stone RM, Bedi A. Arthroscopic hip revision surgery for residual femoroacetabular impingement (FAI): surgical outcomes compared with a matched cohort after primary arthroscopic FAI correction. *Am J Sports Med*. 2014;42(8):1785-1790.
- Larson CM, Kelly BT, Stone RM. Making a case for anterior inferior iliac spine/subspine hip impingement: three representative case reports and proposed concept. *Arthroscopy*. 2011;27(12):1732-1737.
- Laude F, Sariali E. [Treatment of FAI via a minimally invasive ventral approach with arthroscopic assistance. Technique and midterm results]. Article in German. *Orthopade*. 2009;38(5):419-428.
- Lerch TD, Boschung A, Todorski IAS, et al. Femoroacetabular impingement patients with decreased femoral version have different impingement locations and intra- and extraarticular anterior subspine FAI on 3D-CT-based impingement simulation: implications for hip arthroscopy. *Am J Sports Med*. 2019;47(13):3120-3132.
- Malagelada F, Del Carmen VA, Barke SJ, Guirao Cano L, Pleguezuelos Cobo E. The anterior mini-open approach for femoroacetabular impingement: gait and functional assessment at one year post-surgery. *Ann Phys Rehabil Med*. 2015;58(2):60-65.
- Martin RL, Philippon MJ. Evidence of validity for the Hip Outcome Score in hip arthroscopy. *Arthroscopy*. 2007;23(8):822-826.
- Mohtadi NG, Griffin DR, Pedersen ME, et al. The development and validation of a self-administered quality-of-life outcome measure for young, active patients with symptomatic hip disease: the International Hip Outcome Tool (iHOT-33). *Arthroscopy*. 2012;28(5):595-605; quiz 606-510 e591.
- Nawabi DH, Degen RM, Fields KG, et al. Anterior inferior iliac spine morphology and outcomes of hip arthroscopy in soccer athletes: a comparison to nonkicking athletes. *Arthroscopy*. 2017;33(4):758-765.
- Nwachukwu BU, Chang B, Fields K, et al. Outcomes for arthroscopic treatment of anterior inferior iliac spine (subspine) hip impingement. *Orthop J Sports Med*. 2017;5(8):2325967117723109.
- Nwachukwu BU, Rebolledo BJ, McCormick F, et al. Arthroscopic versus open treatment of femoroacetabular impingement: a systematic review of medium- to long-term outcomes. *Am J Sports Med*. 2016;44(4):1062-1068.
- Oji NM, Jansson H, Bradley KE, Feeley BT, Zhang AL. Comparing patient-reported outcome measurements for femoroacetabular impingement syndrome. *Am J Sports Med*. 2021;49(6):1578-1588.
- Pan H, Kawanabe K, Akiyama H, et al. Operative treatment of hip impingement caused by hypertrophy of the anterior inferior iliac spine. *J Bone Joint Surg Br*. 2008;90(5):677-679.
- Poultides LA, Bedi A, Kelly BT. An algorithmic approach to mechanical hip pain. *HSS J*. 2012;8(3):213-224.
- Ribas M, Ledesma R, Cardenas C, et al. Clinical results after anterior mini-open approach for femoroacetabular impingement in early degenerative stage. *Hip Int*. 2010;20(suppl 7):S36-S42.
- Ribas M, Marin-Pena OR, Regenbrecht B, De La Torre B, Vilarrubias JM. Hip osteoplasty by an anterior minimally invasive approach for active patients with femoroacetabular impingement. *Hip Int*. 2007;17(2):91-98.

31. Samim M, Walter W, Gyftopoulos S, Poultsides L, Youm T. MRI assessment of subspine impingement: features beyond the anterior inferior iliac spine morphology. *Radiology*. 2019;293(2):412-421.
32. Sharfman ZT, Grundshtein A, Paret M, et al. Surgical technique: arthroscopic osteoplasty of anterior inferior iliac spine for femoroacetabular impingement. *Arthrosc Tech*. 2016;5(3):e601-e606.
33. Tateishi S, Onishi Y, Suzuki H, et al. Arthroscopic anterior inferior iliac spine decompression does not alter postoperative muscle strength. *Knee Surg Sports Traumatol Arthrosc*. 2020;28(9):2763-2771.
34. Thorborg K, Tijssen M, Habets B, et al. Patient-reported outcome (PRO) questionnaires for young to middle-aged adults with hip and groin disability: a systematic review of the clinimetric evidence. *Br J Sports Med*. 2015;49(12):812.

## APPENDIX



**Figure A1.** Pre- and postoperative pelvic 3-dimensional reconstructed computed tomography images of a 22-year-old female patient with bilateral subspine impingement. (A) Image after failed left hip arthroscopic surgery without subspine decompression. (B) We performed subspine decompression and femoral osteoplasty in the right hip using a mini-open approach. (C) Ten months later, the patient had recovered, and we performed revision subspine decompression surgery in her left hip using a mini-open approach.