



# Abrupt worsening of occult IgA nephropathy after the first dose of SARS-CoV-2 vaccination

Yoko Fujita<sup>1</sup> · Keisuke Yoshida<sup>1</sup> · Daisuke Ichikawa<sup>1</sup> · Yugo Shibagaki<sup>1</sup> · Masahiko Yazawa<sup>1</sup>

Received: 24 September 2021 / Accepted: 27 November 2021 / Published online: 6 January 2022  
© Japanese Society of Nephrology 2021

## Abstract

Here, we report a case of abrupt onset of gross hematuria and nephrotic range proteinuria after the first dose of severe acute respiratory syndrome coronavirus 2 (SARS-CoV-2) vaccination, which led to a diagnosis of immunoglobulin A nephropathy (IgAN). A Japanese woman in their forties with a significant medical history of occult blood by urine dipstick test (over the past 3 years) presented with fever, chills, shivering, marked thrombocytopenia, and gross hematuria 9 days after the first dose of the BNT162b2 mRNA vaccine (Pfizer) against SARS-CoV-2 infection. Although thrombotic microangiopathy (TMA) was first suspected as the cause of the severe thrombocytopenia, TMA was clinically excluded after two sessions of plasma exchange were performed. Renal biopsy was performed as the patient's platelet count improved. We made a diagnosis of acute worsening IgAN, triggered by the first dose of SARS-CoV-2 vaccination. In this case, we speculated that vaccine-induced immune activation may be involved in the exacerbation of occult IgAN, leading to the definite diagnosis. We should pay more attention to the development/worsening of clinically significant kidney disease after SARS-CoV-2 vaccination not only in those with known glomerular disease but also in those with only mild urinary abnormality.

**Keywords** SARS-CoV-2 · Immunoglobulin A nephropathy · BNT162b2 mRNA vaccine

## Introduction

During the severe acute respiratory syndrome coronavirus 2 (SARS-CoV-2) pandemic, mortality and morbidity increased in patients with kidney disease infected with SARS-CoV-2 [1]. Several reports have shown that apart from the coronavirus disease 2019 (COVID-19) infection itself, the SARS-CoV-2 vaccination may be involved in the pathogenesis/

exacerbation of certain kidney diseases such as acute kidney disease, nephrotic syndrome, and glomerulonephritis [2]. Most reports on glomerulonephritis after vaccination are relapsing cases of immunoglobulin A nephropathy (IgAN), while only one case report describes a de novo case of IgAN [3–5], in which exacerbation of immune-mediated glomerular diseases by the vaccine could be the mechanism of action.

IgAN is the most common form of primary glomerulonephritis in the Asia–Pacific region, including Japan, and accounts for 20–40% of all glomerular diseases [6]. Due to the high prevalence of IgAN, there would be a huge number of patients with occult IgAN having only mild microscopic hematuria. We should pay more attention to patients with mild urinary abnormality after SARS-CoV-2 vaccination regardless of the pathologically diagnosed glomerulonephritis, especially IgAN.

Here, we report the case of a patient suspected to have occult IgAN with persistent urine occult blood over the past 3 years, who developed clinically and pathologically apparent IgAN 9 days after SARS-CoV-2 vaccination.

✉ Masahiko Yazawa  
masahikoyazawa@gmail.com

Yoko Fujita  
y2fujita@marianna-u.ac.jp

Keisuke Yoshida  
k.yoshida0622@gmail.com

Daisuke Ichikawa  
ichikawa6008@gmail.com

Yugo Shibagaki  
yugoshibagaki@gmail.com

<sup>1</sup> Division of Nephrology and Hypertension, Department of Internal Medicine, St. Marianna University School of Medicine, 2-16-1 Sugao, Miyamae-Ku, Kawasaki, Kanagawa 216-8511, Japan

## Case report

A Japanese woman in her early forties with a significant history of urine occult blood [a few times of (+1) to (2+)] and proteinuria [(–) to (1+)] by dipstick test over the past 3 years, without further workup presented with fever (body temperature, 38 °C), chills and shivering, back pain, general malaise, and gross hematuria 9 days after receiving the first dose of the BNTb162b2 SARS-CoV-2 vaccine (Pfizer). She had no history of previous infections such as tonsillitis or colitis. Polymerase chain reaction for SARS-CoV-2 was negative. She was prescribed only acetaminophen for these symptoms.

Thirteen days after vaccination, the patient was referred and admitted to our hospital for hematuria, nephrotic-range proteinuria, pyuria, and severe thrombocytopenia of  $7.0 \times 10^3/\mu\text{L}$ . On admission, the fever had subsided, and obvious sore throat, purpura or petechiae, bloody stools, abdominal pain, or lower limb arthralgia were all absent. Table 1 and Fig. 1 show the clinical data on admission and clinical course after vaccination, respectively. On admission, urinalysis showed severe hematuria with a red blood cell count of 100/high power field (HPF), massive proteinuria of 18.13 g/gCr (urine protein-to-creatinine ratio), and a mildly elevated serum creatinine level at 0.86 mg/dL (previous level of 0.76 mg/dL), which suggested the development or worsening of occult glomerular disease. Although she had nephrotic range proteinuria, her serum albumin was persistently greater than 3.0 g/dL. We did not measure the value of albuminuria on admission. Furthermore, proteinuria spontaneously resolved to almost within the normal range without any specific treatment. Thus, such high-level proteinuria would be affected gross hematuria at 9 days after vaccination and consistent with non-glomerular proteinuria. Due to the mildly elevated inflammation marker and urine leukocyte count (5–9 cells/HPF), ampicillin/sulbactam (ABPC/SBT) was administered for 10 days for probable pyelonephritis.

The platelet count further decreased to  $4.0 \times 10^3/\mu\text{L}$  on day 2 of admission (day 13 after vaccination). Although gross hematuria resolved on day 15 after vaccination, the microscopic hematuria and proteinuria persisted. The creatinine level increased to 1.23 mg/dL, indicating progression of renal dysfunction. No fragmented red blood cells were observed, and the lactate dehydrogenase level was normal. However, because of the rapid thrombocytopenia, we considered that the patient might have thrombotic microangiopathy (TMA), especially thrombotic thrombocytopenic purpura (TTP). Two sessions of plasma exchange (PE) therapy were performed until TTP was ruled out. Other causes of thrombocytopenia, such as pseudothrombocytopenia, disseminated intravascular

coagulation, and immune thrombocytopenic purpura, were less likely, as shown in Table 1. Since thrombocytopenia and thrombus formation have been reported after COVID-19 vaccination [7], we tested for antiplatelet antibodies and platelet factor 4, which were negative. Magnetic resonance imaging was performed due to persistent headache till day 17 after vaccination. No thrombus or intracranial hematoma was found. Thrombocytopenia improved to within normal level during her clinical course (Fig. 1).

Since her renal function did not improve completely with persistent hematuria and proteinuria, percutaneous renal biopsy was performed on day 20 after vaccination when the platelet count had improved. The biopsy specimen revealed 33 glomeruli with mild proliferation of the mesangial and endocapillary cells, 2 fibrous crescents (Fig. 2A), and 3 fibrocellular crescents (Fig. 2B), suggesting a mixed acute and chronic phase of glomerular disease. Of the 33 glomeruli, 6% were global glomerulosclerosis (GGS), and interstitial fibrosis/tubular atrophy (IF/TA) was not noticeable. Fluorescent immunostaining showed predominant IgA deposition in the mesangium (Fig. 2C), with concurrent IgG, IgM, and C3 deposition. Electron microscopy showed mildly elevated electron-dense deposits in the mesangium and very mild foot-process effacement (Fig. 2D). There were no features of infection-related or other autoimmune disease-related glomerulonephritis. Thus, we finally made a diagnosis of IgAN with the Oxford MEST-C Classification [8] as M1-E0-S0-T0-C1.

The patient was discharged after all conditions had resolved. Two months after discharge, the serum creatinine level and proteinuria decreased to almost normal levels, while the microscopic hematuria persisted. The urinalysis test result gradually improved with time. No specific treatment for IgAN such as steroids, fish oil, and renin–angiotensin system (RAS) blockers was administered because the clinical course spontaneously and gradually resolved.

## Discussion

This is a case of occult IgAN that developed a significant clinical flare 9 days after the patient received the first dose of the BNT162b2 mRNA COVID-19 vaccine, leading to a kidney biopsy that led to the definitive diagnosis. In retrospect, we speculated that this case was occult IgAN rather than a de novo one since the patient had had urine occult blood over the past 3 years and the biopsy findings were likely to show chronic rather than acute features. This report highlights that COVID-19 vaccination can exacerbate pre-existing occult and even un-diagnosed IgAN with significant clinical flares as urinary abnormalities and renal dysfunction.

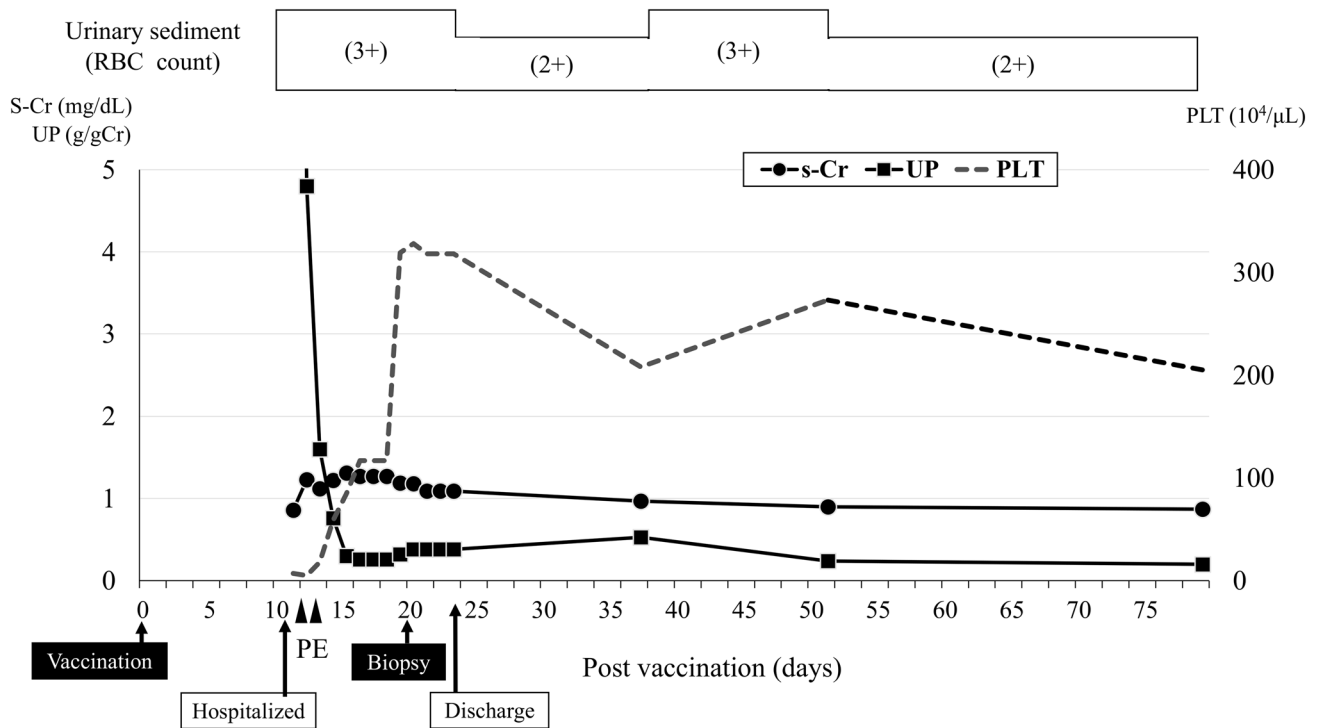
**Table 1** Clinical data on admission

	Day 12 (day of admission)
Laboratory data	
White blood cells ( $10^3/\mu\text{L}$ )	7.5
Hemoglobin (g/dL)	12.9
Platelet ( $10^3/\mu\text{L}$ )	7.0
CRP (mg/dL)	1.67
Total bilirubin (mg/dL)	0.5
AST (IU/L)	21
ALT (IU/L)	15
LDH (U/L)	210
Total protein (g/dL)	6.2
Albumin (g/dL)	3.6
BUN (mg/dL)	12.4
Creatinine (mg/dL)	0.86
eGFR (mL/min/1.73 m <sup>2</sup> )	57.5
Na (mEq/L)	140
Cl (mEq/L)	107
K (mEq/L)	3.8
PT-INR	1.04
APTT (SEC)	28.8
D-dimer ( $\mu\text{g/mL}$ )	2.0
IgA (mg/dL) (standard value: 93–393)	155
C3 (mg/dL) (standard value: 65–135)	88
C4 (mg/dL) (standard value: 13–35)	18
Urine cast	Red blood cell 3+
Proteinuria by dipstick test	2+
Hematuria by dipstick test	3+
Hematuria in urinary sediment (count/HPF)	> 100 (non-glomerular or glomerular hematuria)
White blood cells in urinary sediment (count/HPF)	5~9
Urinary protein creatinine ratio (g/gCr)	18.1
Thrombocytopenia associated laboratory results	
Pseudo thrombocytopenia using EDTA	N/A
Fragmented RBC	N/A
ADAMS13 activity (IU/mL) (reference range: 0.75 – 1.5)	0.64
ADAMS13 antibody (BU/mL) (reference range: <0.5)	<0.5
STEC	Negative
Direct coombs test	Negative
Anti-nuclear antibody (standard value: 0–40)	<40
Anti-platelet antibodies	Negative
PF4 (ng/mL) (standard value: 0–20)	16
PF4—heparin antibodies (U/mL) (standard value: <1.0)	<0.6
Measles IgM (standard value: 0–0.8)	0.14
VZV IgM (standard value: <0.8)	0.39
Rubella IgM (standard value: 0–0.8)	0.39
CMV antigen (C10/C11)	N/A
CMV IgM (standard value: 0–0.8)	0.45
Mumps IgM (standard value: 0–0.8)	0.11
HSV IgM (standard value: 0–0.8)	0.22
EBV anti-VCA IgM (standard value: 0–0.5)	0.0
HIV antibody	Negative

CRP C-reactive protein, AST aspartate aminotransferase, ALT alanine aminotransferase, LDH lactate dehydrogenase, BUN blood urea nitrogen, eGFR estimated glomerular filtration, Na serum sodium, Cl serum chloride, K potassium, PT prothrombin time-international normalized ratio, APTT activated partial thromboplastin time, HPF high power field, Cr creatinine, EDTA ethylenediaminetetraacetic acid, RBC red blood cell, ADAMTS13 a disintegrin-like and metalloproteinase with thrombospondin type 1 motifs 13, BU

**Table 1** (continued)

Bethesda units, *STEC* Shiga-toxin-producing *Escherichia coli*, *PF4* platelet factor 4, *VZV* varicella-zoster virus, *CMV* cytomegalovirus, *HSV* herpes simplex virus, *EBV* Epstein-Barr virus, *VCA* virus capsid antigen, *HIV* human immunodeficiency virus, *N/A* not available



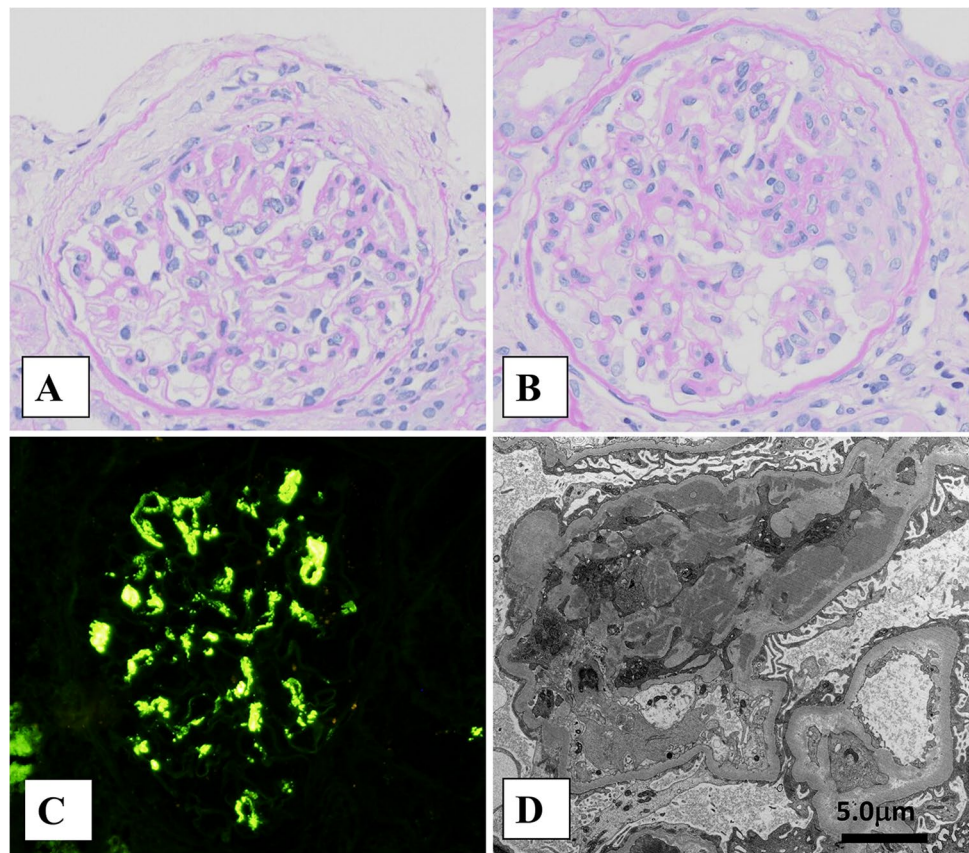
**Fig. 1** Clinical course of key findings after vaccination. *S-Cr* serum creatinine, *UP* urinary protein, *RBC* red blood cell, *PE* plasma exchange, *PLT* platelet count

Relapsing or de novo cases of IgAN after vaccinations have been reported [3–5], in which cases showed gross hematuria immediately after the vaccinations but resolved spontaneously (Table 2). In our case, the abrupt development of gross hematuria following vaccination led to the definitive diagnosis of pre-existing occult IgAN. This is similar to case 4 illustrated in Table 2. However, the present case developed gross hematuria after the first dose of vaccination, and the onset of symptoms was later (9 days post first vaccination, and the onset of symptoms was later (9 days post first vaccination) than that of other cases (within 24 h after the second dose of vaccination). Although previous reports did not specify the degree of renal dysfunction or the amount of proteinuria before and after vaccination, this case showed elevated creatinine, nephrotic-range proteinuria, and gross hematuria. This suggests that the severity of the IgAN flare

in our case was more significant than those mentioned in previous reports, which could also explain why the clinical improvement was slower (the trend of improvement continued even after 2 months of disease onset) than those in the previous reports described in Table 2.

We speculated that the exacerbation of the immune-mediated glomerular disease by the SARS-CoV-2 vaccine could be the mechanism of the exacerbation of IgAN. Vojdani et al. [9] hypothesized the existence of molecular mimicry between the spike protein of SARS-CoV-2 and autoantigens and pointed out that SARS-CoV-2 infection and the mRNA vaccine may lead to the development of immune-mediated diseases. In a small-scale experiment [10], it was reported that SARS-CoV-2 mRNA vaccination induced spike antigen-specific IgA and IgG. Both increased exponentially after vaccination and reached the peak in approximately 20 days.

**Fig. 2** Biopsy findings. **A** Periodic acid-Schiff stain  $\times 200$ , **B** periodic acid-Schiff stain  $\times 200$ , **C** immunofluorescence study  $\times 200$ , and **D** electron micrography  $\times 4000$



It is known that parenteral influenza vaccines that do not activate mucosal immune responses increase the IgA level [11]. A study examining the subclasses of IgA antibodies to intramuscularly injected influenza vaccine reported that patients with IgAN had a stronger monomeric response to subclass IgA1 than healthy subjects.

The markedly decreased platelet count in this case occurred simultaneously with gross hematuria. The various tests to diagnose thrombocytopenia, especially TMA, including TTP, hemolytic uremic syndrome, and other secondary TMA, were negative. There was no thrombus formation in the intracranial vessels, and the results of the antiplatelet antibodies and platelet factor 4 were negative, suggesting that thrombocytopenia associated with SARS-CoV-2 vaccine-related thrombus formation [7] was

unlikely. Since this was not reported with the Pfizer vaccine, it is consistent. Thus, the causal relationship between the SARS-CoV-2 vaccine and thrombocytopenia was unclear even though the patient recovered spontaneously. In terms of treatment for thrombocytopenia, the effect of PE was also unclear in the present case.

In conclusion, the SARS-CoV-2 vaccines may cause exacerbation of both known and occult kidney diseases such as IgAN. However, this does not mean that vaccination should be avoided in those with known or occult kidney diseases but rather that more attention should be paid to patients who develop/exacerbate kidney diseases after receiving the SARS-CoV-2 vaccine regardless of the presence or absence of a definitive diagnosis.

**Table 2** Past case reports on IgA nephropathy and SARS-CoV-2 vaccination

No.	Age	Race	Sex	IgAN diagnose	Vaccine	Dose	Onset of gross hematuria	sCr and proteinuria before vaccination	sCr and proteinuria after onset	Gross hematuria persistent period	Specific treatment for IgAN
1 [3]	38	Caucasian	Female	Prior biopsy proven	Moderna	Second	Between 8 and 24 h	N/A (well preserved kidney function), 0.82 g/day	N/A (sCr did not increase), 1.4 g/day (at 3 weeks after vaccination)	3 days	N/A
2 [3]	38	Caucasian	Female	Prior biopsy proven	Moderna	Second	Between 8 and 24 h	N/A (well preserved kidney function), 0.59 g/day	N/A (sCr did not increase), 0.4 g/day (at 3 weeks after vaccination)	3 days	N/A
3 [4]	52	Asian	Female	Prior biopsy proven	Pfizer	Second	Within 24 h	sCr of 0.7–0.8 g/dL, proteinuria of 4.2 g/gCr, urine microalbumin of 0.6 g/gCr	N/A, urine microalbumin of 2.4 g/gCr (at 48 h after vaccination)	5 days	Continued ARB
4 [5]	30	Western European and South-American Ancestry	Male	Newly biopsy proven	Moderna	Second	1 day	N/A (no known past medical history)	sCr of 1.02 mg/dL, 4+ proteinuria by dipstick test (at one day after vaccination)	2 days	Started ARB
Present case	40 s	Asian	Female	Newly biopsy proven	Pfizer	First	9 days	sCr of 0.76 g/dL, 1+ proteinuria by dipstick test	sCr of 1.23 mg/dL, 18.1 g/gCr (at 12 to 13 days after vaccination)	6 days	No treatment

sCr serum creatinine, ARB angiotensin receptor blocker, N/A not available

**Author contributions** YF and MY participated in the writing of the paper. YO, KY, ID, YS, and MY participated in the approval of final manuscript.

**Funding** This study has not been supported by any grant.

**Availability of data and materials** Corresponding author (MY) proves and administrates the patient's data transparency.

## Declarations

**Conflict of interest** The authors have declared that no conflict of interest exists.

**Ethical approval** An ethical approval statement was not required for this manuscript since no specific information such as patient's age and admission or discharge date were included.

**Informed consent** The patient signed an informed consent to publish this report.

## References

1. D'Marco L, Puchades MJ, Romero-Parra M, Gimenez-Civera E, Soler MJ, Ortiz A, et al. Coronavirus disease 2019 in chronic kidney disease. *Clin Kidney J.* 2020;13:297–306.
2. Morlidge C, El-Kateb S, Jeevaratnam P, Thompson B. Relapse of minimal change disease following the AstraZeneca COVID-19 vaccine. *Kidney Int.* 2021;100:459.
3. Negrea L, Rovin BH. Gross hematuria following vaccination for severe acute respiratory syndrome coronavirus 2 in 2 patients with IgA nephropathy. *Kidney Int.* 2021;99:1487.
4. Rahim SEG, Lin JT, Wang JC. A case of gross hematuria and IgA nephropathy flare-up following SARS-CoV-2 vaccination. *Kidney Int.* 2021;1001:238.
5. Abramson M, Mon-Wei YuS, Campbell KN, Chung M, Salem F. IgA nephropathy after SARS-CoV-2 vaccination. *Kidney Med.* 2021. <https://doi.org/10.1016/j.xkme.2021.05.002>.
6. Donadio JV, Grande JP. IgA nephropathy. *N Engl J Med.* 2002;347:738–48.
7. Schultz NH, Sorvoll IH, Michelsen AE, Munthe LA, Lund-Johansen F, Ahlen MT, et al. Thrombosis and thrombocytopenia after ChAdOx1 nCoV-19 Vaccination. *N Engl J Med.* 2021;384:2124–30.
8. Trimarchi H, Barratt J, Cattran DC, Cook HT, Coppo R, Haas M, et al. Oxford Classification of IgA nephropathy 2016: an update from the IgA Nephropathy Classification Working Group. *Kidney Int.* 2017;91:1014–21.
9. Vojdani A, Kharratian D. Potential antigenic cross-reactivity between SARS-CoV-2 and human tissue with a possible link to an increase in autoimmune diseases. *Clin Immunol.* 2020;217:108480.
10. Wisniewski AV, Campillo Luna J, Redlich CA. Human IgG and IgA responses to COVID-19 mRNA vaccines. *PLoS ONE.* 2021;16:e0249499.
11. Endoh M, Suga T, Miura M, Tomino Y, Nomoto Y, Sakai H. In vivo alteration of antibody production in patients with IgA nephropathy. *Clin Exp Immunol.* 1984;57:564–70.

**Publisher's Note** Springer Nature remains neutral with regard to jurisdictional claims in published maps and institutional affiliations.