

Irreducible Acute Patellar Dislocation due to a New Anatomical Variant – the Notched Patella*

Dislocação patelar aguda irreduzível devido a uma nova variante anatômica - a patela entalhada

Miguel Duarte-Silva¹ Joaquim Rodeia² Tiago Mota Gomes³ Francisco Guerra-Pinto¹

¹Department of Orthopedics and Traumatology, Hospital de Cascais Dr. José de Almeida, Cascais, Portugal

²Department of Orthopedics and Traumatology, Hospital São Francisco Xavier, Centro Hospitalar Lisboa Ocidental, Lisboa, Portugal

³Faculty of Medicine, Department of Anatomy, Universidad de Barcelona, Barcelona, Spain

Address for correspondence Miguel Duarte-Silva, Departamento de Ortopedia e Traumatologia, Hospital de Cascais Dr. José de Almeida, Cascais, Portugal (e-mail: miguelduartesilva@gmail.com).

Rev Bras Ortop 2019;54:90–94.

Abstract

Irreducible patella dislocations are rare and are usually associated with complex mechanisms. The authors report the clinical case of an irreducible lateral patellar dislocation due to an anatomical variant. The authors assisted a 16-year-old patient who presented with a lateral patella dislocation that was impossible to reduce by closed manipulation, even under general anesthesia. During the imaging study, the computed tomography (CT) exam showed a notch in the medial facet of the patella, impacted in the lateral condyle, which prevented the reduction. This anatomical variant was later confirmed during surgery. In a bilateral follow-up CT, this variant was also present in the contralateral, normal knee, excluding traumatic reshaping as the reason for this patellar notch. The authors used a medial parapatellar approach for open reduction of the dislocation and to repair the medial retinaculum. According to Wiberg, there are three different patella types. The authors describe a variation of type III patella with a notch in the medial border that is not included in the previous classification. They emphasize the importance of a CT study in the presence of an irreducible dislocation and the recognition of this anatomical variant of the patella, as further aggressive maneuvers have proven to be unsuccessful. Open reduction appears to be the best option in this scenario.


Keywords

- ▶ joint dislocations
- ▶ intra-articular fractures
- ▶ patellar dislocation

Resumo

As luxações irreduzíveis da patela são raras e são geralmente associadas a mecanismos complexos. Os autores relatam o caso clínico de uma luxação patelar lateral irreduzível devido a uma variante anatômica. Os autores atenderam um paciente de 16 anos que apresentou uma luxação lateral da patela de redução impossível por manipulação

* Work performed at the Hospital de Cascais Dr. José de Almeida, Department of Orthopedics and Traumatology, Cascais, Portugal. Published originally by Elsevier Editora Ltda. © 2018 Sociedade Brasileira de Ortopedia e Traumatologia.

 Miguel Duarte-Silva's ORCID is <https://orcid.org/0000-0002-8826-5403>.

Palavras-chave

- ▶ deslocamentos articulares
- ▶ fraturas intra-articulares
- ▶ deslocamento da patela

fechada, mesmo sob anestesia geral. Durante o estudo de imagem, a tomografia computadorizada (TC) mostrou um entalhe na faceta medial da patela, impactada no côndilo lateral, o que impediu a redução. Esta variante anatômica foi posteriormente confirmada durante a cirurgia. Em uma TC bilateral de acompanhamento, esta variante anatômica também estava presente no joelho contralateral, normal, excluindo o remodelamento traumático como o motivo deste entalhe patelar. Os autores utilizaram uma abordagem parapatelar medial para a redução aberta do deslocamento e para o reparo do retináculo medial. De acordo com Wiberg, existem três tipos diferentes de patela. Os autores descrevem uma variação da patela de tipo III com um entalhe na margem medial que não está incluída na classificação anterior. Ressalta-se a importância de um estudo de TC na presença de luxação irreduzível e o reconhecimento desta variante anatômica da patela, já que manobras agressivas foram testadas sem sucesso. A redução aberta parece ser a melhor opção neste cenário.

Introduction

Acute patellar dislocation is an abrupt disruption in the relationship of the patella with the femoral groove.¹ It is a common emergency, with an annual incidence of 5.8 per 100,000 in the general population, and an average incidence of 29 per 100,000 in the 10–17-year-old age group. Young active adults, particularly adolescent girls and tall overweight males appear to be predisposed.²

Most patellar dislocations are lateral dislocations. The mechanism is a twisting injury to the knee on a planted foot with valgus stress. In 10% of the cases acute patellar dislocations are the result of a direct blow to the medial side of the knee.^{2,3}

Patellar dislocation often reduces spontaneously or with simple closed manipulation, directing the patella medially while doing knee extension and hip flexion to relax the quadriceps muscle.⁴ Irreducible patellar dislocations are rare and they are usually associated with more complex mechanisms that require the reduction under general anesthesia or open reduction.

Irreducible lateral dislocations described in the literature were associated with vertical axis rotation, osteochondral

injury to the medial aspect of the patella, or a patella hooked on the lateral femoral condyle under the prominent osteophytic ridge.^{5–8} In this article we report the case of an acute irreducible lateral patellar dislocation associated with an anatomical variant of the patella.

Case Report

The authors present a case of a previously healthy 16-year-old male patient, who came to the Emergency Room with a clinical presentation of a lateral patella dislocation, after a fall while he was running allegedly with no direct trauma involved. The past history was unremarkable and revealed no predisposing factors, such as trauma or joint laxity.

On physical examination, the knee was locked in extension with the patella located laterally. There was tenderness around the patellar region.

A laterally dislocated patella was seen on the plain radiograph (▶ Fig. 1).

An immediate closed reduction was attempted without success. Subsequently a local anesthetic was administered, with an intra-articular and local infiltration in the medial and lateral facets of the patella (10 cc of Ropivacaín and 10 cc

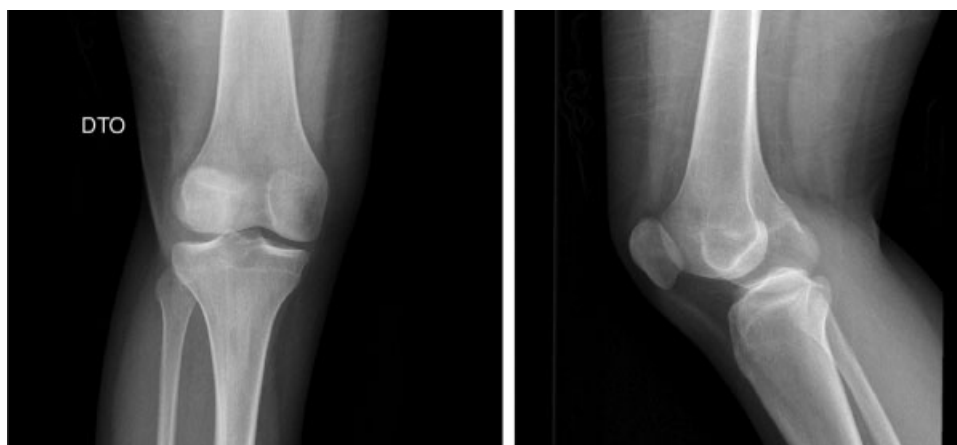


Fig. 1 AP and lateral view of the right knee.

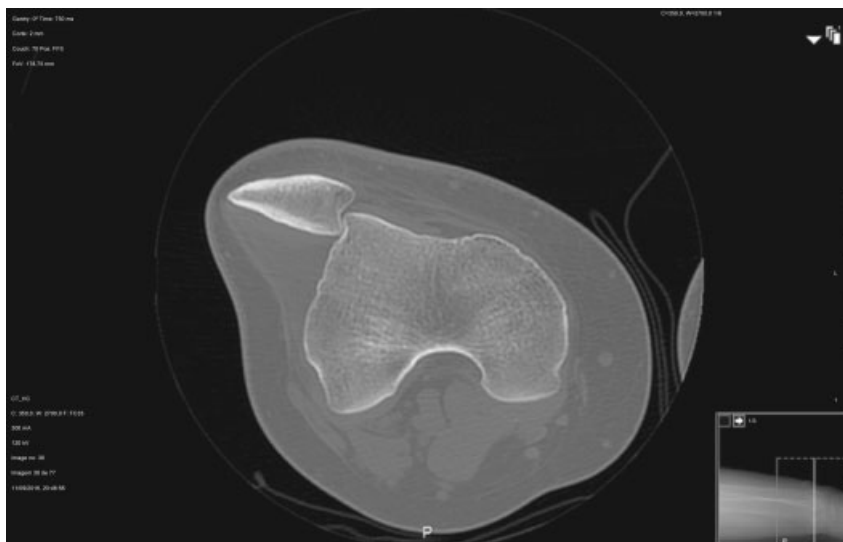


Fig. 2 CT confirmation of the anatomical variant.

of Lidocain). Although the patient was completely pain free the reduction was also unsuccessful.

Given the patient age we suspected a osteochondral lesion was blocking the knee. With this in mind, a Computed Tomography was made. The CT showed an anatomic variation of the patella with a notch in the medial facet that impacted in the lateral condyle of the femur (**► Fig. 2**).

The patient was taken to the Operating Room. It was still not possible to reduce the dislocation under general anesthesia so it was decided to move for an open reduction.

A medial para-patellar approach was performed, with identification of the avulsed fibers of the torn medial retinaculum from the patella. The medial patellar facet, with a notched morphology as observed in the CT, was impacted in the lateral gutter. An osteotome was introduced in the gap and a considerable force was needed to detach the patella, which immediately returned to its normal position. During closure, the medial retinaculum was repaired, with one

anchor in the center of the MPFL patellar foot-print. The limb was immobilized with a cruro-podal splint during two weeks for comfort.

The following rehabilitation proceeded uneventfully. At 4 months follow-up the patient has full range of motion and resumed sports activity. He reports occasional pain but denies any episode of subjective instability. He has no pain or discomfort on the apprehension test. Considering the Knee Severity Score the patient has a 90/100, but with maximal score in the function part.

Follow-up CT of both knees shows the presence of the notch in the medial patellar facet bilaterally. This excludes traumatic re-shaping has a reason for this patellar appearance (**► Fig. 3**).

In this follow up CT, we confirmed a normal patellar height (**► Fig. 4**), the tilt and TTTG was 21.2° and 17.5 mm in the affected knee and 19.9° and 17.8 mm in the contralateral knee (**► Figs. 5–8**). The femoral throchlea was dysplastic: type C of the Dejour classification.

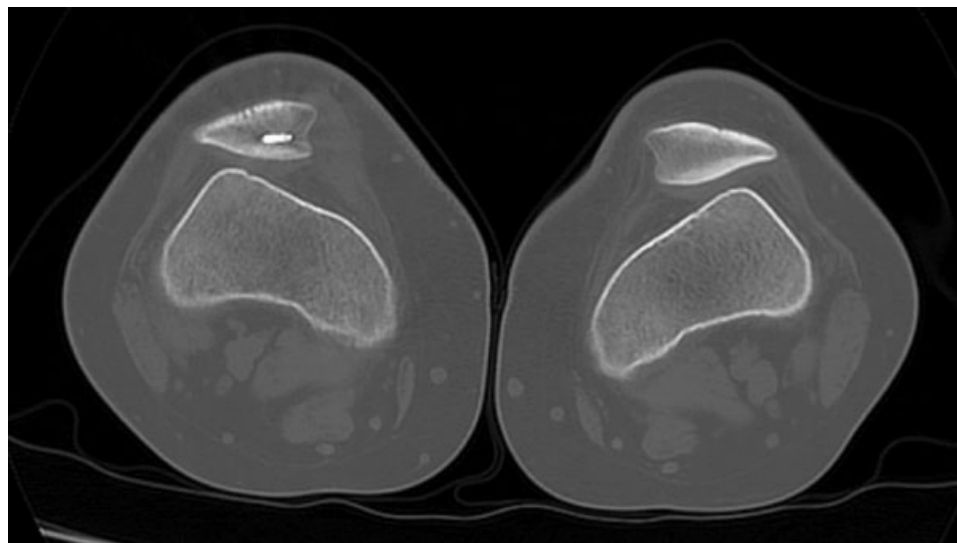


Fig. 3 Bilateral CT.

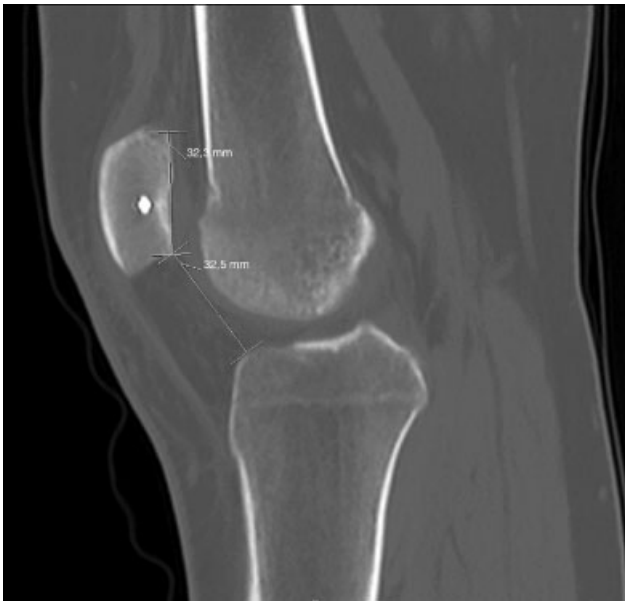

Fig. 4 Patellar height.

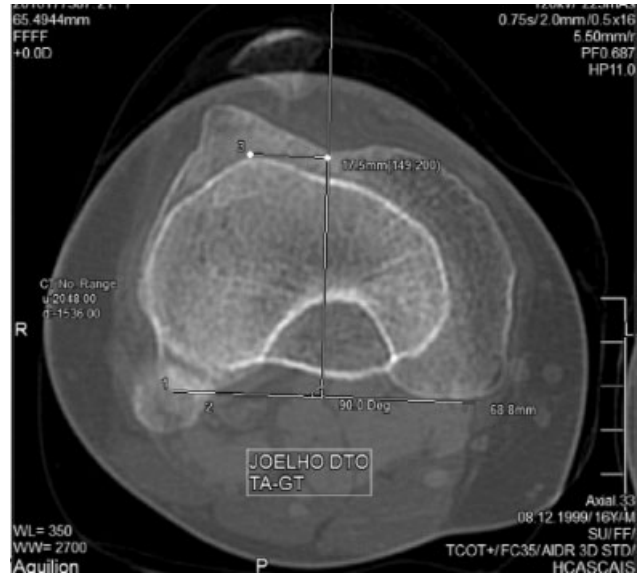

Fig. 6 TTTG of the right knee.

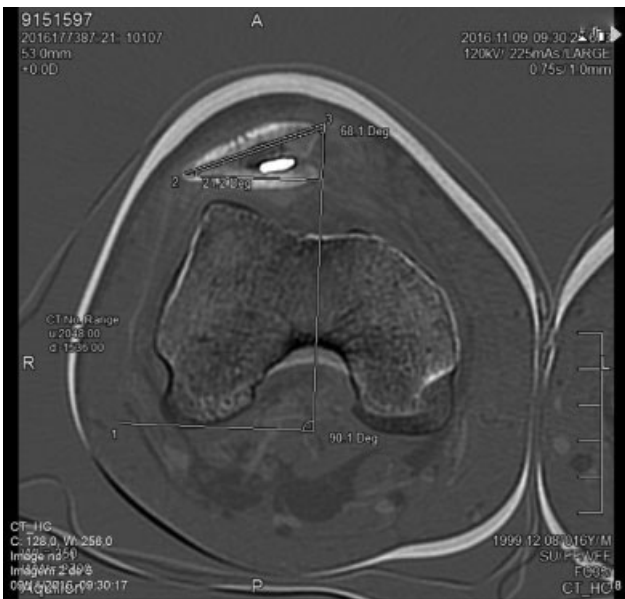

Fig. 5 Patellar tilt of the right knee.

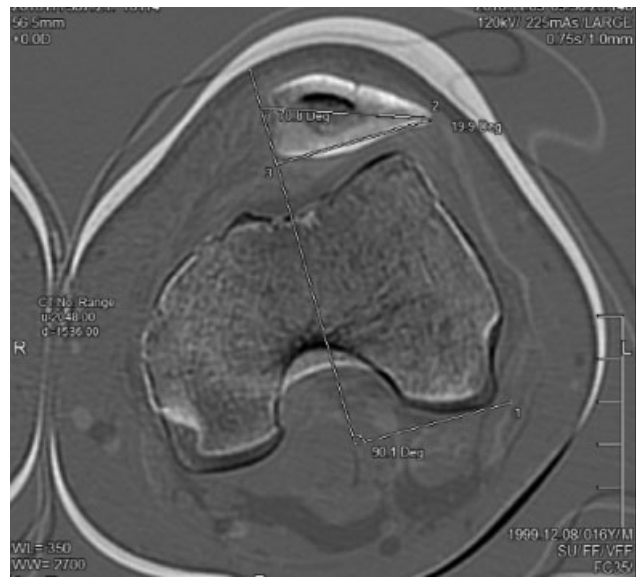

Fig. 7 Patellar tilt of the left knee.

Discussion

The patella is a sesamoid bone involved in the extensor mechanism of the knee. Patellar shape is not constant. Three different patellar types have been described by Wiberg, based mainly on asymmetry between the patellar medial and lateral facet on axial views of the patella: type I with symmetrical facets; type II with slightly smaller size of medial facet and type III with markedly smaller size and more vertical orientation of medial facet. A type IV was later described by Baumgartl, the “Jaegerhut” patella, with no medial facet and, consequently, no median ridge.⁹ The shape of the patella can be a predisposing factor to patellar insta-

bility, with association between Wiberg patellar shape type III and lateral patellar subluxation.¹⁰

In this case report, we describe a variation of type III patella, with a notch in the medial border. This notch on the medial facet of the patella explains why it was locked against the lateral femoral condyle preventing closed reduction. The images of contralateral healthy knee show the same notch on the medial facet of the patella, and make us assume that this was not the result of traumatic re-shaping of the medial border of the patella. Computed tomography images were essential to identify the blocking mechanism in the lateral femoral condyle and avoid persistent attempts at closed reduction, which could cause fracture or additional chondral

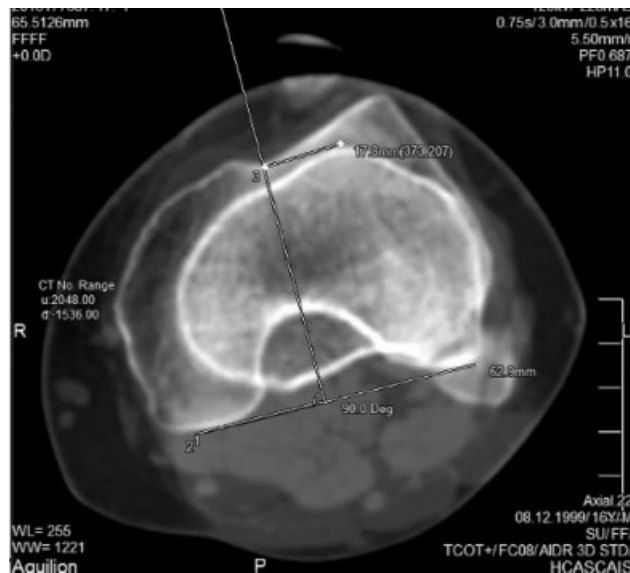


Fig. 8 TTTG of the left knee.

injury. Open reduction was the best attitude as closed manipulation was proving unsuccessful, and it allowed medial retinaculum repair during closure.

Patellar dislocations that do not reduce with simple manipulation deserve further imaging with computed tomography before attempting aggressive maneuvers.

We describe an anatomical variant, the notched patella, and report the unsuccessful attempts of closed reduction under local or general anesthesia. Open reduction seems to

be the best option for patellar dislocations with a notched patella entrapment in the femoral condyle.

Conflicts of Interest

The authors declare no conflicts of interest.

References

- Higgins A, Khalfaoui MY. Atraumatic extra-articular patellar dislocation with vertical axis rotation: a case study. *J Orthop Case Rep* 2016;6(1):58–60
- Grewal B, Elliott D, Daniele L, Reidy J. Irreducible lateral patellar dislocation: a case report and literature review. *Ochsner J* 2016; 16(2):180–4
- Abramov M, Stock H. Lateral patellar dislocation: mechanism of disease, radiographic presentation, and management. *Conn Med* 2013;77(4):235–8
- Dejour H, Walch G, Nove-Josserand L, Guier C. Factors of patellar instability: an anatomic radiographic study. *Knee Surg Sports Traumatol Arthrosc* 1994;2(1):19–26
- Lowe M, Meta M, Tetsworth K. Irreducible lateral dislocation of patella with rotation. *J Surg Case Rep* 2012;2012(3):10. Doi: 10.1093/jscr/2012.3.10
- Yerimah G, Eisenstein N, Turner R. Irreducible lateral dislocation of patella. *BMJ Case Rep* 2013;2013:2
- Soraganvi PC, Narayan Gowda B, Rajagopalakrishnan R, Gavaskar AS. Irreducible, incarcerated vertical dislocation of patella into a Hoffa fracture. *Indian J Orthop* 2014;48(5):525–8
- Gupta RK, Gupta V, Sangwan SS, Kamboj P. Neglected locked vertical patellar dislocation. *Indian J Orthop* 2012;46(5):581–4
- Scott WN. *Insall & Scott Surgery of the knee*. 5th ed. Philadelphia: Elsevier/Churchill Livingstone; 2012
- Panni AS, Cerciello S, Maffulli N, Di Cesare M, Servien E, Neyret P. Patellar shape can be a predisposing factor in patellar instability. *Knee Surg Sports Traumatol Arthrosc* 2011;19(4):663–70