

CASE REPORT

An Incidentally Detected Breast Cancer on Tc-99m MIBI Cardiac Scintigraphy

Duray Seker, Gaye Seker, Emine Ozturk¹, Bahattin Bayar, Hakan KulacogluDepartments of Surgery and ¹Radiology, Diskapi Yildirim Beyazit Teaching and Research Hospital, Ankara, Turkey

Tc-99m methoxyisobutylisonitrile (MIBI) scintigraphy is generally used as a second-line diagnostic tool for obscured breast lesions. When the entire field of view is examined carefully, it is often possible to detect additional lesions unrelated to the initial intent and purpose of the examination. Herein we present a case of breast cancer incidentally detected by cardiac Tc-99m MIBI scintigraphy. An area of uptake was detected in the breast during a cardiac imaging test. Further evaluation of this lesion revealed a histopathological diagnosis of invasive ductal carcinoma of the

breast. Sensitivity of this scintigraphic technique is not enough sufficient to use this test as a screening test for breast cancer, but it may provide supplemental information. Since it is not uncommon to find incidental lesions during imaging studies, examination of the image field may help clinicians find otherwise unrecognized or undiagnosed pathologies.

Key Words: Breast, Carcinoma, Scintigraphy

INTRODUCTION

Tc-99m methoxyisobutylisonitrile (MIBI) scintigraphy is a functional imaging test that was introduced in early 90s, and is now widely used for cardiac imaging. Incidental findings on cardiac imaging are not uncommon [1]. The larger the field of view, and more views obtained, the greater are the variety and number of innocent and significant lesions detected [2]. Should nuclear medicine specialists look for and report incidental findings identifiable during cardiac imaging examinations? As reported by Northam et al. [3] they most certainly should.

Although scintimammography is not the primary diagnostic method for breast cancer it has been recommended in complement for challenging cases where other imaging methods are inconclusive [4]. Furthermore, Tc-99m MIBI is the recommended radiopharmaceutical for sentinel node detection in patient with breast cancer [5]. There have been rare reports about incidental breast cancer diagnosis by Tc-99m MIBI scintigraphy performed for the diagnosis of other pathologies [6]. Also, there are a few reports in medical databases about incidental detection of breast cancer during other nuclear

imaging techniques performed for other diagnostic purposes [7,8].

We herein report a case of breast cancer case that was histopathologically diagnosed after an incidental imaging by Tc-99m MIBI scintigraphy.

CASE REPORT

A 29-year-old female patient was admitted to the cardiology clinic for chest pain. After clinical examination, a Tc-99m MIBI myocardial perfusion scintigraphy was performed. According to the report her cardiac findings were normal but in the field of view there was an area of focal accumulation in the lateral part of left breast, and further examination was recommended (Figure 1). The patient was therefore referred to the department of surgery for breast examination. A 4 × 4 cm sized, immobile solid lesion was detected in the lateral inferior quadrant of her left breast in physical examination. Ultrasound revealed a 24 × 18 mm sized spiculated mass lesion which contained microcalcifications in addition to a heterogeneous hypoechoic area filling the lateral inferior quadrant of the left breast. There were also multiple axillary lymphadenopathies, the greatest size of which was 13.5 × 13.5 mm. The lesion was classified as BIRADS 5 (Figure 2). Fine needle aspiration cytology was reported as suspicious for malignancy. Further test revealed no distant metastasis.

A two-step operation was scheduled. First, the lesion was

Correspondence: Duray Seker

Department of Surgery, Diskapi Yildirim Beyazit Teaching and Research Hospital, Mebusevleri Ayten Sokak No:13/4, Tandogan, Ankara, Turkey
Tel: +90-312-596-2353, Fax: +90-312-223-5158
E-mail: duray@superonline.com

Received: August 12, 2011 Accepted: January 3, 2012

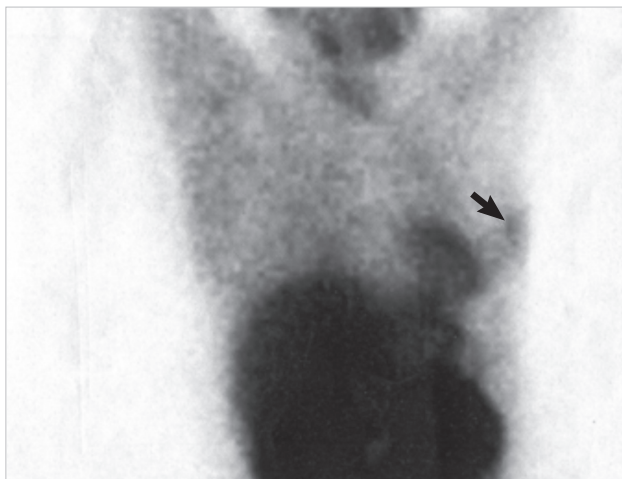


Figure 1. Scintigraphic image showing accumulation in left breast (arrow).

excised totally and sent to histopathology department for frozen section examination. After receiving a confirmed diagnosis of “infiltrative ductal carcinoma” a modified radical mastectomy was performed. The histopathologic examination report of the specimen was infiltrative ductal carcinoma in the 4 cm tumor and 4 out of 28 dissected lymph nodes were found to be metastatic. The tumor was staged as pT2N2M0.

DISCUSSION

Although mammography has a relatively high sensitivity of 80% to 90%, especially in examination of older women, it is less reliable for detecting lesions in dysplastic and dense breast [9]. The major drawback of mammography is its low specificity and low positive predictive value of only 10% to 35% for non-palpable cancers [10].

Tc-99m MIBI is widely available as a myocardial perfusion imaging agent. The uptake of Tc-99m MIBI in breast cancer was first reported in 1992 [11]. MIBI was subsequently studied by many investigators for imaging of non-palpable breast lesions, staging of breast cancer, lymph node imaging and to document the extensiveness of breast cancer lesions and as prognostic marker for chemotherapy response. Although this radiopharmaceutical may not be sensitive enough to serve as a screening test, it is useful in the evaluation of patient with inconclusive breast examinations as a second line diagnostic tool [12]. The overall sensitivity and specificity of Tc-99m MIBI scintigraphy is respectively 75.4% and 82.7% [13]. Tc-99m MIBI scintigraphy has a sensitivity of 84.2% and a specificity of 90.9% in detecting axillary metastasis [14]. The sensitivity and specificity is higher in palpable lesions but in such cases, other tests like ultrasonography and mammography are more

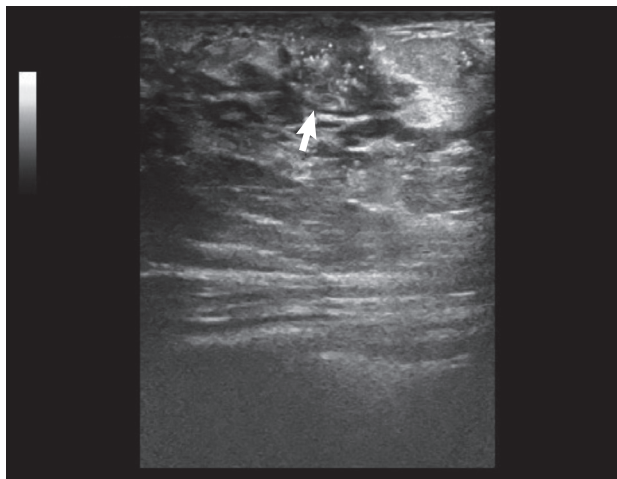


Figure 2. Ultrasonographic image of the breast lesion (arrow).

useful for diagnosis. It is reported lower sensitivity and specificity in non-palpable lesions. In the postpartum period diffuse uptake of Tc-99m sestamibi can be seen in non-cancer breast tissue due to lactation [15].

Once an examination is performed, a wide surgical approach must be done and all available data must be evaluated to apply appropriate judgement and to proceed in the best interest of the patient. As in this case, some times patients may have breast masses or other lesions that are not yet discovered. Since it is not surprising to find incidental lesions during imaging studies, examination of the image field in its entirety consideration of all the data may assist clinicians in the diagnosis of previously undetected illnesses.

CONFLICT OF INTEREST

The authors declare that they have no competing interests.

REFERENCES

1. Colletti PM. Incidental findings on cardiac imaging. *AJR Am J Roentgenol* 2008;191:882-4.
2. Haller S, Kaiser C, Buser P, Bongartz G, Bremerich J. Coronary artery imaging with contrast-enhanced MDCT: extracardiac findings. *AJR Am J Roentgenol* 2006;187:105-10.
3. Northam M, Koonce J, Ravenel JG. Pulmonary nodules detected at cardiac CT: comparison of images in limited and full fields of view. *AJR Am J Roentgenol* 2008;191:878-81.
4. Mathieu I, Mazy S, Willemart B, Destine M, Mazy G, Lonnewux M. Inconclusive triple diagnosis in breast cancer imaging: is there a place for scintimammography? *J Nucl Med* 2005;46:1574-81.
5. Sadeghi R, Zakavi SR, Forghani MN, Aryana K, Kakhki VR, Ayati NK, et al. The efficacy of Tc-99m sestamibi for sentinel node mapping in

- breast carcinomas: comparison with Tc-99m antimony sulphide colloid. *Nucl Med Rev Cent East Eur* 2010;13:1-4.
6. Hod N, Mindlin L, Horne T. Detection of occult breast carcinoma during evaluation of a skeletal tumor by Tc-99m MIBI scintigraphy. *Isr Med Assoc J* 2003;5:296-7.
 7. Conrad GR, Sloan DA, Sinha P. Detection of late chest wall recurrence of breast carcinoma during Tc-99m sestamibi parathyroid scintigraphy. *Clin Nucl Med* 2003;28:408-9.
 8. Arbab AS, Koizumi K, Arai T, Mera K, Miyazaki A, Otaka M. Incidental detection of breast cancer during Tl-201 myocardial SPECT study. *Ann Nucl Med* 1995;9:143-4.
 9. Sickles EA. Mammographic features of "early" breast cancer. *AJR Am J Roentgenol* 1984;143:461-4.
 10. Moskowitz M. The predictive value of certain mammographic signs in screening for breast cancer. *Cancer* 1983;51:1007-11.
 11. Campeau RJ, Kronemer KA, Sutherland CM. Concordant uptake of Tc-99m sestamibi and Tl-201 in unsuspected breast tumor. *Clin Nucl Med* 1992;17:936-7.
 12. Waxman AD. The role of (99m)Tc methoxyisobutylisonitrile in imaging breast cancer. *Semin Nucl Med* 1997;27:40-54.
 13. Khalkhali I, Villanueva-Meyer J, Edell SL, Connolly JL, Schnitt SJ, Baum JK, et al. Diagnostic accuracy of 99mTc-sestamibi breast imaging: multicenter trial results. *J Nucl Med* 2000;41:1973-9.
 14. Taillefer R, Robidoux A, Lambert R, Turpin S, Laperrière J. Technetium-99m-sestamibi prone scintimammography to detect primary breast cancer and axillary lymph node involvement. *J Nucl Med* 1995;36:1758-65.
 15. Ramakrishna G, Miller TD. Significant breast uptake of Tc-99m sestamibi in an actively lactating woman during SPECT myocardial perfusion imaging. *J Nucl Cardiol* 2004;11:222-3.