

Manually Steerable Catheter With Improved Agility

Geir Arne Tangen^{1,2,3}, Frode Manstad-Hulaas^{1,2,4}, Erik Nypan^{1,2} and Reidar Brekken^{1,2,3}

¹Department of Circulation and Medical Imaging, Norwegian University of Science and Technology (NTNU), Trondheim, Norway. ²Norwegian National Advisory Unit for Ultrasound and Image-Guided Therapy, St. Olavs Hospital, Trondheim, Norway. ³Department of Health Research, SINTEF Technology and Society, Trondheim, Norway. ⁴Department of Radiology, St. Olavs Hospital, Trondheim, Norway.

Clinical Medicine Insights: Cardiology
Volume 12: 1–4
© The Author(s) 2018
Reprints and permissions:
sagepub.co.uk/journalsPermissions.nav
DOI: 10.1177/1179546817751432



ABSTRACT:

PURPOSE: A prototype steerable catheter was designed for endovascular procedures. This technical pilot study reports the initial experience using the catheter for cannulation of visceral arteries.

TECHNIQUE: The 7F catheter was manually steerable with operator control handle for bending and rotation of the tip. The maximum bending angle was approximately 90° and full 360° rotation of the tip was supported. The study involved 1 pig with 4 designated target arteries: the left and right renal arteries, the superior mesenteric artery, and the celiac trunk. Fluoroscopy with 3-dimensional (3D) overlay showing the ostia from preoperative computed tomography angiography was used for image guidance. The cannulation was considered successful if the guidewire was placed well inside the target artery. In addition to evaluating cannulation success, procedure time and associated radiation doses were recorded. The procedure was performed twice with 2 different operators.

CONCLUSIONS: Both operators successfully reached all 4 target arteries, demonstrating the feasibility of the steerable catheter for endovascular cannulation of visceral arteries. No contrast medium was used, and median radiation dose was 4.5 mGy per cannulation. An average of approximately 2 minutes was used per cannulation. This study motivates further testing in a more comprehensive study to evaluate reproducibility in several animals and with inclusion of more operators. Further development by integrating the new catheter tool in a navigation system is also an interesting next step, combining fine control of catheter tip movements and 3D image guidance without ionizing radiation.

KEYWORDS: Steerable catheter, vascular cannulation, endovascular procedure, image fusion, image registration

RECEIVED: June 28, 2017. **ACCEPTED:** December 7, 2017.

TYPE: Technical Advance

FUNDING: The authors disclosed receipt of the following financial support for the research, authorship, and/or publication of this article: The study was funded by the Norwegian University of Science and Technology (NTNU) and The Norwegian National Advisory Unit on Ultrasound and Image-Guided Therapy. Research was conducted using infrastructures available through The Comparative Medicine Core Facility at NTNU, "The Operating Room of the Future" at St. Olavs Hospital" and "The Norwegian

Centre for Minimally Invasive Image Guided Therapy and Medical Technologies (NorMIT)."

DECLARATION OF CONFLICTING INTERESTS: The author(s) declared no potential conflicts of interest with respect to the research, authorship, and/or publication of this article.

CORRESPONDING AUTHOR: Geir Arne Tangen, Department of Health Research, SINTEF Technology and Society, PO Box 4760 Sluppen, Trondheim 7465, Norway. Email: Geir.A.Tangen@sintef.no

Introduction

Endovascular procedures have over the past decades changed the treatment of arterial disease. In a number of clinically relevant procedures, arterial side branches must be selectively catheterized. The cannulation may be cumbersome and the choice of catheter is generally based on operator experience and the anticipation for a specific catheter to facilitate the necessary access. Maneuverability of a catheter is limited by factors, such as vessel tortuosity and angulation, and the ability to transfer rotational motion from the proximal end to the distal tip of the catheter. Often different catheters must be tried and sometimes a cannulation remains unsuccessful. Therefore, the maneuverability of instruments is important for successful treatment.¹

In recent years, robotic systems for endovascular applications have become commercially available, such as Magellan (Hansen Medical, Mountain View, CA, USA) and CorPath (Corindus Vascular Robotics, Waltham, MA, USA). Studies have shown that robotically controlled systems can facilitate advanced procedures with less operator training.^{2–5} Despite promising results, the clinical use of endovascular robots is still limited, probably

due to the relatively high investment costs and infrastructure requirements. Thus, there is a need for simpler solutions that can more easily be implemented in existing procedures.

To this end, we have participated in the development of a manually steerable catheter for endovascular applications. The study objective was to investigate the feasibility of this catheter for in vivo cannulation of visceral arteries.

Technique

The catheter

A series of prototype steerable catheters were designed and produced by DEAM (Amsterdam, The Netherlands), with contribution from the authors during specification phase and during testing of the prototypes.

The catheter had a relatively stiff body and a flexible steerable tip. Using push/pull and rotation manipulators in the handle, the tip could be bent to an angle of approximately 90° and rotated 360° individually, thus allowing the tip to point in



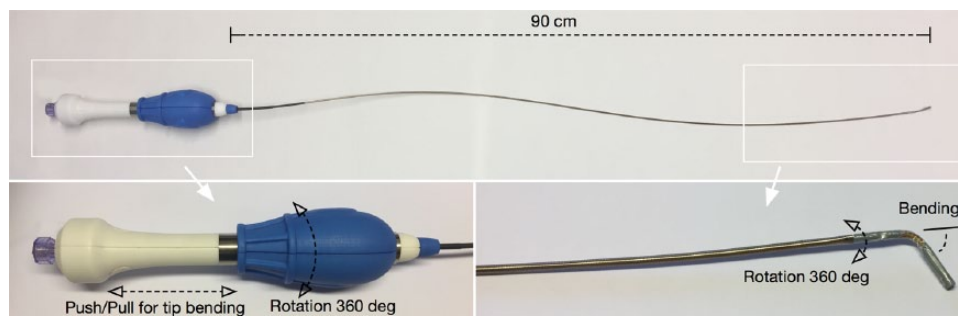


Figure 1. Manually steerable catheter. The steering part is integrated in the handle, supporting 360° rotation and up to 90° bending of the distal tip section.

any direction without having to rotate the entire catheter. This design was chosen to provide more fine control of the tip position compared with existing commercial one-directional/bidirectional solutions where the accumulation of torque forces in the catheter body degrades the maneuverability of the tip and can cause sudden unwanted rotation movements of the tip. The length of the catheter body was 90 cm, with a diameter of 7F (2.3 mm) and a lumen for a 0.035 in (0.9 mm) guidewire. The catheter, with illustration of control handle operations, is shown in Figure 1.

Setup

A 50 kg female domestic swine under general anesthesia was used in this study. After the experiment, the animal was euthanized. The swine was treated according to the Guide for the Care and Use of Laboratory Animals, and the Norwegian Food Safety Authority approved the study protocol (FOTS ID 10682). The anesthesia followed a standardized protocol from our Department of Comparative Medicine. Computed tomography (CT) angiography was acquired with the swine in supine position and after intravenous injection of 80 mL of contrast media (Omnipaque 350 mg I/mL; GE Healthcare, Chicago, Illinois, USA). Slice thickness and slice distance were 1.0 and 0.7 mm, respectively. The preoperative CTA was transferred to a Siemens Syngo Multimodality Workplace (Siemens AG, Forchheim, Germany). Four target arteries were designated: the left and right renal arteries, the superior mesenteric artery (SMA), and the celiac trunk. These were manually marked using the Siemens Syngo iPilot functionality.

In the hybrid operating room (OR), the animal was again placed in supine position. Vascular access was established percutaneously with a 9F introducer in the right common femoral artery, placed with ultrasound guidance. The bigger introducer was chosen because our prototype catheter (7F) had a small thicker area between the catheter body and the bending section due to a production flaw. A noncontrast cone beam CT (CBCT) of the abdomen at the level of the renal arteries was acquired. Siemens Syngo iPilot was used for registering the CBCT to the preoperative CTA. The marked

ostia were then overlaid on the live fluoroscopy operator screen, adding preoperative image information to the image-guided procedure.

Experiment

The steerable catheter was placed inside the abdominal aorta just above the iliac bifurcation. Primary parameter was whether cannulation was achieved for each of the targets. Secondary parameters were “time used” for navigation from the initial position in the abdominal aorta until successful cannulation and the associated radiation dose. No contrast medium was used during the experiment. Each target was approached twice with 2 different operators. One operator was an experienced interventional radiologist, whereas the other had no previous experience performing in vivo endovascular procedures.

Observations

Both operators successfully cannulated all 4 target arteries (Figure 2). For the experienced user, mean time for each cannulation was 126.5 seconds, with variations from 53 seconds for the left renal artery up to 172 seconds for the SMA. Time was comparable for the inexperienced user, except for the SMA, for which clearly longer time was needed. Median radiation dose was 4.5 mGy, with variations between 2 and 10 mGy but with a maximum of 60 mGy for cannulation of the SMA by the less experienced user. Using the iPilot fluoroscopy with overlay of the ostia from preoperative CT, no contrast was necessary for navigation.

As illustrated in Figure 2D, the SMA was a more complicated target because of the large angle between the aorta and the branch. When the catheter was bent close to 90°, the friction between the catheter lumen and the guidewire increased, thus complicating the cannulation. This was also relevant for the celiac trunk but less pronounced. This limitation should be dealt with during further development of the catheter. The catheter was subject to a sharp bend when passing through the introducer into the femoral artery but still kept a good steerability in the distal part during cannulation.

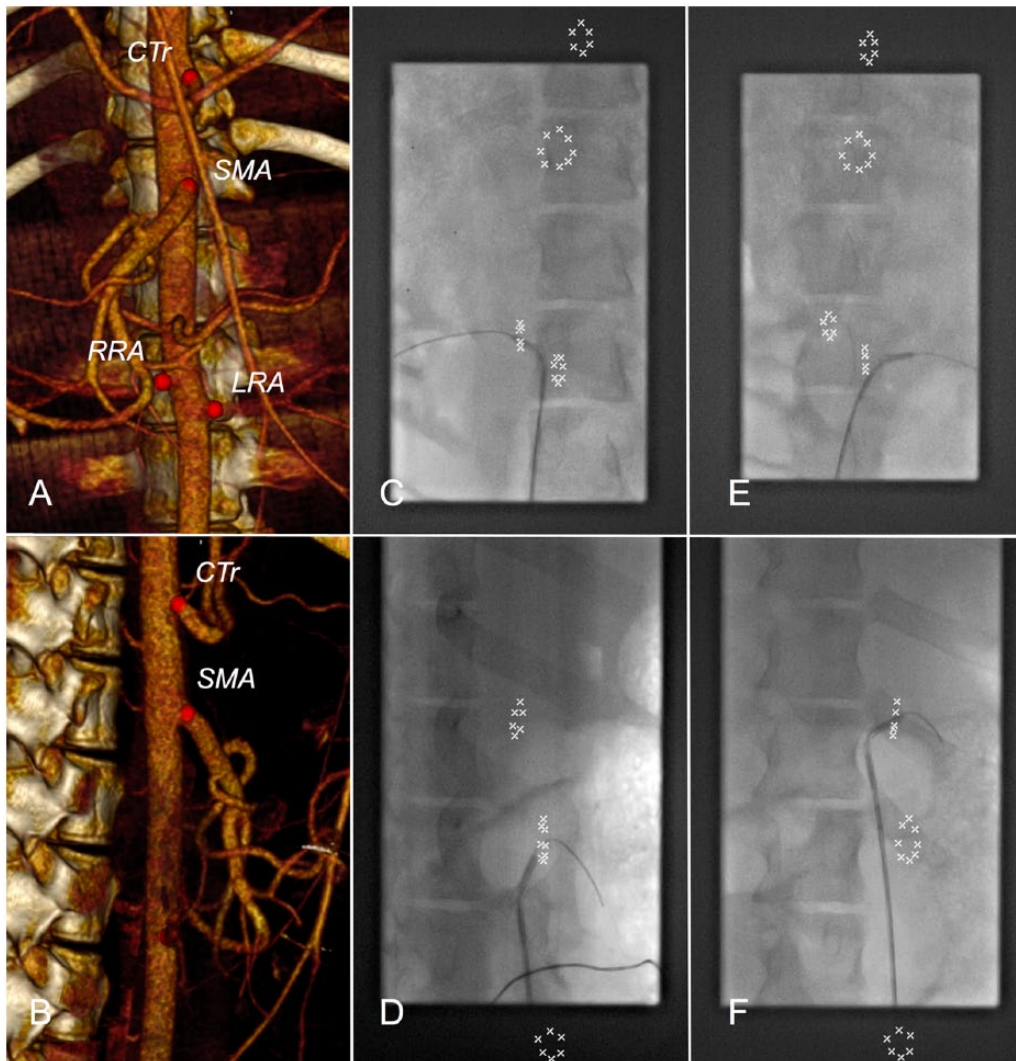


Figure 2. Image data. (A-B) Preoperative computed tomography angiography showing target vessels in an (A) anterior and (B) lateral view. (C-F) Live fluoroscopy illustrating successful cannulations of target vessels: right renal artery (RRA), superior mesenteric artery (SMA), left renal artery (LRA), and celiac trunk (CTr), respectively.

Discussion

Current endovascular procedures involve the use of fixed pre-shaped catheters. This requires highly trained and experienced operators. Several attempts with different catheter types are often needed to successfully cannulate target vessels, especially in cases with complex anatomy. Using our prototype steerable catheter, both users were able to successfully cannulate 4 different target arteries without changing catheters. A catheter with multidirectional bending capability may have the ability to reduce both procedure time and strain on the blood vessels compared with conventional catheters.

In a similar study setup by Chinnadurai et al,⁶ an endovascular robotic system was used for cannulation (Magellan; Hansen Medical, Mountain View, CA, USA). The robot had 2 steerable segments, thus providing more precise control of deflection and shape of the catheter. This enables maneuvering through more tortuous vascular anatomy, however, at the cost of a more technically complex solution. The main advantage of our approach is

that a handheld manual steerable catheter provides a solution with a smaller footprint, which is easier to integrate in existing procedures and OR infrastructure compared with a robot.

Some manually steerable catheter solutions are commercially available, specially developed for cardiac applications. These catheters provide one-directional or bidirectional deflection of the distal tip, which means that the user has to rotate the entire catheter body to control the bending direction of the catheter tip. In contrast, with our omnidirectional prototype catheter, the user has full control of the distal tip direction without rotating the catheter itself, and the challenge with transfer of torque from proximal control handle to distal tip is therefore avoided.

Conclusions

This technical pilot study demonstrated the feasibility of the steerable catheter for endovascular cannulation of visceral arteries. The catheter was easy to use, and, being handheld, it should be well suited for integration in the OR. The findings

motivate further evaluation and refinement of the catheter, and we have planned a more comprehensive study to evaluate reproducibility, involving several animals and more operators.

Acknowledgements

The authors have contributed in design specifications and testing of the prototype catheter in cooperation with DEAM (Amsterdam, The Netherlands) but have no financial interests in the device or company. The content of this article has not been presented previously.

Author Contributions

All four authors participated in the design and execution of the experiment and contributed to the writing of the paper.

REFERENCES

1. Fu Y, Liu H, Huang W, Wang S, Liang Z. Steerable catheters in minimally invasive vascular surgery. *Int J Med Robot.* 2009;5:381–391.
2. de Ruiter QM, Moll FL, van Herwaarden JA. Current state in tracking and robotic navigation systems for application in endovascular aortic aneurysm repair. *J Vasc Surg.* 2015;61:256–264.
3. Schwein A, Kramer B, Chinnadurai P, et al. Flexible robotics with electromagnetic tracking improves safety and efficiency during in vitro endovascular navigation. *J Vasc Surg.* 2017;65:530–537.
4. Riga CV, McWilliams RG, Cheshire NJW. In situ fenestrations for the aortic arch and visceral segment: advances and challenges. *Perspect Vasc Surg Endovasc Ther.* 2011;23:161–165.
5. Riga CV, Bicknell CD, Sidhu R, et al. Advanced catheter technology: is this the answer to overcoming the long learning curve in complex endovascular procedures. *Eur J Vasc Endovasc Surg.* 2011;42:531–538.
6. Chinnadurai P, Duran C, Al-Jabbari O, Abu Saleh WK, Lumsden A, Bismuth J. Value of C-arm cone beam computed tomography image fusion in maximizing the versatility of endovascular robotics. *Ann Vasc Surg.* 2016; 30:138–148.