


A Comprehensive Study Regarding the Intrauterine Development of Nails

Octavian Munteanu^a, Florin-Mihail Filipoiu^a, Monica Mihaela Cirstoiu^b, Andra-Ioana Băloiu^c, Ioan-Andrei Petrescu^c, and Roxana Elena Bohiltea ^b

^aDepartment of Anatomy, Carol Davila University of Medicine and Pharmacy, Bucharest, Romania; ^bDepartment of Obstetrics and Gynecology, Carol Davila University of Medicine and Pharmacy, Bucharest, Romania; ^cFaculty of Medicine, Carol Davila University of Medicine and Pharmacy, Bucharest, Romania

ABSTRACT

The nail apparatus serves as a protective layer over the dorsal aspect of each distal phalanx of both hands and feet. Besides protection, other functions include serving as part of defense or attack mechanisms, scratching, and dexterity. Nail development has been a subject of interest since the 19th century, from both the phylogenetic and ontogenetic points of view. Despite the early spark of interest, nail embryology has yet been analyzed by a relatively small number of scientists. In the Department of Anatomy of “Carol Davila” University of Medicine and Pharmacy, we performed a morphological analysis on 41 embryos and fetuses with gestational ages that varied between 6 and 29 weeks.

ARTICLE HISTORY

Received 4 December 2020
Revised 25 February 2021
Accepted 3 March 2021

KEYWORDS

Embryology; nails; fetuses; development; organogenesis; ontogenesis; dexterity; tactile receptors

Introduction

The nail apparatus serves as a protective layer over the dorsal aspect of each distal phalanx of both hands and feet.¹ Besides protection, other functions include serving as part of defense or attack mechanisms, scratching, or for cosmetic purposes.^{1,2} A more subtle utility is that the nail plate increases the sensory discriminatory capacity of the tactile receptors, and thus the dexterity, by counterbalancing the pressure exerted on the volar surface of the terminal phalanx.^{1,3,4}

The nail unit consists of the nail plate and four surrounding structures: the nail matrix, the nail bed, the proximal nail fold, and the hyponychium.⁵ The nail plate is the hard, slightly convex, translucent, rectangular structure that covers the distal part of the dorsal aspects of the digits and can further extend past their free edge.^{5,6} The cells that constitute the nail plate are anucleate, adherent, and flattened, situated in planes parallel to the plane of the nail plate.^{6–8} Three cutaneous folds border the proximal and lateral edges of the nail plate. Once the nail plate is removed, three grooves corresponding to the nail folds become apparent. These grooves are formed by the adjacent epidermis folding over the nail plate.^{5,6} The proximal nail fold has a dorsal surface, which is

a continuation of the dorsal epidermis, and a ventral surface adherent to the nail plate, termed the eponychium.^{3,5} The proximal nail groove is formed by this ventral surface (toward the dorsal aspect) and the nail matrix, which produces the nail plate, toward the ventral aspect of the digit. The part of the nail matrix, which extends past the proximal nail fold and is noticeable as a paler opacity with an arched border is termed the lunula.^{5,6} The nail bed is the vascular surface underneath the nail plate, extending from the nail matrix to the hyponychium.^{1,3,9} The hyponychium marks the transition from the nail bed to the epidermis of the digits and also extends beneath the free edge of the nail plate, serving as a protective layer.^{1,6}

Regarding the embryological aspects, Zaias et al.^{5,9,10} provide in three studies detailed information regarding the stages of evolution of the nail unit: the earliest signs of cell differentiation in relation to the nail appear at around 8 weeks, and the first macroscopic structures to be observed is the nail field bordered by nail grooves, at 9 weeks of gestation. The proximal nail groove shelters the cells of the future matrix. The distal nail groove separates the nail field from the epidermis on the volar surface of the fingers. At 11 weeks, a group of

cells emerges from the proximal nail groove and extends proximally into the digit, differentiating into the matrix primordium. Furthermore, in the distal half of the nail field appears the distal ridge, which will eventually differentiate into the hyponychium. At 13 weeks of gestation, the nail plate can be observed emerging from underneath the proximal nail fold, while at 20 weeks the matrix cells are completely differentiated. By the 32nd week, the nail unit consists of distinct structures.

Nail development has been a subject of interest since the 19th century, from both the phylogenetic and the ontogenetic point of view. Boas et al.^{11,12} compared in two studies the anatomy of nails of mammals and the claws of reptiles. Kolliker et al.¹³ and Zander et al.¹⁴ studied the development of nails in humans. In the 20th century, Zaias et al.^{5,9,10} and Lewis et al.¹⁵ have further clarified the aspects of nail embryology, observing the structures from both macroscopic and microscopic perspectives. Despite the early spark of interest, nail embryology has yet been analyzed by a relatively small number of scientists. Furthermore, in the last decades, embryology has been outclassed by concerns over pathological aspects regarding the nail apparatus.^{1,3,9,16} Most of the results of these previous studies, although accurate, have been subjected to constraints of a yet undeveloped technological realm. Given the continuous progress of the noninvasive methods of prenatal diagnosis, especially 3D ultrasound, this paper aims to clarify the macroscopic aspects of human nails embryology.

Materials and methods

In the Department of Anatomy of “Carol Davila” University of Medicine and Pharmacy, we performed a morphological analysis on 41 embryos and fetuses with gestational ages that varied between 6 and 29 weeks. The gestational ages have been established by measuring the crown-rump length of the subjects, in comparison to Carnegie staging system.

The specimens have been preserved in 10% neutral buffered formalin solution. Previously to the analysis, each specimen was removed from the formaldehyde solution and rested on a surgical tray for

half an hour. This procedure ensures the visibility of the small-scale features that could otherwise be deteriorated by manually drying attempts. Due to the fact that one fetus presented polydactyly in the lower limbs, a total of 412 fingers and toes have been subjected to the analysis, upon which nine fingers and toes were excluded from the results due to extensive deterioration, lesions or stains, thus examining a total of 403 fingers and toes. The specimens have been organized into five groups corresponding to the gestational ages, as follows: Group 1 is comprised of embryos between 6 and 8 weeks of gestation, Group 2 – between 8 and 12 weeks, Group 3 – between 12 and 15 weeks, Group 4 – between 15 and 25 weeks, and Group 5 – between 25 and 28 weeks of gestation.

High-resolution photos were taken of both fingers and toes using a dissection-microscope for the subjects in stages 1 and 2, while an HD camera was utilized for stages 3, 4, and 5. We analyzed the development of the nails in different stages of evolution. We also compared the differences between the development of the fingernails and toenails. Median and sagittal dissections of the distal phalanx of the pollex and hallux were performed on fetuses in Group 5 in order to further clarify the regional anatomy.

Procedures and the experiments we have done respect the ethical standards in the Helsinki Declaration of 1975, as revised in 2000 (5), as well as the national law. We have obtained written consent from all patients that agreed that their aborted products of conception to be used in research purpose. The study has ethical approval of Morphological Science Department of “Carol Davila” University of Medicine and Pharmacy.

Results

By morphologically evaluating the 41 embryos and fetuses, we established 5 chronological stages concerning the macroscopic features of a developing nail.

Group 1

Embryos in Group 1 display the first structure that can be observed, the nail field (Figure 1). It appears on the dorsal surface of the distal phalanx, as a

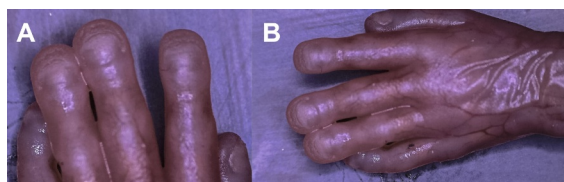


Figure 1. Macroscopic view of the dorsal aspect of fingernails in embryos pertaining to Group 1, using a dissection microscope. Note the convex, rectangular nail field bordered by the four nail grooves.

rectangular thickening of the epithelium bordered by four grooves. Each groove has an arched shape with the convexity facing the nail field, and each one continues the adjacent one. Out of the 15 specimens included in Group 1, 40% of the embryos present this feature in fingernails, as early as 7 weeks of gestation. However, the nail field is not yet recognizable in toes. The proximal groove is the deepest. It has an arched shape with transverse direction, with the apex located proximally and toward the midline of the digit. The two lateral grooves are smaller in length and more superficial. The distal groove is shallow at this point.

Group 2

In Group 2, the nail field of the fingers enlarges and becomes dome-shaped, heightening the proximal groove. The tissues that lay proximal to the nail unit portray a swollen aspect, as well (Figure 2). At this point, the nail complex has a clubbed nail appearance. This phenomenon, however, is only transitory. By the 9th week of gestation, the nail field of the toes becomes recognizable as well, bordered by equivalent nail grooves. The nail field is however more rectangular in shape, with the longer side perpendicular to the direction of the toes. Thus, the lateral nail grooves are significantly shorter than

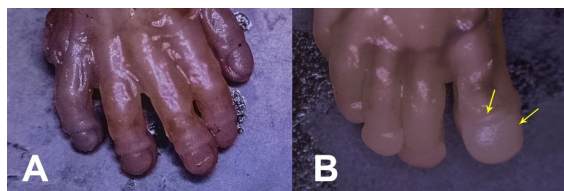


Figure 2. Fingernails (a) and toenails (b) of embryos in group 2. A: note the dome-shaped nail field and the heightened proximal nail groove in fingernails. B: the nail grooves are shallow and barely noticeable in toenails (yellow arrows).

the proximal groove, especially in toes 2–5. Furthermore, the proximal nail groove is concave in relation to the nail field, as opposed to the convex shape seen in fingers.

Group 3

The nail field has decreased in height in fingers of the subjects in Group 3, as early as 12 weeks of gestation (Figure 3). The proximal groove deepens and narrows, hidden at this point by the proximal nail fold. The nail plate becomes visible as a semi-circular, flat structure with smooth appearance, emerging from beneath the proximal nail fold. Proximally and parallel to the distal groove appears the distal ridge. In this stage, the ridge is hardly noticeable, having a blunt border. Regarding the toenails, the nail plate has not yet extended past the proximal nail field. Likewise, the distal ridge is not apparent.

Group 4

In fetuses in Group 4, the nail plate continues to grow toward the distal ridge, maintaining its arched shape and covering approximately half of the nail field by the 16th week of gestation (Figure 4). The distal ridge heightens and develops a sharp edge. In some cases, one to two smaller ridges with the same characteristics may appear parallel to it. The lateral

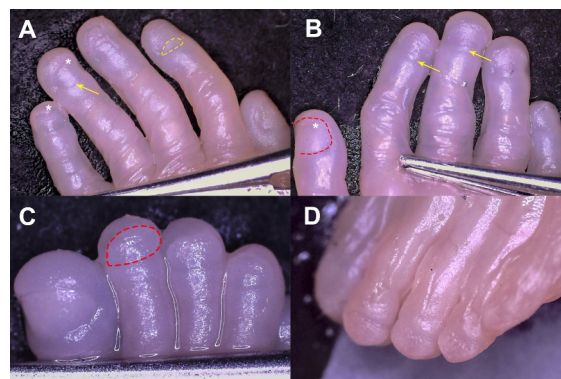


Figure 3. Macroscopic view of fingernails (a, b) and toenails (c, d) in subjects pertaining to Group 3. A, B: Note the distal ridge (asterisk), as well as the emergence of the nail plate (yellow dotted line). Yellow arrows mark the proximal nail fold. C: Toenail in this stage lack the aforementioned features. The red dotted line outlines the nail field, following the path of the four continuous nail grooves. D: Oblique-lateral view; note the convex trajectory of the distal nail groove.

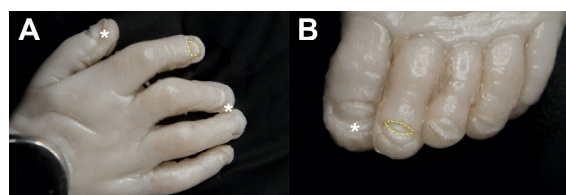


Figure 4. Fingernails (a) and toenails (b) in fetuses pertaining to Group 4. A: Note the nail plate with its arched distal border (yellow dotted line), covering half of the nail bed; the distal ridge is prominent in this stage (asterisk). Figure 4.B: The nail plate emerges from underneath the proximal nail fold (yellow dotted line); the asterisk marks the distal ridge.

and distal grooves have become deeper and narrower, having a more evident appearance. Folds of the epidermis on both the radial and ulnar sides of each fingernail become apparent, aiding this process. By the 20th week, the nail plate has covered two thirds of the future fingernail surface. The lateral nail folds now portray a more distinguishable appearance. In regard to the toenails, the nail plate emerges around the 18th week mark, and the distal ridge is distinguishable at this point (Figure 5). Both structures present the characteristics of a 12-week fingernail.

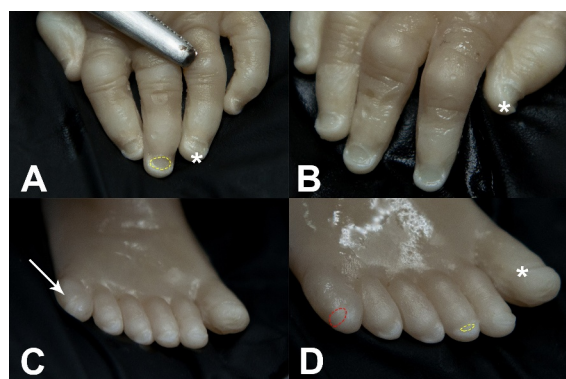


Figure 5. Fingernails (a, b) and toenails (c, d) of fetuses from Group 4; 20 weeks of gestation. A, B: The distal ridge (asterisk) maintains its height as the nail plate grows distally (yellow dotted line). C: Fetus with polydactyly. The arrow marks the supernumerary toe. D: Note the nail unit of the accessory toe, undeveloped in comparison to those of the other toes. The nail field is slightly noticeable, bordered by shallow nail grooves (red dotted line), whereas in the rest of the toes both the nail plate (yellow dotted line) and the distal ridge (marked with asterisks) are visible.

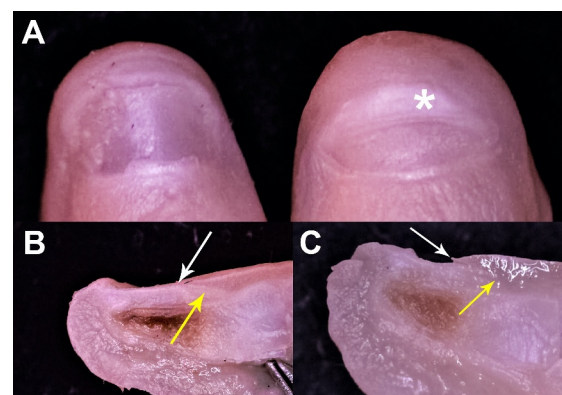

Figure 6. Pollex and hallux nail units (a) and corresponding sagittal sections (b, c) in fetuses pertaining to Group 5. A: The nail unit of the pollex resembles considerably the one of the adults. In toes, the distal ridge (asterisk) is still elevated and wide as the nail plate continues to extend. B: The proximal nail groove (yellow arrow) and nail fold (white arrow) are easily recognizable. Note the extending nail plate emerging from beneath the proximal nail fold. C: The nail fold (white arrow) is not completely attached to the nail plate; the proximal nail groove (yellow arrow) is shorter in comparison to fingernails.

Group 5

Group 5 fetuses present a flattened distal ridge in fingernails around 25 weeks, as the nail plate continues to grow (Figure 6.A.). The nail plate has a smooth, solid structure and is noticeably thicker. The distal groove becomes shallower and widens, while the lateral grooves are almost entirely concealed by the evolving nail plate. In this stage, the fingernail begins to resemble the features seen in adults. The only appreciable future modifications consist in thickness growth and the further extension of the nail plate that will reach and afterward cover the distal ridge. The 25-week nail plate in the toes covers approximately half of the nail surface. The distal ridge has lowered but remains strongly apparent in comparison to the fingers. Upon performing sagittal sections (Figure 6.B, 6.C.), the proximal nail groove in fingers clearly possesses a more defined appearance, with the dorsal and ventral surfaces tightly attached to either aspect of the growing nail plate. In toenails, the dorsal surface of this groove is not yet completely affixed to the nail plate. Furthermore, the length of the proximal nail groove is undoubtedly larger in fingers, compared to toes. The distances that the nail plate has reached as well as the height of the distal ridge are easily comparable.

Discussion

Nails represent a narrow area of human anatomy, in spite of their numerous and often undervalued functions. The embryological study of the nails is thus more a niche subject. Nevertheless, a number of dermatologists and other specialists have associated their names through their research with these structures. N Zaias is most prominently associated with the pioneering stages of the morphological development of the nails, as a result of his sustained analysis and numerous theses on the theme.^{5,9,10}

The chronology of the growth and differentiation stages of the nail unit in our study is consistent with the timeline established by Zaias et al.⁵ However, we have faced a few exceptions regarding the age at which these structures first appear. It is interesting that although in the early weeks of gestation there is a rather great discrepancy between previous results and ours, these differences tend to attenuate progressively and become consistent with the facts known this far as the fetuses advance in age. Concerning Group 1, we observed that the nail field becomes evident as early as 7 weeks of gestation. This statement comes in contrast to several studies that determined the earliest external changes take place at 9 or 10 weeks.^{1,3,5,6,9,17} However, the morphological appearance of both the nail grooves and nail field in fingers is consistent with the results of the aforementioned papers. We also noticed that the first structure to be recognized in toes develops at around 9 weeks. Given the fact that several studies mention a 4-week delay between the developments of the fingernails versus toenails, our observation supports a much shorter gap between the outsets of the aforementioned evolutionary steps.^{1,3,5} The macroscopic aspect of the distal ridge as described in subjects in Group 3 is consistent with the description provided by Zaias et al.⁵ Regarding the structures recognized in Group 4, the discrepancies are rather minor. We established that both the distal ridge and the nail plate appear at 12 weeks, while variant studies determined the age to be 11 weeks or 13 weeks of gestation, respectively.^{1,3,5,9,17} Zaias et al.⁵ state that by the 17th week, the nail plate covers almost the entire nail bed. Our research, on the other hand, denotes that the nail plate covers half of the nail bed

by the 16th week and two thirds by the 20th week, thus encountering a delay.

Although most papers portray the more or less constant a 4-week delay between the development of fingernails and toenails, our study determined an initial 2-week lag regarding the emergence of the nail field, which gradually increases to 9-weeks, with reference to the age by which the nail plate has covered half of the nail bed.^{1,3,5}

A 29-week fetus with Fraser syndrome was also included in the study. Although he presented syndactyly, our analysis determined that the distal phalanges did not have any abnormalities that could potentially affect the development of the fingernails; we expect further studies to conclude whether distal phalanx anomalies are linked in any manner to the potentially improper morphogenesis of the covering nail unit.

The disparities between our results and those of others may be attributed to several factors, such as the small number of subjects, the lengthy preservation in 10% neutered formalin of part of the specimens that led, to some extent, or damage of the more fragile elements. Additionally, our study focuses exclusively on macroscopic aspects, having to put aside the elements concerning histological and molecular transformations. Nonetheless, we hope that in the future, we may continue our study in order to determine the exact embryological stages of the fingernail and toenail development.

Conclusions

Fingernail development begins, from a macroscopic perspective, at 7 weeks of gestation. Four nail grooves border the nail field. The proximal nail groove deepens and becomes covered by a fold of tegument, the nail fold. At 12 weeks of gestation, the nail plate emerges from beneath the nail fold and extends distally in order to cover the entire nail field. Toenails undergo equivalent transformations following the pattern presented in fingernails. However, toenail development and differentiation are delayed in comparison to fingernails.

Conflicts of Interest

The authors declare no conflict of interest.

Funding

This research received no external funding.

ORCID

Roxana Elena Bohiltea  <http://orcid.org/0000-0002-6381-7419>

References

- Jiaravuthisan MM, Sasseville D, Vender RB, Murphy F, Muhn CY. Psoriasis of the nail: anatomy, pathology, clinical presentation, and a review of the literature on therapy. *J Am Acad Dermatol.* 2007;57(1):1–27. doi:10.1016/j.jaad.2005.07.073..
- Murdan S. Drug delivery to the nail following topical application. *Int J Pharm.* 2002;236(1–2):1–26. doi:10.1016/s0378-5173(01)00989-9..
- Baran R, De Berker DA, Holzberg M, Thomas LB. Dawber's diseases of the nails and their management. John Wiley & Sons; 2012. p. 15–40. Baran R, De Berker DA, Holzberg M, Thomas LB. Dawber's diseases of the nails and their management. John Wiley & Sons; E-Book ISBN 978-1-118-28670-8, 2012. p. 15–40.
- Scher RK, Daniel CR III. Nails: therapy, diagnosis, surgery. Philadelphia (PA): W.B. Saunders Company; 2003. p. 39–82.
- Zaias N. Embryology of the human nail. *Arch Dermatol.* 1963;87(1):37. doi:10.1001/archderm.1963.01590130043010..
- Fleckman P, McCaffrey L. Structure and function of the nail unit. Rubin AI, Jellinek NJ, Daniel III CR, Scher RK, Scher, Nails D, editors. *Diagnosis, Surgery, Therapy.* 4th ed. Springer International Publishing; 2018. 83–97. Fleckman P, McCaffrey L. Structure and function of the nail unit. Rubin AI, Jellinek NJ, Daniel III CR, Scher RK, Scher, Nails D, editors. *Diagnosis, Surgery, Therapy.* 4th ed. Springer International Publishing; Switzerland. 2018. 83–97.
- Forslind B. Biophysical studies of the normal nail. *Acta Derm Venereol.* 1970;50(3):161–68. PMID: 4193212. doi:10.2340/0001555550161168.
- Caputo R, Dadati E. Preliminary observations about the ultrastructure of the human nail plate treated with thio-glycolic acid. *Arch Klin Exp Derm.* 1968;231(4):344–54. doi:10.1007/BF00517687..
- Zaias N. The nail in health and disease. Dordrecht: Springer International Publishing; Switzerland. 1980. 1–30.
- Zaias N, Alvarez J. The formation of the primate nail plate. An autoradiographic study in squirrel monkey. *J Invest Dermatol.* 1968;51(2):129–36. doi:10.1038/jid.1968.103..
- Zur BJ. *Morphologie der Wirbeltierkrallen, Gegenbauers Morpholog. Jahrbuch, Bd.* Leipzig: Wilhelm Engelmann 1894. p. 21.
- Boas JEV. Ein Beitrag zur Morphologie der Nägel, Krallen, Hufe und Klauen der Säugethiere. *Morphologisches Jahrbuch* 1884;9:389–99.
- Von Kölliker A. Die Entwicklung des menschlichen Nagels, *Z. Wiss. Zool.* Leipzig: Wilhelm Engelmann Vol. 7, 1888.
- Zander R. Die frühesten Stadien der Nagelentwicklung und ihre Beziehung zu den Digitalnerven. *Arch Anat Entwickl.* 1884;103-144.
- Lewis BL. Microscopic studies of fetal and mature nail and surrounding soft tissue. *AMA Arch Derm Syphilol.* 1954;70(6):732–47. PMID: 13206419. doi:10.1001/archderm.1954.01540240038005.
- Rand R, Baden HP. Pathophysiology of nails-onychopathophysiology. In: Soter NA, Baden HP, editors. *Pathophysiology of dermatologic diseases.* New York (NY): McGraw-Hill; 1991. p. 209.
- Telfer NR, Barth JH, Dawber RP. Congenital and hereditary nail dystrophies-an embryological approach to classification. *Clin Exp Dermatol.* 1988;13(3):160–63. doi:10.1111/j.1365-2230.1988.tb01960.x.