


Frontal Inverted Papillomas: A 25-Year Study

Cheuk Lun Sham, MD; C. Andrew van Hasselt, MMED(Otol); Samuel M. W. Chow, FRCS(Ed);
Dennis L. Y. Lee, FRCS(Ed); Ryan H. W. Cho, FRCS(Ed); John K. S. Woo, FRCS(Ed);
Michael C. F. Tong, MD 

Objectives/Hypothesis: This study analyzes the treatment outcomes of frontal inverted papillomas (FIPs) in an attempt to provide guidelines for surgery selection.

Study Design: Retrospective case series.

Methods: The treatment results of 29 FIPs classified into five categories were retrospectively analyzed. The five categories are F1, tumor prolapsed into frontal sinus, tumor origin outside frontal sinus; F2, tumor origin inside frontal sinus, medial to the plane of lamina papyracea; F3, tumor origin inside frontal sinus, lateral to the plane of lamina papyracea; F4, bilateral; and F5, extranasal.

Results: Of the 11 F1 cases, 73% had Draf I and 27% had Draf IIA procedures. There was one (9%) frontal recurrence and one (9%) frontal stenosis. Of the 10 F2 cases, 10% had Draf I, 40% had Draf IIA, 40% had Draf IIB, and 10% had Draf III surgery with a trephination. One patient (10%) had a frontal recurrence. Of the five F3 cases, 40% had Draf IIA surgery, 20% had external frontoethmoidectomy, and 40% had external frontal sinusotomy. The recurrence rate was 60%, and frontal stenosis rate was 60%. The two F4 cases had external frontal sinusotomies and Draf III surgery with no frontal recurrence or stenosis. The patient with the F5 had a frontal recurrence after Draf IIA surgery and external frontoethmoidectomy.

Conclusions: Draf I or IIA surgery is adequate for most F1 tumors, and Draf II surgery is adequate for most F2 tumors. F3 and F4 tumors can be managed initially by Draf III surgery with external frontal sinusotomy added when required. F5 tumors probably require combined surgical approaches.

Key Words: Frontal sinus, inverted papilloma, treatment results, endoscopic, sinus surgery.

Level of Evidence: 4

Laryngoscope, 130:1622–1628, 2020

INTRODUCTION

Frontal inverted papillomas (FIPs) affecting the frontal sinus is uncommon and accounts for <10% of all sinonasal inverted papillomas.^{1–4} A recent systematic review showed that the overall recurrence rate of FIP is 22.4%, which is relatively high compared to inverted papillomas affecting the maxillary and ethmoid sinuses. This is attributable to the technical difficulties associated with operating in and around the frontal sinus and proximity to the neighboring critical structures.⁵ Previous staging systems group all FIPs into one category.^{6,7} Recent publications emphasize the importance of identifying the tumor origin, not only for complete disease removal but also to guide the choice of surgical approach.^{8–14} Because FIP is a heterogeneous group of tumors with different origins and hence technical demands for their treatment, the choice of surgery may vary according

to the location of tumor origin. This article analyzes retrospectively the treatment results of 29 FIPs classified by an origin-based classification in an attempt to provide guidelines for selection of surgical approach.

MATERIALS AND METHODS

Twenty-nine patients with FIP managed from 1992 to 2016 were included for analysis. Fungiform and cylindrical cell papillomas were excluded. The study was approved by the Joint Chinese University of Hong Kong–New Territories East Cluster Clinical Research Ethics Committee (CRE: 2016.600). The surgeries were performed by the first five authors of this article. All patients had a minimum follow-up of 2 years. Information detailing the tumor origin, surgical approach, any complication, recurrence, and revision surgery was gathered and analyzed. Tumors were classified into five categories according to the location of tumor origin determined intraoperatively (Table I, Fig. 1). The frontal opening, defined anteriorly by the frontal beak and posteriorly by the junction of the anterior skull base and the posterior wall of the frontal sinus, was used as the anatomical landmark to differentiate F1 from F2 tumors. The plane of the lamina papyracea was used to distinguish F2 from F3 tumors because it is an easily definable intraoperative reference landmark to differentiate the more easily accessible central tumors from the more difficult peripheral tumors.

All patients had preoperative computed tomography (CT) scans of their sinuses, preoperative histological diagnosis, and consent for endoscopic resection and extended resection via external approaches if deemed necessary during surgery. All patients were operated on under general anesthesia. Bulky

This is an open access article under the terms of the Creative Commons Attribution-NonCommercial License, which permits use, distribution and reproduction in any medium, provided the original work is properly cited and is not used for commercial purposes.

From the Department of Otorhinolaryngology–Head and Neck Surgery, Chinese University of Hong Kong, Hong Kong.

The authors have no funding, financial relationships, or conflicts of interest to disclose.

Editor's Note: This Manuscript was accepted for publication July 31, 2019.

Send correspondence to Michael C. F. Tong, MD, 6/F, Lui Che Woo Clinical Sciences Building, Prince of Wales Hospital, New Territories, Shatin, Hong Kong. E-mail: mtong@ent.cuhk.edu.hk

DOI: 10.1002/lary.28245

TABLE I.
Classification of Frontal Inverted Papillomas According to Tumor Origin.

Group	Location of Tumor Origin
F1	Tumor origin all outside frontal sinus, tumor prolapsed into frontal sinus
F2	Tumor with part or all of the origin from the frontal sinus walls or its opening, medial to the plane of lamina papyracea
F3	Tumor with part or all of the origin from the frontal sinus walls lateral to the plane of lamina papyracea
F4	Tumor involving both frontal sinuses (tumor origin inside or outside the frontal sinuses)
F5	Tumor with extrasinonasal involvement (tumor origin inside or outside the frontal sinuses)

exophytic tumors were resected using forceps and/or a microdebrider under endoscopic control until the tumor origin was clearly defined. Following resection, the location of the tumor base was cauterized and if necessary, polished with a microdrill. Tumor origins accessible by the endoscopic route were managed by Draf I, II, or III procedures. For those in which endoscopic access to the tumor origin was found to be inadequate during surgery, a combination of external and endoscopic approaches was used to achieve total tumor resection in one surgery. The most common external approach was open frontal sinusotomy via an eyebrow incision in unilateral cases or a central butterfly incision when tumors were bilateral. Frontoethmoidectomy via the Lynch incision was used only in the early cases of the learning process and avoided later because of its limited exposure and significant postoperative stenosis. If deemed necessary, a Draf III procedure was added with the intention of avoiding postoperative frontal stenosis.

All patients were advised to undergo lifelong follow-up. Frontal stenosis was defined as an opening too small for endoscopic frontal sinus disease surveillance. Small and accessible recurrent disease was resected and cauterized in the outpatient clinic under local anesthesia. Large and inaccessible recurrences were resected under general anesthesia with or without external approaches, depending on the severity and location of the disease.

RESULTS

There were 29 patients operated on between 1992 and 2016, with follow-up of more than 2 years. Twenty-eight patients were disease free and one patient had residual disease pending further surgery. The disease-free follow-up of the 28 patients ranged from 1 month to

21 years (mean = 4.7 years). The male to female ratio was 3:1. The age of patients ranged from 36 to 80 years (mean = 55 years). Eleven patients (38%) had undergone previous surgery. Only six of these 11 patients had a clinical record of the original tumor origins, which were the same as those of the recurrent tumors. There were 27 unilateral (93%) and two bilateral tumors (7%). There was one tumor with extrasinonasal extension to the orbit (3.5%). There was no associated dysplasia or malignancy.

The tumors were classified into five categories (Table I). There were 11 F1 (38%), 10 F2 (35%), five F3 (17%), two F4 (7%), and one F5 (3.5%) tumors. The details of the patients in each category, their treatment procedures, intraoperative complications, postoperative complications, treatment outcomes, and whether or not they required revision surgery are listed in Tables II–VI.

The overall frontal sinus recurrence rate was 21%. The frontal recurrence rates for the individual groups were: F1, 9%; F2, 10%; F3, 60%; F4, 0%; and F5, 100%. The overall complication rate was 21%, which included frontal stenosis (14%), mucocele, orbital hematoma (4%), and cerebrospinal fluid (CSF) leakage (4%). The frontal stenosis rates for the individual groups were: F1, 11%; F2, 10%; F3, 60%; F4, 0%; and F5, 0%. Among the 28 disease-free patients, 22/28 (79%) were managed with endoscopic surgery alone, and 6/28 (21%) required combined approaches to achieve disease-free status.

One of the 11 patients with an F1 tumor (9%) had undergone previous surgery. Seven F1 tumors (64%) originated from the ethmoid sinus, two (18%) from the frontal recess, and two (18%) from the middle turbinate. Eight patients (73%) had Draf I, and three patients (27%) had Draf IIA procedures. Three patients (27%) who had Draf I surgery had local recurrences at the frontal recess and ethmoid area, including two successfully resected under local anesthesia in the outpatient clinic and one successfully resected under general anesthesia. One patient (9%) who had Draf I surgery had a frontal sinus recurrence successfully resected by Draf IIA surgery under general anesthesia. One patient (9%) who had Draf IIA surgery had postoperative frontal stenosis. The mean disease-free follow-up for this group was 3.7 years.

Five of the 10 patients with F2 tumors (50%) had undergone previous surgery. Seven F2 tumors (70%) originated from the frontal sinus, either from the medial wall

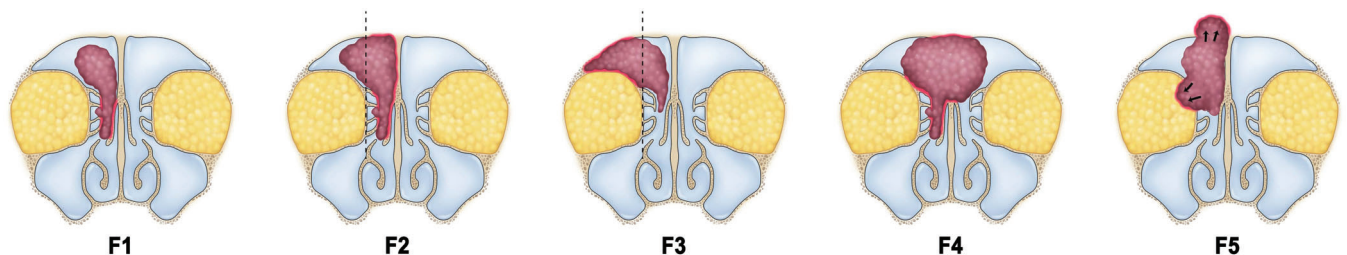


Fig. 1. Five categories of FIP. F1, tumor origin outside frontal sinus, tumor prolapsed into frontal sinus. F2, tumor origin inside frontal sinus, origin medial to the plane of lamina papyracea. F3, tumor origin inside frontal sinus, origin lateral to the plane of lamina papyracea. F4, bilateral FIP, tumor origin inside or outside frontal sinus. F5, FIP with extrasinonasal extension, tumor origin inside or outside frontal sinus). Red outline indicates tumor origin. FIP = frontal inverted papilloma.

TABLE II.
F1 (Tumor Origin Outside Frontal Sinus, Tumor Prolapsed Into Frontal Sinus).

Case	Prev	Sex/Age, yr	Location	Surgery	Complication	Recurrence	Revision	DFFU, yr
1	No	M/53	L ethmoid	1998 Draf I	0	0	0	4
2	No	M/43	R ethmoid	2000 Draf I	0	Fr sinus	GA	0.8
3	No	M/65	L mid-turb	2008 Draf I	0	0	0	10
4	Yes	M/38	R ethmoid	2008 Draf I	0	0	0	10
5	No	M/68	L mid-turb	2013 Draf I	0	0	0	4
6	No	M/55	R fr recess	2013 Draf IIA	0	0	0	4
7	No	F/71	R ethmoid	2014 Draf I	0	Ethmoid	OPD	1
8	No	M/56	R fr recess	2014 Draf IIA	0	0	0	3
9	No	F/45	L ethmoid	2015 Draf I	0	Fr recess	OPD	1
10	No	F/41	L ethmoid	2015 Draf I	0	Ethmoid	GA	1
11	No	M/59	L ethmoid	2016 Draf IIA	Fr stenosis	0	0	2

DFFU = disease-free follow-up; Fr = frontal; GA = general anesthesia; L = left; mid-turb = middle turbinate; OPD = outpatient department; Prev = previous surgery; R = right.

or posterior wall or both; one (10%) had its origin involving an intersinus septal cell, one (10%) involved the frontal sinus opening, one (10%) involved a Kuhn III cell, and one (10%) involved the walls of a hypoplastic frontal sinus. One patient (10%) had Draf I, four patients (40%) had Draf IIA, four patients (40%) had Draf IIB, and one patient (10%) had Draf III surgery with trephination of the frontal sinus. Two patients (20%) had surgical complications, one of which was a CSF leak after Draf III surgery with trephination, whereas the other was an orbital hematoma and subsequent ethmoid mucocele after Draf IIA surgery. The overall complication rate in this group was 20%. Three patients (30%) had recurrences localized at the frontal recess after Draf IIB surgery and successful resection under local anesthesia in the outpatient department. There was one frontal sinus recurrence (10%) after Draf III surgery and trephination requiring endoscopic stripping under general anesthesia. The mean disease-free follow-up was 3.1 years.

Four of the five patients with F3 tumors (80%) had undergone previous surgery. Four F3 tumors (80%) had

origins involving the frontal sinus walls, with one (20%) involving a type 4 Kuhn's cell, and four (80%) had extended origins from the ethmoid sinus. Two patients (40%) had Draf IIA surgery, one patient (20%) had an external frontoethmoidectomy, and two patients (40%) had external frontal sinusotomies. Three patients (60%) had postoperative frontal stenosis. The frontal stenosis rates were: Draf IIA surgery, 50%; external frontoethmoidectomy, 100%; and external frontal sinusotomy, 50%. Three patients (60%) had frontal sinus recurrence. The recurrence rate for Draf IIA surgery versus external approaches was 100% versus 33%. Of the two patients with frontal sinus recurrence after Draf IIA surgery, one had revision Draf IIA surgery, whereas the other had an external frontal sinusotomy and Draf III surgery. The patient with frontal sinus recurrence after external frontal sinusotomy had revision external frontal sinusotomy. Overall, 4/5 (80%) patients in this group required a combined approach (either in their initial surgery or in the revision surgery) to achieve disease-free status at their latest follow-up (Table VI). There were two patients (40%) with frontal stenosis at their latest follow-up and were unsuitable for further surgery

TABLE III.
F2 (Tumor Origin Inside Frontal Sinus, Origin Medial to the Plane of Lamina Papyracea).

Case	Prev	Sex/Age, yr	Location	Surgery	Complication	Recurrence	Revision	DFFU, yr
1	Yes	M/56	L ethm, fr med wall, ISSC	2007, Draf IIB	0	Fr recess	OPD	7
2	No	M/51	L fr med wall, L Fr post wall	2010, Draf III, trephine	CSF leak	Fr sinus	GA endo, stripping	3
3	Yes	M/52	L ethm, L fr post wall	2011, Draf IIB	0	Fr recess	OPD	6
4	Yes	M/60	L ethm, L fr med wall	2011, Draf IIB	0	Fr recess	OPD	3
5	Yes	F/53	R fr ostium	2011, Draf IIA	Orbital hematoma, ethm mucocele	0	0	7
6	No	F/51	R fr med wall, R fr post wall	2013, Draf IIA	0	0	0	4
7	Yes	M/59	L fr Kuhn III cell	2013, Draf IIA	0	0	0	4
8	No	M/52	R ethm, R fr post wall	2015, Draf I	0	0	0	2
9	No	M/67	L fr post wall	2015, Draf IIB	0	0	0	2
10	No	M/61	R ethm, R fr sinus, hypoplastic	2016, Draf IIA	0	0	0	1.5

CSF = cerebrospinal fluid; DFFU = disease-free follow-up; endo = endoscopic; ethm = ethmoid; F = female; fr = frontal; GA = general anesthesia; ISSC = intersinus septal cell; L = left; M = male; med = medial; OPD = outpatient department; post = posterior; Prev = previous surgery; R = right.

TABLE IV.
F3 (Tumor Origin Inside Frontal Sinus, Origin Lateral to the Plane of Lamina Papyracea).

Case	Prev	Sex/Age, yr	Location	Surgery	Complication	Recurrence	Revision	DFFU, yr
1	Yes	F/58	R ethm, fr inf wall	1992 ext fronto ethmoidectomy	Fr stenosis	0	0	21
2	Yes	F/53	L ethm, fr med wall, fr post wall	2002 ext fronto sinusotomy	0	Fr med wall	Ext fronto sinusotomy	8
3	Yes	M/36	L ethm, L fr inf wall	2003 Draf IIA	Fr stenosis	Fr post wall L fr, bilateral fr, nose lat wall	OPD 2005 ext fr sinusotomy, 2007 ext fr sinusotomy, Draf III, OPD	4
4	Yes	M/80	L ethm, supraorbital, fr sup wall, fr med wall	2008 ext fronto sinusotomy	Fr stenosis	0	0	10
5	No	M/57	L Kuhn 4 cell	2012 Draf IIA	0	Fr Kuhn4cell	2013 Draf IIA	4

CX = complication; DFFU = disease-free follow-up; ethm = ethmoid; ext = external; F = female; fr = frontal; inf = inferior; L = left; lat = lateral; M = male; med = medial; OPD = outpatient department; post = posterior; Prev = previous surgery, R = right; sup = superior.

TABLE V.
F4 (Bilateral Frontal Inverted Papilloma, Tumor Origin Inside or Outside Frontal Sinus).

Case	Pre	Sex/Age, yr	Location	Surgery	Complication	Recurrence	Revision	DFFU, yr
1	Yes	M/44	Bilat fr med, L ethm	2008 ext fr sinusotomy, Draf III	0	L post ethm	OPD	5
2	No	M/59	Bilat fr med, R fr lat	2015 ext fr sinusotomy, Draf III	0	0	0	2

Bilat = bilateral; DFFU = disease-free follow-up; ethm = ethmoid; ext = external; fr = frontal; L = left; lat = lateral; M = male; med = medial; OPD = outpatient department; Pre = previous surgery; post = posterior; R = right.

because of old age. The mean disease-free follow-up was 8.8 years.

There were two patients with F4 tumors, one of whom had undergone previous surgery. Both tumors had origins involving the medial wall of both frontal sinuses, and one of these tumors had the origin extending to the lateral wall of the frontal sinus. Both patients had an external frontal sinusotomy and Draf III surgery. There was no surgical complication or frontal sinus recurrence. One patient had a small localized ethmoid recurrence that was successfully endoscopically resected under local anesthesia in the outpatient department. The mean disease-free follow-up was 3.3 years.

The patient with an F5 tumor had no previous surgery. The tumor involved the posterior and lateral walls of the right frontal sinus with extension to the periorbita. The patient had both frontal and ethmoid recurrences after Draf IIA surgery and external frontoethmoidectomy. He refused further external surgery after two failed endoscopic revisions.

DISCUSSION

There have been meaningful advances in the management of sinonasal inverted papilloma over the past

few decades. Firstly, the origin should be deliberately identified and the base drilled and cauterized with the intention of eradicating tumor buried in crevices of the underlying bone, and there is agreement that residual disease is usually due to inadequate treatment of the tumor origin.^{3,12,15-17} Secondly, pedicle-orientated surgery is becoming the accepted norm.⁸⁻¹⁴ Thirdly, improvement in surgical instrumentation enables more precise tumor identification, drilling, and removal from hidden areas within the sinuses. Fourthly, progressive evolution of surgical techniques enables flexible yet effective application of different surgical procedures.

Walgama et al. reported a systematic analysis of 49 cases of FIP from 13 studies. Half (51%) of these patients had undergone previous surgery, 16.3% had bilateral frontal sinus involvement, and the overall recurrence rate was 22.4%.⁵ In our series, 38% of patients had previous surgery, 7% of cases had bilateral frontal sinus involvement, and the frontal sinus recurrence rate was 21%. The high percentage of patients having previous surgery, particularly in the F2 (50%), F3 (80%), and F4 (50%) groups of our study, and the finding that all the recurrences were of the same origin as the initial tumors suggest that these were residual tumors resulting from

TABLE VI.
Final Surgery Received and Status of the 28 Disease-Free Patients at Their Latest Follow-up.

Class	No.	Draf I	Draf IIA	Draf IIB	Draf III	Combined	Stenosis
F1	11	7/11 (64%)	4/11 (36%)	0	0	0	1/11 (9%)
F2	10	1/10 (10%)	4/10 (40%)	4/10 (40%)	1/10 (10%)	0	0
F3	5	0	1/5 (20%)	0	0	4/5 (80%)	2/5 (40%)
F4	2	0	0	0	0	2/2 (100%)	0

Combined means combined endoscopic and external surgical approach. Stenosis means frontal stenosis.

TABLE VII.
Comparison of Treatment Results of Recent Publications.

Category	Series	No.	Surgical Approach	Frontal Recurrence	Stenosis/Mucocele
F1 (prolapsed tumor)	Kamel et al., 2012	4	Draf I, Draf II	0	0
	Adriaensen et al., 2015	6	Draf IIB	0	0
	Peng et al., 2015	8	Draf IIB	0	3 (38%)
	Verillaud et al., 2016	4	Draf I, Draf II	0	1 (25%)
	Sham et al., 2019	11	Draf I, Draf IIA	1 (9%)	1 (9%)
	Total	33		1 (3%)	5 (15%)
F2 (unilateral central tumor)	Peng et al., 2015 (origin medial to pupil center line)	7	Draf IIB	1 (14%)	3 (43%)
	Verillaud et al., 2016 (origin medial, inferior)	10	Draf IIB, Draf III	0	2 (20%)
	Sham et al., 2019 (origin medial to lamina papyracea)	10	Draf I, Draf II, Draf III	1 (10%)	1 (10%)
	Total	27		2 (7%)	6 (22%)
F3 (unilateral peripheral tumor)	Yoon et al., 2009 (origin lateral, multiple)	8	Trephine, Draf III, combined	3 (38%)	0
	Verillaud et al., 2016 (origin distal location)	13	Combined	2 (15%)	7 (54%)
	Sham et al., 2019 (origin lateral to lamina papyracea)	5	Draf IIA, frontoethmoidectomy, combined	3 (60%)	3 (60%)
	Total	26		8 (31%)	10 (39%)
F4 (bilateral tumor)	Yoon et al., 2009	2	Draf III, combined	0	0
	Kamel et al., 2012	1	Draf III	0	0
	Adriaensen et al., 2015	6	Draf III	1 (17%)	0
	Sham et al., 2019	2	Combined	0	0
	Total	11		1 (9%)	0

Combined surgical approach means endoscopic with external frontal sinusotomy.

inadequate initial treatment of the tumor origin or failure to resort to additional approaches in inaccessible tumors.

There are only a few recent reports of treatment results based on categorizations of tumor origin that were similar to our classification with respect to unilateral tumors prolapsed into the frontal sinus (F1) and bilateral tumors (F4) (Table VII). The main difference among these series lies in the dividing line between central and peripheral origin in unilateral tumors with intrasinus origins. Our concept of using the lamina papyracea as an intraoperative landmark stems from previous staging systems of sinonasal papilloma, in which medial and superior maxillary tumors were differentiated from those involving the other walls of the maxillary sinus.^{6,7} Although most recent reports on FIP provided a gross differentiation of the intrasinus tumor origin, one report used a specific reference landmark, the pupil center line, which is slightly lateral to the plane of the lamina papyracea used in our series.¹³ Although the pupil center line is easy to determine on radiological films, its intraoperative determination could be difficult. Although the total number of cases is still too small for the validation of any categorization system, meaningful preliminary observations can be made comparing these reports (Table VII).

In our series, 73% of F1 patients had Draf I procedures and only 27% required a Draf IIA procedure, because the majority of tumors could be delivered easily into the nasal cavity without enlargement of the frontal sinus opening, which resulted in low recurrence (9%) and complication (9%) rates. Comparable results in the F1 category are reported in other series.^{10,12,14} In Peng et al.'s series, there was no recurrence in the eight cases of FIP with non-frontal sinus origin

treated by Draf IIB surgery.¹³ However, three patients had frontal outflow tract problems (38%), including two closures and one mucocele.¹³ Overall, the low average rate of recurrence (3%) and frontal outflow tract obstruction (15%) in the 33 F1 cases analyzed suggest that Draf I or II surgery is usually adequate for F1 tumors (Table VII). However, extensive drilling in the Draf IIB surgery increases the risk of frontal sinus outflow tract problems.

In our study, 80% of patients with F2 tumors were successfully treated with Draf II procedures. The low frontal sinus recurrence rate (10%) and mucocele rate (10%) reflects the adequacy of the Draf II procedure in providing tumor access, removal, and establishment of a patent outflow tract for disease surveillance in these patients. Verillaud et al. reported 10 cases with both frontal recess and frontal infundibulum origin that were more medially and inferiorly situated than those with frontal sinus origin.¹⁴ In their report, Draf IIB surgery was used in nine cases (90%), Draf III surgery was used in one case (10%), and there were no recurrences.¹⁴ Two patients (20%) had postoperative mucocoeles.¹⁴ In Peng et al.'s series, there was one recurrence (14%) in the seven FIPs, the origin of which was medial to the pupil center line and was treated by Draf IIB surgery.¹³ There were three patients (43%) with frontal sinus outflow tract problems including one closure and two stenoses.¹³ Although different reference landmarks have been used in these studies, they share our view that the centrally located tumors are more easily accessible and should be differentiated from the more technically demanding peripheral tumors. Overall, analysis of these 27 centrally located FIPs show a low recurrence rate (7%) but a

significant rate of frontal outflow tract obstruction (22%). Draf I and III surgeries were rarely used, and Draf IIB was the most commonly employed surgery for this group of tumors.^{9,13,14} Special care should be taken in Draf IIB surgery to ensure a patent frontal sinus outflow tract.^{13,14}

In our series of patients, 2/5 (40%) with F3 tumors had Draf IIA surgery, 1/5 (20%) had an external frontoethmoidectomy, and 2/5 (40%) had external frontal sinusotomy. In the patients with Draf IIA surgery, the recurrence rate was 2/2 (100%), and the rate of frontal stenosis was 1/2 (50%). In the patients with external approaches, the recurrence rate was 1/3 (33%), and the frontal stenosis rate was 2/3 (67%). Overall, 4/5 (80%) of the patients in this group required a combined approach to achieve disease-free status, and 2/5 (40%) patients still had frontal stenosis at their latest follow-up (Table VII). In Verillaud et al.'s series, there were 13 patients with tumors originating from a distal location of the frontal sinus who were treated by combined endoscopic and external approaches.¹⁴ The frontal sinus recurrence rate was 2/13 (15%) and frontal mucoceles occurred in 7/13 (54%).¹⁴ In Yoon et al.'s series, eight patients who had tumors originating from the lateral wall or multiple walls had endoscopic sinus surgery with or without trephination, endoscopic modified Lothrop procedure, or osteoplastic frontal sinus surgery.⁹ The recurrence rate was 3/8 (38%). Two patients had CSF leaks, one following endoscopic sinus surgery and the other after endoscopic modified Lothrop procedure and trephination.⁹ When compared with the results of these two studies, it is clear that Draf IIA surgery in our earlier cases were associated with a very high recurrence rate (100%) and inadequate in managing laterally situated FIPs. The much lower recurrence rate (15%) in Verillaud et al.'s series demonstrates the advantage of the combined approach in managing tumors originating from distal locations of the frontal sinus. The high rate of frontal stenosis and mucocele in Verillaud et al.'s series and our series is possibly related to extensive surgery in the frontal outflow tract in both the endoscopic and external surgical groups. We believe this may be improved by additional enlargement of the frontal opening via a Draf III approach. Recent publications suggest that using a mucosal graft or flap in the frontal opening may reduce the chance of postoperative frontal stenosis and mucocele formation.^{13,14,18} Overall, the relatively high rate of recurrence (31%) and frontal outflow tract obstruction (39%) associated with these peripheral tumors suggests that although Draf III surgery should be tried as the initial approach for F3 tumors, an external frontal sinusotomy should be added when required in inaccessible tumors, and extra care should be taken to ensure a patent frontal sinus outflow tract (Table VII).

In our study, there was no frontal sinus recurrence or stenosis in the two patients with F4 tumors managed by Draf III surgery and external frontal sinusotomy. In Adriaensen et al.'s series of 20 FIPs, there was one recurrence out of the six bilateral frontal FIPs all treated by Draf III surgery.¹² However, it is important to note that 4/6 (67%) of their cases had topical application of 5-fluorouracil to the surgical sites.¹² In Yoon et al.'s study, there was also no recurrence or stenosis in the two patients with bilateral frontal sinus tumors managed by osteoplastic frontal sinus surgery and endoscopic modified Lothrop procedure, respectively.⁹ Overall, the low recurrence rate (9%) and absence of

frontal outflow tract obstruction in these 11 bilateral FIPs analyzed suggest that Draf III surgery combined with external frontal sinusotomy when required provide good access and large frontal sinus opening and should be the surgery of choice for most F4 tumors (Table VII).

There are very few cases of inverted papillomas with extrasinonasal extension reported in the literature.^{19,20} In our series, the only patient with F5 tumor extending to the orbit had frontal sinus recurrence after Draf IIA surgery and external frontoethmoidectomy. Further revision surgery for this patient would be an endoscopic approach combined with external frontal sinusotomy. A recent publication suggests that this group of tumors may be managed by combining endoscopic with a transpalpebral miniorbitofrontal craniotomy.¹⁹ A recent review on inverted papillomas with intracranial extension found that craniofacial resection has been the surgery of choice because of its associated low recurrence rate, and the role of endoscopic surgery alone is still to be determined.²⁰

As there is marked variation in the configuration and degree of pneumatization of the frontal sinus, it is understandable that there is significant variation in the technical demand of tumors even within each of the five categories. Nevertheless, the plane of the lamina papyracea provides an easily definable intraoperative reference to differentiate the less technically demanding central tumor from the more demanding peripheral tumor. This plane provides information for choosing the initial surgical approach, which may be modified according to the difficulty encountered during surgery, provided there is careful preoperative patient counseling and consent.

This study reflects the learning process of a group of operators with different experience over a 25-year time span, during which there have been major changes in the understanding of the pathology, surgical instrumentation, techniques, and concepts of management. Traditional frontoethmoidectomy via the Lynch incision for F3 tumor has been abandoned because of its potential drawbacks of inadequate exposure and postoperative stenosis (case 1 in Table IV). It is clear that suboptimal treatment was provided in the initial surgery in some of the early F1 and F3 cases because of insufficient evaluation, diagnosis, and treatment of the tumor origin; incorrect choice of surgical approach; and/or failure to convert to more extensive or open approaches for inaccessible tumors (case 2 in Table II, case 3 in Table IV). Given the aforementioned, the above recurrences and stenoses are potentially avoidable. The current aim of surgery is not only complete tumor excision but also provision of a patent frontal sinus outflow tract for disease surveillance all achieved by one surgery.

FIP is an uncommon disease that makes a long-term, prospective, randomized trial difficult to accomplish. Although limited by the small number of subjects and the retrospective nature of this study, this analysis provides a reference for selecting a surgical approach according to the intraoperative nature of the tumor origin.

CONCLUSION

This retrospective analysis of treatment results of 29 FIPs provides a guideline for the selection of an

operative approach according to the location of tumor origin. F1 tumors can usually be managed by Draf I or Draf IIA surgeries. Draf II surgery is usually adequate for F2 tumors. F3 and F4 tumors may be managed initially by Draf III surgery, and an external frontal sinusotomy must be considered when difficult access is encountered. F5 tumors probably require a combined endoscopic and external approach. Future prospective studies with larger patient numbers are required to further evaluate the validity of these proposed guidelines.

Acknowledgments

The authors thank Dr. Janice Lin for secretarial support during the preparation of this article.

BIBLIOGRAPHY

- Lombardi D, Tomenzoli D, Buttà L, et al. Limitations and complications of endoscopic surgery for treatment for sinonasal inverted papilloma: a reassessment after 212 cases. *Head Neck* 2011;33:1154–1161.
- Lawson W, Patel ZM. The evolution of management for inverted papilloma: an analysis of 200 cases. *Otolaryngol Head Neck Surg* 2009;140:330–333.
- Sham CL, Woo JK, van Hasselt CA, Tong MC. Treatment results of sinonasal inverted papilloma: an 18-year study. *Am J Rhinol Allergy* 2009;23:203–211.
- Kim DY, Hong SL, Lee CH, et al. Inverted papilloma of the nasal cavity and paranasal sinuses: a Korean multicenter study. *Laryngoscope* 2012;122:487–494.
- Walgama E, Ahn C, Batra PS. Surgical management of frontal sinus inverted papilloma: a systematic review. *Laryngoscope* 2012;122:1205–1209.
- Krouse JH. Development of a staging system for inverted papilloma. *Laryngoscope* 2000;110:965–968.
- Cannady SB, Batra PS, Sautter NB, et al. New staging system for sinonasal inverted papilloma in the endoscopic era. *Laryngoscope* 2007;117:1283–1287.
- Zhang L, Han D, Wang C, et al. Endoscopic management of the inverted papilloma with attachment to the frontal sinus drainage pathway. *Acta Otolaryngol* 2008;128:561–568.
- Yoon BN, Batra PS, Citardi MJ, Roh HJ. Frontal sinus inverted papilloma: surgical strategy based on the site of attachment. *Am J Rhinol Allergy* 2009;23:337–341.
- Kamel RH, Abdel Fattah AF, Awad AG. Origin oriented management of inverted papilloma of the frontal sinus. *Rhinology* 2012;50:262–268.
- Pagella F, Pusateri A, Giourgos G, et al. Evolution in the treatment of sinonasal inverted papilloma: pedicle-oriented endoscopic surgery. *Am J Rhinol Allergy* 2014;28:75–81.
- Adriaensen GF, van der Hout MW, Reinartz SM. Endoscopic treatment of inverted papilloma attached in the frontal sinus/recess. *Rhinology* 2015;53:317–324.
- Peng R, Huang Q, Liang N, et al. A study on the prognosis of Draf II b surgery in treating frontal sinus inverted papilloma. *Lin Chung Er Bi Yan Hou Tou Jing Wai Ke Za Zhi* 2015;29:1423–1427.
- Verillaud B, Le Clerc N, Blancal JP, et al. Mucocoele formation after surgical treatment of inverted papilloma of the frontal sinus drainage pathway. *Am J Rhinol Allergy* 2016;30:181–184.
- Chiu AG, Jackman AH, Antunes MB, et al. Radiographic and histologic analysis of the bone underlying inverted papillomas. *Laryngoscope* 2006;116:1617–1620.
- Nygren A, Kiss K, von Buchwald C, Bilde A. Rate of recurrence and malignant transformation in 88 cases with inverted papilloma between 1998-2008. *Acta Otolaryngol* 2016;136:333–336.
- Healy DY Jr, Chhabra N, Metson R, et al. Surgical risk factors for recurrence of inverted papilloma. *Laryngoscope* 2016;126:796–801.
- Hildenbrand T, Wormald PJ, Weber RK. Endoscopic frontal sinus drainage Draf type III with mucosal transplants. *Am J Rhinol Allergy* 2012;26:148–151.
- Albathi M, Ramanathan M Jr, Lane AP, Boahene KD. Combined endonasal and eyelid approach for management of extensive frontal sinus inverting papilloma. *Laryngoscope* 2018;128:3–9.
- Wright EJ, Chernichenko N, Ocal E, et al. Benign inverted papillomas with intracranial extension: prognostic factors and outcomes. *Skull Base Rep* 2011;1:145–150.