

THE MONONUCLEAR PHAGOCYTE SYSTEM OF THE
MOUSE DEFINED BY IMMUNOHISTOCHEMICAL
LOCALIZATION OF ANTIGEN F4/80

Relationship Between Macrophages, Langerhans Cells, Reticular Cells,
and Dendritic Cells in Lymphoid and Hematopoietic Organs*

BY DAVID A. HUME,[‡] ANNE P. ROBINSON, GORDON G. MACPHERSON,
AND SIAMON GORDON

From the Sir William Dunn School of Pathology, South Parks Road, Oxford OX1 3RE, U.K.

The immune response genes of the major histocompatibility gene complex code for surface antigens (Ia) now believed to be involved in the interaction between T cells and accessory or "antigen-presenting" cells (1, 2). Whilst some groups suggest that Ia antigens present on subpopulations of mononuclear phagocytes are involved in T cell activation (1-4), others have presented evidence for the involvement of a separate Ia⁺ cell population (5-8) now generally referred to as dendritic cells. The in vivo correlate of the isolated antigen-presenting dendritic cell is not yet clear. The availability of a specific monoclonal antibody against mouse dendritic cells (9) will be helpful in clarifying this question. One obvious candidate is the Ia⁺ "interdigitating cell" that has been described in thymus and in T cell-dependent areas of lymphoid organs (10-15). However, whilst the isolated splenic dendritic cell has virtually none of the functional characteristics of a mononuclear phagocyte (6), it has been suggested that interdigitating cells are members of the mononuclear phagocyte system and are related to epidermal Langerhans cells and similar cells found in afferent lymphatics (14).

Apart from T cell activation during an immune response, macrophages have also been implicated in the control of hematopoiesis in the bone marrow (16-20), the differentiation of thymocytes in the thymus (21), proliferation and keratinization of squamous epithelial cells (Langerhans cells [22-24]), and the antibody response of B lymphocytes to T-independent antigens (25).

In order to determine the roles of mononuclear phagocytes and other cells in these systems, it is necessary to have reliable surface markers analogous to those that have delineated subclasses of T lymphocytes (26). F4/80 is a hybridoma that secretes a noncytotoxic rat IgG2b directed against a 160-kdalton plasma membrane antigen of mouse mononuclear phagocytes (27). The antigen is similar in

* Supported in part by the Medical Research Council, U. K.

[‡] Present address: Dept. of Medicine and Clinical Science, John Curtin School of Medical Research, Woden Valley Hospital, Garran, A.C.T., Australia.

¹ Abbreviations used in this paper: ABC, avidin-biotin-peroxidase complex; BCG, bacillus Calmette-Guerin.

size, distribution, and selective proteolytic cleavage to the gp160 molecule of the guinea pig macrophage plasma membrane (28). F4/80 is a maturation marker for mononuclear phagocytes in liquid bone marrow cultures (29) and is absent from blood cells other than monocytes (27) and from splenic dendritic cells (6). We report here the immunohistochemical localization of F4/80 antigen in lymphoid and hematopoietic organs of the mouse and discuss the relationship between macrophages and "dendritic"-type cells.

Materials and Methods

For all preparations male mice (C57B1/6, CBAT6/T6, or BALB/c obtained from our departmental breeding facility; BALB/c nu/nu from OLAC, Bicester, Oxon) were fixed by perfusion through the aorta using 0.5% glutaraldehyde in 1% sucrose 0.1 M sodium cacodylate buffer, pH 7.4 before routine paraffin histology. For sections of bone marrow, excised femurs were decalcified in several changes of 10% sodium citrate, pH 4.7 overnight before embedding in paraffin. The immunohistochemical method is based on the avidin-biotin-peroxidase complex (ABC) method of Hsu et al. (30) and has been described in detail elsewhere (31). Control preparations without antibody F4/80 were unstained.

Where desired, bacillus Calmette-Guerin (BCG) infection was carried out by intraperitoneal or subcutaneous (flank) injection of $\sim 10^7$ live organisms (Pasteur strain 1011 from Dr. R. North, Trudeau Institute, Saranac Lake, NY).

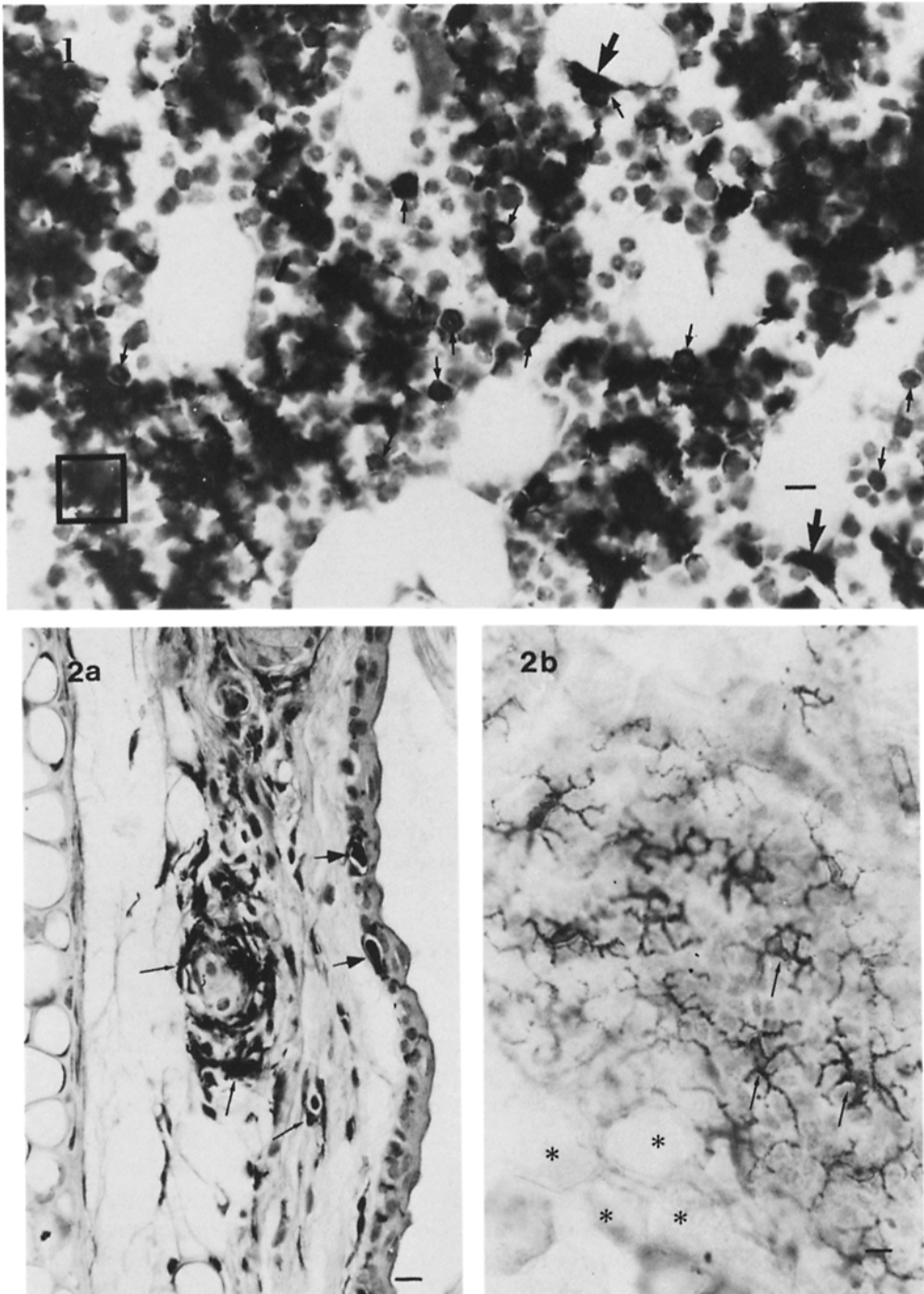
Results

Bone Marrow. Fig. 1a shows the distribution of F4/80⁺ cells in the bone marrow of C57B1/6 mice carrying a subcutaneous BCG-induced granuloma. This particular example is shown to demonstrate the presence of F4/80 on presumed monocytes before their entry into the circulation. In uninfected animals the overall pattern of staining of stromal macrophages is not different, but labeled mononuclear phagocyte precursors are much less frequent. In all cases, the marrow stroma is heavily labeled, the predominant cell type being a large macrophage forming the center of a hematopoietic island and extending processes throughout the stroma (Fig. 1).

An important feature that cannot be adequately demonstrated in black and white micrographs, but is obvious in the original colors, is that F4/80⁺ immature mononuclear phagocytes in infected marrow are often found immediately adjacent to the cell body of these stromal macrophages.

Apart from the two labeled populations mentioned above, a third macrophage population is seen associated with the vascular sinuses. F4/80 is absent from the endothelial cells. The distribution of the antigen in bone marrow sinuses is reminiscent of the liver, where Kupffer cells are F4/80⁺ but the endothelial cells are not (Hume, D. A., V. H. Perry, and S. Gordon, manuscript in preparation). However, as in the subcapsular sinuses of the lymph node (see Fig. 8a), the macrophages are much more extensively spread in the sinus than are Kupffer cells and are not prominent in cross sections.

Langerhans Cells. Langerhans cells are an Ia⁺ component of the basal layers of the epidermis of the skin (22–24). They can be identified by electron

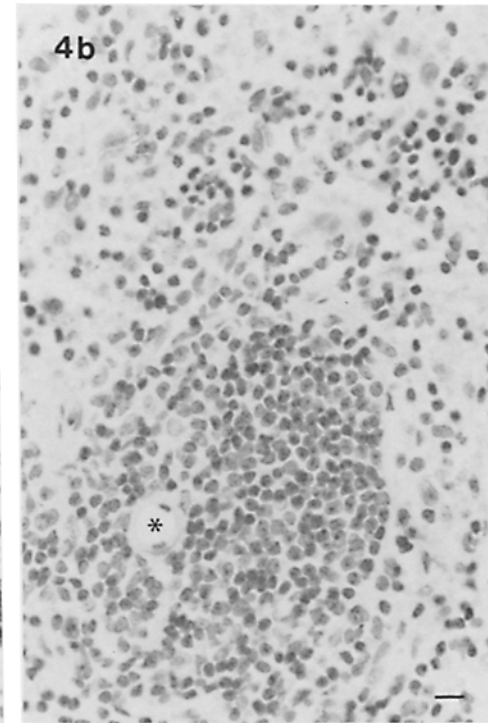
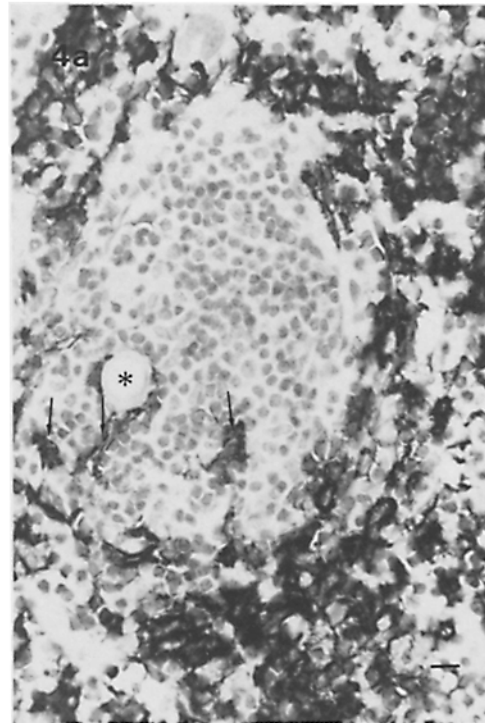
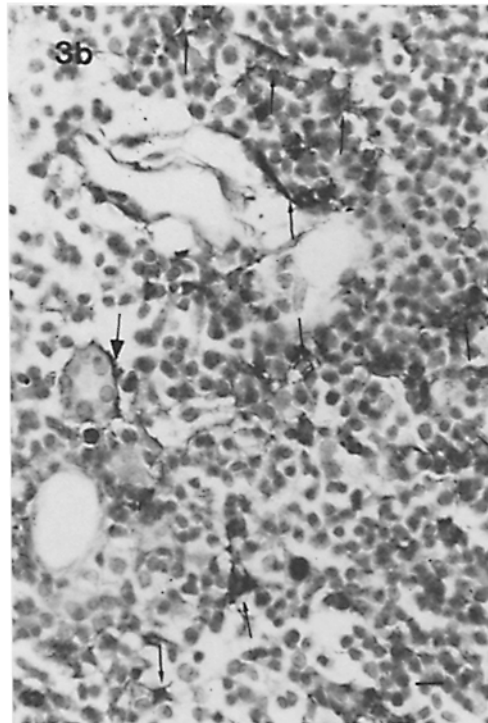
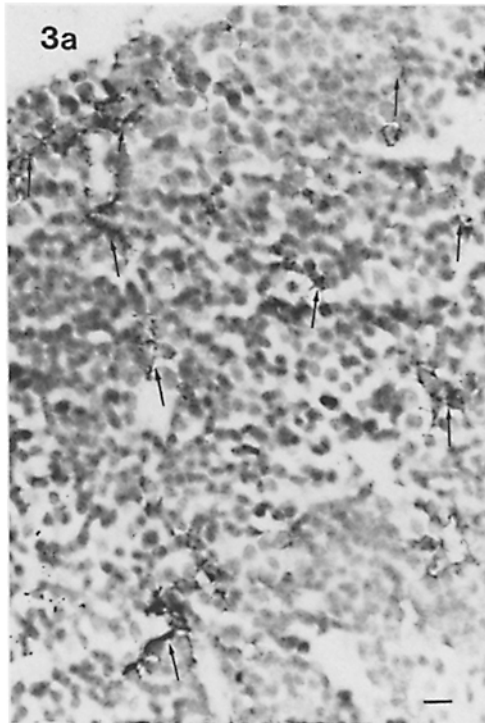


FIGURES 1 and 2 FIG. 1 Localization of F4/80 in bone marrow. Light micrograph of a 5- μ m section of femoral bone marrow of a C57 B1/6 male mouse infected subcutaneously 6 d previously with 10^7 live BCG. Black precipitate indicates diaminobenzidine reaction product

microscopy because of their characteristic cytoplasmic Birbeck granules. Fig. 2*a* shows a vertical section of mouse ear; an albino strain (BALB/c) was chosen to avoid confusion with pigment-containing cells. F4/80⁺ cells are seen throughout the dermis, being particularly numerous in the vicinity of glandular structures. In the epidermis, occasional stained cell bodies or processes can be observed amongst the basal layer. The F4/80⁺ cell bodies are often surrounded by an apparent clear space. Potten and Allen (23) observed a similar space surrounding epidermal Langerhans cells and attributed it to a shrinkage artifact resulting from the absence of tight junctions between these cells and adjacent epidermal cells. A definitive identification of Langerhans cells cannot be made on this basis alone. The problem is solved by taking *en face* sections, since Potten and Allen have shown that the Langerhans cells of mouse ear form the center of squame piles which are present in a regular hexagonal array on the surface. The distribution of F4/80⁺ cells in a thick (10 μm) horizontal section of BALB/c ear is shown in Fig. 2*b*. Membrane processes extend between the basal cells of the epidermis, making contact with every cell in the basal layer. As reported by Potten and Allen, each Langerhans cell forms the center of a group of 9–10 basal cells and these groups form a roughly hexagonal pattern. No overlapping of processes between adjacent Langerhans cells is observed. Although we cannot identify the indeterminate or type 3 cell of the epidermis that has been described by others (23), the F4/80-labeled population of the epidermis is homogeneous in its morphology and relationship to the epidermal basal cells. No evidence for another separate F4/80⁺ cell type is seen.

Thymus. The thymus contains several populations of F4/80⁺ cells distinguishable on the basis of morphology and anatomical location (Fig. 3, *a* and *b*). On the outer surface the labeled cells are extensively spread on the underside of the capsule; similar cells can be seen lying along the connective tissue septae that project into the cortex. In the cortex and around the corticomedullary junction there is a population of F4/80⁺ cells that extends fine membrane processes between groups of thymocytes. The morphology of the cortical F4/80⁺ cells is similar to that of F4/80⁺ microglial cells in brain (V. H. Perry, D. A. Hume, and S. Gordon, unpublished) and the processes are so fine that they are impossible

following immunoperoxidase localization of F4/80 antigen, control sections were unstained. The majority of the labeled cells are large reticular cells in the stroma forming the center of groups of mainly unlabeled hematopoietic cells. The box encloses a single cell of this type. Note that the processes of these F4/80⁺ cells do not overlap with each other. Two additional F4/80⁺ cell populations can be seen. Large arrowheads indicate examples of F4/80⁺ cells associated with the vascular sinuses. Small arrows indicate examples of small round mononuclear F4/80⁺ cells (presumed promonocytes) found associated with hematopoietic islands and at various stages of migration towards the vascular sinuses. Bar, 7.5 μm. FIG. 2 Localization of F4/80 in mouse ear. (*a*) Localization of F4/80 in a 5-μm vertical section of BALB/c ear. F4/80⁺ cells (small arrows) are seen in the dermis surrounding a glandular structure. Two labeled cells (large arrows) can be seen in the basal layer of the epidermis. Fine F4/80⁺ membrane processes can be observed throughout the basal layer, but do not contrast sufficiently to be seen in black and white. They are more obvious in the thicker flat and tangential section of the ear in *b*. Bar, 10 μm. (*b*) Localization of F4/80 in a 10-μm horizontal section of BALB/c ear. The section cuts through several layers of the epidermis. The asterisks indicate the region where the upper keratinized layer has been sectioned, showing the regular array of hexagonal squame piles. Smaller arrows indicate F4/80⁺ Langerhans cells between groups of 9–10 basal cells in the lower layers of the epidermis. Note that processes of adjacent cells do not overlap. Photograph taken with Ilford 303 blue filter to increase contrast. Bar, 10 μm.



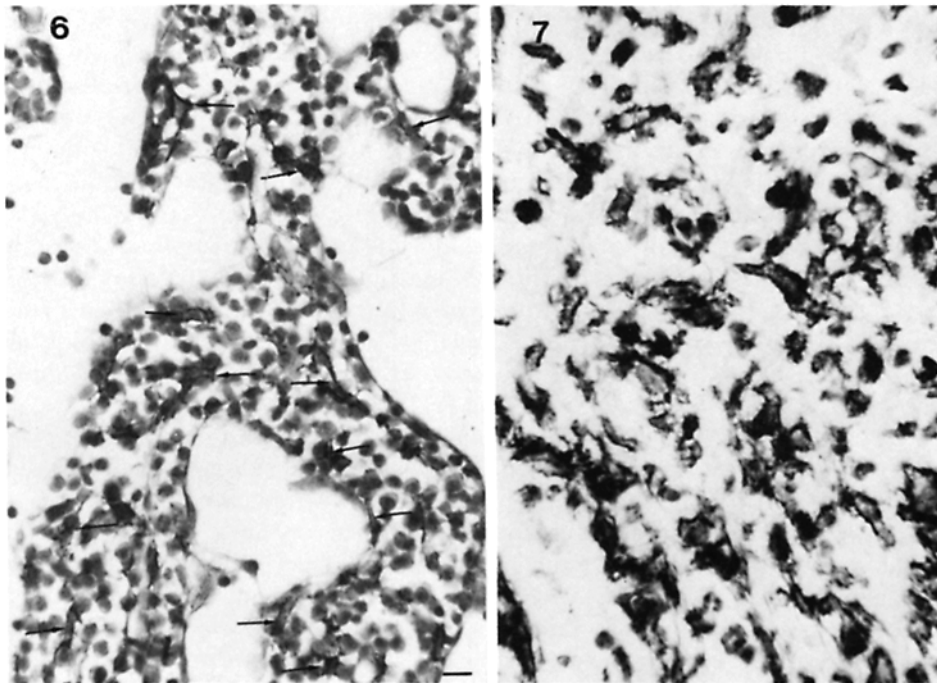
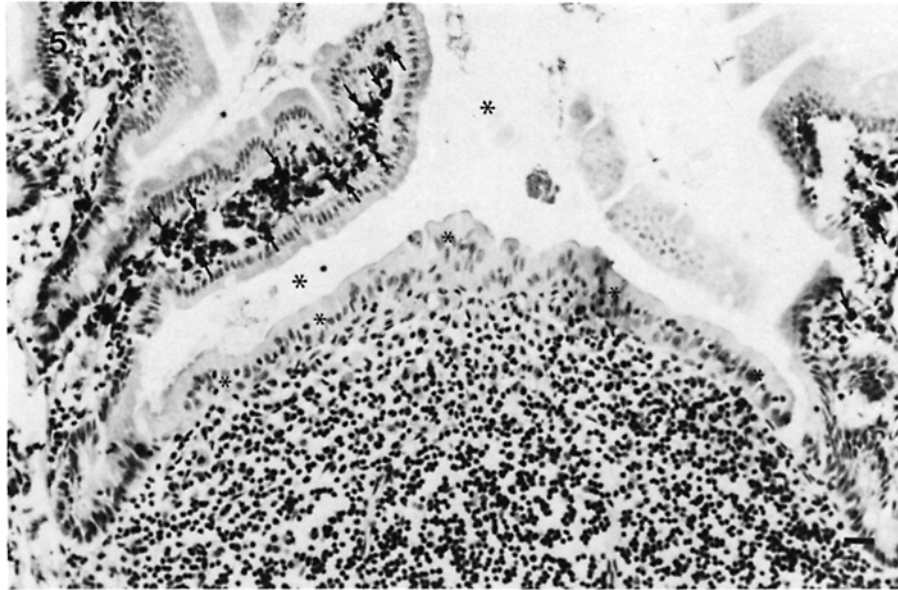
to contrast with the densely hematoxylin-stained thymocyte nuclei in black and white micrographs. In color it is clear that the membrane processes form an extensive network throughout the cortex. In the medulla similar groups of thymocytes are sometimes seen; they are somewhat smaller and the associated F4/80⁺ cell has shorter processes. Apart from thymocytes and connective tissue, F4/80⁺ cells are adjacent to two other cell types, microvascular endothelial cells and thymic epithelial cells. Only isolated examples of the latter association can be easily distinguished in the cortex because of the dense packing of thymocytes, but in the medulla it is more obvious. In particular, modified epithelial cells forming Hassall's corpuscles are often surrounded by F4/80⁺ cells (Fig. 3*b*), so extensively spread that only occasional cell bodies can be seen. Finally, the medulla also contains a population of rather rounded F4/80⁺ cells with the classical appearance of macrophages that have no obvious relationships to other cell types and often have large inclusions.

Spleen, Lymph Node and Gut-associated Lymphoid Areas. In marked contrast to the thymus, cells labeled with F4/80 are rarely seen in association with dense groups of T lymphocytes in other lymphoid organs, including spleen, lymph nodes, Peyer's patch and other gut-associated lymphoid follicles. In the spleen the white pulp is virtually devoid of F4/80⁺ cells; isolated examples are found in the marginal zones (not illustrated), or immediately adjacent to arterioles in the periarteriolar lymphoid sheath (Fig. 4*a*). As seen in Fig. 4*a*, the red pulp provides a marked contrast and represents the densest concentration of F4/80 antigen in the mouse. The specificity of our procedure is seen in the control section of this region, where there is no background staining (Fig. 4*b*).

The cortical regions of lymph nodes and gut-associated lymphoid areas also contain very few F4/80⁺ macrophages (see Fig. 5). In lymph nodes they are concentrated within medullary sinuses and immediately adjacent paracortical regions (Fig. 6). Another F4/80⁺ population can be distinguished lining the subcapsular sinus. These cells are spread so extensively that they appear almost like endothelial cells in cross section (see Fig. 8*a*).

In Peyer's patch and in lymphoid follicles associated with colon and caecum F4/80⁺ cells are seen only immediately under the capsule and in the lamina propria (Fig. 5). In the lamina propria, as in the lymph node medulla, close apposition between lymphocytes and F4/80⁺ macrophages is common. The distribution of macrophages in the gastrointestinal tract will be described more fully elsewhere (D. A. Hume, V. H. Perry, and S. Gordon, in preparation). In the Peyer's patch and lymph node itself only occasional labeled cells have been seen in presumed germinal centers (tingible body macrophages), but follicular dendritic cells are clearly F4/80 negative. The rarity of tingible body macro-

FIGURES 3 and 4 FIG. 3 Localization of F4/80 in the mouse thymus. Each of these figures is taken from the thymus of a 6-wk old CBA T6/T6 mouse. Bar, 10 μ m in each case. (a) F4/80⁺ cells in the cortex (arrows) exhibit extensive fine membrane processes extending between the densely-packed thymocytes. (b) F4/80⁺ cells in the corticomedullary junction region (small arrows). Large arrow indicates an F4/80⁺ cell spread along the outside of a Hassall's corpuscle. FIG. 4 Localization of F4/80 in the periarteriolar lymphoid sheath (PALS) in mouse spleen. (a) F4/80⁺ cells (arrows) are seen immediately adjacent to the arteriole (asterisk). Occasional cells are found towards the outside of the sheath (marginal zone). The adjacent red pulp is very heavily labeled. Bar, 10 μ m. (b) Control for Fig. 5*a* in which staining was carried out identically except for the omission of first antibody (F4/80) Bar, 10 μ m.



FIGURES 5-7 FIG. 5 Localization of F4/80 in Peyer's patch. No F4/80 positive cells can be identified in the lymphoid tissue of the Peyer's patch (lower half of view) in contrast to the dense staining of cells in the lamina propria of adjacent intestinal villi (small arrows). Large asterisks mark the intestinal lumen; smaller asterisks mark the dome epithelium of the Peyer's patch. Bar, 20 μm . FIG. 6 Localization of F4/80 in the mesenteric lymph node of the mouse. F4/80⁺ cells (arrows) found in the medullary sinuses extend processes between groups of lymphocytes. Bar, 10 μm . FIG. 7 Localization of F4/80 in BCG elicited subcutaneous granuloma. Tissue was taken 6 d after injection of 10^7 live organisms into the flank of an adult male C57B1/6 mouse. Numerous macrophages showed dense staining localized to the plasma membrane. Bar, 10 μm .

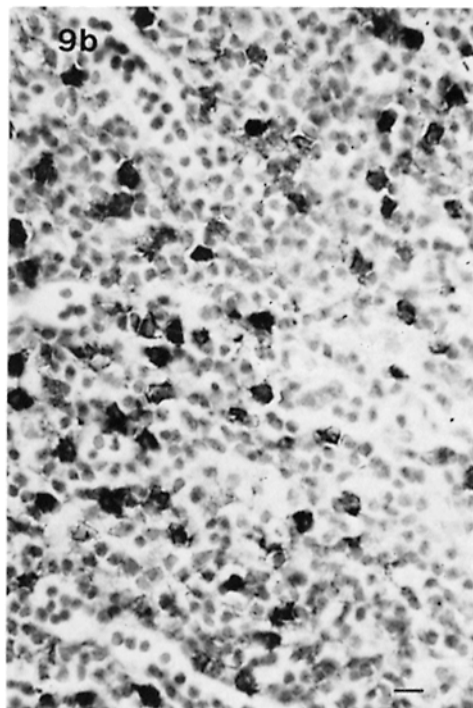
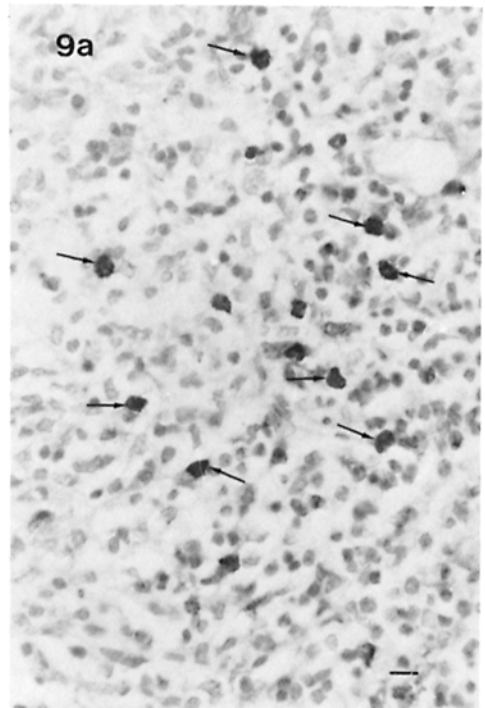
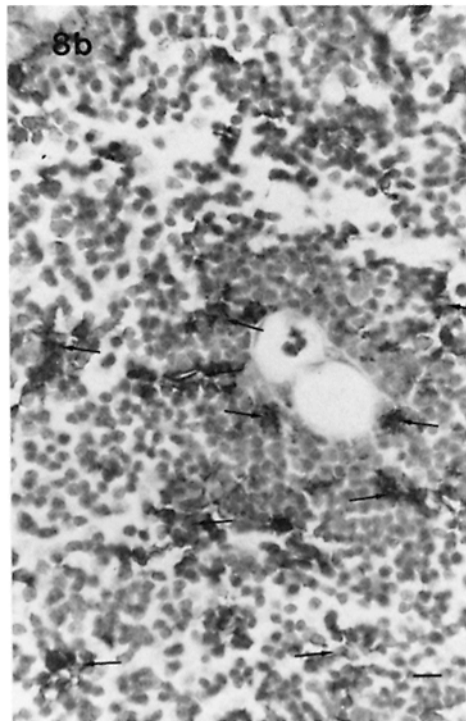
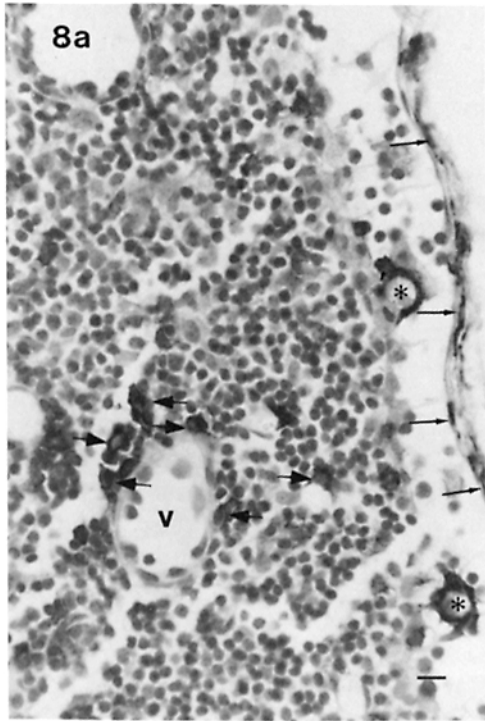
phages is probably a reflection of the lack of immunological reactivity in these preparations. Le Fevre et al. (32) have discussed the identification of macrophages in the T cell area underlying the dome epithelium of the Peyer's patch of the rat following ingestion by the animal of latex or colloidal carbon. We see no F4/80⁺ cells in this region (Fig. 5).

BCG-Granuloma and Draining Lymph Node. In the susceptible C57/B16 strain injection of 10⁷ live BCG in the flank causes the appearance of a discernible nodule within 3–5 d and a solid granuloma is present after 10–20 d. The granulomatous material is adequately fixed by vascular perfusion fixation after 6 d and is very heavily stained with F4/80 at this and later times (Fig. 7). Epithelioid cells are present in the 20-d granuloma and are stained, but no well-defined giant cells have been observed. The draining axillary lymph nodes are greatly enlarged after injection of BCG in the flank. Heavily F4/80-positive secondary granulomata are present within the medulla and closely adjacent paracortex. Quite apart from the granulomata, the inflamed lymph nodes contain far more labeled cells than resting nodes. These are seen within the subcapsular sinus and throughout the paracortex (Fig. 8*a* and *b*) although the follicles are not so noticeably affected. The F4/80⁺ cells are often adjacent to blood vessels and presumed high-endothelial venules (see Fig. 8*a* and *b*), the latter being somewhat difficult to identify because of the effects of vascular perfusion. In many cases the morphology of the cells is similar to those in the thymus, with fine processes extending between groups of lymphocytes.

Nude Mice. The virtual absence in healthy animals of F4/80⁺ cells from T-dependent areas in lymphoid organs other than thymus suggests strongly that the antigen is absent from interdigitating cells. In the T cell-deficient nu/nu mouse the T-dependent regions of lymphoid organs are more readily identifiable because of the absence of the T cells. At least in the athymic rat, the interdigitating cells are known to be present as normal (15). In Fig. 9*a* we show a section through the mesenteric lymph node paracortex of a nude mouse. The interdigitating cells are readily identifiable by their nuclear morphology (15) and are definitively unstained with F4/80 in contrast to the labeled mononuclear cells which are somewhat more numerous than in the paracortex of a normal mouse. Since the mice used in this study were not germ-free the infiltration of macrophages into the lymph node paracortex might be indicative of the susceptibility of the nu/nu mouse to infection. Indeed, in mesenteric lymph node obtained from nu/nu mice infected systemically as a result of intraperitoneal injection of live BCG the paracortex was massively infiltrated with F4/80-positive cells (Fig. 9*b*). In contrast to the lymph node of the BCG-infected normal mouse (Fig. 8*a* and *b*) these macrophages in the nu/nu have no membrane processes and are seen as rounded cells with readily identifiable reniform nuclei.

Discussion

Our results confirm the *in vitro* observation (29) that F4/80 is a marker for mononuclear phagocytes in the mouse and does not cross-react significantly with any other cell type. The immunohistochemical method is particularly sensitive. Previous results from this laboratory (33) have shown that F4/80 is expressed at very low levels on BCG-activated peritoneal macrophages, at times reaching the



limits of detection of autoradiographic or fluorescent-activated cell sorter analysis (unpublished). However, F4/80⁺ macrophages infiltrating the BCG-induced granuloma (Fig. 7) or the inflamed lymph node (Fig. 8*a* and *b*) are readily identifiable in tissue sections. The antigen can also be detected with the immunoperoxidase method in adherent cultures of activated peritoneal macrophages (unpublished). We cannot, with a single marker, eliminate the possibility that an F4/80⁻ macrophage population exists but we have not, so far, identified such a population.

The distribution of F4/80 in bone-marrow (Fig. 1) accords well with identification of macrophages based on ultrastructural or cytochemical criteria (16–20). Their role in erythropoiesis, erythrophagocytosis, and iron metabolism in this site has been described (20, review). The regulatory function of “macrophages” in granulocytopenia has been studied extensively *in vitro* (17), but little good *in vivo* evidence exists. Our results suggest that the stromal macrophages do extend processes throughout the marrow, often visible between granulocytes identifiable by their nuclear morphology. It will be interesting to compare the distribution of F4/80 with that of alkaline phosphatase, which is a plasma membrane marker of an apparently separate reticular cell population seen particularly in areas of granulocytopenia (16). To our knowledge the identification of F4/80 on small mononuclear cells adjacent to the much larger stromal macrophages represents the first evidence of the site of monocytopoiesis in the marrow, as well as supporting *in vitro* evidence that F4/80 is expressed at an early stage in macrophage differentiation (29). A comparison of the distribution of F4/80⁺ cells with that of acid phosphatase (16) in bone marrow indicates the advantage of using a membrane rather than a lysosomal enzyme marker. Because lysosomes are generally concentrated around the cell body, the acid phosphatase-positive cells appear relatively rounded and isolated; their processes can only be seen with an electron microscope and are difficult to identify reliably.

The results we have obtained using lymphoid organs of BCG-infected mice indicate that macrophages are not a static component of T-dependent lymphoid areas. They are normally virtually absent from such regions but appear to migrate in during an inflammatory response via the blood and afferent lymphatics (Figs. 8*a* and *b*, 9*a* and *b*). Since macrophage infiltration is, if anything, even more evident in the athymic *nu/nu* mouse (Fig. 9*b*) it seems unlikely that T cells play a role. Enhanced production of monocytes observed in the marrow undoubtedly

FIGURES 8 and 9 FIG. 8 Localization of F4/80 in axillary lymph node draining a BCG-elicited granuloma. Tissue was taken from C57B1/6 mice 6 d after injection of 10⁷ live organisms into the flank. (*a*) Paracortical region between two follicles in the axillary lymph node shows several F4/80⁺ cell populations. Extensively spread cells are seen in the outer wall of the subcapsular sinus (thin arrows). More rounded cells are found throughout the lymphoid area (thick arrows) particularly in the vicinity of the sinus and high endothelial venule (*v*). Two very large F4/80⁺ cells with many membrane projections are seen in the subcapsular sinus (asterisks). (*b*) Paracortical region closer to the medulla. Dense group of lymphocytes and F4/80⁺ cells (arrows) are seen surrounding blood vessels. F4/80⁺ cells extend long membrane processes between groups of lymphocytes. FIG. 9 Localization of F4/80 in the mesenteric lymph node of athymic (*nu/nu*) mouse. (*a*) Occasional rounded F4/80⁺ cells can be seen in the paracortex of the lymph node (arrows). Interdigitating cells (not readily identified at this magnification) are not labeled. Bar, 10 μm. (*b*) The same region of mesenteric lymph node from a *nu/nu* mouse 10 d after *i.p.* injection of 10⁷ live BCG. A massive influx of F4/80⁺ cells is apparent.

contributes, but there is evidence that foreign antigenic materials affect macrophage distribution (12, 34–37). Thus, Fossum (34) showed that when colloidal carbon or ferritin is injected into the foot pad of a rat, labeled macrophages migrate into the popliteal lymph node. The distribution of macrophages in lymphoid organs must, therefore, always be related to the immunological status of the animal. Differences in immunological status or species, or the use of particulate markers, may explain the discrepancy between the distribution of macrophages in mouse lymphoid organs reported here compared with previous reports on the rat (32, 40).

We have shown definitively that the “interdigitating cell” as classically described in T-dependent areas of lymphoid organs is not labeled with F4/80. Others have argued for the inclusion of this cell in the mononuclear phagocyte system and its relationship to the Langerhans cells (14). It seems much more likely that these interdigitating cells are related to the “dendritic cell” (5–7) and Ia-positive nonphagocytic cells in afferent lymph (39). An Ia⁺ dendritic cell in the skin, the indeterminate cell (40) might also be a member of this system of cells and we have noted the probable absence of F4/80 from this population (see results and Fig. 2*b*). Similarly, Mayrhofer et al. (38) have suggested the existence in intestinal lamina propria of the rat of an Ia⁺ dendritic cell population that does not express a rat macrophage marker, W3/25.

Interdigitating cells of the thymus (11) are less readily analyzed since F4/80⁺ cells are a normal component of this organ. In the corticomedullary junction region of the thymus, as in the inflamed lymph node, we suspect that the term “interdigitating cell” actually corresponds to several distinguishable cell types. Kyewski et al. (41) have shown that stable cellular aggregates can be isolated from disrupted mouse thymus. These “thymocyte rosettes” contain Ia⁺ cells very similar to splenic dendritic cells, Ia⁻ phagocytic cells and a specific subpopulation of T cells. If thymic “Langerhans cells” are Ia⁺, like their epidermal counterparts (42, 43) they would represent a third adherent population that might be confused with the “dendritic” cells. Beller and Unanue (21) suggested the involvement of Ia⁺ “macrophages” in T cell differentiation. F4/80 will be a useful marker for delineating the contributions of Ia⁺ or Ia⁻ macrophages and dendritic cells to differentiation in the thymus and the structure of thymocyte rosettes.

Although “Langerhans cells” in the thymus cannot be identified in our sections, those in the epidermis of the ear have been shown to be F4/80⁺ (Fig. 2*b*). This supports the conclusion that these cells are mononuclear phagocytes based on the presence of Fc and C3 receptors and the derivation from a bone marrow precursor (42, 43). Most interest has centered on the immunological role of the Langerhans cell (42, 43) and its relationship to the basal cells of the epidermis has been neglected. Our observations provide confirmation of the central position of Langerhans cells in groups of proliferating epithelial cells (22, 23). This precise anatomical location is strongly suggestive of a controlling role (22), but no mechanism has been proposed. We consider the interaction between mononuclear phagocytes and epithelial cells to be a general phenomenon and have confirmed this proposal by immunohistochemical localization of F4/80 in many other mouse tissues (reference 31; D. A. Hume, V. H. Perry, and S. Gordon, manuscript in preparation). It is clear that the Langerhans cell adapts to the

epithelial environment by becoming Ia⁺, poorly endocytic, and dendritic in appearance, which has led to the confusion over its relationship to other mononuclear phagocytes and to "dendritic" cells (42, 43). F4/80 is the first reported unique surface marker for these cells.

There is a striking resemblance between hematopoietic islands and epidermal proliferative units distributed around a central macrophage. Macrophages may also associate with proliferating lymphoid cells. The associating lymphocytes may be immature thymocytes in the thymus, mature T cells in the inflamed lymph node, or B cells and plasma cells in the lymph node medulla or the lamina propria of the intestine (see results). Other markers will be needed for their identification. The close proximity of macrophages to lymphocytes in these areas is strongly suggestive of a regulatory interaction similar to that in the marrow and skin. Macrophages are known to produce both positive (interleukin 1) and negative (prostaglandin E) effectors of lymphocyte activation (44). Thus, although the dendritic/interdigitating cell may play a primary role in T cell recognition of antigen (5-8) a contribution to subsequent regulation by mononuclear phagocytes appears to be both anatomically and biochemically feasible.

Summary

The macrophage-specific antigen F4/80 has been localized in mouse lymphoid and hematopoietic tissue and skin using immunoperoxidase staining. The antigen permits identification of early mononuclear phagocyte precursors in the bone marrow, and is present also on larger cells forming the center of hematopoietic islands and lining vascular sinuses. In thymus F4/80⁺ cells are numerous in both cortex and medulla and are particularly concentrated around the corticomedullary region. In spleen, lymph node, and gut-associated lymphoid areas the major F4/80⁺ populations are in the red pulp, the medulla and subcapsular sinus, and the adjacent lamina propria, respectively. F4/80⁺ cells are rarely seen in T-dependent areas of lymph nodes, spleen, or Peyer's patch, but are present in large numbers in these areas during bacillus Calmette-Guerin (BCG)-induced inflammation. Macrophage infiltration occurs also in lymph nodes from athymic nu/nu mice and is therefore T cell independent. The interdigitating cell of T-dependent areas is F4/80⁻, but the Langerhans cell of the epidermis of the skin, which bears some ultrastructural resemblance to the interdigitating cell, is F4/80⁺. We conclude that the two cell types are probably not related.

We thank Drs. Neil Barclay, Hugh Perry, and Ralph Steinman for helpful discussion, Mr. Don Etheridge for expert assistance with histology, Mr. Stan Buckingham, Miss Jill Roberts, and Miss Mari Bergin for photography, and Mrs. Pam Woodward and Miss Paula Gaskel for preparation of the manuscript.

Received for publication 20 January 1983 and in revised form 13 April 1983.

References

1. Rosenthal, A. S. 1978. Determinant selection and macrophage function in genetic control of the immune response. *Immunol. Rev.* 40:136.
2. Niederhuber, J. E. 1978. The role of I region gene products in macrophage-T lymphocyte interaction. *Immunol. Rev.* 40:28.

3. Erb, P., A. C. Stern, S. S. Alkan, S. Studer, E. Zoumbou, and R. H. Gisler. 1980. Characterization of accessory cells required for helper T cell induction in vitro: evidence for a phagocytic, Fc-receptor, and Ia-bearing cell type. *J. Immunol.* 125:2504.
4. Nadler, P. I., R. J. Klingenstein, and R. J. Hones. 1980. Ontogeny of murine accessory cells: Ia antigen expression and accessory cell function in in vitro primary antibody responses. *J. Immunol.* 125:914.
5. Steinman, R. M., and M. C. Nussenzweig. 1980. Dendritic cells: features and functions. *Immunol. Rev.* 53:127.
6. Nussenzweig, M. C., R. M. Steinman, J. C. Unkeless, H. D. Witmer, B. Gutchinov, and Z. A. Cohn. 1981. Studies of the cell surface of mouse dendritic cells and other leukocytes. *J. Exp. Med.* 154:168.
7. Sunshine, G. H., D. R. Katz, and M. Feldmann. 1980. Dendritic cells induce T cell proliferation to synthetic antigens under Ir gene control. *J. Exp. Med.* 152:1817.
8. Muramatsu, S., and K. Inaba. 1982. Functions of Ia⁺ nonlymphoidnonmacrophage cells in the initiation of immune response. In *Self-defense mechanisms. Role of macrophages.* D. Mizuno, Z. A. Cohn, K. Takeya, and N. Ishida, editors. Elsevier, University of Tokyo Press. pp. 111–124.
9. Nussenzweig, M. C., R. M. Steinman, M. D. Witmer, and B. Gutchinov. 1982. A monoclonal antibody specific for mouse dendritic cells. *Proc. Natl. Acad. Sci. USA.* 79:161.
10. Veerman, A. J. P. 1974. On the interdigitating cells in the thymus-dependent area of the rat spleen. A relation between the mononuclear phagocyte system and T lymphocytes. *Cell Tissue Res.* 148:247.
11. Duijvestijn, A. M., and E. C. M. Hoefsmit. 1981. Ultrastructure of the rat thymus. The microenvironment of T-lymphocyte maturation. *Cell Tissue Res.* 218:279.
12. Kamperdijk, E. W. A., E. M. Raajmakers, J. H. S. de Leeuw, and E. C. M. Hoefsmit. 1978. Lymph-node macrophages and reticulum cells in the immune response. I. The primary response to paratyphoid vaccine. *Cell Tissue Res.* 192:1.
13. Veldman, J. E., and E. Kaiserling. 1981. Interdigitating cells. In *The Reticuloendothelial System—A Comprehensive Treatise. Vol. 1. Morphology.* I. Carr and W. T. Daems, editors. Plenum Press, New York. p. 381.
14. Hoefsmit, E. C. M., A. M. Duijvestijn, and E. W. A. Kamperdijk. 1982. Relationship between Langerhans cells, veiled cells and interdigitating cells. *Immunobiology.* 161:255.
15. Fossum, S., M. E. Smith, E. B. Bell, and W. L. Ford. 1980. The architecture of rat lymph nodes. III. The lymph-nodes and lymph-borne cells of the congenitally athymic rat (rnu). *Scand. J. Immunol.* 12:421.
16. Westen, H., and D. F. Bainton. 1979. Association of alkaline-phosphatase positive reticulum cells in bone marrow with granulocytic precursors. *J. Exp. Med.* 150:919.
17. Cline, M. J., and D. W. Golde. 1979. Cellular interactions in hematopoiesis. *Nature (Lond.)* 277:177.
18. Dexter, T. M. 1982. Stromal cell associated haemopoiesis. *J. Cell Physiol. Suppl* 1, 87.
19. Weiss, L. 1976. The hematopoietic microenvironment of the bone marrow. An ultrastructural study of the stroma in rats. *Anat. Rec.* 186:161.
20. Hudson, G., and J. R. Shortland. 1981. Bone marrow macrophages. In *The reticuloendothelial system—A comprehensive treatise. Vol. 1. Morphology.* I. Carr and W. T. Daem, editors. Plenum Press, New York. p. 329.
21. Beller, D. I., and E. R. Unanue. 1978. Thymic macrophages modulate one stage of T cell differentiation in vitro. *J. Immunol.* 121:1861.
22. Potten, C. S., and T. D. Allen. 1976. A model implicating the Langerhans cell in keratinocyte proliferation control. *Differentiation.* 5:443.

23. Potten, C. S., and T. D. Allen. 1974. The fine ultrastructural identification and organisation of the epidermal proliferative unit. *J. Cell Sci.* 15:291.
24. Schweizer, J., and F. Marks. 1977. A developmental study of the distribution and frequency of Langerhans cells in relation to formation of patterning in mouse tail epidermis. *J. Invest. Dermatol.* 69:198.
25. Persson, U., L. Hammarstrom, E. Moller, G. Moller, and C. I. E. Smith. 1978. The role of adherent cells in B and T lymphocyte activation. *Immunol. Rev.* 40:78.
26. Cantor, H., and E. A. Boyse. 1975. Functional subclasses of T lymphocytes bearing different Ly antigens. II. Cooperation between subclasses of Ly⁺ cells in the generation of killer activity. *J. Exp. Med.* 141:1390.
27. Austyn, J. M., and S. Gordon. 1981. F4/80: a monoclonal antibody directed specifically against the mouse macrophage. *Eur. J. Immunol.* 10:805.
28. Remold-O'Donnell, E. 1982. Biosynthesis of gp160, the major trypsin-sensitive surface glycoprotein of macrophages. *J. Biol. Chem.* 257:6600.
29. Hirsch, S., J. M. Austyn, and S. Gordon. 1981. Expression of the macrophage-specific antigen F4/80 during differentiation of mouse bone marrow cells in culture. *J. Exp. Med.* 154:713.
30. Hsu, S. M., L. Raine, and H. Fanger. 1981. The use of avidin-biotin-peroxidase (ABC) complex in immunoperoxidase techniques: a comparison between ABC and unlabelled antibody (PAP) procedures. *J. Histochem. Cytochem.* 29:577.
31. Hume, D. A., and S. Gordon. 1983. The mononuclear phagocyte system of the mouse defined by immunohistochemical localization of antigen F4/80. Identification of resident macrophages in renal medullary and cortical interstitium and the juxtaglomerular complex. *J. Exp. Med.* 157:1704.
32. Le Fevre, M. E., R. Hammer, and D. D. Joel. 1979. Macrophages of the mammalian small intestine. A review. *J. Reticuloendothel. Soc.* 26:553.
33. Ezekowitz, R. A. B., J. Austyn, P. D. Stahl, and S. Gordon. 1981. Surface properties of bacillus Calmette-Guerin-activated mouse macrophages. Reduced expression of mannose-specific endocytosis, Fc receptors and antigen F4/80 accompanies induction of Ia. *J. Exp. Med.* 154:60.
34. Fossum, S. 1980. The architecture of rat lymph nodes. IV. Distribution of ferritin and colloidal carbon in the lymph nodes after foot pad injection. *Scand. J. Immunol.* 12:443.
35. Kelly, R. H., B. M. Balfour, J. A. Armstrong, and S. Griffiths. 1978. Functional anatomy of lymph nodes. II. Peripheral lymph-borne mononuclear cells. *Anat. Rec.* 190:5.
36. Kelly, R. H. 1970. Localisation of afferent lymph cells within the draining node during a primary immune response. *Nature (Lond.)* 227:510.
37. Kotani, M., K. Okada, H. Fujii, H. Tsuchiya, K. Matsuno, S. Ekino, and S. Fukuba. 1977. Lymph macrophages enter the germinal centre of lymph nodes of guinea pigs. *Acta Anat.* 99:391.
38. Mayrhofer, G., C. W. Pugh, and A. N. Barclay. 1983. The distribution ontogeny and origin in the rat of Ia positive cells with dendritic morphology and of Ia antigen in epithelia with particular reference to the intestine. *Eur. J. Immunol.* 13:112.
39. Pugh, C. W., G. G. MacPherson, and H. W. Steer. 1983. Characterization of nonlymphoid cells derived from rat peripheral lymph. *J. Exp. Med.* 157:1758-1779.
40. Rowden, G., T. M. Phillips, and M. G. Lewis. 1979. Ia antigen expression on indeterminate cells of the epidermis. Immunoelectron microscope studies of surface antigen. *Br. J. Dermatol.* 100:531.
41. Kyewski, B. A., R. V. Rouse, and H. S. Kaplan. 1982. Thymocyte rosettes—multicellular complexes of lymphocytes and bone marrow derived stromal cells in

- the mouse thymus. *Proc. Natl. Acad. Sci. USA.* 79:5646.
42. Stingl, G., K. Tamaki, and S. Katz. 1980. Origin and function of epidermal Langerhans cells. *Immunol. Rev.* 53:149.
 43. Silberberg-Sinakin, I., I. Gigli, G. J. Baer, and G. J. Thorbecke. 1980. Langerhans cells—role in contact hypersensitivity and relationship to lymphoid dendritic cells and to macrophages. *Immunol. Rev.* 53:203.
 44. Hume, D. A., and M. J. Weidemann. 1980. *Mitogenic Lymphocyte Transformation.* Elsevier/North Holland, Amsterdam.