



Case report

Traumatic extraperitoneal bladder rupture in the absence of pelvic fracture in a patient with pelvic organ prolapse: A case report and review of the literature

Logine Abouzead^a, Celia Leone^b, Saamia Shaikh^{c,*}, Jidefor Aniwku^c

^a Rowan University School of Osteopathic Medicine, Stratford, NJ, United States of America

^b St. George's University School of Medicine, Grenada, West Indies, United States of America

^c Department of Surgery, St. Joseph's University Medical Center, Paterson, NJ, United States of America

ARTICLE INFO

Keywords:

Traumatic extraperitoneal bladder rupture
CT cystography
Case reports

ABSTRACT

Introduction and importance: Traumatic bladder rupture is a rare occurrence. It is more likely to occur following blunt injury and is associated with pelvic fractures in patients presenting with hematuria. We present a unique case of an extraperitoneal bladder rupture in a female after sustaining a minor fall in the absence of a pelvic fracture.

Presentation of case: The patient is a morbidly obese female with a history of vaginal vault prolapse who reported profuse vaginal bleeding and lower abdominal and suprapubic pain shortly after falling off of her bed. The patient showed no signs of hemodynamic instability and genital bleeding was ruled out in the emergency department. A Computed Tomography (CT) cystogram confirmed bladder rupture confined to the extraperitoneal space without any evidence of pelvic fractures.

Discussion: Blunt traumatic extraperitoneal bladder rupture is typically associated with concomitant pelvic fracture. These injuries tend to occur as a result of high-impact motor vehicle or motorcycle collisions and are associated with an increased morbidity and mortality.

Conclusion: Dedicated bladder imaging should be considered in blunt abdominopelvic trauma patients presenting with hematuria in the absence of pelvic fracture when the patient's underlying medical conditions or comorbidities increase the risk of bladder rupture. Our patient's history of pelvic organ prolapse placed her at an increased risk of traumatic injury to the bladder.

1. Introduction

Traumatic bladder rupture is seen in less than 2% of abdominopelvic blunt trauma [1]. Bladder rupture occurs when there is a disruption of the bladder wall resulting in the extravasation of urine into the surrounding tissues. Bladder injury can be classified as contusions (Type I), intraperitoneal injuries, (Type II), interstitial injury (Type III) extraperitoneal rupture (Type IV), or a combination of both intra- and extraperitoneal rupture (Type V) [2,3]. The dome of the bladder is the weakest portion of the organ and is the most susceptible to injury. Furthermore, full or distended bladders are more vulnerable to injury while empty bladders tend to be protected [3]. Intraperitoneal bladder rupture is most often the result of a horizontal tear at the dome of a fully distended bladder arising in the setting of an increased intravesicular

pressure [1,4,5]. Extraperitoneal bladder rupture, the most common type of bladder injury, is associated with pelvic ring fractures secondary to blunt trauma from a direct blow to the lower abdomen or from the blunt force during a motor vehicle collision [5–7]. Typically, patients present with gross or microscopic hematuria, lower abdominal pain, and voiding difficulties [8–11]. We present a rare case of a patient who suffered from an extraperitoneal bladder rupture after a low impact blunt trauma in the absence of a pelvic fracture. This case is reported with consideration to the SCARE criteria and PROCESS guidelines [12,13].

2. Case presentation

The patient is a 60-year-old obese female with a history of vaginal

* Corresponding author: Department of Surgery, St. Joseph's University Medical Center, 703 Main Street, Paterson, NJ 07503, United States of America.

E-mail address: r_shaikhs@sjhmc.org (S. Shaikh).

<https://doi.org/10.1016/j.ijscr.2022.107150>

Received 6 April 2022; Received in revised form 27 April 2022; Accepted 30 April 2022

Available online 4 May 2022

2210-2612/© 2022 The Authors. Published by Elsevier Ltd on behalf of IJS Publishing Group Ltd. This is an open access article under the CC BY-NC-ND license (<http://creativecommons.org/licenses/by-nc-nd/4.0/>).

prolapse and previous pessary placement who presented to the emergency department with an eleven-hour history of heavy vaginal bleeding. The patient reported that her symptoms began after she fell out of her bed, landing on her buttocks. Of note, the patient also has a history of a rectocele, cystocele, and a previous total vaginal hysterectomy with vaginal vault prolapse. Nevertheless, after her fall, the patient stated that she heard a snapping sound and subsequently experienced abdominal pain and vaginal bleeding. She denied any fever, chills, urinary incontinence, bowel incontinence, or dysuria.

On examination, she was hemodynamically stable with a pulse rate of 98 beats per minute and a blood pressure of 132/77 mmHg. A genitourinary examination was conducted which showed soft tissue swelling in the vaginal vault with no apparent vaginal bleeding. On the initial CT scan of the abdomen and pelvis with contrast, a large hyperdense lesion in the bladder measuring 6.7×3.7 cm was seen extending through the posterior wall of the urinary bladder suspicious for a hematoma and extraperitoneal bladder rupture (Fig. 1). Urology was consulted and confirmed the aforementioned findings. A CT cystogram showed extravasation of contrast in the posterior wall, also confirming the presence of an extraperitoneal bladder rupture (Fig. 2). Urinalysis revealed >100 /HPF RBCs and a moderate amount of blood in the urine.

An external foley catheter was placed and the patient was also treated with antibiotics for a suspected UTI. The patient had an uncomplicated hospital course and was advised to follow up with urology for a repeat cystogram prior to foley catheter removal.

3. Discussion

Traumatic rupture of the bladder is a relatively rare occurrence as the anatomical location of the bladder makes it a well-protected organ [14]. It is housed deep in the pelvis, posterior and superior to the pubic symphysis, and is secured by its many ligamentous attachments to structures in the pelvic cavity [15]. False ligamentous attachments are created by peritoneal folds at the superior portion of the bladder and a tough ligamentous attachment affixes the neck of the bladder to the pubic symphysis which allows for stability without disrupting distensibility [6,16]. Additionally, the bladder is surrounded by loose connective tissue which separates it from adjacent structures thereby creating an additional layer of protection [6,16,17].

Bladder rupture usually occurs following anterior compression forces transmitted in a ventral to dorsal direction or from lateral compression forces that displace the pubic bone in a lateral to medial direction, injuring the bladder wall [18]. The most common mechanisms of injury are motor vehicle or motorcycle collisions (45%), falls from altitudes greater than 15 ft (20%), and auto-pedestrian collisions [18,19].

In the last decade, nearly all bladder injuries reported in the literature have been associated with gross hematuria and pelvic fractures [19]. It is extremely rare to sustain an isolated traumatic bladder injury in the absence of a pelvic fracture [1]. That being said, dedicated

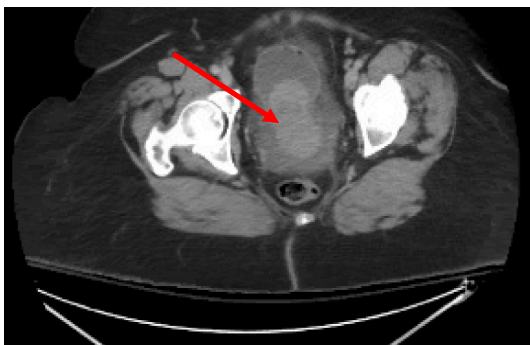


Fig. 1. CT of the Abdomen and Pelvis with contrast demonstrating a hyperdense lesion in the bladder extending through the posterior wall.

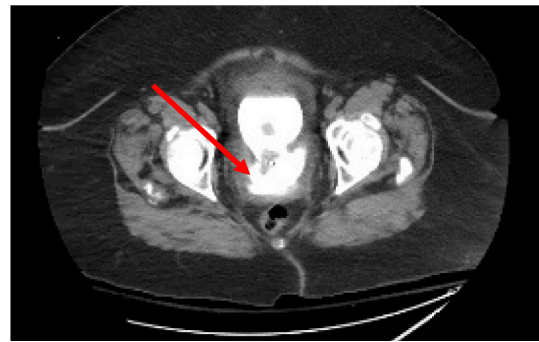


Fig. 2. CT Cystogram demonstrating extravasation of contrast from the urinary bladder into the adjacent soft tissues.

imaging of the bladder is typically performed in the setting of hematuria and pelvic fractures [14].

During our literature search, we were only able to find less than a handful of cases of blunt traumatic bladder rupture in the absence of a pelvic fracture. In 2017, a case of a 37-year-old patient who developed an intra- and extraperitoneal bladder injury as a result of blunt force during a high-velocity motor vehicle collision was published [20]. The patient presented with stable vital signs, abdominal tenderness and bruising of the lower abdomen on physical examination. He had no clinical signs of pelvic instability. A CT scan showed findings consistent with intra- and extraperitoneal bladder rupture without any evidence of pelvic fractures [20]. Similarly, in 2019, there was a case describing seat-belt induced intraperitoneal bladder rupture following a high-impact collision between a motor vehicle and tree [21]. Additionally, in 2021, an 8-year-old boy who took a fall from a six-meter ski lift was found to have a bladder rupture due to perforations in two separate areas in the absence of a pelvic fracture [3]. Unlike the aforementioned cases where the patients suffered high-impact and high-velocity traumas, the present case describes a low-impact trauma.

In addition to our patient presenting after a blunt low-impact trauma, our patient had no associated pelvic fracture. This case is particularly interesting as blunt traumatic extraperitoneal bladder rupture tends to occur with concomitant pelvic fracture and because the patient's pre-existing medical conditions may have contributed to her bladder rupture. Disruption to the pelvic viscera secondary to organ prolapse and its protrusion through the vaginal vault may render the bladder vulnerable to injury from minor trauma.

We present this unique case to show that having an underlying genitourinary prolapse could in fact pose an increased risk of sustaining a serious bladder injury. Based on the recommendations of the Eastern Association for the Surgery of Trauma (EAST) and the American Urologic Association (AUA), patients are stratified into groups based on their baseline risk. For example, in low-risk patients presenting with microscopic hematuria only, no radiographic imaging is indicated. However, patients who are at a moderate risk of injury who present with gross hematuria, a CT cystogram is recommended as well as there is a higher likelihood of bladder rupture. Likewise, patients at high risk of bladder injury who present with gross hematuria and pelvic fractures, a CT cystogram is also recommended. CT cystography is the initial imaging modality of choice in the acute setting due to its comparable accuracy and utility in conjunction with trauma CT surveys in patients with suspected bladder injuries [6,22].

The EAST and AUA recommend non-operative management and use of a foley catheter for extraperitoneal bladder ruptures when extravasation is confined to the peri-vesicular space. The foley catheter is left in place for up to 14 days pending follow up with a post-injury CT cystogram. In general, patients undergo spontaneous healing of the bladder with only 2.4% ultimately requiring operative repair on follow up. In the event where a pelvic fracture is present and open repair is indicated, the

bladder rupture may be repaired intraoperatively to avoid exposure of the orthopedic hardware to the urine [21,22].

Extraperitoneal bladder rupture with extravasation that extends beyond the peri-vesicular space is managed operatively to minimize complications from persistent bladder leakage [21,22].

4. Conclusion

Traumatic bladder rupture is typically seen following blunt trauma in patients presenting with hematuria who also have pelvic fractures; however, the diagnosis should be included in the differential for patients with a history of a genitourinary prolapse presenting after a minor fall. Prompt diagnosis of bladder rupture is necessary as missed injuries could result in complications such as pelvic infections, sepsis, and urinary fistulae. This kind of injury requires a high degree of clinical suspicion and serious complications could arise if a bladder injury is not detected.

Consent

Written informed consent was obtained from the patient for publication of this case report and accompanying images. A copy of the written consent is available for review by the Editor-in-Chief of this journal on request.

Funding

This research did not receive any specific grant from funding agencies in the public, commercial, or not-for-profit sectors.

Guarantor

Dr. Jidefor Aniukwu, MD, PhD, FACS.

Provenance and peer review

Not commissioned, externally peer-reviewed.

Ethical approval

This case report did not require approval by the ethics board at St. Joseph's University Medical Center.

Registration of research studies

N/A.

CRedit authorship contribution statement

(1) The conception and design of the study, or acquisition of data, or analysis and interpretation of data: Logine Abouzead, Celia Leone, Saamia Shaikh, Jidefor Aniukwu

(2) Drafting the article or revising it critically for important intellectual content: Saamia Shaikh, Jidefor Aniukwu

(3) Final approval of the version to be submitted: Saamia Shaikh,

Jidefor Aniukwu, Logine Abouzead, Celia Leone.

Declaration of competing interest

The authors have no conflicts to disclose.

References

- [1] J. Barnard, T. Overholt, A. Hajiran, C. Crigger, M. Jessop, J. Knight, C. Morley, Traumatic bladder ruptures: a ten-year review at a level 1 trauma center, *Adv. Urol.* 2614586 (2019) 1–4.
- [2] B. Phillips, S. Holzmer, L. Turco, M. Mirzaie, E. Mause, A. Mause, A. Person, S. W. Leslie, D.L. Cornell, M. Wagner, R. Bertellotti, J.A. Asensio, Trauma to the bladder and ureter: a review of diagnosis, management, and prognosis, *Eur. J. Trauma Emerg. Surg.* 43 (6) (2017) 763–773.
- [3] Y. Tatekawa, A case of traumatic rupture of the urinary bladder due to a fall from a chair-style ski lift, *J. Surg. Case Rep.* 8 (2021) 1–3.
- [4] K.A. Matlock, A.H. Tyroch, Z.N. Kronfol, S.F. McLean, M.A. Pirela-Cruz, Blunt traumatic bladder rupture: a 10-year perspective, *Am. Surg.* 79 (6) (2013) 589–593.
- [5] Y. Mahat, J.Y. Leong, P.H. Chung, A contemporary review of adult bladder trauma, *J. Inj. Violence Res.* 11 (2) (2019) 101–106.
- [6] D.F. Fouladi, S. Shayesteh, E.K. Fishman, L.C. Chu, Imaging of urinary bladder injury: the role of CT cystography, *Emerg Rad* 27 (1) (2020) 87–95.
- [7] J.N. Corriere Jr., C.M. Sandler, Mechanisms of injury, patterns of extravasation and management of extraperitoneal bladder rupture due to blunt trauma, *J. Urol.* 139 (1) (1988) 43–44.
- [8] R.G. Gomez, L. Ceballos, M. Coburn, J.N. Corriere Jr., C.M. Dixon, B. Lobel, J. McAninch, Consensus statement on bladder injuries, *BJU Int.* 94 (1) (2004) 27–32.
- [9] A.F. Morey, A.J. Iverson, A. Swan, W.J. Harmon, S.S. Spore, S. Bhayani, S. B. Brandes, Bladder rupture after blunt trauma: guidelines for diagnostic imaging, *J. Trauma* 51 (4) (2001) 683–686.
- [10] O. Traxer, F. Pasqui, B. Gattegno, M.S. Pearle, Technique and complications of transurethral surgery for bladder tumours, *BJU Int.* 94 (4) (2004) 492–496.
- [11] E.E. Moore, T.H. Cogbill, G.J. Jurkovich, J.W. McAninch, H.R. Champion, T. A. Gennarelli, M.A. Malangoni, S.R. Shackford, P.G. Trafton, Organ injury scaling. III: chest wall, abdominal vascular, ureter, bladder, and urethra, *J. Trauma* 33 (3) (1992) 337–339.
- [12] R.A. Agha, M.R. Borrelli, R. Farwana, K. Koshy, A. Fowler, D.P. Orgill, For the SCARE Group, The SCARE 2018 statement: updating consensus Surgical CAse REport (SCARE) guidelines, *Int J Surg* 60 (2018) 132–136.
- [13] R.A. Agha, T. Franchi, C. Sohrabi, G. Mathew, for the SCARE Group, The SCARE 2020 guideline: updating consensus Surgical CAse REport (SCARE) guidelines, *International Journal of Surgery* 84 (2020) 226–230.
- [14] A.M. Hertz, N.M. Hertz, N.V. Johnsen, Identifying bladder rupture following traumatic pelvic fracture: a machine learning approach, *Injury* 51 (2020) 334–339.
- [15] D.J. Wolk, C.M. Sandler, J.N. Corriere Jr., Extraperitoneal bladder rupture without pelvic fracture, *J. Urol.* 134 (6) (1985) 1199–1201.
- [16] J.E. Jelovsek, C. Maher, M.D. Barber, Pelvic organ prolapse, *Lancet* 369 (9566) (2007) 1027–1038.
- [17] R. Lich Jr., L.W. Howerton, M. Amin, Anatomy and surgical approach to the urogenital tract in the male, *Campbell's Urol.* 1 (1978) 3.
- [18] S.S. Clark, R.F. Prudencio, Lower urinary tract injuries associated with pelvic fractures. Diagnosis and management, *Surg. Clin. North Am.* 52 (1) (1972) 183–201.
- [19] L. Flint, H.G. Cryer, Pelvic fracture: the last 50 years, *J. Trauma* 69 (3) (2010) 483–488.
- [20] L. Grünherz, X. Startseva, M. Kozomara-Hocke, B.K. Barth, H.P. Simmen, L. Mica, T. Rauer, Combined intra- and extraperitoneal urinary bladder rupture - a rare seat-belt injury: a case report, *Int. J. Surg. Case Rep.* 38 (2017) 119–121.
- [21] A. Elkbuli, J.D. Ehrhardt, S. Hai, M. McKenney, D. Boneva, Management of blunt intraperitoneal bladder rupture: case report and literature review, *Int. J. Surg. Case Rep.* 55 (2019) 160–163.
- [22] L.L. Yeung, A.A. McDonald, J.J. Como, B. Robinson, J. Knight, M.A. Person, J. K. Lee, P. Dahm, Management of blunt force bladder injuries: a practice management guideline from the eastern Association for the Surgery of trauma, *J. Trauma Acute Care Surg.* 86 (2019) 326–336.