

An option for delta-shaped gastroduodenostomy in totally laparoscopic distal gastrectomy for gastric cancer: A single-layer suturing technique for the stapler entry hole using knotless barbed sutures combined with the application of additional knotted sutures

TAKAYA TOKUHARA, EIJI NAKATA, TOSHIYUKI TENJO, ISAO KAWAI,
KEISAKU KONDO, HIROFUMI UEDA and ATSUSHI TOMIOKA

Department of Surgery, Otori Stomach and Intestines Hospital, Osaka 593-8311, Japan

Received June 7, 2017; Accepted October 19, 2017

DOI: 10.3892/ol.2017.7306

Abstract. We report an option for delta-shaped gastroduodenostomy in totally laparoscopic distal gastrectomy (TLDG) for gastric cancer. We detail a single-layer suturing technique for the endoscopic linear stapler entry hole using knotless barbed sutures combined with the application of additional knotted sutures. From June 2013 to February 2017, we performed TLDG with delta-shaped gastroduodenostomy in 20 patients with gastric cancer. The linear stapler was closed and fired to attach the posterior walls of the remnant stomach and the duodenum together. After creating a good view of the greater curvature side of the entry hole for the stapler by retracting the knotted suture on the lesser curvature side toward the ventral side, we performed single-layer entire-thickness continuous suturing of this hole using a 15-cm-long barbed suture running from the greater curvature side to the lesser curvature side. We placed the second and third stitches between the seromuscular layer of the remnant stomach and the entire-thickness layer of the duodenum while suturing the duodenal mucosa as minutely as possible. In addition, we routinely added one or two entire-thickness knotted sutures at the site near the greater curvature side. We placed similar additional knotted sutures at the site with a broad pitch. TLDG with this reconstruction technique was successfully performed in all patients with no occurrences of anastomotic leakage or intraabdominal abscess

around the anastomosis. It is suggested that this method can be one option for delta-shaped gastroduodenostomy in TLDG due to its cost-effectiveness and feasibility.

Introduction

Since laparoscopic-assisted distal gastrectomy was first reported by Kitano *et al* (1), the effectiveness for laparoscopic distal gastrectomy in the treatment of early gastric cancer has been established in several clinical studies (2-6). Moreover, in the past 15 years, totally laparoscopic distal gastrectomy (TLDG), in which all surgical procedures including lymph node dissection, gastric resection, and anastomosis are performed in a wide laparoscopic visual field, has been developed due to improvements in laparoscopic devices and techniques (7-18). Therefore, we introduced TLDG with Roux-en-Y reconstruction or Billroth-I (B-I) reconstruction in 2013. Antecolic Roux-en-Y reconstruction with antiperistaltic gastrojejunostomy was used when the remnant stomach was small or the first portion of the duodenum was short (8,11,16,17). On the other hand, B-I reconstruction was used when the tension in the gastroduodenostomy was low.

Since intracorporeal delta-shaped B-I reconstruction, in which a functional end-to-end gastroduodenostomy was performed using endoscopic linear staplers, was first described by Kanaya *et al*, this technique has been accepted worldwide (7,9-15,17,18). However, the disadvantage of this procedure is the higher cost because it requires many linear stapler cartridges (7,9,10,12). Furthermore, Noshiro *et al* reported that one knotted suture was added on the greater curvature side of the closed entry hole for the stapler to prevent not only anastomotic leakage but also intraabdominal abscess around the anastomosis (15).

V-Loc 180 Wound Closure device (Covidien, Mansfield, MA, USA) consists of a barbed unidirectional absorbable thread with a needle at one end and a loop at the other end. This design causes the tissues to adhere at many points without the need to tie surgical knots (19,20). Here, to reduce the number of linear stapler cartridges used in the

Correspondence to: Dr Takaya Tokuhara, Department of Surgery, Otori Stomach and Intestines Hospital, 653-1 Kami, Sakai, Osaka 593-8311, Japan
E-mail: sur123@osaka-med.ac.jp

Abbreviations: BI, Billroth-I; TLDG, totally laparoscopic distal gastrectomy

Key words: gastric cancer, totally laparoscopic distal gastrectomy, delta-shaped gastroduodenostomy, barbed suture, additional knotted suture

intracorporeal delta-shaped gastroduodenostomy, we present a single-layer entire-thickness suturing technique for the stapler entry hole using 3-0 V-Loc 180 (VLOCL0604; taper point, 1/2 circle/26 mm; length, 15 cm). In addition, to prevent both anastomotic leakage and intraabdominal abscess around the anastomosis, we describe our initial experience combining the application of additional knotted sutures of 3-0 Prolene (Ethicon Endo-Surgery, Cincinnati, OH, USA).

Materials and methods

From June 2013 to February 2017, 20 patients underwent TLDG with delta-shaped gastroduodenostomy with the combined application of 3-0 V-Loc 180 of 15 cm in length and 3-0 Prolene at Otori Stomach and Intestines Hospital. The indication for TLDG at our institution is T1N0M0 gastric cancer, according to the Japanese classification of gastric carcinoma (21), that is located in the middle or lower third of the stomach and is not a candidate for endoscopic submucosal dissection. B-I reconstruction was performed when the tension in the gastroduodenostomy was low.

Patients were placed in the modified lithotomy position. The operator stood between the patient's legs, with the first assistant operating the laparoscope on the left side and the second assistant on the right side. After five trocars were placed in the upper abdomen including the umbilicus and a Nathanson's retractor was inserted from just below the xiphoid process to elevate the round ligament and the lateral segment of the liver, lymphadenectomy based on the Japanese treatment guidelines was performed under a pneumoperitoneum (22). The duodenal bulb was transected in a posteroanterior direction using one endoscopic linear stapler during lymphadenectomy. Proximal gastric resection with reference to preoperative endoscopic marking was carried out (23), and the specimen was removed through the extended umbilical wound using a large plastic bag. Pneumoperitoneum was re-established before the reconstruction.

A small hole was made on the greater curvature side of the remnant stomach and the posterior side of the duodenum. A 45-mm linear stapler was introduced through a left lower port, with one jaw in each hole. The stapler was closed and fired to attach the posterior walls of the remnant stomach and the duodenum together. After confirming that there was no bleeding in the intraluminal anastomotic line, the entry hole for the stapler was closed by the single-layer entire-thickness suturing technique using a knotless barbed suture combined with the application of additional knotted sutures.

An entire-thickness suture with 3-0 Prolene was placed on the lesser curvature side of the entry hole using the extracorporeal slip knot technique (Roeder's knot) (Fig. 1). After creating a good view of the greater curvature side by retracting this knotted suture toward the ventral side (Fig. 2), continuous suturing with a 15-cm 3-0 V-Loc 180 device was carried out from the greater curvature side to the lesser curvature side. The first entire-thickness stitch was positively placed on the greater curvature side, and the needle was passed through the loop (Fig. 3). The second and third stitches were made between the seromuscular layer of the remnant stomach and the entire-thickness layer of the duodenum, with the duodenal mucosa being sutured as minutely as possible (Figs. 4 and 5) to

avoid extroversion of the mucosa of the alimentary tract near the greater curvature side (Fig. 6). Thereafter, single-layer entire-thickness continuous suturing was performed until the suture crossed over the knotted suture on the lesser curvature side (Fig. 7). The suture end was then cut simply, as short as possible, without the need for a knot. Routinely, one or two entire-thickness knotted sutures with 3-0 Prolene were added at the site near the greater curvature side to reinforce this site and avoid loosening of the 3-0 V-Loc 180 (Fig. 8). Similar additional sutures were made on the site with a broad pitch. The intracorporeal B-I reconstruction was then accomplished (Fig. 9).

Results

Patient characteristics and operative outcomes are shown in Table I. In all patients (13 men and 7 women), TLDG with this reconstruction technique was successfully performed without any intraoperative complications. The mean patient age was 64.4 ± 7.8 years (45-77 years), and the mean body mass index was 21.6 ± 1.8 kg/m² (19.3-24.6 kg/m²). The mean operation time was 249 ± 23 min (205-273 min), and the mean estimated blood loss was 22.5 ± 4.6 ml (20-30 ml). The mean number of linear stapler cartridges used intraoperatively was 4.4 ± 0.5 (4-5). The overall mean suturing time of the stapler entry hole was 14.8 ± 1.6 min (12.0-18.1 min). The mean suturing time involving the 3-0 V-Loc 180 was 9.4 ± 1.6 min (7.4-13.0 min), and the mean number of additional knotted sutures placed was 2.9 ± 0.9 (2-4). According to the postoperative complications related to the anastomosis, neither anastomotic leakage nor intraabdominal abscess around the anastomosis, were encountered. However, in one patient, anastomotic hemorrhage at the vertex of the V-shaped staple line requiring endoscopic hemostasis occurred on postoperative day 1, which was categorized as grade IIIa according to the Clavien-Dindo classification (24). There were no other complications, including anastomotic stenosis, pancreatic fistula, and intestinal obstruction. The mean postoperative hospital stay was 13.8 ± 1.5 days (12-17 days). Fig. 10 is a typical upper gastrointestinal fluoroscopic image on postoperative day 3 that shows no anastomotic leakage and stenosis.

Discussion

To securely perform TLDG for gastric cancer, establishment of safe and reproducible intracorporeal reconstruction is essential in addition to precise lymph node dissection and accurate proximal gastric resection. In B-I reconstruction for TLDG, the delta-shaped gastroduodenostomy using only endoscopic linear staplers has been accepted worldwide due to its safety and simplicity (7,9-15,17,18), but the disadvantage of this technique is its higher cost (7,9,10,12). On the other hand, some authors have reported the efficacy of the knotless barbed unidirectional absorbable suture in gastrointestinal reconstruction (25-29), and especially, Nemecek *et al* stated that single-layer entire-thickness sutures of the alimentary tract with 3-0 V-Loc 180 had higher bursting pressures than those with 3-0 monofilament in a cadaver study (27). Therefore, to reduce the number of linear stapler cartridges used in the delta-shaped gastroduodenostomy, a single-layer

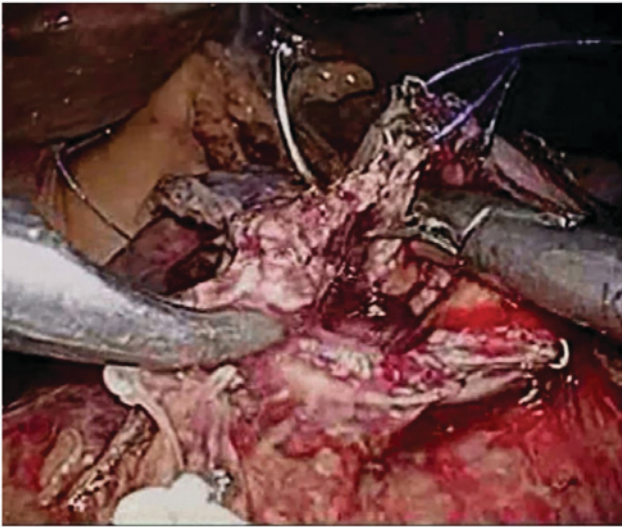


Figure 1. An entire-thickness suture of 3-0 Prolene is made on the lesser curvature side of the stapler entry hole using the extracorporeal slip knot technique (Roeder's knot).

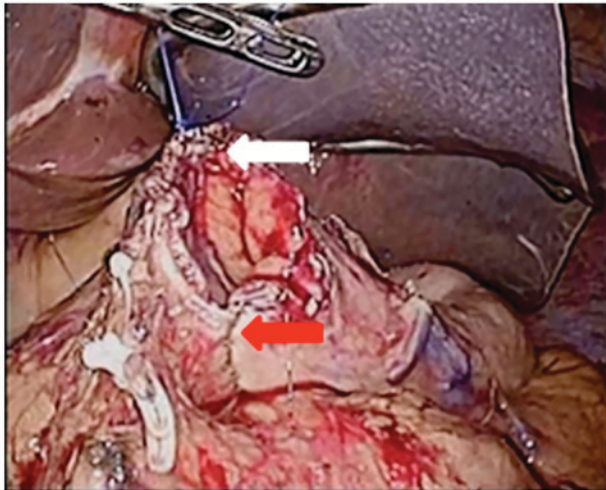


Figure 2. The knotted suture at the lesser curvature side (white arrow) is retracted toward the ventral side to create a good view of the greater curvature side of the stapler entry hole (red arrow).

entire-thickness continuous suturing technique for the stapler entry hole using a 15-cm-long 3-0 V-Loc 180 device was applied because it was not only effective for gastrointestinal reconstruction but also easy to handle in the abdominal cavity. In this patient series, no linear stapler cartridges were used to close the entry hole.

Noshiro *et al* reported that among the initial 71 patients undergoing delta-shaped gastroduodenostomy using linear staplers, 6 experienced anastomotic leakage and 2 developed intraabdominal abscess around the anastomosis, and in all of these patients, the affected site was the greater curvature side of the closed entry hole for the stapler (15). They indicated two possible reasons for these complications. First, the procedure for closing the greater curvature side of the entry hole was uncertain because this site tended to roll backward behind the linear stapler. Next, the extroverted gastroduodenostomy sometimes directly contacted the pancreatic head after

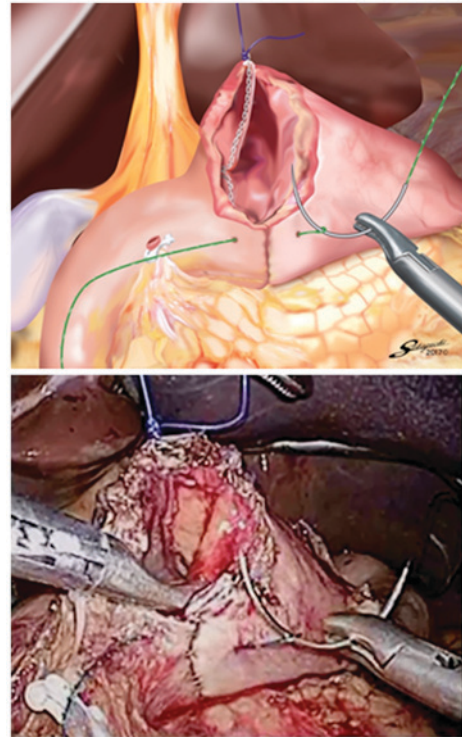


Figure 3. The first entire-thickness stitch with 3-0 V-Loc 180 is placed on the greater curvature side of the stapler entry hole and the needle is passed through the loop.

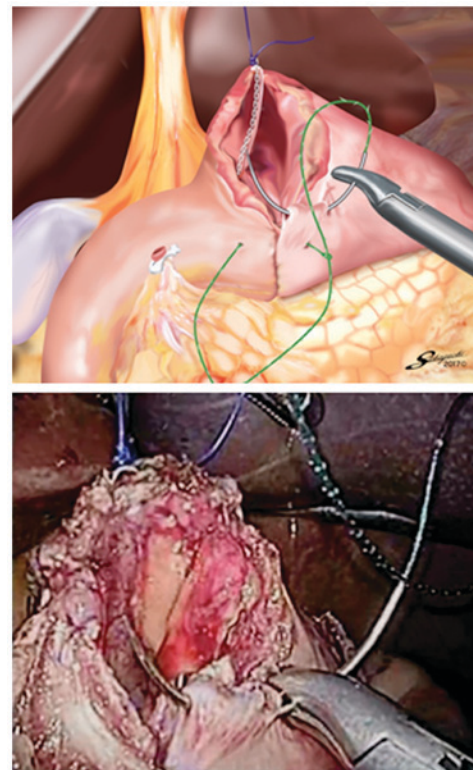


Figure 4. The second and third stitches with 3-0 V-Loc 180 are made on the seromuscular layer of the remnant stomach.

infrapyloric lymph node dissection, and so even minimal leakage of pancreatic juice might be activated by the attachment of mucosa of the alimentary tract. They added one

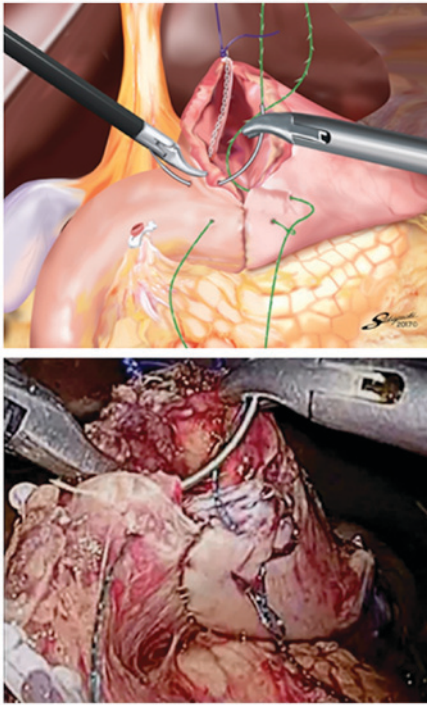


Figure 5. The second and third stitches with 3-0 V-Loc 180 are made on the entire-thickness layer of the duodenum, with the duodenal mucosa being sutured as minutely as possible.

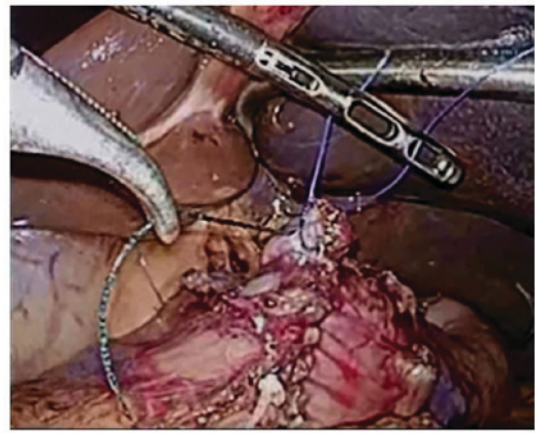


Figure 7. The single-layer entire-thickness continuous suture of the entry hole with 3-0 V-Loc 180 is performed until it crosses over the knotted 3-0 Prolene suture on the lesser curvature side.

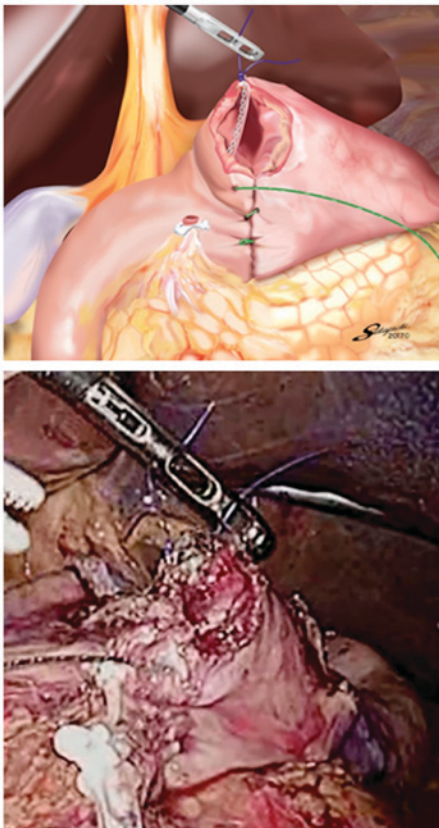


Figure 6. There is no extroversion of mucosa of the alimentary tract near the greater curvature side of the stapler entry hole.

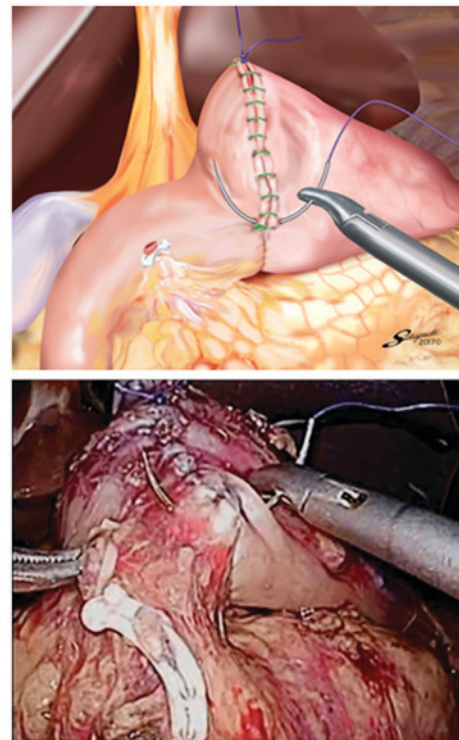


Figure 8. One or two entire-thickness knotted 3-0 Prolene sutures are routinely added at the site near the greater curvature side of the stapler entry hole.

knotted suture on the greater curvature side of the closed entry hole in the last 71 patients and neither anastomotic leakage

nor intraabdominal abscess around the anastomosis occurred among these patients. Thus, to stabilize the outcomes of the delta-shaped gastroduodenostomy with 3-0 V-Loc 180, we standardized the procedure by adding knotted 3-0 Prolene sutures using the extracorporeal slip knot technique (Roeder's knot). The steps of this procedure include; i) retracting the knotted 3-0 Prolene suture on the lesser curvature side toward the ventral side to create a good view of the greater curvature side of the entry hole for the stapler; ii) performing single-layer entire-thickness continuous suturing of the entry hole using 3-0 V-Loc 180 from the greater curvature side to the lesser curvature side; iii) placing the second and third stitches of

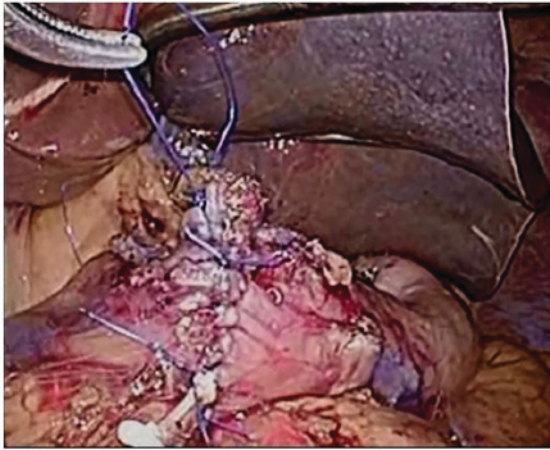


Figure 9. Intracorporeal Billroth-I reconstruction is completed.

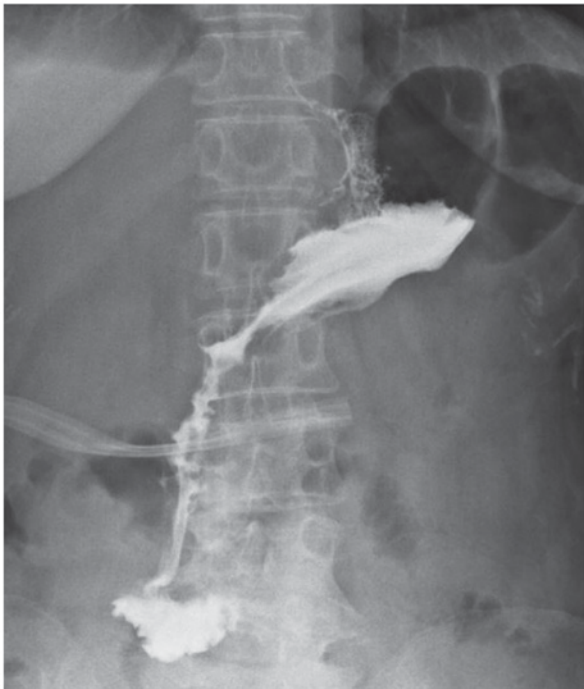


Figure 10. Postoperative fluorography demonstrates the smooth passage of oral contrast through the anastomosis without leakage or stenosis.

3-0 V-Loc 180 between the seromuscular layer of the remnant stomach and the entire-thickness layer of the duodenum by suturing the duodenal mucosa as minutely as possible to avoid extroversion of the alimentary tract near the greater curvature side; iv) routinely adding one or two entire-thickness knotted sutures with 3-0 Prolene at the site near the greater curvature side to reinforce this site and avoid loosening of the 3-0 V-Loc 180; and v) placing similar additional knotted sutures on the site with a broad pitch. In this patient series, this reconstruction procedure resulted in no incidences of anastomotic leakage or intraabdominal abscess around the anastomosis. These results were comparable to those of the last 71 patients reported by Noshiro *et al.*

The knotless barbed suture is assumed to make intracorporeal digestive anastomoses easier to perform because it does

Table I. Patient characteristics and outcomes.

Characteristics and outcomes	Data
Cases, n	20
Age, years	64.4±7.8
Sex, n	
Male	13
Female	7
BMI, kg/m ²	21.6±1.8
Operative time, min	249±23
Blood loss, ml	22.5±4.6
Linear stapler cartridges used, n	4.4±0.5
Overall suturing time, min	14.8±1.6
V-Loc suturing time, min	9.4±1.6
Additional knotted sutures, n	2.9±0.9
Postoperative hospital stay, d	13.8±1.5
Postoperative complications, n	
Anastomotic leakage	0
Intraabdominal abscess	0
Anastomotic hemorrhage	1
Anastomotic stenosis	0
Pancreatic fistula	0
Intestinal obstruction	0

Data are presented as the mean ± SD. BMI, Body Mass Index.

not require any knots and the tension is self-maintained during the running suture, with no need for continuous traction (28). In addition, the extracorporeal knotted suturing technique such as Roeder's knot could be carried out more easily than the intracorporeal ligation technique. Therefore, it is considered that a single-layer suturing technique for the stapler entry hole using 3-0 V-Loc 180 combined with the application of additional knotted sutures of 3-0 Prolene is not difficult to master for the gastrointestinal surgeons.

Although there is a concern that the free tail of the barbed suture might cause intestinal obstruction (30-32), this complication was not encountered in this series. For this reason, it could be considered that we cut the suture end as short as possible and the free tail located at the lesser curvature side of the closed entry hole was covered by the liver.

In conclusion, it is suggested that a single-layer entire-thickness suturing technique for the stapler entry hole using 3-0 V-Loc 180 with a length of 15 cm combined with the application of additional knotted sutures of 3-0 Prolene can be one option for delta-shaped gastroduodenostomy in TLDG due to its cost-effectiveness and feasibility. Examination of a larger number of patients needs to be performed to draw a conclusion on the utility of this reconstruction technique.

References

1. Kitano S, Iso Y, Moriyama M and Sugimachi K: Laparoscopy-assisted Billroth I gastrectomy. *Surg Laparosc Endosc* 4: 146-148, 1994.

2. Adachi Y, Shiraishi N, Shiromizu A, Bandoh T, Aramaki M and Kitano S: Laparoscopy-assisted Billroth I gastrectomy compared with conventional open gastrectomy. *Arch Surg* 135: 806-810, 2000.
3. Kitano S, Shiraishi N, Fujii K, Yasuda K, Inomota M and Adachi Y: A randomized controlled trial comparing open vs. laparoscopy-assisted distal gastrectomy for the treatment of early gastric cancer: An interim report. *Surgery* 131 (1 Suppl): S306-S311, 2002.
4. Hayashi H, Ochiai T, Shimada H and Gunji Y: Prospective randomized study of open versus laparoscopy-assisted distal gastrectomy with extraperigastric lymph node dissection for early gastric cancer. *Surg Endosc* 19: 1172-1176, 2005.
5. Naka T, Ishikura T, Shibata S, Yamaguchi Y, Ishiguro M, Yurugi E, Nishidoi H, Kudoh H, Murakami S and Tsujitani S: Laparoscopy-assisted and open distal gastrectomies for early gastric cancer at a general hospital in Japan. *Hepatogastroenterology* 52: 293-297, 2005.
6. Kim YW, Baik YH, Yun YH, Nam BH, Kim DH, Choi IJ and Bae JM: Improved quality of life outcomes after laparoscopy-assisted distal gastrectomy for early gastric cancer: Results of a prospective randomized clinical trial. *Ann Surg* 248: 721-727, 2008.
7. Kanaya S, Gomi T, Momoi H, Tamaki N, Isobe H, Katayama T, Wada Y and Ohtoshi M: Delta-shaped anastomosis in totally laparoscopic Billroth I gastrectomy: New technique of intraabdominal gastroduodenostomy. *J Am Coll Surg* 195: 284-287, 2002.
8. Takaori K, Nomura E, Mabuchi H, Lee SW, Agui T, Miyamoto Y, Iwamoto M, Watanabe H and Tanigawa N: A secure technique of intracorporeal Roux-Y reconstruction after laparoscopic distal gastrectomy. *Am J Surg* 189: 178-183, 2005.
9. Kim JJ, Song KY, Chin HM, Kim W, Jeon HM, Park CH and Park SM: Totally laparoscopic gastrectomy with various types of intracorporeal anastomosis using laparoscopic linear staplers: Preliminary experience. *Surg Endosc* 22: 436-442, 2008.
10. Song KY, Park CH, Kang HC, Kim JJ, Park SM, Jun KH, Chin HM and Hur H: Is totally laparoscopic gastrectomy less invasive than laparoscopy-assisted gastrectomy?: Prospective, multicenter study. *J Gastrointest Surg* 12: 1015-1021, 2008.
11. Ikeda O, Sakaguchi Y, Aoki Y, Harimoto N, Taomoto J, Masuda T, Ohga T, Adachi E, Toh Y, Okamura T and Baba H: Advantages of totally laparoscopic distal gastrectomy over laparoscopically assisted distal gastrectomy for gastric cancer. *Surg Endosc* 23: 2374-2379, 2009.
12. Kanaya S, Kawamura Y, Kawada H, Iwasaki H, Gomi T, Satoh S and Uyama I: The delta-shaped anastomosis in laparoscopic distal gastrectomy: Analysis of the initial 100 consecutive procedures of intracorporeal gastroduodenostomy. *Gastric Cancer* 14: 365-371, 2011.
13. Kim MG, Kawada H, Kim BS, Kim TH, Kim KC, Yook JH and Kim BS: A totally laparoscopic distal gastrectomy with gastroduodenostomy (TLDG) for early surgical outcomes in high BMI patients. *Surg Endosc* 25: 1076-1082, 2011.
14. Kinoshita T, Shibasaki H, Oshiro T, Oshiro M, Okazumi S and Katoh R: Comparison of laparoscopy-assisted and total laparoscopic Billroth-I gastrectomy for gastric cancer: A report of short-term outcomes. *Surg Endosc* 25: 1395-1401, 2011.
15. Noshiro H, Iwasaki H, Miyasaka Y, Kobayashi K, Masatsugu T, Akashi M and Ikeda O: An additional suture secures against pitfalls in delta-shaped gastroduodenostomy after laparoscopic distal gastrectomy. *Gastric Cancer* 14: 385-389, 2011.
16. Bouras G, Lee SW, Nomura E, Tokuhara T, Nitta T, Yoshinaka R, Tsunemi S and Tanigawa N: Surgical outcomes from laparoscopic distal gastrectomy and Roux-en-Y reconstruction: Evolution in a totally intracorporeal technique. *Surg Laparosc Endosc Percutan Tech* 21: 37-41, 2011.
17. Lee SW, Tanigawa N, Nomura E, Tokuhara T, Kawai M, Yokoyama K, Hiramatsu M, Okuda J and Uchiyama K: Benefits of intracorporeal gastrointestinal anastomosis following laparoscopic distal gastrectomy. *World J Surg Oncol* 10: 267, 2012.
18. Matsuhashi N, Yamaguchi K, Okumura N, Tanahashi T, Matsui S, Imai H, Tanaka Y, Takahashi T, Osada S and Yoshida K: The technical outcomes of delta-shaped anastomosis in laparoscopic distal gastrectomy: A single-center safety and feasible study. *Surg Endosc* 31: 1257-1263, 2017.
19. Alessandri F, Remorgida V, Venturini PL and Ferrero S: Unidirectional barbed suture versus continuous suture with intracorporeal knots in laparoscopic myomectomy: A randomized study. *J Minim Invasive Gynecol* 17: 725-729, 2010.
20. Shah HN, Nayyar R, Rajamahanty S and Hemal AK: Prospective evaluation of unidirectional barbed suture for various indications in surgeon-controlled robotic reconstructive urologic surgery: Wake Forest University experience. *Int Urol Nephrol* 44: 775-785, 2012.
21. Japanese Gastric Cancer Association: Japanese classification of gastric carcinoma: 3rd English edition. *Gastric Cancer* 14: 101-112, 2011.
22. Japanese Gastric Cancer Association: Japanese gastric cancer treatment guidelines 2014 (ver. 4). *Gastric Cancer* 20: 1-19, 2017.
23. Tokuhara T, Nakata E, Tenjo T, Kawai I, Sato S, Inoue K, Araki M, Ueda H and Higashi C: A novel option for preoperative endoscopic marking with India ink in totally laparoscopic distal gastrectomy for gastric cancer: A useful technique considering the morphological characteristics of the stomach. *Mol Clin Oncol* 6: 483-486, 2017.
24. Dindo D, Demartines N and Clavien PA: Classification of surgical complications: A new proposal with evaluation in a cohort of 6336 patients and results of a survey. *Ann Surg* 240: 205-213, 2004.
25. Lee SW, Nomura E, Tokuhara T, Kawai M, Matsuhashi N, Yokoyama K, Fujioka H, Hiramatsu M, Okuda J and Uchiyama K: Laparoscopic technique and initial experience with knotless, unidirectional barbed suture closure for staple-conserving, delta-shaped gastroduodenostomy after distal gastrectomy. *J Am Coll Surg* 213: e39-e45, 2011.
26. Tyner RP, Clifton GT and Fenton SJ: Hand-sewn gastrojejunostomy using knotless unidirectional barbed absorbable suture during laparoscopic gastric bypass. *Surg Endosc* 27: 1360-1366, 2013.
27. Nemecek E, Negrin L, Beran C, Nemecek R and Hollinsky C: The application of the V-Loc closure device for gastrointestinal sutures: A preliminary study. *Surg Endosc* 27: 3830-3834, 2013.
28. Facy O, De Blasi V, Goergen M, Arru L, De Magistris L and Azagra JS: Laparoscopic gastrointestinal anastomoses using knotless barbed sutures are safe and reproducible: A single-center experience with 201 patients. *Surg Endosc* 27: 3841-3845, 2013.
29. Costantino F, Dente M, Perrin P, Sarhan FA and Keller P: Barbed unidirectional V-Loc 180 suture in laparoscopic Roux-en-Y gastric bypass: A study comparing unidirectional barbed monofilament and multifilament absorbable suture. *Surg Endosc* 27: 3846-3851, 2013.
30. Thubert T, Pourcher G and Defieux X: Small bowel volvulus following peritoneal closure using absorbable knotless device during laparoscopic sacral colpopexy. *Int Urogynecol J* 22: 761-763, 2011.
31. Donnellan NM and Mansuria SM: Small bowel obstruction resulting from laparoscopic vaginal cuff closure with a barbed suture. *J Minim Invasive Gynecol* 18: 528-530, 2011.
32. Buchs NC, Ostermann S, Hauser J, Roche B, Iselin CE and Morel P: Intestinal obstruction following use of laparoscopic barbed suture: A new complication with new material? *Minim Invasive Ther Allied Technol* 21: 369-371, 2012.