



# Atypical metastases from prostate cancer detected on 68Ga-PSMA PET/CT: a case series

Lilian Yuri Itaya Yamaga<sup>1</sup>, Marcelo Livorsi da Cunha<sup>1</sup>

<sup>1</sup> Departamento de Imagem, Hospital Israelita Albert Einstein, São Paulo, SP, Brasil

## CASES PRESENTATION

Prostate cancer (PCa) is one of the most frequent malignant tumors in men worldwide. The primary treatment of localized disease consists of radical prostatectomy and radiation therapy. Unfortunately, tumor recurrence after initial treatment is not uncommon and is suspected by the rise in prostate-specific antigen (PSA) levels. Distinguishing between a local recurrence and distant metastases is critical to define an effective therapy (1).

The most common pattern of tumor spread involves abdominopelvic lymph nodes and the bones followed by the lung, liver, pleura, supra-diaphragmatic lymph nodes and adrenal glands. Rarer metastatic sites may be observed in nearly any organ such as the brain, breast, diaphragm, gastrointestinal tract, skin, heart, penis and testicle (2-5).

Traditionally, PCa recurrence is investigated by prostate imaging such as computed tomography, magnetic resonance and bone scintigraphy. However, this approach has limited sensitivity particularly at low PSA levels (1).

The recently introduced positron emission tomography/computed tomography (PET/CT) with the new tracer 68Ga-labeled prostate specific membrane antigen ligand (PSMA) has revolutionized the evaluation of patients with PCa recurrence. PSMA is a transmembrane enzyme which is significantly overexpressed in the majority of

prostatic adenocarcinomas. PSMA expression rises with increasing tumor dedifferentiation, metastatic and hormone-refractory cancers. PET/CT with 68Ga-PSMA provides a high detection rate in the evaluation of local recurrence or metastatic disease with the summary sensitivity and specificity of 86% on per-patient analysis. PET/CT positive results increase with PSA level and shorter PSA doubling time (6-8).

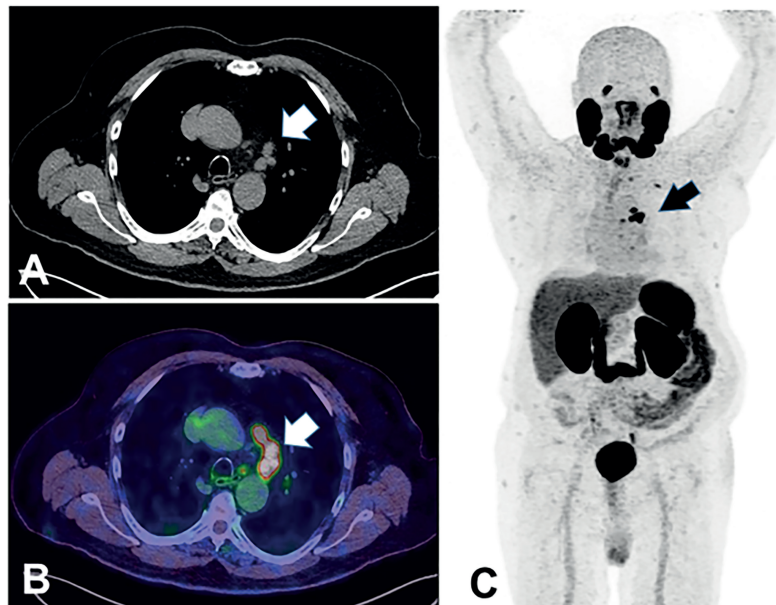
However, to date, a few investigations have described rare sites of metastases from PCa detected by PET/CT with 68Ga-PSMA (9, 10).

We report a case series in which atypical sites of PCa metastases in mediastinal lymph nodes (Figure-1), rectum (Figure-2), testis (Figure-3), deferent duct (Figure-4), penis (Figure-5) and abdominal wall (Figure 6) were detected by PET/CT with 68Ga-PSMA. Of note, a single atypical metastasis was detected by PET/CT in each of three of the six reported cases (Figures 3, 4 and 6). In this context, PET/CT with 68Ga-PSMA had an effective role not only in the detection of the PCa metastasis but also in the treatment planning.

## CONCLUSIONS

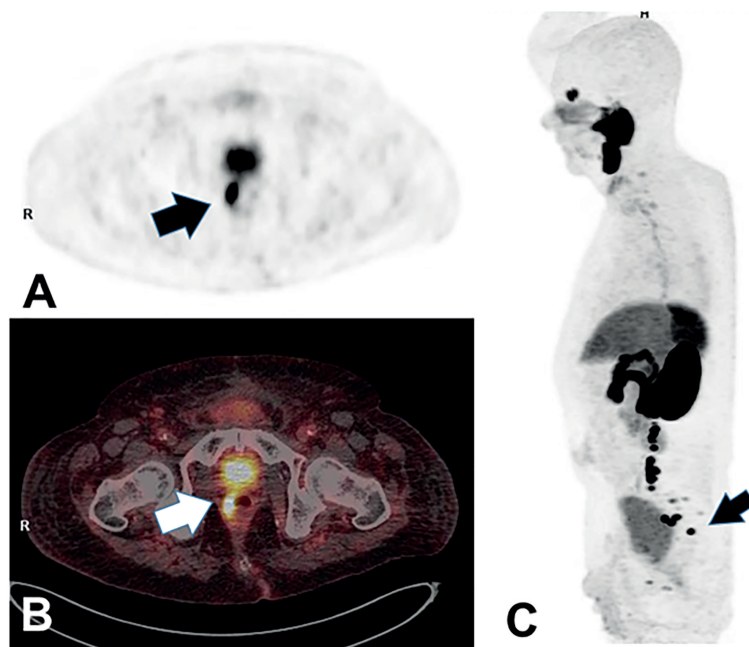
PET-CT with 68Ga-PSMA allows the detection of PCa metastases, including the rarer sites, proving its diagnostic value in the evaluation of the extent of the disease in patients with recurrence.

**Figure 1 - Mediastinal lymph nodes metastases.**



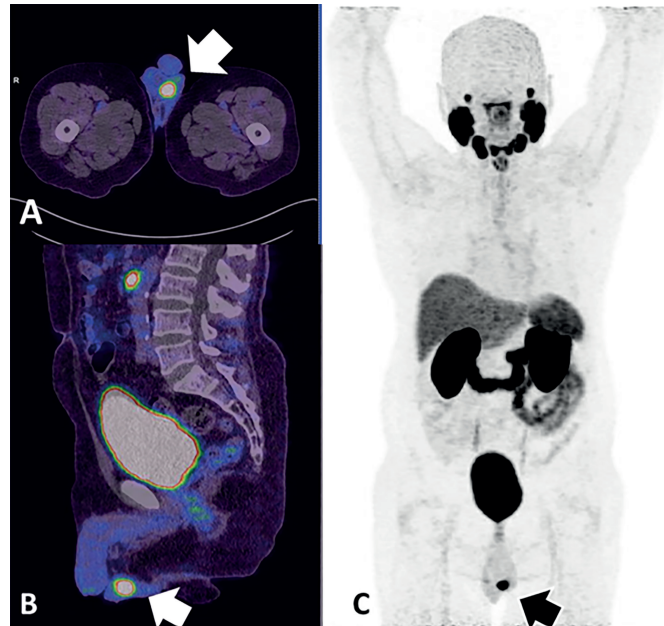
A 70-year-old man presented biochemical recurrence of PCa five years after RP (Gleason score 9 = 4+5) and three years after radiotherapy and hormone therapy. Recent PSA level was of 2.49 ng/mL. 68Ga-PSMA PET/CT: (A) A chest CT, (B) axial PET/CT fused and (C) maximum intensity projection (MIP) images showed tracer uptake in mediastinal lymph nodes. A CT-guided biopsy confirmed lymph node metastases of PCa.

**Figure 2 - Rectal metastasis.**



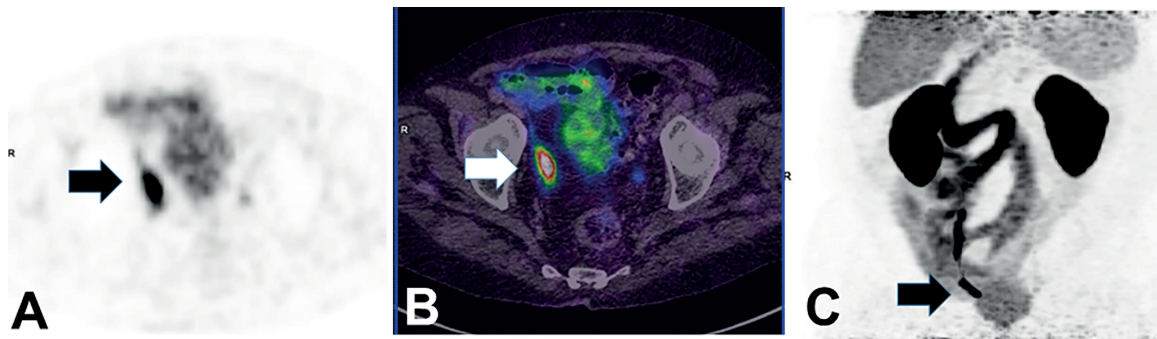
A 84-year-old man underwent RP followed by radiotherapy twenty years ago and antiandrogen hormonal therapy for eighteen months until one year ago. Recent PSA level was of 4.3 ng/mL. 68Ga-PSMA PET/CT: (A) Axial PET and (B) axial PET/CT fused images detected a focal uptake in the rectal wall (arrow). (C) MIP image shows PCa metastases in rectum and also in pelvic lymph nodes. Colonoscopy evidenced thickening in the rectum wall. A CT-guided biopsy confirmed a rectal infiltration by adenocarcinoma of prostatic origin

**Figure 3 - Testicular metastasis.**



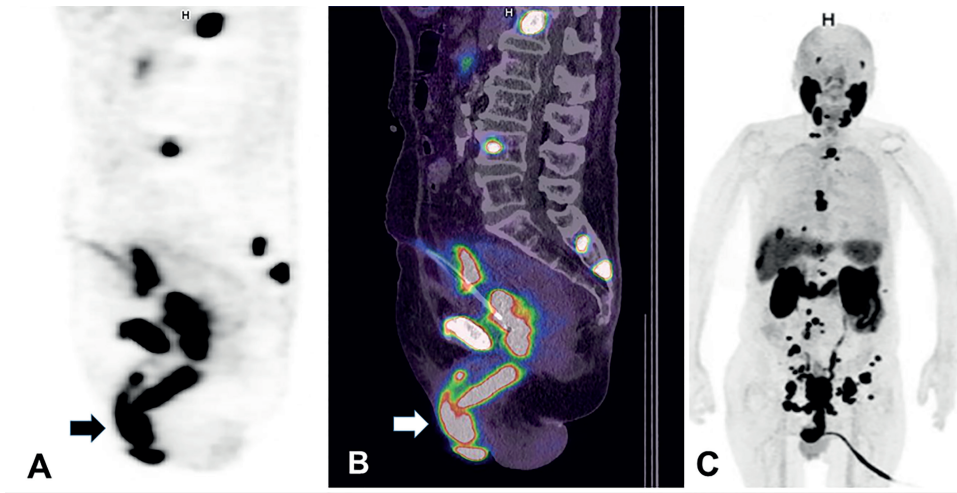
A 68-year-old man with biochemical recurrence seven years after RP (Gleason score 7 = 3+4). Recent PSA level was of 1.2 ng/mL. 68Ga-PSMA PET/CT: (A) axial and (B) sagittal PET/CT fused images and (C) MIP images evidenced a single focus of uptake in left testicle. A firm painful nodule was palpable on the left testicle. A subsequent left orchiectomy and histopathological exam confirmed a testicular PCa metastasis.

**Figure 4 - Deferent duct metastasis.**



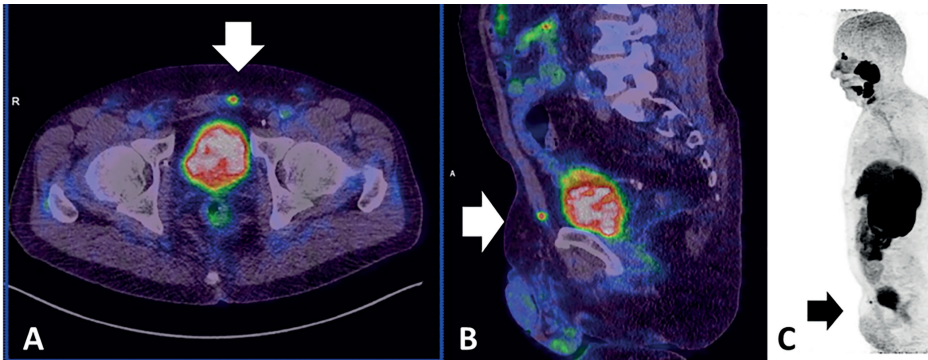
A 88-year-old man presented biochemical recurrence sixteen years after RP for PCa (Gleason score 9 = 4+5). Recent PSA level was of 21,0 ng/mL. 68Ga-PSMA PET/CT: (A) axial PET, (B) axial PET/CT fused and (C) MIP images demonstrated a single area of focal uptake in the right deferent duct. A CT-guided biopsy confirmed a secondary involvement in this location.

**Figure 5 - Penile metastases.**



A 86-year-old man with metastatic PCA after RP (Gleason score 9 = 5+4). Recent PSA level of 3.7 ng/mL. Physical examination revealed multiple non tender nodules involving the glans and the shaft of the penis. 68Ga-PSMA PET/CT: (A) Sagittal PET and (B) Sagittal PET/CT fused images demonstrated metastases in the corpus cavernosum. (C) MIP image also shows secondary lesions in bone, liver, pelvic and retroperitoneal lymph nodes. Because of the advanced disease, a biopsy for histopathological confirmation was not performed and the diagnosis of penile metastases was considered because of the clinical and imaging findings.

**Figure 6 - Abdominal wall metastasis.**



A 71-year-old man developed biochemical recurrence three years after robot-assisted RP (Gleason score 7 = 3+4) for PCA. PSA level was of 0.38 ng/ml. 68Ga-PSMA PET/CT: (A) axial and (B) sagittal PET/CT fused images and (C) MIP images demonstrated a single area of focal abnormal uptake in the anterior abdominal wall. A US guided biopsy confirmed a PCA metastasis.

**Ethical approval**

This study was approved by the institutional Ethics Review Board.

**CONFLICT OF INTEREST**

None declared.

**REFERENCES**

1. Bott SR. Management of recurrent disease after radical prostatectomy. *Prostate Cancer Prostatic Dis.* 2004;7:211-6.
2. Bubendorf L, Schöpfer A, Wagner U, Sauter G, Moch H, Willi N, et al. Metastatic patterns of prostate cancer: an autopsy study of 1,589 patients. *Hum Pathol.* 2000;31:578-83.
3. Gandaglia G, Abdollah F, Schiffmann J, Trudeau V, Shariat SF, Kim SP, et al. Distribution of metastatic sites in patients with prostate cancer: A population-based analysis. *Prostate.* 2014;74:210-6.
4. Vinjamoori AH, Jagannathan JP, Shinagare AB, Taplin ME, Oh WK, Van den Abbeele AD, et al. Atypical metastases from prostate cancer: 10-year experience at a single institution. *AJR Am J Roentgenol.* 2012;199:367-72.
5. Long MA, Husband JE. Features of unusual metastases from prostate cancer. *Br J Radiol.* 1999;72:933-41.
6. Afshar-Oromieh A, Avtzi E, Giesel FL, Holland-Letz T, Linhart HG, Eder M, et al. The diagnostic value of PET/CT imaging with the (68)Ga-labelled PSMA ligand HBED-CC in the diagnosis of recurrent prostate cancer. *Eur J Nucl Med Mol Imaging.* 2015;42:197-209.
7. Eiber M, Maurer T, Souvatzoglou M, Beer AJ, Ruffani A, Haller B, et al. Evaluation of Hybrid 68Ga-PSMA Ligand PET/CT in 248 Patients with Biochemical Recurrence After Radical Prostatectomy. *J Nucl Med.* 2015;56:668-74. Erratum in: *J Nucl Med.* 2016;57:1325.
8. Perera M, Papa N, Christidis D, Wetherell D, Hofman MS, Murphy DG, et al. Sensitivity, Specificity, and Predictors of Positive (68) Ga-Prostate-specific Membrane Antigen Positron Emission Tomography in Advanced Prostate Cancer: A Systematic Review and Meta-analysis. *Eur Urol.* 2016;70:926-37.

**Correspondence address:**

Lilian Yuri Itaya Yamaga MD, PhD  
 Rua José Máximo Monteiro de Oliveira, nº  
 196, Parque dos Príncipes  
 Osasco, São Paulo, Brasil  
 Cep: 06030-362  
 Tel.: 55 11 21510489  
 E-mail: itayay@hotmail.com

**ARTICLE INFO**

 **Lilian Yuri Itaya Yamaga**  
<http://orcid.org/0000-0002-0223-7381>

**Int Braz J Urol. 2021; 47: 205-9**

Submitted for publication:  
 February 02, 2020

Accepted after revision:  
 April 29, 2020

Published as Ahead of Print:  
 September 10, 2020