

# Rare Occurrence of Left Ampullary Ectopic Pregnancy After Ligation of the Left Fallopian Tube: A Case Report

Xue Ke<sup>1</sup>, Li He<sup>2</sup>, Jia-Feng Zheng<sup>1</sup>, Yong-Hong Lin<sup>1</sup>, Fang Wang<sup>1</sup>

<sup>1</sup>Department of Reproductive Medicine, Chengdu Women's and Children's Central Hospital, School of Medicine, University of Electronic Science and Technology of China, Chengdu, People's Republic of China; <sup>2</sup>Department of Gynecology, Chengdu Women's and Children's Central Hospital, School of Medicine, University of Electronic Science and Technology of China, Chengdu, People's Republic of China

Correspondence: Fang Wang, Department of Reproductive Medicine, Chengdu Women's and Children's Central Hospital, School of Medicine, University of Electronic Science and Technology of China, Chengdu, People's Republic of China, Email wangfcd2022@163.com

**Purpose:** Ectopic pregnancy (EP) is rare among patients having received tubal ligation; in these cases, a fertilized ovum is implanted in the proximal tube stump. Distal tubal EP cases in patients having undergone ipsilateral tubal ligation and who have relatively intact contralateral adnexa are extremely rare. Here, we report a case of pregnancy in the distal stump of the ipsilateral fallopian tube following fallopian tubal isthmus ligation.

**Case Presentation:** A 28-year-old woman was admitted after having experienced lower abdominal pain for 10 days and amenorrhea for 1 week and receiving a transvaginal color ultrasonography finding of a heterogeneous echo (2.1 × 1.2 × 1.4 cm) near the left ovary. The patient had a medical history of transvaginal left tubal ligation under single-port laparoscopy for a left hydrosalpinx. Postoperatively, the patient had undergone in vitro fertilization for assisted reproduction. After ovum retrieval, whole-embryo cryopreservation had been performed due to the ovarian hyperstimulation syndrome trend. This pregnancy was natural after embryo cryopreservation. After the patient was admitted, laparoscopic exploration revealed an elevated ampulla in the distal stump of the left fallopian tube. Left salpingectomy with removal of the ectopic pregnancy in the distal remnant tube was performed under the guidance of transvaginal single-port laparoscopy. Serum β-human chorionic gonadotropin levels gradually decreased. Thereafter, the patient underwent two cycles of frozen embryo transfer, both of which resulted in chemical pregnancies.

**Conclusion:** This case suggests that gynecologists should pay attention to the possibility of fallopian tube ectopic pregnancy in the distal tubal segment post-tubal ligation.

**Keywords:** distal stump, ectopic pregnancy, tubal ligation, unilateral salpingectomy, in vitro fertilization

## Introduction

Ectopic pregnancy (EP) is a condition in which a fertilized ovum is implanted outside the endometrial cavity. With a prevalence of approximately 1.5–2.0% among all pregnancies, EP accounts for a major causative factor for maternal mortality in early pregnancy.<sup>1</sup> Under most circumstances, EP evolves within the oviduct (95%) and usually occurs within the ampulla (70%).<sup>2</sup> Uncommon sites for implantation include the diaphragm, abdominal and pelvic retroperitoneal cavity, parametrium, iliac vessels, and liver lobes.<sup>3–7</sup> To the best of our knowledge, EP is rare among patients receiving tubal ligation in which a fertilized ovum is implanted in the proximal tube stump (isthmus or interstitial region). If EP does occur in this population, it typically does so during in vitro fertilization (IVF)-assisted reproduction and after tubal sterilization.<sup>8,9</sup> However, distal tubal EP cases following patients that have undergone ipsilateral tubal ligation and have relatively intact contralateral adnexa are extremely rare. Therefore, this paper reports a rare case of left ampullary pregnancy following isthmus ligation due to a left hydrosalpinx. The patient had a medical history of a right fallopian tube EP and a right salpingostomy.

## Case Presentation

### Chief Complaints

A 28-year-old woman was admitted with the chief complaint of amenorrhea having lasted for 47 days, lower abdominal pain for 10 days, and vaginal bleeding for 1 week.

### History of Present Illness

Two months previously, the patient had undergone an IVF-assisted reproduction procedure. The long-acting protocol was adopted, in which six oocytes were harvested after an ovarian stimulation period of 12 days. Owing to elevated progesterone levels on the triggering day, four D3 embryos were subjected to whole-embryo cryopreservation. This pregnancy was natural after embryo cryopreservation.

### History of Past Illness

A 28-year-old female patient of childbearing age experienced regular menstruation and normal ovulation. She had lived with her partner for over 6 years and had undergone right salpingostomy due to right tubal pregnancy. After surgery, the patient had not conceived for over 5 years without any contraception, and a hysterosalpingography examination revealed bilateral fallopian tube obstruction. The patient then underwent IVF at our hospital for assisted reproduction. Before IVF, a 5.4×4.1 cm cystic-solid mixed echo mass revealed by transvaginal ultrasonography in the left adnexa area with no abnormal blood flow signal suggested a teratoma, with the possibility of a left hydrosalpinx not excluded. After being informed of the effect of hydrosalpinx on pregnancy, the patient underwent transvaginal single-port laparoscopic exploration. Intraoperative findings revealed retroversion of the uterus with fullness of morphology and no obvious abnormalities. The right ovary was 4 × 3 × 2 cm in size, and no obvious abnormalities were observed in the right fallopian tube. The left ovary was approximately 6 × 5 × 4 cm in size, and a cyst of approximately 4 cm in diameter was observed. Mild hydrops was observed in the ampulla and at the distal end of the left fallopian tube. Therefore, the patient first underwent left teratoma-stripping under transvaginal single-port laparoscopy, followed by left tubal ligation. Hysteroscopy revealed no obvious abnormalities in the cervical canals or intracervical opening, normal uterine cavity morphology, normal tunica intima, and visible bilateral fallopian tube openings. Semen examination undergone by the patient's husband and a karyotype analysis of the couple revealed no abnormalities.

### Personal and Family History

There was no relevant personal or family history.

### Physical Examination

The patient's body temperature was 36.4° C, heart rate was 90 bpm, respiratory rate was 21 breaths per minute, blood pressure was 112/63 mmHg, and blood oxygen saturation was 97%. The general appearance was moderate distress. A gynecologic examination revealed normal uterine size, tenderness in the left adnexal area, and stable vital signs.

### Laboratory Examination

Blood analysis revealed a hemoglobin concentration of 9.5 g/dL with normal leukocyte and platelet counts. The prothrombin and partial thromboplastin times were normal, human chorionic gonadotropin level was 1231.2 mIU/mL, and blood biochemistries and urine analysis were normal.

### Imaging Examinations

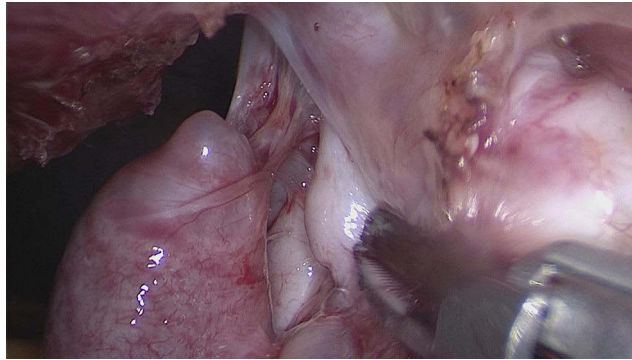
Transvaginal color ultrasonography revealed that the endometrial echo was 1.0 cm in thickness. No definite gestational sac echo was detected in the uterine cavity, and a 2.1 × 1.2 × 1.4 cm hypoechoic mass with irregular heterogeneity was detected in the left adnexal region next to the left ovary, accompanied by dotted blood flow signals. A dissociated echoless retrouterine fossa (4 cm) was detected.

## Final Diagnosis

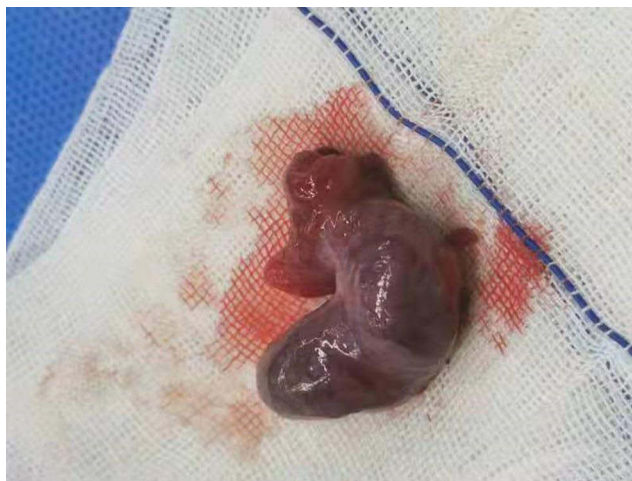
The final diagnosis of the presented case was left distal stump ectopic pregnancy of dissociated echoless retrouterine fossa in the left fallopian tube.

## Treatment

After admission, a transvaginal single-port laparoscopic exploration was performed. In brief, a 2-cm incision was made at the posterior vaginal fornix for access to the abdominal cavity, and a port was subsequently inserted. Laparoscopic findings revealed a dark red hematocoele (approximately 200 mL) in the pelvic cavity, membranous adhesion of the omentum majus, and an intestinal canal with left adnexa. The uterus was of normal size, the uterine wall surface was smooth, and no abnormality was seen in the bilateral ovary morphologies. There was an absence of the isthmus of the left fallopian tube, and an ampullar expansion of approximately  $2.5 \times 1.5 \times 1.5$  cm with a purple- and blue-colored surface was present. A small amount of active bleeding was also observed in the fimbriated extremity of the left fallopian tube, and the proximal end of the ampulla was a blinded end that was not connected with the uterus (Figure 1). Therefore, a left salpingectomy with EP removal from the distal stump tube was performed under the guidance of transvaginal single-port laparoscopy. The sample was then packaged and completely removed from the vaginal incision (Figure 2).



**Figure 1** Transvaginal single-port laparoscopic exploration revealed that the left fallopian tube was separated from the isthmus, and the proximal end of the ampulla was a blind end.



**Figure 2** The ectopic pregnancy is shown in the distal remnant of the left fallopian tube.

## Outcome and Follow-Up

Histological analysis suggested trophoblastic tissues, confirming the EP diagnosis. Unfortunately, two frozen embryo transfers (FETs) after surgery resulted in chemical pregnancies.

## Discussion

The most significant risk factors for EP are previous procedures and conditions that cause tubal injury. To improve the success rate of FET in infertile patients with factors such as hydrosalpinx, ligation, and salpingectomy should be performed beforehand.<sup>8</sup> Some studies have posited that salpingectomy is as safe and effective as tubal ligation for sterilization and reduces the risk of postoperative pregnancies and ovarian cancer. Laparoscopic salpingectomy prior to IVF was shown to be beneficial in patients with large hydrosalpinges that were visible on ultrasound.<sup>9,10</sup>

The risk of repeated EP (REP) significantly increases along with the number of previous EPs. In a study by Moini et al, EP risk increased 17-fold in women with a previous EP history relative to controls.<sup>11</sup> EP risk also increases for those having undergone tubal microsurgery or conservative surgery for tubal pregnancy.<sup>12</sup> While these studies emphasize the impact of multiple EPs, the effect of same-site occurrence remains unclear. In this case study, under the condition of an unobstructed fallopian tube where EP previously occurred, REP occurred in the previously ligated contralateral fallopian tube and not in the isthmus or interstitial region, which is extremely rare.

A history of tubal surgery such as recanalization and tubectomy is also a major risk factor for EP, with REP rates after salpingectomy and salpingostomy reported as 5% and 8%, respectively.<sup>13</sup>

Tubal ligation leads to a higher risk of EP in a large-sample prospective cohort study, with risk factors such as smoking and intrauterine device use showing a far lower risk than tubal ligation.<sup>14</sup> However, the reason that tubal ligation carries such a high risk for EP remains unclear. Additionally, Cho et al reported a rare case of broad-ligament EP following bilateral tubal ligation.<sup>15</sup> Interligamentous or broad-ligament pregnancy is quite uncommon, occurring in 1/300 EPs. Among rare EP sites, the proximal tube stump is more commonly reported because of the number of embryos transferred in IVF.<sup>8</sup>

As assisted reproductive technologies develop, EP is showing an increasing incidence, occurring in 1.4–3.2% of the pregnancies post-IVF treatment, which is approximately 2.5–5 times greater than in natural conceptions.<sup>16,17</sup> The EP rate also shows a positive relationship with ovarian stimulation during fresh IVF and intracytoplasmic sperm injection cycles and increases depending on peak estradiol levels in patients with tubal and non-tubal infertility in fresh cycles. Therefore, it is speculated that changes in estrogen levels are involved in tubal cilium movement, thus participating in EP formation.<sup>17</sup> In our case, EP occurred 2 months following ovarian stimulation and oocyte retrieval.

The patient in this case showed several risk factors for REP, and there are multiple possibilities for the mechanism of distal tubal EP. In the first, the sperm entered the pelvic cavity through the right fallopian tube from the uterine cavity. After ovulation, the early embryo was picked up by the left distal tubal stump. However, owing to the restriction of the blinded interstitial stump, the embryo was not transported into the uterine cavity but implanted in the distal stump. The second possibility was that the sperm entered the pelvic cavity via the right fallopian tube after entering the uterine cavity and then entered the ampulla of the left fallopian tube through its fimbriated extremity. Thereafter, these fimbriae picked up the ovum, and pregnancy developed after the ovum entered the ampulla. According to the literature, whether spermatozoa migrate into the abdominal cavity via the cornual fistulous tract remains unclear.<sup>2</sup> Additionally, Yang et al reported a patient who underwent right salpingectomy due to right fallopian EP and developed an omental pregnancy after left tubal ligation.<sup>2</sup> It has been speculated that the postoperative fallopian tube stumps may spontaneously reperfuse or form a fistula, making it possible for the uterine cavity to communicate with the retroperitoneal cavity.<sup>18</sup> Ching-Min Lin et al reported a rare case of spontaneous right distal tubal pregnancy after bilateral laparoscopic tubal sterilization. They inferred that a micro fistula had formed and therefore sperm penetration was possible through the blunt end.<sup>19</sup> However, in the present case, intact bilateral fallopian tube stumps were observed while the distal fallopian stump was detached from the isthmus of the fallopian tube, which seems to exclude this explanation. Another hypothesis suggests that the fertilized ovum reached the retroperitoneal cavity through the lymphatic system in a mechanism similar to metastasis because lymphatic tissues have been detected in ectopic masses in post-surgical pathological analysis.<sup>20</sup> Regardless of which hypothesis is true, it is certain that the ligated

fallopian tube ampulla and the distal stump have physiological functions. Ching-Min Lin et al reported a rare case of spontaneous right distal tubal pregnancy after bilateral laparoscopic tubal sterilization.

## Conclusion

The literature associates tubal ligation and partial salpingectomy with increased EP risk, and total salpingectomy may be more safe and more effective than tubal ligation for sterilization. For treating hydrosalpinx, complete salpingectomy may be conducted to eliminate the EP risk as well as the associated morbidity and mortality. This is especially true for patients planning to receive IVF-assisted reproduction. This work focused on emphasizing the variety of EP and suggests that gynecologists remain vigilant of the possibility of EP at the distal fallopian tube stump. We conclude that patients with regular menstruation and high risk factors for EP should undergo a pregnancy test a few days following amenorrhea, even if there is a history of tubal ligation.

## Abbreviations

EP, ectopic pregnancy; IVF, in vitro fertilization; FET, frozen embryo transfers; REP, repeated ectopic pregnancy.

## Ethical Approval

The study was approved by the ethics committee of Chengdu Women's and Children's Central hospital (V1.0 2022135).

## Declaration of Patient Consent

Written informed consent was obtained from the patient for publication of this case report and any accompanying images.

## Acknowledgments

We would like to acknowledge our patient for consenting to the publication of this case report and express gratitude to our colleague Li He, Department of Gynecology, for her help with the production of intra-operative imagery.

## Author Contributions

All authors made a significant contribution to the work reported, whether that is in the conception, study design, execution, acquisition of data, analysis and interpretation, or in all these areas; took part in drafting, revising or critically reviewing the article; gave final approval of the version to be published; have agreed on the journal to which the article has been submitted; and agree to be accountable for all aspects of the work.

## Disclosure

The authors report no conflict of interest for this work.

---

## References

1. Jin XY, Li C, Xu W, Liu L, Wei ML. Factors associated with the incidence of ectopic pregnancy in women undergoing assisted reproductive treatment. *Chin Med J*. 2020;133(17):2054–2060. doi:10.1097/CM9.0000000000001058
2. Yang -L-L, Zhou Y, Luo S-P. A primary omental pregnancy after unilateral salpingectomy and unilateral tubal ligation. *Taiwan J Obstet Gynecol*. 2015;54(6):786–787. doi:10.1016/j.tjog.2015.10.015
3. Qiaorui S, Xue W, Xiaohui W. A rare case of ectopic pregnancy: posterior ectopic pregnancy of the iliac vessels. *Int J Gynaecol Obstet*. 2021;153(2):359–360. doi:10.1002/ijgo.13597
4. Xu H, Cheng D, Yang Q, Wang D. Multidisciplinary treatment of retroperitoneal ectopic pregnancy: a case report and literature review. *BMC Pregnancy Childbirth*. 2022;22(1):472. doi:10.1186/s12884-022-04799-5
5. Di Lorenzo G, Romano F, Mirenda G, Cracco F, Buonomo F. “Nerve-sparing” laparoscopic treatment of parametrial ectopic pregnancy. *Fertil Steril*. 2021;116(4):1197–1199. doi:10.1016/j.fertnstert.2021.05.106
6. Chen LF, Liu JW, Shu J, Zeng WJ, Zhao XF. Successful laparoscopic management of diaphragmatic pregnancy: a rare case report and brief review of the literature. *BMC Pregnancy Childbirth*. 2019;19(1):99. doi:10.1186/s12884-019-2248-0
7. Hao JW, Cheng Z, Hu N, Xiao LZ, Wang YH. Imaging of hepatic ectopic pregnancy by 18F-FDG PET/CT. *Clin Nucl Med*. 2016;41(9):697–698. doi:10.1097/RLU.0000000000001307
8. OuYang Z, Yin Q, Wu J, Zhong B, Zhang M, Li F. Ectopic pregnancy following in vitro fertilization after bilateral salpingectomy: a review of the literature. *Eur J Obstet Gynecol Reprod Biol*. 2020;254:11–14. doi:10.1016/j.ejogrb.2020.08.046

9. Mills K, Marchand G, Sainz K, Azadi A, Ware K. Salpingectomy vs tubal ligation for sterilization: a systematic review and meta-analysis. *Am J Obstet Gynecol*. 2021;224(3):258–265. doi:10.1016/j.ajog.2020.09.011
10. Kirsten Ely L, Throng M. The role of opportunistic bilateral salpingectomy vs tubal occlusion or ligation for ovarian cancer prophylaxis. *J Minim Invasive Gynecol*. 2017;24(3):371–378. doi:10.1016/j.jmig.2017.01.001
11. Moini A, Hosseini R, Jahangiri N, Shiva M, Akhoond MR. Risk factors for ectopic pregnancy: a case-control study. *J Res Med Sci*. 2014;19(9):844–849.
12. Xu Z, Yan L, Liu W, Xu X, Li M. Effect of treatment of a previous ectopic pregnancy on in vitro fertilization-intracytoplasmic sperm injection outcomes: a retrospective cohort study. *Fertil Steril*. 2015;104(6):1446–51.e1. doi:10.1016/j.fertnstert.2015.08.034
13. Mol F, van Mello NM, Strandell A, Strandell K, Jurkovic D. Salpingotomy versus salpingectomy in women with tubal pregnancy (ESEP study): an open-label, multicentre, randomized controlled trial. *Lancet*. 2014;383(9927):1483–1489. doi:10.1016/S0140-6736(14)60123-9
14. Gaskins AJ, Missmer SA, Rich-Edwards JW, Williams PL, Souter I, Chavarro JE. Demographic, lifestyle, and reproductive risk factors for ectopic pregnancy. *Fertil Steril*. 2018;110(7):1328–1337. doi:10.1016/j.fertnstert.2018.08.022
15. Cho YK, Henning S, Harkins G. Broad ligament ectopic pregnancy after bilateral tubal ligation. *J Minim Invasive Gynecol*. 2018;25(2):314–315. doi:10.1016/j.jmig.2017.02.024
16. Londra L, Moreau C, Strobino D, Garcia J, Zacur H, Zhao Y. Ectopic pregnancy after in vitro fertilization: differences between fresh and frozen-thawed cycles. *Fertil Steril*. 2015;104(1):110–118. doi:10.1016/j.fertnstert.2015.04.009
17. Bu Z, Xiong Y, Wang K, Sun Y. Risk factors for ectopic pregnancy in assisted reproductive technology: a 6-year, single-center study. *Fertil Steril*. 2016;106(1):90–94. doi:10.1016/j.fertnstert.2016.02.035
18. Wang X, Ma D, Zhang Y, Chen Y, Zhang Y. Rare heterotopic pregnancy after frozen embryo transfer: a case report and literature review. *BMC Pregnancy Childbirth*. 2020;20(1):542. doi:10.1186/s12884-020-03214-1
19. Lin CM, Ku YL, Cheng YT, Giin NY, Ou YC. An uncommon spontaneous right distal tubal pregnancy post bilateral laparoscopic sterilization: a case report. *Medicine*. 2019;98(4):e14193. doi:10.1097/MD.00000000000014193
20. Liang C, Li X, Zhao B, Du Y, Xu S. Demonstration of the route of embryo migration in retroperitoneal ectopic pregnancy using contrast-enhanced computed tomography. *J Obstet Gynaecol Res*. 2014;40(3):849–852. doi:10.1111/jog.12233

International Journal of Women's Health

Dovepress

## Publish your work in this journal

The International Journal of Women's Health is an international, peer-reviewed open-access journal publishing original research, reports, editorials, reviews and commentaries on all aspects of women's healthcare including gynecology, obstetrics, and breast cancer. The manuscript management system is completely online and includes a very quick and fair peer-review system, which is all easy to use. Visit <http://www.dovepress.com/testimonials.php> to read real quotes from published authors.

Submit your manuscript here: <https://www.dovepress.com/international-journal-of-womens-health-journal>