



## Case report

## Cutibacterium avidum: A rare but expected agent of breast implant infection



Ramírez Isabel<sup>a,b,\*</sup>, Manrique Monica<sup>c</sup>

<sup>a</sup> Internal Medicine and Infectious Diseases Section, University of Antioquia Medical School, calle 78B#69-240, 050010, Medellín, Colombia

<sup>b</sup> Infectious Diseases Section, Hospital Pablo Tobón Uribe, 050010, Medellín, Colombia

<sup>c</sup> CES University Medical School, Cl. 10a #22 - 04, 050021, Medellín, Colombia

## ARTICLE INFO

## Article history:

Received 14 February 2019

Received in revised form 28 April 2019

Accepted 28 April 2019

## Keywords:

*Cutibacterium avidum*

Breast

Implants

Infection

## ABSTRACT

*Cutibacterium avidum* is largely commensal and part of the skin microbiota, recently recognized as a pathogen that causes surgical site infections, especially in the presence of implants or medical devices.

We present a 50-year-old woman with *Cutibacterium avidum* infection associated with breast implant augmentation, which required the removal of the implants to achieve the cure.

As a skin commensal, *Cutibacterium avidum* previously was considered of low pathogenicity, but is now recognized as a causative organism of serious spontaneous and surgical site infections. It should not be routinely disregarded without further investigation, particularly if clinical signs of infection are present.

© 2019 The Authors. Published by Elsevier Ltd. This is an open access article under the CC BY-NC-ND license (<http://creativecommons.org/licenses/by-nc-nd/4.0/>).

## Introduction

Infections associated with breast augmentation with implants are one of the complications that frequently lead to their loss, with undesirable aesthetic consequences. The microorganisms that belong to the skin microbiota are regularly implicated in this type of infections. *Staphylococcus aureus*, and staphylococcal coagulase negative species are the most frequently isolated pathogens. Rarely, Gram-negative rods, mycobacteria and molds are reported [1,2]. As part of microbiota, *Cutibacterium* (formerly *Propionibacterium*) species are associated with this type of infection, but currently, only cases of *C. acnes* infection have been reported [2]. We present the first case of *C. avidum* infection associated with breast implant augmentation.

## Case report

A 50-year-old woman with a previous history of penicillin allergy, hypothyroidism, dyslipidemia and prediabetes, was admitted to the hospital with left breast pain, erythema and edema 16 days after having a mastopexy with breast implants. A single 900-mg dose of perioperative intravenously administered clindamycin was used. On examination, the patient had erythema and seropurulent drainage from the right breast surgical wound

(Figs. 1A, B), and cellulitis in the inferior quadrants of the left breast (Fig. 1C). She had no signs of sepsis. She had operative surgical lavage of the right breast; cultures of the drainage and tissue were negative, then she received oral clindamycin 600 mg three times day. Eight days later, the patient continued with inflammatory signs and wound drainage; antimicrobials were discontinued and two days later she had repeat surgical lavage and removal of the implants. Bilateral tissue cultures were taken. Gram-positive rods were present on tissue Gram stains. Cultures grew Gram-positive bacilli identified by MALDITOF - MS as *Cutibacterium avidum*, no susceptibility testing were done due to lack of availability in the laboratory. The patient was treated with oral moxifloxacin 400 mg/day for seven days with complete resolution of her symptoms at one year follow-up.

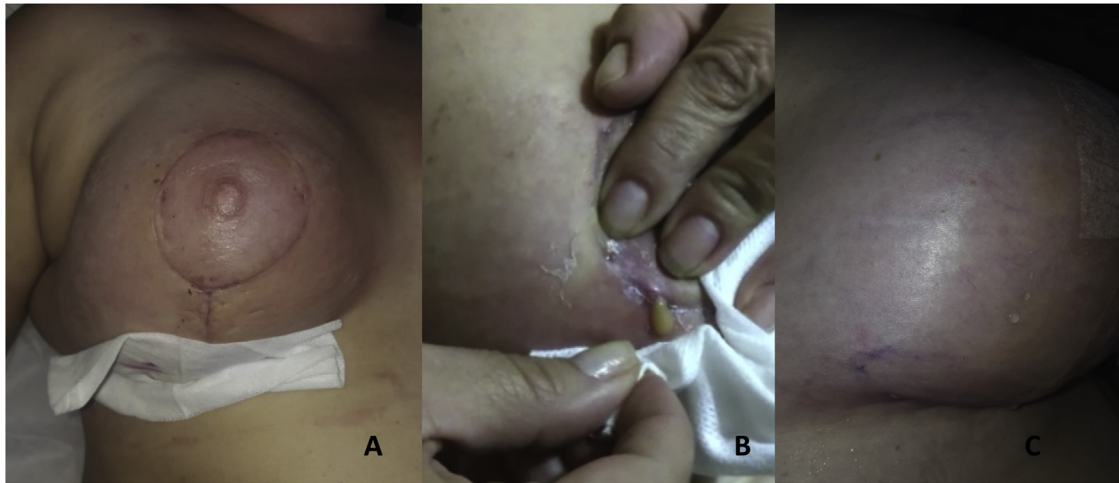
## Discussion

*Cutibacterium avidum* is a Gram-positive anaerobic rod, which belongs to the skin microbiota. It grows mainly in humid skin areas and pilosebaceous follicles of regions such as axilla, folds and perianal region [3]. Infections caused by this microorganism are usually associated to predisposing factors such as surgery, foreign bodies and malignancy. As a skin commensal, previously considered of low pathogenicity, it is now recognized as a causative organism of serious spontaneous and surgical site infections (SSI) [4]. Indeed groin colonization is a recognized risk factor for hip periprosthetic joint infection [5].

According to the literature available there have been reports of SSI after breast reduction [6,7], post-mastectomy [8], abdominal

\* Corresponding author at: calle 78B#69-240, Medellín, Colombia.

E-mail addresses: [iramirez@hptu.org.co](mailto:iramirez@hptu.org.co) (R. Isabel), [mmanrique@outlook.com](mailto:mmanrique@outlook.com) (M. Monica).



**Fig. 1.** A. Erythema and swelling of the right breast. B. Seropurulent drainage through the surgical wound in the right breast. C. Cellulitis in the inferior quadrants of the left breast.

parietoplasty [9], periprosthetic infections [10], prosthetic valve endocarditis [11], and sacroiliitis after herniorrhaphy [12]. Post-procedural infections, including splenic abscess after coronary bypass [13], and cardiac catheterization [14] have also been described in immunocompetent patients [15].

*C. avidum* is highly susceptible to multiple antimicrobials, including beta-lactam agents and fluoroquinolones. Clindamycin resistance has been described [4], and in our case, maybe could explain the failure of antibiotic perioperative prophylaxis and further empirical treatment, but unfortunately, we could not perform susceptibility testing. The treatment includes early surgical debridement and appropriate antibiotic therapy, and in some patients, implant removal is required to resolve the infection.

## Conclusion

As a skin commensal, *Cutibacterium avidum* previously was considered of low pathogenicity, but is now recognized as a causative organism of serious spontaneous and surgical site infections. It should not be routinely disregarded without further investigation, particularly if clinical signs of infection are present.

## Declarations of interest

None.

## Compliance with ethical standards

This article does not contain any studies with human participants or animals performed by any of the authors.

## Informed consent

Written informed consent was obtained from the patient for publication of this case report and accompanying images. A copy of the written consent is available for review by the Editor-in-Chief of this journal on request.

## Funding source

This study did not receive any specific grant from funding agencies in the public, commercial, or not-for-profit sectors.

## Ethical approval

This report was approved by the ethics and research committees of the Institutions.

## CRedit authorship contribution statement

**Ramírez Isabel:** Conceptualization, Data curation, Investigation, Methodology, Writing - original draft, Writing - review & editing. **Manrique Monica:** Conceptualization, Data curation, Investigation, Methodology, Writing - original draft, Writing - review & editing.

## References

- [1] Lalani T. Breast implant infections: an update. *Infect Dis Clin North Am* 2018;32:877–84.
- [2] Seng P, Bayle S, Alliez A, Romain F, Casanova D, Stein A. The microbial epidemiology of breast implant infections in a regional referral centre for plastic and reconstructive surgery in the south of France. *Int J Infect Dis* 2015;35:62–6.
- [3] Nordstrom NK, Noble WC. Colonization of the axilla by *Propionibacterium avidum* in relation to age. *Appl Environ Microbiol* 1984;47:1360–2.
- [4] Corvec S. Clinical and biological features of *Cutibacterium* (Formerly *Propionibacterium*) *avidum*, an underrecognized microorganism. *Clin Microbiol Rev* 2018. doi:<http://dx.doi.org/10.1128/CMR.00064-17>.
- [5] Böni L, Kuster SP, Bartik B, Zbinden R, Zingg PO, Achermann Y. *Cutibacterium avidum* colonization in the groin is associated with obesity: a potential risk factor for hip periprosthetic joint infection. *Clin Infect Dis* 2018;67:1878–82.
- [6] Levin B, Foo H, Lee A, Gottlieb T. *Propionibacterium avidum* as the cause of severe breast infection following reduction mammoplasty. *ANZ J Surg* 2008;78:318–9.
- [7] Panagea S, Corkill JE, Hershman MJ, Parry CM. Breast abscess caused by *Propionibacterium avidum* following breast reduction surgery: case report and a review of the literature. *J Infect* 2005;51:253–5.
- [8] Werno AM, Seaward LM, Laird H, Short PF. Breast abscess caused by *Propionibacterium avidum*. *Clin Microbiol News* 2004;29:70–1.
- [9] Janvier F, Delacour H, Larréché S, Abdalla S, Aubert P, Mérens A. Abdominal wall and intra-peritoneal abscess by *Propionibacterium avidum* as a complication of abdominal parietoplasty. *Pathol Biol (Paris)* 2013;61:223–5.
- [10] Achermann Y, Liu J, Zbinden R, Zingg PO, Anagnostopoulos A, Barnard E, et al. *Propionibacterium avidum*: a virulent pathogen causing hip periprosthetic joint infection. *Clin Infect Dis* 2018;66:54–63.
- [11] Loureiro-Amimigo J, Pons S, Sierra M, Meije Y. Prosthetic valve with infective endocarditis caused by *Propionibacterium avidum*. A case report. *Enferm Infecc Microbiol Clin* 2017;35:196–7.
- [12] Estoppey O, Rivier G, Blanc CH, Widmer F, Gallusser A, So AK. *Propionibacterium avidum* sacroiliitis and osteomyelitis. *Rev Rheum Engl Ed* 1997;67:54–6.

- [13] Dunne Jr. WM, Kurschenbaum HA, Deshur WR, Dee TH, Samter TG, Williams JE, et al. *Propionibacterium avidum* as the etiologic agent of splenic abscess. *Diagn Microbiol Infect Dis* 1986;5:87–92.
- [14] Vohra A, Saiz E, Chan J, Castro J, Amaro R, Barkin J. Splenic abscess caused by *Propionibacterium avidum* as a complication of cardiac catheterization. *Clin Infect Dis* 1998;26:770–1.
- [15] Kritikos A, Pagin M, Borens O, Voide C, Orasch C. Identification of *Propionibacterium avidum* from a breast abscess: an overlooked etiology of clinically significant infections. *New Microbes New Infect* 2014, doi:<http://dx.doi.org/10.1016/j.nmni.2014.12.001>.