


ORIGINAL ARTICLE

# Percutaneous transhepatic cholangiography in the era of magnetic resonance cholangiopancreatography: A prospective comparative analysis in preoperative evaluation of benign biliary stricture

Kailash C Kurdia,\* Santhosh Irrinki,\* Bharath Siddharth,\* Vikas Gupta,\* Anupam Lal† and Thakur D Yadav\* 

Departments of \*General Surgery and †Radiodiagnosis, Post Graduate Institute of Medical Education and Research (PGIMER), Chandigarh, India

## Key words

benign biliary stricture, cholecystectomy, magnetic resonance cholangiopancreatography, percutaneous transhepatic cholangiography, Roux-en-Y hepatico-jejunostomy.

Accepted for publication 8 June 2021.

## Correspondence

Thakur D Yadav, Department of General Surgery, 5th Floor, F block, Nehru Hospital, Postgraduate Institute of Medical Education and Research, Chandigarh 160012, India.  
Email: tdyadav@gmail.com

**Declaration of conflict of interest:** No conflicts of interest to disclose.

## Abstract

**Background and Aim:** Accurate anatomical delineation is the key before definitive repair for benign biliary stricture (BBS). The role of percutaneous transhepatic cholangiography (PTC) as a road map is less studied in the era of magnetic resonance cholangiopancreatography (MRCP).

**Methods:** A prospective observational study, performed between July 2012 and December 2013. All patients of post-cholecystectomy BBS were evaluated with MRCP and PTC prior to definitive repair. Findings of MRCP and PTC were compared with intraoperative details.

**Results:** Thirty patients with BBS were included in the study. MRCP was performed in all but PTC was amenable in 28 of 30 (93.3%) patients. PTC was comparable to MRCP in diagnosing stricture type (96.4% vs 89.3%), intrahepatic stones (75% vs 75%), and biliary anomalies (95.6% vs 100%). Additionally, PTC revealed internal biliary fistula in 4 (85.7% vs 61.4%; *P* value 0.04). PTC-related minor complications were noted in 2 (7.1%) patients.

**Conclusion:** PTC is comparable to MRCP in diagnosing the stricture type, intrahepatic biliary stones, and biliary anomalies. Though comparable to MRCP, the authors could not reveal any additional information that could change the course of management in BBS.

## Introduction

Benign biliary strictures (BBS) following an iatrogenic injury cause physical, social as well mental trauma in turn affecting the quality of life. Their multidimensional impact causes a significant morbidity and mortality.<sup>1</sup> Benign strictures require durable repair because most patients are in otherwise good health and are expected to live for years. The management of biliary strictures presents a significant challenge to surgeons. Management of BBS requires a multidisciplinary approach. If not recognized promptly or if managed improperly, it may result in complications like cholangitis, secondary biliary cirrhosis (SBC), and portal hypertension.<sup>2,3</sup> The long-term outcome in BBS is determined by multiple factors like detailed preoperative evaluation, preoperative optimization, appropriate planning for the surgery, and technical expertise. Preoperative evaluation includes extent of liver dysfunction, associated vascular injury, assessing for complications such as atrophy/hypertrophy complex, SBC, and portal hypertension, establishing the exact level and type of stricture. An accurate anatomical delineation of biliary system by cholangiographic assessment of biliary tree acts

as a road map. This in turn helps to ensure the drainage of all hepatic segments by the proposed bilio-enteric drainage. The success of operative procedure depends directly on the proper and accurate delineation of the injury. Stewart and Way, had shown that the failure rates of the surgery in BBS may increase up to 96% when performed without a preoperative cholangiogram.<sup>4</sup> Magnetic resonance cholangiopancreatography (MRCP) is the preferred mode of investigation to delineate stricture preoperatively owing to its ability to provide a precise anatomical detail with good sensitivity. In spite of its invasive nature, many hepato-pancreatico-biliary (HPB) experts still continue to use percutaneous transhepatic cholangiography (PTC) as a preoperative roadmap in many centers worldwide.

Considering the paucity of data comparing the role of PTC and MRCP in preoperative evaluation, the current study is an attempt to compare the accuracy of PTC over MRCP.

## Methodology

A prospective observational study of all the patients with post-cholecystectomy BBS was performed in a tertiary care center

of north India after the approval of institutional review board. All the patients of BBS who presented between July 2012 and December 2013 were included in the study. Patients with severe comorbid conditions (coronary artery disease, cirrhosis, chronic kidney disease, congestive heart failure) and the patients in whom magnetic resonance imaging was contraindicated were excluded. The clinical details of the patients were noted along with the time to referral from the index cholecystectomy. In case of bile leak or when presented with cholangitis, further management was done using a nonsurgical (percutaneous and/or endoscopic) or an emergency surgical intervention to drain the bile collections and attain a controlled biliary fistula. Definitive repair of the strictures were delayed usually for a minimum of 6 weeks as per institutional protocol. All the clinical, hematological, biochemical, and coagulation parameters were recorded prospectively.

Preoperative MRCP was performed in all patients before admission, and PTC was performed 1 day prior to the surgery or on the day of surgery under antibiotic cover. MRCP was performed on a 3 T MR system (Magnetom Verio, Siemens, and Erlangen, Germany). The patient was kept fasting for 3–4 h before the examination. The standard MRCP protocol included T2-coronal and axial, T1 axial nonfat saturation, T1 axial fat saturation, and T2 HASTE fat saturation thick slab.

PTC was performed in the Department of Radiology under ultrasonography (USG) guidance under antibiotic cover and local anesthesia. The left hepatic ductal system was used for cholangiographic imaging of the biliary tree. In addition, the right hepatic ductal system was used if complete imaging of the biliary tree was not possible with left system. The area to be injected was infiltrated with 2% lignocaine. A 6-inch 20-gauge needle with a stylet was used for the puncture. As the needle was advanced into the liver parenchyma, aspiration by gentle withdrawal of the plunger was carried out until bile was aspirated; radiographs were taken in anterior–posterior, lateral oblique position after the injection of contrast. In cases where dilated bile ducts were not encountered, the needle was advanced to the optimal depth into the liver and small injections of 1.0–2.0 cc. of contrast material were injected at a time. The needle was moved slowly back or forth in the liver parenchyma until the biliary radicles were seen to fill by the contrast material, or the procedure was abandoned. All cholangiograms were performed and reported by a single experienced radiologist in order to avoid observer bias.

After adequate preoperative optimization, all patients underwent the open hepatico-jejunostomy using a modified Blumgart technique. The intraoperative findings were noted. The findings of the preoperative cholangiography both MRCP and PTC were individually corroborated to the intraoperative findings.

**Statistical analysis.** Data were recorded using Microsoft Office Excel 2010 and analyzed using SPSS software v17.0. Sensitivity and specificity were calculated by using the true and false positive and/or negative fraction and standard formulas. Wilcoxon signed rank test was used to compare the data. A *P* value of <0.05 has been taken as statistically significant.

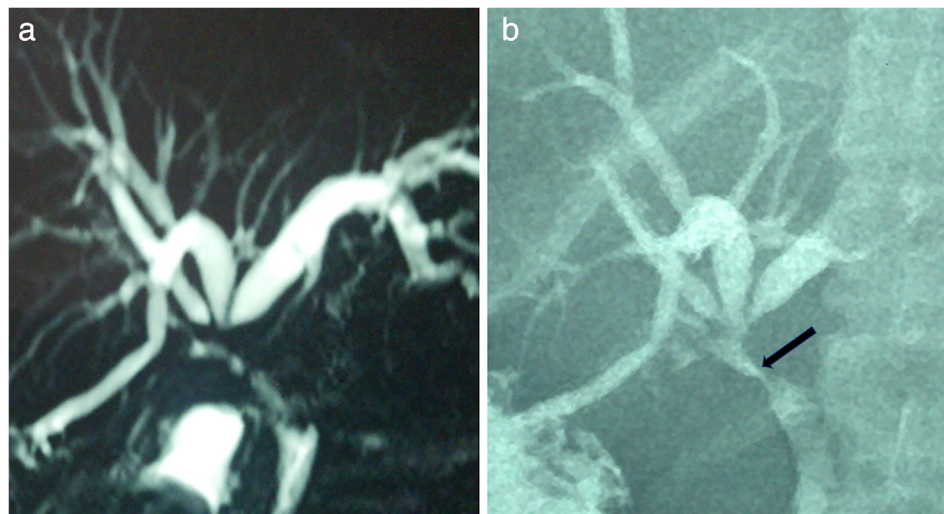## Results

A total of 30 patients with a diagnosis of post-cholecystectomy BBS were analyzed. The mean age of the study population was 41.3 ± 13.2 (range 18–73) years. There were 25 females (83.33%) and 5 males (16.67%). All patients have been referred from outside. The demographic and clinical details of the patients are shown in Table 1.

The median time for detection of biliary injury was 4 days (range 0–120 days). In 4 patients (13%), it was recognized intraoperatively. Intraoperative repair was attempted in one of these patients before the referral to our hospital. Seven patients (23%) presented with bile leak in early postoperative (within 72 h) period, and in rest of the 19 patients (64%), injury was

**Table 1** Demographic and clinical details of the study population

Characteristic	Number (%)
Mean age	41.3 ± 13.2 years
Sex	
Male	25 (86.3%)
Female	05 (16.7%)
Technique of index cholecystectomy	
Open	16 (53%)
Laparoscopic	13 (43%)
Lap converted to open	01 (3%)
Timing of diagnosis of biliary injury	
Intraoperative	04 (13%)
Early postoperative (<72 h)	07 (23%)
3 days to 3 months	17 (56.6%)
>3 months	02 (6.6%)
Symptoms at presentation	
Jaundice	22 (73%)
Bile leak	18 (60%)
Fever	17 (57%)
Pain	15 (50%)
Need for intervention before definitive surgery	
No intervention	07 (23%)
Intervention needed	23 (77%)
Percutaneous (Pigtail, PTBD)	09 (30%)
Endoscopic (ERCP)	02 (6.6%)
Surgery	12 (40%)
Time to definitive repair	
<3 months	08 (26.6%)
3–6 months	10 (33.3%)
>6 months	12 (40%)
Surgery performed	
Roux-en-Y hepatico-jejunostomy	27 (90%)
Redo Roux-en-y hepatico-jejunostomy	03 (10%)
Intraoperative findings	
Type of stricture	
I	01 (3%)
II	03 (10%)
III	18 (60%)
IV	07 (23%)
V	01 (3%)
Anatomical variations in biliary tract	05 (16.7%)
Intrahepatic stones	08 (36.6%)
Fistula (internal; external)	13 (43.3%)



**Figure 1** (a) Magnetic resonance cholangiopancreatography (MRCP) showing trifurcation of ducts at the confluence. (b) Percutaneous transhepatic cholangiography showing trifurcation of bile duct with internal biliary fistula (black arrow), which was not evident on MRCP.

recognized after 72 h following cholecystectomy. Three of these patients presented with a strictured hepatico-jejunostomy. All patients underwent the BBS repair elsewhere and presented after a mean duration of 5.6 years (range 1–9 years).

Before definitive surgery, 23 patients (77%) needed interventions for control of sepsis; surgical exploration was performed in 12 patients (40%) and 11 patients (37%) needed percutaneous interventions in the form of pigtail or percutaneous trans hepatic biliary drainage (PTBD). After preoperative optimization, all patients underwent cholangiography. MRCP was performed in all patients; however, PTC was amenable in 28 patients only. In the remaining two patients, owing to minimal intrahepatic biliary radical dilation (IHBRD), PTC could not be performed. Of the 28 patients who underwent PTC, the test was performed through an already existing PTBD in three patients. All except three patients underwent Roux-en-Y HJ and the remaining three underwent redo hepatico-jejunostomy for recurrent stricture.

Eight patients (27%) underwent Roux-en-Y HJ within 3 months from biliary injury, 10 patients (33%) underwent HJ between 3 and 6 months after biliary injury, and 12 patients (40%) after a period of 6 months. Intraoperative findings with respect to the type of stricture, anatomical variations, intrahepatic stones, and biliary fistulae (internal and external) are described in

Table 1. Intraoperative findings were corroborated with the findings of MRCP and PTC in 28 patients. Postoperative period was uneventful in all the patients (Figure 1).

The diagnostic accuracy, sensitivity, and specificity of MRCP and PTC in determining the stricture type, anatomical variations of biliary anatomy, intrahepatic stones, and fistula are described in Table 2. None of the patients had complications related to MRCP while complications due to PTC were reported in 2 (7%) patients, which include mild cholangitis in one patient requiring intravenous antibiotic and another patient had left lobe subcapsular hematoma identified intraoperatively.

## Discussion

Injury to the biliary tract is a serious complication after cholecystectomy accounting for significant morbidity and mortality. The incidence of biliary injury is reported to be higher in laparoscopic cholecystectomy (0.5–0.89%) than in open cholecystectomy (0.2%).<sup>5,6</sup> In this study, open cholecystectomy contributed to higher BDI than laparoscopic cholecystectomy, which were 53% and 43% respectively, while the remaining 4% were laparoscopic converted to open, which is similar to the incidence reported by Chaudhary *et al.*<sup>7</sup> This is possibly due to a higher number of

**Table 2** Comparative table for the diagnostic accuracy of percutaneous transhepatic cholangiography (PTC) over magnetic resonance cholangiopancreatography (MRCP)

	MRCP			PTC			P value
	sensitivity	Specificity	Diagnostic accuracy	Sensitivity	Specificity	Diagnostic accuracy	
Stricture type	NR <sup>†</sup>	NR <sup>†</sup>	89.3%	NR <sup>†</sup>	NR <sup>†</sup>	96.4%	0.317
Variations in biliary anatomy	95.6%	100%	96.4%	100%	100%	100%	0.317
stone	75%	90%	85.7%	75%	100%	92.8%	0.414
Fistula	61.4%	100%	82.1%	85.7%	100%	96.4%	0.04

<sup>†</sup>The sensitivity and the specificity were not recorded in that specific parameters for MRCP and PTC.

open cholecystectomies still being performed, especially in developing countries.

Evidence suggests that the outcome of definitive repair can be improved when performed by an experienced hepatobiliary surgeon. The preoperative optimization of the patient condition with respect to control of sepsis, nutritional rehabilitation, and accurate assessment of complexity of the injury (type of stricture, associated vascular injury, atrophy–hypertrophy complex of liver, SBC, portal hypertension) are the corner stones for the improvement of the long-term outcome.<sup>3,8,9</sup> In addition to these factors, timing of the definitive repair is also pivotal in determining the outcome. However, the optimal timing for repair is still debatable even though evidence suggests an inclination toward the delayed repair worldwide.<sup>10–13</sup>

In our study, intraoperative findings showed Bismuth Type III and Type IV strictures are the most common types of strictures. They accounted for 18 (60%) and 7 patients (23%) respectively, which concord with the previous studies by Blumgart *et al.* and Sarno *et al.*, where type III strictures were the most commonly reported.<sup>14,15</sup>

Although MRCP has fast become the choice of investigation for preoperative evaluation at most hepatobiliary centers, the proponents for PTC still feel that it provides a better road map before attempting the repair in complex biliary injury.<sup>8</sup>

In this study, MRCP and PTC both were found to be very useful in identification of the type of stricture, variation in biliary anatomy, intrahepatic stones, and biliary fistulae with some differences as discussed further. We observed that the diagnostic accuracy of PTC was better than MRCP with respect to the identification of the type of stricture (96.4% vs 89.3%), although it was not statistically significant. MRCP and PTC had shown some discrepancies with respect to the type of stricture. In three patients, the stricture type was assessed as type II on MRCP but on PTC it was reported as type III. In all these patients, intraoperatively, the findings corroborated with PTC. Also in one patient, PTC had underestimated the stricture as type II and on MRCP it appeared as type III. The intraoperative findings have corroborated with MRCP in this instance. However, both the situations did not necessitate any change in management in any of these patients. In none of the patients there was no difference between PTC and MRCP in reporting type III and Type IV injuries.

However, MRCP and PTC had a comparable sensitivity and specificity with respect to the identification of the variations in biliary anatomy (95.6% vs 100%) and diagnosing intrahepatic stones (75% vs 75%). These observations of the comparability of MRCP and PTC in detecting the type of stricture, intrahepatic calculi were in accordance to the previous study conducted by Chaudhary *et al.* in 26 patients.<sup>7</sup>

In our study, PTC was found to be more sensitive over the MRCP (85.7% vs 61.4%; *P* value 0.04) in identifying biliary fistulae. PTC could identify internal biliary fistulae in four patients, which were not shown on MRCP. Although the higher sensitivity and specificity of PTC in identifying the biliary fistula are never reported to the best of our knowledge, its clinical importance is still questionable.

In spite of these advantages, PTC suffers disadvantages like failure of the procedure, need for multiple punctures in complex strictures (Type IV and V), need for intervention, requirement of intravenous analgesics after the procedure, lack of information regarding vascular anomalies, intra-abdominal

collections, risk of cholangitis, and bleeding, which make it a less preferred investigation over MRCP.

In the current study, complications due to PTC were observed in two patients (7%), which include cholangitis (3.5%), and subcapsular left lobe hematoma (3.5%) at the site of puncture, which was detected intraoperatively. However, none of these complications have changed the course of treatment. No major complications like systemic sepsis induced by cholangitis and hemobilia, which are well documented in the literature following PTC, have occurred in our study.<sup>16</sup>

## Conclusion

MRCP and PTC were comparable in diagnosing the stricture type, intrahepatic biliary stones, and biliary anomalies. Even though PTC had a better sensitivity to diagnose internal biliary fistula, it did not additionally contribute to preoperative decision-making when compared with MRCP. Owing to its noninvasive nature and its ability to provide more information makes MRCP the investigation of choice over PTC in BBS.

## References

- Otto W, Sierdziński J, Smaga J, Dudek K, Zieniewicz K. Long-term effects and quality of life following definitive bile duct reconstruction. *Medicine*. 2018; **97**: e12684.
- Lillemoe KD, Melton GB, Cameron JL *et al.* Postoperative bile duct strictures: management and outcome in the 1990s. *Ann. Surg.* 2000; **232**: 430–41.
- Schreuder AM, Busch OR, Besseling MG *et al.* Long-term impact of iatrogenic bile duct injury. *Dig. Surg.* 2020; **37**: 10–21.
- Stewart L, Way LW. Bile duct injuries during laparoscopic cholecystectomy. Factors that influence the results of treatment. *Arch. Surg.* 1995; **130**: 1123–9.
- MacFadyen BV Jr, Vecchio R, Ricardo AE, Mathis CR. Bile duct injury after laparoscopic cholecystectomy. *Surg Endosc.* 1998; **12**: 315–21.
- Roslyn JJ, Binns GS, Hughes EF, Saunders-Kirkwood K, Zinner MJ, Cates JA. Open cholecystectomy. A contemporary analysis of 42,474 patients. *Ann. Surg.* 1993; **218**: 129–37.
- Chaudhary A, Manisegran M, Chandra A, Agarwal AK, Sachdev AK. How do bile duct injuries sustained during laparoscopic cholecystectomy differ from those during open cholecystectomy? *J. Laparoendosc. Adv. Surg. Tech. A.* 2001; **11**: 187–91.
- Sikora SS. Management of post-cholecystectomy benign bile duct strictures: review. *Indian J. Surg.* 2012; **74**: 22–8.
- Pottakkat B, Vijayahari R, Prasad KV *et al.* Surgical management of patients with post-cholecystectomy benign biliary stricture complicated by atrophy–hypertrophy complex of the liver. *HPB.* 2009; **11**: 125–9.
- A European-African HepatoPancreatoBiliary Association (E-AHPBA) Research Collaborative Study management group; Other members of the European-African HepatoPancreatoBiliary Association Research Collaborative. Post cholecystectomy bile duct injury: early, intermediate or late repair with hepaticojejunostomy—an E-AHPBA multi-center study. *HPB.* 2019; **21**: 1641–7.
- Stilling NM, Frstrup C, Wettergren A *et al.* Long-term outcome after early repair of iatrogenic bile duct injury. A national Danish multicentre study. *HPB.* 2015; **17**: 394–400.
- Ismael HN, Cox S, Cooper A, Narula N, Aloia T. The morbidity and mortality of hepaticojejunostomies for complex bile duct injuries: a multi-institutional analysis of risk factors and outcomes using NSQIP. *HPB.* 2017; **19**: 352–8.

- 13 Wang X, Yu WL, Fu XH, Zhu B, Zhao T, Zhang YJ. Early versus delayed surgical repair and referral for patients with bile duct injury: a systematic review and meta-analysis. *Ann. Surg.* 2020; **271**: 449–59.
- 14 Blumgart LH, Kelley CJ, Benjamin IS. Benign bile duct stricture following cholecystectomy: critical factors in management. *Br. J. Surg.* 1984; **71**: 836–43.
- 15 Sarno G, Al-Sarira AA, Ghaneh P, Fenwick SW, Malik HZ, Poston GJ. Cholecystectomy-related bile duct and vasculobiliary injuries. *Br J Surg.* 2012; **99**: 1129–36.
- 16 Choi SH, Gwon DI, Ko GY *et al.* Hepatic arterial injuries in 3110 patients following percutaneous transhepatic biliary drainage. *Radiology.* 2011 Dec; **261**: 969–75.