

CASE REPORT

Open Access



A novel elastin gene frameshift mutation in a Russian family with cutis laxa: a case report

E. G. Okuneva¹, A. A. Kozina², N. V. Baryshnikova^{1,3}, A. Yu Krasnenko^{1,3}, K. Yu Tsukanov¹, O. I. Klimchuk¹, E. I. Surkova^{1*} and V. V. Ilinsky^{3,4}

Abstract

Background: Cutis laxa (CL) is a rare connective tissue disorder characterized by loose, redundant, inelastic and wrinkled skin. Patients develop a prematurely aged appearance. Inheritance can be autosomal dominant or autosomal recessive. The X-linked form is now classified in the group of copper transport diseases. Autosomal dominant CL is characterized by wrinkled, redundant and sagging, inelastic skin and in some cases is associated with internal organ involvement.

Case presentation: We report a familial case of autosomal dominant CL, which includes a 33-year-old woman and her 11-year-old son with dry, thin and wrinkled skin that appeared prematurely aged. No serious involvement of internal organs was found. In both patients, we identified novel heterozygous mutation c.2323delG (p.Ala775fs) in exon 34 of elastin transcript NM_001278939.1. Similar frameshift mutations in the last exons of elastin gene were previously reported in patients with autosomal dominant CL.

Conclusions: Our results show a novel frameshift mutation that was found in patients with cutis laxa. Exome sequencing is effective and useful technology for properly diagnosis of diseases with similar phenotype to ensure proper treatment is provided.

Keywords: Cutis laxa, Elastolysis, Elastin, *ELN*, Progeria

Background

Cutis laxa (CL), or elastolysis, is a group of rare connective tissue disorders characterized by loose, redundant, wrinkled skin [1]. The disease can be inherited or acquired. Inherited form can be autosomal dominant or autosomal recessive. The formerly classified X-linked form, caused by mutations in the *ATP7A* gene, is now classified within the group of copper deficiency syndromes and has been shown to be allelic with Menkes syndrome [2].

CL is caused by mutations in multiple genes, crucial for genesis of elastic fibers [3]. Elastic fibers are extracellular matrix structures responsible for properties of resilience and elastic recoil in all elastic tissues including

lungs, large blood vessels and dermis. Histologically, cutis laxa elastic fibers are sparse and fragmented [4].

Differences in clinical presentation of congenital forms of CL depend on the pattern of inheritance. Autosomal dominant cutis laxa (ADCL) is characterized by a generalized loose skin folds and distinctive facial features including long philtrum, a high and broad forehead, prominent ears, and a beak-like nose. Other manifestations occasionally include aortic root dilatation, pulmonary artery stenosis, emphysema and sudden death. ADCL is commonly considered as a milder form of CL with minor systemic involvement and normal neuromotor development whereas ARCL (autosomal recessive form) is more severe with many involved systems and poor prognosis [5].

Elastin gene mutations predominate as the cause of autosomal dominant cutis laxa (OMIM 123700). *ELN* gene is a single-copy gene with 34 exons localized in

* Correspondence: esurkova@genotek.ru

¹Genotek Ltd., Nastavnicheskii pereulok 17/1, 105120 Moscow, Russia
Full list of author information is available at the end of the article



humans at 7q11.2. Most patients with ADCL have heterozygous frameshift deletions that are localized in last 5 exons of *ELN* [6–9]. Also, a mutation in exon 25 of *ELN* has been described for ADCL patients [10]. Other ADCL-causing mutations were also identified in *FBLN5* [11] and *ALDH18A1* [12].

In this study we analyzed clinical and genetic characteristics of 33-year-old female proband and her 11-year-old son with dry and wrinkled skin. Differential diagnosis was conducted between progeria and cutis laxa.

Case presentation

The two patients are the proband and her son from Kazakhstan who are Russian by nationality. Both patients have dry, wrinkled skin and look older than their age (Fig. 1). Family history was negative for similar clinical conditions, indicating de novo mutation occurring in the proband or incomplete penetrance in previous generations.

Patient 1 mother

Cutis laxa was noted immediately at birth. Height and weight at birth were normal. In childhood, frequent colds were observed. Over the past twenty years, the severity of skin changes has increased (skin has become drier, thinner, and more wrinkled). Weakness and fatigue also progressed.

At the age of 33 years her height and weight were 167 cm (72 percentile) and 49 kg (11 percentile), respectively. Blood pressure was 110/70 mmHg. Skin was dry, thinned and wrinkled. Subcutaneous fat layer was thinned out. Low muscle tone was observed. Hair, nails and teeth were normal. Biochemical blood test did not reveal abnormalities. Respiratory examination revealed normal vesicular breathing, carried out in all lung compartments, there was no wheezing. Heart sounds were clear and rhythmic. Heart rate was 66 beats per minute.

Cardiovascular evaluation by echocardiography revealed mitral valve prolapse and diffuse changes in myocardium. Aortic root diameter was 27 mm (normal range 18.8–25.4 mm). Abdomen was soft and painless. Ophthalmologic examination demonstrated exotropia and myopic astigmatism of both eyes. Stool was with a tendency to constipation. Micturition was normal. Intelligence was normal.

The patient had the following concomitant diseases: endemic goiter, chronic cholecystitis in remission, chronic pyelonephritis in remission, chronic pancreatitis in remission. She was on treatment with Levothyroxine sodium (150 mg/day) to treat goiter.

Differential diagnosis was carried out with progeria. Level of glucose (4.7 mmol/L) and cholesterol (5.7 mmol/L) in biochemical analysis of blood was normal, so cutis laxa was suggested.

Patient 2 son

Height and weight at birth were 53 cm (94.5 percentile) and 3850 g (91.9 percentile), respectively. Skin laxity was first noticed at the age of 1 year.

At the age of 11 years his height and weight were 159 cm (98.9 percentile) and 34 kg (38.2 percentile) respectively. Height was above average in contrast to a small deficit in weight. The patient had thymomegaly and allergic reactions in early childhood. Cardiovascular evaluation by electrocardiography revealed single extrasystoles. Aortic root diameter was 23 mm (normal range 18.8–25.4 mm). Ophthalmologic examination demonstrated myopia of mild degree of both eyes. Intelligence was normal.

Clinical exome sequencing was done by Genotek Ltd. Ethics committee of Genotek Ltd. has approved the study (07/2018). The proband (mother) gave written informed consent to studies and publication of clinical information, images and sequencing data of her and her son.

Genomic DNA from peripheral blood samples of the proband and her son was collected using QIAamp DNA Mini Kit (Qiagen, Hilden, Germany). We did not test DNA from maternal grandparents due to the unavailability of the material. DNA libraries were constructed using the NEBNext Ultra DNA Library Prep Kit for Illumina (New England Biolabs, Ipswich, MA, USA) with adapters for sequencing on Illumina platform according to manufacturer's protocol. For target enrichment, we used SureSelect XT2 (Agilent Technologies, Santa Clara, CA, USA). Enriched samples were sequenced using an Illumina HiSeq 2500 system (Illumina, San Diego, CA, USA) in paired-end mode (100 bp reads). We trimmed 3'-ends with read quality below 10 using Cutadapt [13]. We used SAMtools rmdup for duplicate removal [14] and FASTQS for quality control of data [15]. Sequences were analyzed as recommended by GATK Best Practices for DNA-seq [16, 17]: mapping was performed using BWA-MEM [18], variant calling using GATK




Fig. 1 Clinical photograph of proband and her son, ages 33 and 11, respectively

HaplotypeCaller [19]. The effect of each mutation was assessed using snpEff [20]. To evaluate pathogenicity and conservation, the data was extracted from the dbNSFP [21], Clinvar [22, 23], OMIM [24] and HGMD [25]. Pathogenicity prediction by SIFT and PolyPhen-2 was not carried out due to the limitation of their use for this type of mutation. Allele frequency information was obtained from 1000 Genomes project [26, 27], ExAC [28, 29] and Genotek frequency data. Pathogenicity was predicted according to the Standards and Guidelines developed by ACMG (American College of Medical Genetics and Genomics), AMP (Association for Molecular Pathology) and CAP (College of American Pathologists) [30]. Copy number alterations were determined using CNVkit [31].

Using Sanger sequencing, the new identified *ELN* pathogenic mutation was confirmed in the proband and her son.

Discussion and conclusions

Exome analysis showed a novel heterozygous c.2323delG mutation of elastin gene in both patients (mother and son). This mutation is single nucleotide deletion in 34 exon (NM_001278939.1) and results in a shift of reading frame. Mutation was confirmed by Sanger sequencing (Fig. 2).

This mutation was not previously reported in literature, nor in the 60,706 subjects in ExAC, the 2535 subjects in the 1000 Genomes browser, or the 2000 Genotek patients. According to ACMG recommendations, this mutation is considered to be pathogenic - deletion with frameshift.

We also found that the proband and his son have two missense mutations: the c.2738C>T (p.Ala913Val) in the *KCNH2* gene and the c.233C>T (p.Thr78Met) in *CAV3* gene. According to ACMG recommendations, both mutations are considered to be pathogenic. Both mutations were described by Vatta et al. in patient with digenic form of congenital long-QT syndrome [32].

No other pathogenic variants and CNVs were found.

We discovered a novel frameshift mutation (c.2323delG, p.Ala775fs) in a two-patient Russian family with cutis laxa, presenting with phenotypes consistent with those previously reported. Although novel, this mutation is similar to frameshift mutations previously reported in *ELN*, for example c.2156delG described by Duz et al. [33]. Frameshift mutations of human elastin gene have been identified in several families with autosomal dominant cutis laxa [5, 7]. These mutations are deletions of guanine or cytosine in distal *ELN* exons. The location of the mutation correlates with the phenotype of patients. Mutations in the last exons cause fewer cardiovascular and pulmonary abnormalities than mutations elsewhere [6, 8].

Elastin is the primary protein determinant of connective tissue elasticity and also plays a critical role in development of cardiovascular and respiratory systems [34, 35]. Therefore, these systems are often affected in cutis laxa patients. This is especially characteristic of the autosomal recessive form, however, inguinal hernias, emphysema, aortic aneurysmal disease and root dilatation has also been described in the autosomal dominant form of cutis laxa

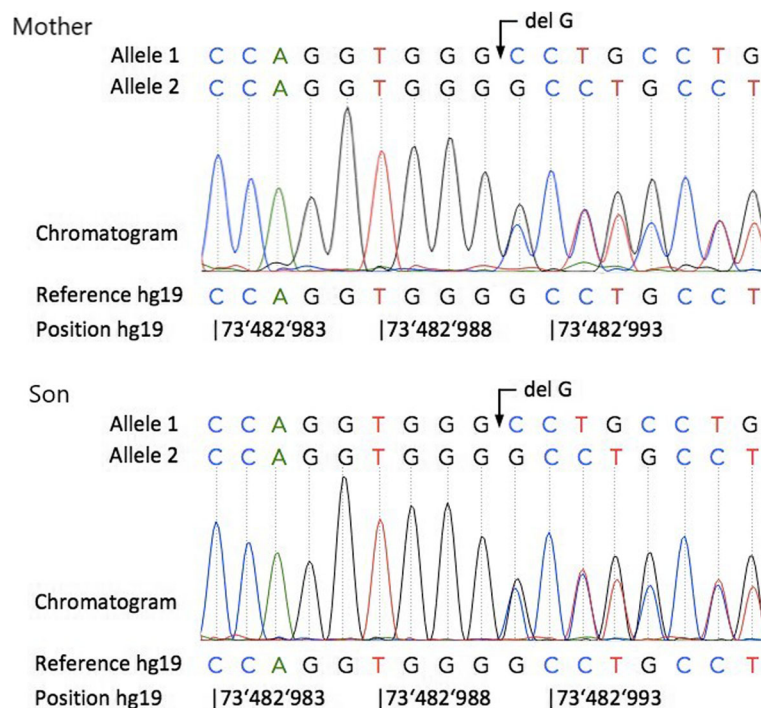


Fig. 2 DNA sequencing chromatograms from proband (Mother) and her son (Son) showing the heterozygous c.2323delG mutation in both patients

[8, 36, 37]. Some *ELN* mutations (as partial tandem duplication in the elastin locus) can lead to fatal pulmonary complications [38]. Translocations, gross deletions and point mutations that disrupt the elastin gene lead to supravalvular aortic stenosis (OMIM 185500) [39]. Our patients did not have serious failures of internal organs consistent with a typical form of ADCL. Patient described by Duz et al. [33] also had only skin findings without cardiovascular and pulmonary complications. It is likely that mutations resulting in an elongated protein lead to this clinical phenotype.

Little is known about molecular mechanisms of ADCL. Callewaert with colleagues concluded that this form of cutis laxa is associated with increased TGF β signaling and mutation-specific differences in endoplasmic reticulum stress and apoptosis [6].

There is overlapping of clinical features of several syndromes, including progeria, congenital cutis laxa, wrinkly skin syndrome and progeria osteodysplastica. All these conditions are challenging for clinicians. Our case confirmed that molecular diagnosis is the only way to resolve these phenotypically similar conditions.

Abbreviations

ACMG: American College of Medical Genetics and Genomics; ADCL: autosomal dominant cutis laxa; AMP: Association for Molecular Pathology; CAP: College of American Pathologists; CL: Cutis laxa

Acknowledgments

We are grateful to the patients with cutis laxa for their participation of this study.

Funding

Analysis and interpretation of data were carried out with financial support from the Fundamental Scientific Research Program of the Russian Academy of Sciences for 2013–2020.

Availability of data and materials

We did not use new software, databases, or applications/tools in the manuscript. The datasets used and analyzed during the current study available from the corresponding author on reasonable request.

Authors' contributions

EG, AA, NV, AYu, KYu, OI, EI, W met the International Committee of Medical Journal Editors (ICMJE) criteria for authorship. EG, AA, NV and EI contributed to data collection and the first draft of the manuscript. AYu, KYu and OI carried out the mutation analysis, interpretation of data and revised the manuscript. EG cared for the patient. W was a mentor who developed design of the study and substantially revised the manuscript. All authors read and approved the final manuscript.

Ethics approval and consent to participate

All research was approved by the ethics committee of Genotek Ltd. (07/2018). The proband (mother) has signed informed consent to participate in this study for herself and for her son.

Consent for publication

The proband gave written informed consent to studies and publication of clinical information, images and sequencing data of her and her son.

Competing interests

The Authors are employed by Genotek Ltd. The Authors declare that there is no other conflicting interests.

Publisher's Note

Springer Nature remains neutral with regard to jurisdictional claims in published maps and institutional affiliations.

Author details

¹Genotek Ltd., Nastavnicheskii pereulok 17/1, 105120 Moscow, Russia. ²Institute of Biomedical Chemistry, Pogodinskaya street 10 building 8, 119121 Moscow, Russia. ³Pirogov Russian National Research Medical University, Ostrovitianova street 1, 117997 Moscow, Russia. ⁴Vavilov Institute of General Genetics, Gubkina street 3, 119333 Moscow, Russia.

Received: 10 August 2018 Accepted: 28 January 2019

Published online: 31 January 2019

References

- Berk DR, Bentley DD, Bayliss SJ, Lind A, Urban Z. Cutis laxa: a review. *J Am Acad Dermatol*. 2012;66(5):842.e1–17. <https://doi.org/10.1016/j.jaad.2011.01.004>.
- Das S, Levinson B, Vulpe C, Whitney S, Gitschier J, Packman S. Similar splicing mutations of the Menkes/mottled copper-transporting ATPase gene in occipital horn syndrome and the blotchy mouse. *Am J Hum Genet*. 1995; 56(3):570–6.
- Urban Z. The complexity of elastic fiber biogenesis: the paradigm of cutis laxa. *J Invest Dermatol*. 2012;132(E1):E12–4. <https://doi.org/10.1038/skinbio.2012.4>.
- Fazio MJ, Olsen DR, Uitto JJ. Skin aging: lessons from cutis laxa and elastoderma. *Cutis*. 1989;43(5):437–44.
- Rodriguez-Revenga L, Iranzo P, Badenas C, Puig S, Carrió A, Millà M. A novel elastin gene mutation resulting in an autosomal dominant form of cutis laxa. *Arch Dermatol*. 2004;140(9):1135–9.
- Callewaert B, Renard M, Huchtagowder V, Albrecht B, Hausser I, Blair E, et al. New insights into the pathogenesis of autosomal-dominant cutis laxa with report of five *ELN* mutations. *Hum Mutat*. 2011;32(4):445–55. <https://doi.org/10.1002/humu.21462>.
- Zhang MC, He L, Giro M, Yong SL, Tiller GE, Davidson JM. Cutis laxa arising from frameshift mutations in exon 30 of the elastin gene (*ELN*). *J Biol Chem*. 1999;274(2):981–6.
- Hadj-Rabia S, Callewaert BL, Bourrat E, Kempers M, Plomp AS, Layet V, et al. Twenty patients including 7 probands with autosomal dominant cutis laxa confirm clinical and molecular homogeneity. *Orphanet J Rare Dis*. 2013;8:36. <https://doi.org/10.1186/1750-1172-8-36>.
- Siefring ML, Lawrence EC, Nguyen TC, Lu D, Pham G, Lorenchick C, et al. A novel elastin gene mutation in a Vietnamese patient with cutis laxa. *Pediatr Dermatol*. 2014;31(3):347–9. <https://doi.org/10.1111/pde.12334>.
- Graul-Neumann LM, Hausser I, Essayie M, Rauch A, Kraus C. Highly variable cutis laxa resulting from a dominant splicing mutation of the elastin gene. *Am J Med Genet A*. 2008;146A(8):977–83. <https://doi.org/10.1002/ajmg.a.32242>.
- Markova D, Zou Y, Ringpfeil F, Sasaki T, Kostka G, Timpl R, et al. Genetic heterogeneity of cutis laxa: a heterozygous tandem duplication within the fibulin-5 (*FBLN5*) gene. *Am J Hum Genet*. 2003;72(4):998–1004.
- Bhola PT, Hartley T, Bareke E. Care4Rare Canada Consortium, Boycott KM, Nikkel SM, et al. autosomal dominant cutis laxa with progeroid features due to a novel, de novo mutation in *ALDH18A1*. *J Hum Genet*. 2017;62(6):661–3. <https://doi.org/10.1038/jhg.2017.18>.
- Martin M. Cutadapt removes adapter sequences from high-throughput sequencing reads. *EMBnetjournal*. 2011;17:10–2.
- Li H, Handsaker B, Wysoker A, Fennell T, Ruan J, Homer N, et al. The sequence alignment/map format and SAMtools. *Bioinformatics*. 2009;25(16): 2078–9.
- FastQC: a quality control tool for high throughput sequence data. <https://www.bioinformatics.babraham.ac.uk/projects/fastqc/>. Accessed 26 July 2018.
- DePristo MA, Banks E, Poplin R, Garimella KV, Maguire JR, Hartl C, et al. A framework for variation discovery and genotyping using next-generation DNA sequencing data. *Nat Genet*. 2011;43(5):491–8. <https://doi.org/10.1038/ng.806>.
- Van der Auwera GA, Carneiro MO, Hartl C, Poplin R, del Angel G, Levy-Moonshine A, et al. From FastQ data to high confidence variant calls: the Genome Analysis Toolkit best practices pipeline. *Curr Protoc Bioinformatics*. 2013;11(1110):11.10.1–11.10.33. <https://doi.org/10.1002/0471250953.bi1110s43>.

18. Li H, Durbin R. Fast and accurate short read alignment with burrows-wheeler transform. *Bioinformatics*. 2009;25(14):1754–60.
19. McKenna A, Hanna M, Banks E, Sivachenko A, Cibulskis K, Kernytzky A, et al. The genome analysis toolkit: a MapReduce framework for analyzing next-generation DNA sequencing data. *Genome Res*. 2010;20(9):1297–303. <https://doi.org/10.1101/gr.107524.110>.
20. Cingolani P, Platts A, Wang LL, Coon M, Nguyen T, Wang L, et al. A program for annotating and predicting the effects of single nucleotide polymorphisms, SnpEff: SNPs in the genome of *Drosophila melanogaster* strain w1118; iso-2; iso-3. *Fly (Austin)*. 2012;6(2):80–92. <https://doi.org/10.4161/fly.19695>.
21. Liu X, Wu C, Li C, Boerwinkle E. dbNSFP v3.0: a one-stop database of functional predictions and annotations for human non-synonymous and splice site SNVs. *Hum Mutat*. 2016;37(3):235–41.
22. ClinVar. <http://www.ncbi.nlm.nih.gov/clinvar/>. Accessed 26 July 2018.
23. Landrum MJ, Lee JM, Benson M, Brown G, Chao C, Chitipiralla S, et al. ClinVar: public archive of interpretations of clinically relevant variants. *Nucleic Acids Res*. 2016;44(Database issue):D862–8. <https://doi.org/10.1093/nar/gkv1222>.
24. OMIM database (Online Mendelian Inheritance in Man). <https://omim.org/>. Accessed 26 July 2018.
25. The Human Gene Mutation Database. <http://www.hgmd.cf.ac.uk/ac/gene.php?gene=CTNS>. Accessed 26 July 2018.
26. 1000Genomes project. <http://browser.1000genomes.org/index.html>. Accessed 26 July 2018.
27. 1000 Genomes Project Consortium, Auton A, Brooks LD, Durbin RM, Garrison EP, Kang HM, et al. A global reference for human genetic variation. *Nature*. 2015;526(7571):68–74. <https://doi.org/10.1038/nature15393>.
28. ExAC (Exome Aggregation Consortium). <http://exac.broadinstitute.org/>. Accessed 26 July 2018.
29. Lek M, Karczewski KJ, Minikel EV, Samocha KE, Banks E, Fennell T, et al. Analysis of protein-coding genetic variation in 60,706 humans. *Nature*. 2016;536(7616):285–91. <https://doi.org/10.1038/nature19057>.
30. Richards S, Aziz N, Bale S, Bick D, Das S, Gastier-Foster J, et al. Standards and guidelines for the interpretation of sequence variants: a joint consensus recommendation of the American College of Medical Genetics and Genomics and the Association for Molecular Pathology. *Genet Med*. 2015;17(5):405–23.
31. Talevich E, Shain AH, Botton T, Bastian BC. CNVkit: genome-wide copy number detection and visualization from targeted sequencing. *PLoS Comput Biol*. 2014;12(4):e1004873.
32. Vatta M, Ackerman MJ, Ye B, Makielski JC, Ughanze EE, Taylor EW, Tester DJ, Balijepalli RC, Foell JD, Li Z, Kamp TJ, Towbin JA. Mutant caveolin-3 induces persistent late sodium current and is associated with long-QT syndrome. *Circulation*. 2006;114(20):2104–12.
33. Duz MB, Kirat E, Coucke PJ, Koparir E, Gezdirici A, Paeppe A, et al. A novel case of autosomal dominant cutis laxa in a consanguineous family: report and literature review. *Clin Dysmorphol*. 2017;26(3):142–7. <https://doi.org/10.1097/MCD.0000000000000179>.
34. Dietz HC, Mecham RP. Mouse models of genetic diseases resulting from mutations in elastic fiber proteins. *Matrix Biol*. 2000;19(6):481–8.
35. Milewicz DM, Urbán Z, Boyd C. Genetic disorders of the elastic fiber system. *Matrix Biol*. 2000;19(6):471–80.
36. Corbett E, Glaisyer H, Chan C, Madden B, Khaghani A, Yacoub M. Congenital cutis laxa with a dominant inheritance and early onset emphysema. *Thorax*. 1994 Aug;49(8):836–7.
37. Szabo Z, Crepeau MW, Mitchell AL, Stephan MJ, Puntel RA, Yin Loke K, et al. Aortic aneurysmal disease and cutis laxa caused by defects in the elastin gene. *J Med Genet*. 2006;43(3):255–8.
38. Urban Z, Gao J, Pope FM, Davis EC. Autosomal dominant cutis laxa with severe lung disease: synthesis and matrix deposition of mutant tropoelastin. *J Invest Dermatol*. 2005 Jun;124(6):1193–9.
39. Metcalfe K, Rucka AK, Smoot L, Hofstadler G, Tuzler G, McKeown P, et al. Elastin: mutational spectrum in supravalvular aortic stenosis. *Eur J Hum Genet*. 2000;8(12):955–63.

Ready to submit your research? Choose BMC and benefit from:

- fast, convenient online submission
- thorough peer review by experienced researchers in your field
- rapid publication on acceptance
- support for research data, including large and complex data types
- gold Open Access which fosters wider collaboration and increased citations
- maximum visibility for your research: over 100M website views per year

At BMC, research is always in progress.

Learn more biomedcentral.com/submissions

